

## Root resorption in deciduous teeth after applying orthodontic forces

A.P. Fiore Aguilar / A.G. Aquila / A.M. Ubios

*The relation between orthodontic forces applied to deciduous teeth and the occurrence of root resorption, as a possible outcome of these forces, has not been studied to date. The aim of this work was to study root resorption in deciduous teeth of patients receiving orthodontic treatment. Twenty-four deciduous molars extracted for therapeutic purposes were studied: nineteen molars treated with light orthodontic forces and five untreated molars that served as control. Histological and histomorphometric studies were performed to determine the magnitude of root resorption. Location of root resorption in treated deciduous teeth was different from that of physiological root resorption. Extent and volume of root resorption were more extensive and deeper in treated than in untreated teeth. These results suggest that radiographic follow-up of deciduous teeth subjected to orthodontic forces would be useful to prevent root fractures.*

J Clin Pediatr Dent 29(4): 283-286, 2005

### INTRODUCTION

To allow for exfoliation and eruption of the successional teeth, the deciduous tooth undergoes root resorption<sup>1</sup>. Mineralized dental tissues are resorbed by cells termed odontoclasts, which are similar to osteoclasts in histological features.<sup>2</sup> As a result of this process, eroded surfaces can be observed on the root.<sup>3,4</sup> Resorption of hard tissues, which occurs prior to exfoliation, sometimes alternates with another process involving cementum apposition in the same area.

Cement-like tissue forms to compensate for the resorbed tissue.<sup>5</sup> This tissue is more eosinophilic and more cellular than cementum.<sup>6</sup> The orientation of root resorption differs according to whether the tooth has one or more roots. Deciduous molars are succeeded by permanent premolars, so that the tooth germs of the latter are located between the diverging roots of the deciduous molars. For this reason, root resorption begins on the apical third of the radicular aspect facing the interradicular septum.

Between the onset of shedding of deciduous teeth and eruption of all permanent teeth, there is a transition period, termed mixed dentition, during which both types of dentition co-exist. Detection and prognosis of anomalous positioning of teeth is possible during this time. At this stage, preserving the deciduous teeth is strongly recommended in order to prevent premature loss of space. Orthodontic treatments aim to correcting dental arch, occlusal and intermaxillary anomalies, and to eliminating functional interferences.<sup>7</sup> These orthodontic treatments are interceptive and are currently initiated at a very early age, when the child is still at the mixed dentition stage.

One of the complications of orthodontic treatments applied to permanent teeth is the occurrence of areas of root resorption.<sup>8</sup> For that reason, the caliber of the orthodontic wires must be in accordance with the force the movement required, in order to diminish risk of root resorption. Thus, it is essential to control the force and follow-up closely on the compromised teeth. Although physiological root resorption at shedding has been investigated thoroughly, there are no reports to date on root resorption in deciduous teeth as a possible outcome of orthodontic treatment.

A great number of issues related to physiological resorption in animals have been clarified since Hesse,<sup>9</sup> Kronfeld<sup>10</sup> and Hardnt.<sup>11</sup> In 1961, Zerossi<sup>3</sup> described areas of resorption and apposition of cement-like tissue during shedding, and more recently Sasaki *et al.*,<sup>4</sup> Sahara *et al.*,<sup>5</sup> Wo *et al.*,<sup>2</sup> and other authors contributed data on the histological characteristics of resorption and shedding.

Department of Histology and Embryology, School of Dentistry, University of Buenos Aires

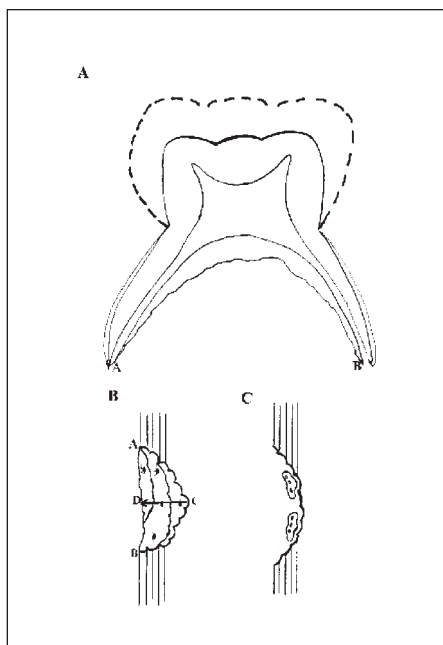
Send all correspondence to Dr. A.M. Ubios, Department of Histology and Embryology,

School of Dentistry, University of Buenos Aires, Marcelo T. de Alvear 2142- 1° A, C1122AAH Buenos Aires, Argentina.

Voice: 5411-49641270

Fax: 5411-45083958 (Fax)

E-mail: amubios@histo.odon.uba.ar



**Figure 1.** (A) Schematic drawing of a deciduous tooth showing the surface of resorption measured from point A, the most apical point covered with cementum on the mesial aspect of the root, to point B, the most apical point on the distal aspect. (B) Diagram depicting repaired resorption. Segment CD shows the maximum depth of resorption. (C) Schematic drawing of non-repaired resorption with odontoclasts on the surface.

Application of orthodontic forces causes a change in the spatial relationship between the deciduous and successional teeth, which may result in the emergence of resorption areas at different sites from those typically associated with physiological resorption. Deciduous teeth subjected to orthodontic forces also undergo physiological root resorption; the magnitude of the latter depends on chronological age, dental age, and the tooth involved. Molars subjected to the orthodontic forces are often extracted with the aims to obtaining space in the dental arch.

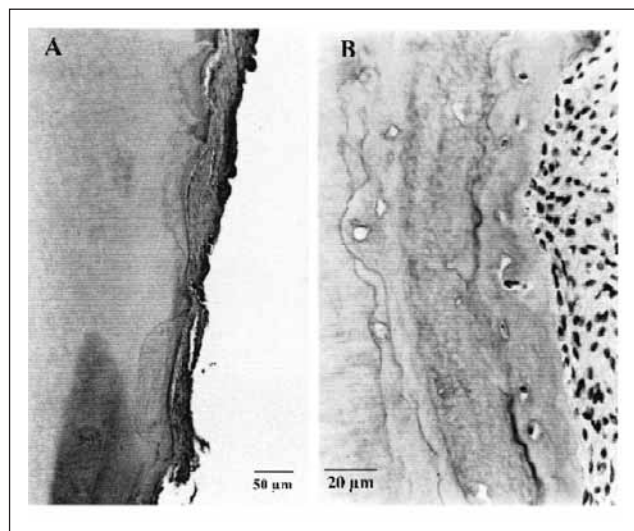
In view of the above, the aim of this work was to study the histological features and location of root resorption in deciduous molars subjected to orthodontic forces, and establishes comparison with untreated molars.

### MATERIALS AND METHODS

The study was performed on nineteen deciduous (first and second) molars of children aged 7 to 11 years treated with light orthodontic forces, and five deciduous (first and second) molars of children aged 7 to 10 years, who had not received orthodontic treatment.

All tooth extractions were performed for therapeutic purposes. Surgeries were planned and parents gave informed consent. The teeth were fixed in formalin, decalcified in 15% EDTA and embedded in paraffin. Mesio-distally oriented sections were obtained and stained with hematoxylin-eosin.

Histological studies were performed on the inter-



**Figure 2.** (A) Microphotograph of a deciduous tooth subjected to light orthodontic forces, evidencing deep areas of repaired resorption. (B) Reversal lines are visible at higher magnification.

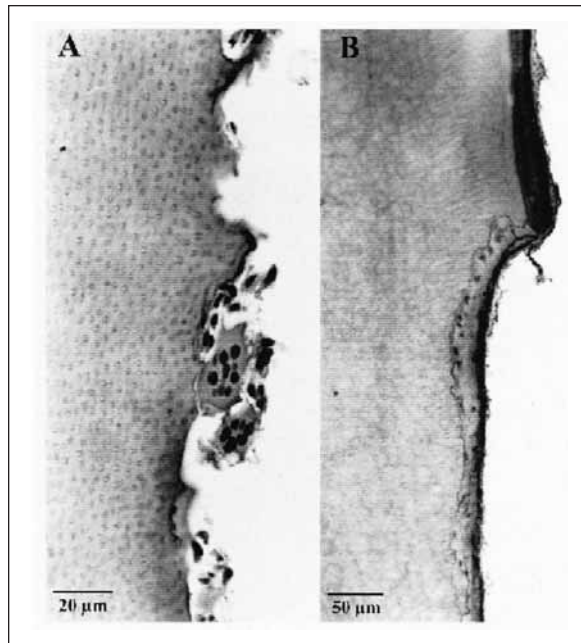
radicular tooth surface of all treated and control molars. The following histomorphometric parameters were determined according to accepted stereological principles:<sup>12-14</sup>

Percentage of root surface presenting resorption, differentiating repaired from non-repaired resorption. Root surface was defined as the distance between the most apical point covered with cementum on the mesial aspect of the root facing the septum and the most apical point covered with cement on the distal aspect (Figure 1A).

- Surface presenting repaired and non-repaired resorption, measured in mm. Comparison was established between treated molars and untreated age-matched controls (8 and 10 years of age).
- Width of repaired area, measured on segment CD between the deepest point of the innermost reversal line and the root surface (Figure 1B).
- Volume of resorted and repair tissue, considering the innermost rest line as the inner limit and the repair tissue surface as the outer limit. Treated and untreated age-matched control specimens (8 and 10 years of age) were compared (Figure 1C).
- Volume of repair tissue to extent of repaired root surface ratio (V/S).

### RESULTS

The histological studies showed that both orthodontically treated and control molars presented resorption areas on the inner surface of the root. In the control molars, the resorption areas were mainly located in the apical third of the root, whereas treated samples not



**Figure 3.** (A) Microphotograph of a control deciduous tooth evidencing shallow repaired resorption. (B) Microphotograph of a control deciduous tooth showing non-repaired resorption with odontoclasts on the surface.

only presented areas of resorption in the apical third but also in the middle and cervical thirds.

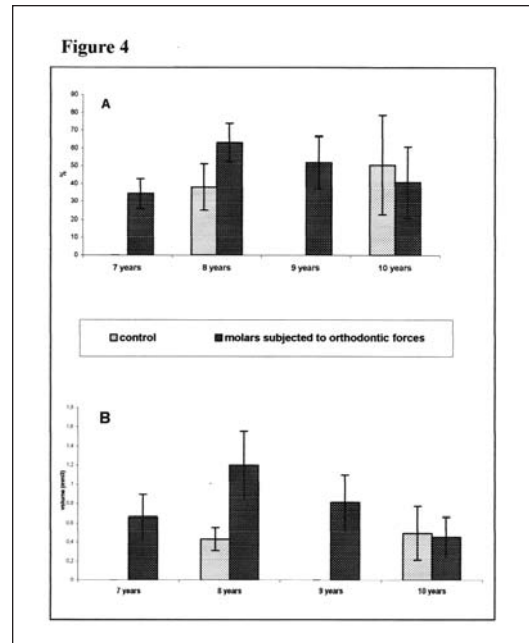
Resorption areas in treated molars were found to be eroded, with and without odontoclasts on the surface, either totally or partly repaired presenting a large number of rest lines and containing cells in some cases (Figures 2 A and B). Resorption areas located at the apical third of the root in control molars were shallow and presented odontoclasts on the surface (Figure 3A). Some areas had healed and presented few rest lines (Figure 3B)

Control molars exhibited non-repaired resorption on 46.9% of the surface and repaired resorption on 45.6%; the corresponding percentages for treated molars were 35.5% and 50.5% respectively.

Analysis of specimens corresponding to 8-year-old subjects showed repaired resorption on 63.2% of total surface of treated molars and on only 38.15% of control molars. Conversely, molars extracted from 10-year-old patients presented repaired resorption on 40.85% of root surface of treated molars and on 50.6% of controls (Figure 4A).

Total surface presenting repaired resorption was 7.8mm<sup>2</sup> in the case of treated molars extracted from 8 year olds and 5.35mm<sup>2</sup> in age-matched controls. Repair tissue volume was 1.20 mm<sup>3</sup> ± 0.35 mm<sup>3</sup> in treated molars and 0.43mm<sup>3</sup> ± 0.12mm<sup>3</sup> in controls.

As regards molars extracted from 10-year-olds, total surface presenting repaired resorption was 4.5mm<sup>2</sup> in molars subjected to orthodontic forces, and 5.9mm<sup>2</sup> in control molars. Volume of repair tissue in this same age group was 0.45mm<sup>3</sup> ± 0.21mm<sup>3</sup> in treated molars and



**Figure 4.** (A) This graph shows the percentage of root surface evidencing signs of repaired resorption in the different age groups, as compared to control molars of 8 and 10 year old patients. (B) This graph shows the volume of repair root tissue after root resorption in the internal aspects of the molar root of children treated with light orthodontic forces.

0.49mm<sup>3</sup> ± 0.28mm<sup>3</sup> in controls.

Repair tissue volume was greater in deciduous molars subjected to light orthodontic forces than in controls, and was also higher in molars extracted from 8 year-olds than in those corresponding to 10 year-old patients (Figure 4B).

The volume/surface ratio was higher in treated than in untreated molars in both age groups: 0.15 versus 0.08 in molars extracted from 8-year-olds and 0.11 versus 0.07 in those corresponding to 10 year-olds.

Depth of repaired resorption areas was greater in treated than in untreated molars, ranging between 0.02mm and 0.88mm and between 0.01mm and 0.21mm respectively.

## DISCUSSION

Our results show that repaired root resorption is a frequent finding in deciduous teeth subjected to light orthodontic forces, and the most outstanding feature is the marked depth it reaches. Because the location of these sites differs from that typically associated with physiological resorption prior to shedding, the occurrence of these resorption areas may be attributed to the orthodontic forces.

Although there are a great number of investigations on root alterations found in teeth subjected to orthodontic treatment, these investigations were done on permanent teeth. As regards deciduous teeth, a number of authors have studied resorption associated with shedding. As early as 1932, Kronfeld<sup>10</sup> and later Henry

and Weinmann<sup>15</sup> described root resorption and demonstrated the capacity of the body to compensate for resorption by means of bone or cementum deposition. Later studies described the features of these resorption areas differentiating between deep and linear resorption areas; the former penetrate deeply into the hard structures and contain several odontoclasts, and the latter are devoid of grooves and present odontoclasts aligned in a single row.<sup>3</sup> The surface of resorption areas as well as the tissue contained within were described, and the process of root resorption in deciduous teeth was classified into three phases: 1) active root resorption, 2) the resting phase and 3) root repair by cellular cementum formation.<sup>4</sup> Odontoclasts, the cells responsible for resorption, were described by a number of authors including Sasaki *et al.*,<sup>16</sup> Matsuda,<sup>17</sup> Gotz *et al.*,<sup>18</sup> and Sahara *et al.*<sup>19</sup> Later studies found that repair tissue was different from cementum and bone, and was termed bone-like or cement-like tissue.<sup>5,20</sup>

Our results showed resorption areas on deciduous teeth subjected to orthodontic forces to be deeper than those observed on control molars and than those described in the literature. Resorption in the experimental group was found compensated for by apposition of bone-like tissue. The experimental group also exhibited a larger number of rest lines in the repair tissue, indicating the occurrence of resorption, deposition, and rest phases. This finding, added to the marked depth, shows that resorption took place over a considerable length of time. It can be thought that the orthodontic forces caused a substantial initial loss of dental tissue followed by apposition of repair tissue, which in turn underwent a succession of resorption and deposition phases. The variation among patients observed in this study can be attributed to differences in frequency of use of the appliance, musculature and habits.

The location of these resorption areas must also be taken into consideration, since in addition to apical resorption typically associated with shedding, the treated molars exhibited resorption in the middle and cervical third of the root.

Interestingly, orthodontically treated molars extracted from 8-year-old patients presented a marked increase in repair tissue as compared to age-matched controls.

Our results have clinical implications, since radiographic follow-up of these patients is uncommon, and in view of the characteristics and depth of resorption, root fracture is a potential risk. Extraction of fractured root remnants can cause damage to the successional premolars, and avoiding extraction can result in the remnants becoming encapsulated by cement. We therefore recommend radiographic follow-up to monitor orthodontic treatment of deciduous teeth closely and allow for timely adjustments in the treatment plan in order to minimize future fracture risk.

## ACKNOWLEDGMENTS

This paper was supported in part by Grant UBACyT O 013 of the University of Buenos Aires. The technical assistance of Mrs. Ana María Gómez is acknowledged.

## REFERENCES

1. Kitamura H. Shedding of teeth. *Oral Embryology and Pathohistology*. Tokyo, Ishiyoku Euro America Inc. pp 47-52, 1988.
2. Wo YM, Richards DW, Rowe DJ. Production of matrix-degrading enzymes and inhibition of osteoclast-like cell differentiation by fibroblast-like cells from the periodontal ligament of human primary teeth. *J Dent Res* 78: 681-689, 1999.
3. Zeroli C. Linear resorption process of the roots of deciduous teeth. *Arch Ital Biol Orale* 2: 33-45, 1961.
4. Sasaki T, Watanabe C, Shimizu T, Debar K, Segawa K. Possible role of cementoblasts in the resorbant organ of human deciduous teeth during root resorption. *J Periodontal Res* 25: 143-151, 1990.
5. Sahara N, Okafuji N, Toyoki A, Ashizawa Y, Yagasaki H, Deguchi T *et al.* A histological study of the exfoliation of human deciduous teeth. *J Dent Res* 72: 634-640, 1993.
6. Furseth R. The resorption processes of human deciduous teeth studied by light microscopy, microradiography and electron microscopy. *Arch Oral Biol* 13: 417-431, 1968.
7. Cameron A. *Handbook of pediatric dentistry*. 2nd ed. Edinburgh, New York, Mosby, 2003.
8. Tronstad L. Root resorption- etiology, terminology and clinical manifestations. *Endod Dent Traumatol* 4: 241-252, 1988.
9. Hesse G. Ueber persistierende Milchzähne bei unterzähligen Gebissen, zugleich Beitrag zur Frage die Pulpa Zement bilbet. *Dt Mschr Zahnheilk* 16: 161-174, 1931.
10. Kronfeld R. The resorption of the roots of deciduous teeth. *Dental Cosmos* 74: 103-120, 1932.
11. Hardt E. Die resorption der milchzahnwurzeln unter physiologischen und pathologischen bedingugen. *Dt Zahn-Mund-u Kieferheilk* 2: 12-36, 1948.
12. Weibel ER, Elias H. Introduction to stereology and morphology. In: *Quantitative methods in morphology*. Berlin: Springer - Verlag, pp 3-19, 1967.
13. Ubios AM, Guglielmotti MB, Steimetz T, Cabrini RL. Uranium inhibits bone formation in physiologic alveolar bone modeling and remodeling. *Environ Res* 54: 17-23, 1991.
14. Mandalunis PM, Gibaja F, Ubios AM. Experimental renal failure and iron overload: A histomorphometric study in the alveolar bone of rats. *Exp Toxicol Pathol* 54: 85-90, 2002.
15. Henry JL, Weinmann M D. The pattern of resorption and repair of human cementum, *J A D A* 42: 270-290, 1951.
16. Sasaki T, Motegi N, Susuki H, Watanabe C, Tadokoro K, Yanagisawa T, Higashi S. Dentin resorption mediated by odontoclasts in physiological root resorption of human deciduous teeth. *Am J Anat* 183: 303-15, 1988.
17. Matsuda E. Ultrastructural and cytochemical study of the odontoclasts in physiologic root resorption of human deciduous teeth. *J Electron Microsc* 41: 131-40, 1992.
18. Gotz W, Quondamatte F, Ragotzki S, Affeldt J, Jager A. Localization of cathepsin D in human Odontoclast. A light and electron microscopical immunocytochemical study. *Connect Tissue Res* 41:185- 94, 2000.
19. Sahara N. Cellular events at the onset of physiological root resorption in rabbit deciduous teeth. *Anat Rec* 264: 387- 96, 2001.
20. Sahara N, Okafuji N, Toyoki A, Suzuki I, Deguchi T, Suzuki K. Odontoclastic resorption at the pulpal surface of coronal dentin prior to shedding of human deciduous teeth. *Arch Histol Cytol* 55: 273-85, 1992.