

Lower mesiodens: report of an unusual case

Marilia Alencar* / Danilo Duarte** / Patricia Cury*** / Marcelo Bönecker****

This report describes a case of an 11 years old girl presenting a supernumerary tooth between lower central incisors. The case initially required only surgical treatment to remove the lower mesiodens. Sequentially, the patient was referred to an orthodontic therapy due to a presence of diastema.
J Clin Pediatr Dent 29(4): 353-356, 2005

INTRODUCTION

A very few cases of supernumerary teeth in the anterior region of the mandible have been reported.¹⁻⁴ According to dental literature, only 2% of supernumerary teeth occur in the anterior mandible region.⁵ In fact, the upper mesiodens is the clinically most frequent supernumerary tooth.

Mesiodens term is used to refer to an unerupted supernumerary tooth in the central region of maxilla or mandible between the two central incisors.⁶ Supernumerary teeth are often found bilaterally although might occur singly, multiply or unilaterally, and in one or both jaws.⁷

Mesiodens teeth might be erupted or not and the direction of their long axis is either normal (downward) or inverted (upward) and in few cases it is horizontal.⁸ Generally, these teeth are small and have the form of a cone-shaped crown with a short root⁹ and they are usually normal in appearance, particularly in the area of the mandible incisors.¹⁰

The etiology of supernumerary teeth remains unclear, however, several theories have been suggested for their occurrence. Heredity^{6,7,11,12} and phylogenetic process of atavism¹¹⁻¹³ have been suggested to explain the development of supernumerary teeth. The localized

and independent hyperactivity of the dental lamina^{6,7,10,12,13} and dichotomy of the tooth bud^{6,7,11-13} are also suggested as a possible etiological factors.

Most supernumerary teeth are asymptomatic and commonly discovered during routine radiographic examination.^{11,14} The mesiodens that remain unerupted might cause premature resorption of primary incisors and some other complications such as delay or prevention of eruption and displacement or rotations of permanent teeth. Less frequent complications include crowding, diastema, dilacerations of permanent teeth and cyst formation.^{6,7,11,13,14} Radiological findings, although very rare might include cyst formation or progressive external resorption of the crown.^{11,13}

Surgical removal of mesiodens is considered, if the developing complications are suspected, or the tooth would serve little function, or the tooth is associated with certain pathological conditions.⁸ When to treat mesiodens is highly controversial. An early intervention might prevent clinical complications, however, must be based on a proper behavior management.¹¹ At the same time, an early approach also poses the risk of damaging adjacent developing tooth germs or roots. Whether an early or delayed approach is used, early diagnosis is most important, and will lead to a more comprehensive long-term treatment plan.¹³

The purpose of this paper is to report a rare case of the presence of a lower mesiodens that was referred to the Paediatric Dentistry Clinic for assessment and treatment.

CASE REPORT

An 11 years old girl presented with a chief complaint of a diastema between lower central incisors and a "piece of tooth" in the region. Medical and dental histories were non-contributory; there was no previous trauma to the teeth or jaws. Clinical examination showed a healthy girl with no other physical abnormalities. Intra oral examination revealed a partially erupted tooth slightly palpable on the labial surface between the

* Marilia Alencar, Department of Pediatric Dentistry, UNICSUL, São Paulo, Brazil.

** Danilo Duarte, Department of Pediatric Dentistry, UNICSUL, São Paulo, Brazil.

*** Patricia Cury, Department of Oral Pathology and Oral Microbiology, Centro de Pesquisas Odontológicas São Leopoldo Mandic, São Paulo, Brazil.

**** Marcelo Bönecker, Department of Pediatric Dentistry, University of São Paulo, USP, São Paulo, Brazil.

Send all correspondence to Dr. Marcelo Bönecker, Av. Prof Lineu Prestes 2227 - Cidade Universitária, 05508-900 São Paulo - Brazil

Voice/Fax: 55 11 30917854

E-mail address: bonecker@usp.br

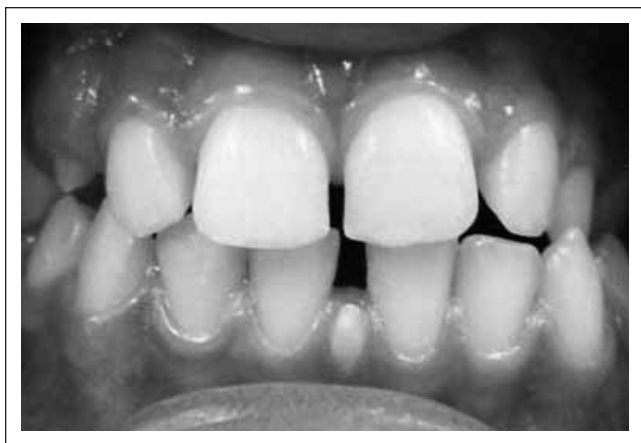

Figure 1. Conical single mesiodens partially erupted.

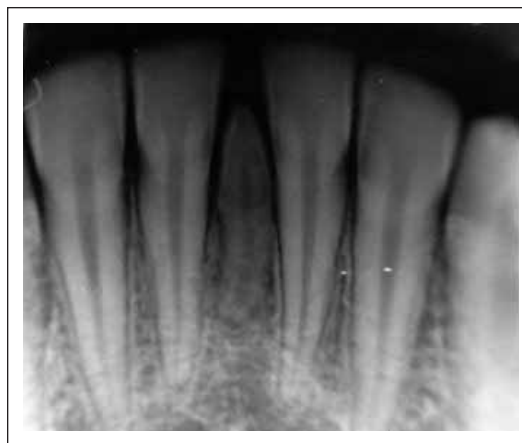

Figure 2. Periapical radiography showing a rotated mesiodens with an apex dilaceration.

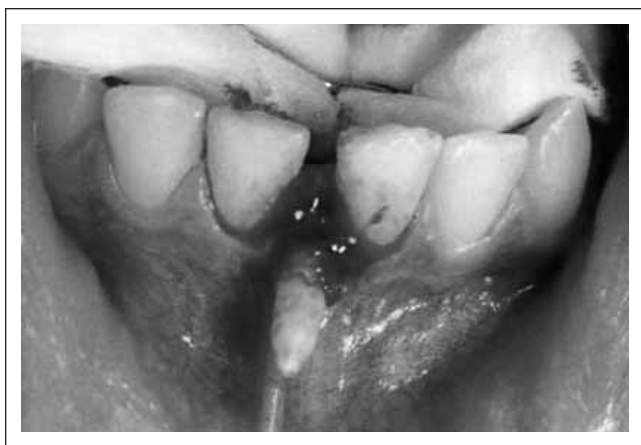

Figure 3. Surgical procedure using a manual instrument.




Figure 4. Mesiodens was 12cm length and had a short cone-shaped crown and root with an evident dilaceration at apex.

lower permanent central incisors and also the presence of an abnormal diastema in the region. Permanent teeth were not delayed in its eruption nor even displaced. (Figure 1).

Initially, a periapical radiograph was essential to solve the diagnostic query. An unerupted mesiodens was observed between the lower central permanent incisors. The radiographic examination was essential to assess the number and location or displacement of the mesiodens; to define that there was no discernable effect upon adjacent teeth and bone structures and also to confirm that root development of both lower incisor teeth was completed. The radiography showed that the mesiodens seemed to be a central incisor in small proportion that had rotated about 90° along the long axis having a dilaceration on the apex. (Figure 2)

Although the use of the panoramic radiograph is limited because of the distortion and thin focal through in the anterior dental midline region, in this case it was helpful to assess the absence of other supernumerary teeth in other regions.

Considering the clinical and radiographic findings and based on patients agreement it was decided to

remove the mesiodens. The surgical procedure was painless and straightforward using a manual instrument as the buccal alveolar bone was not thick. (Figure 3).

The extracted mesiodens was 12cm length and had a short cone-shaped root with an evident dilaceration at apex and a crown with characteristics of incisor and canine teeth (Figure 4). The treatment goals were achieved without complication and the patient returned twice for radiographic follow-up. After that she was referred to orthodontic treatment.

Decalcification of the removed mesiodens was done using an aqueous solution of ethylenediaminetetraacetic acid (EDTA) under microwave irradiation for 35h in the same oven.¹⁵ Hematoxylin-eosin staining sections were obtained and analyzed by light microscope. Histologically the pulp of the mesiodens showed a normal and typical loose connective tissue, with a variable number of fibroblasts-like cells, odontoblasts and undifferentiated mesenchymal cells all arranged among collagen fibers, blood vessels and nervous fibers. Odontoblasts forming a single layer lining the periphery of the pulp might be observed. (Figure 5).

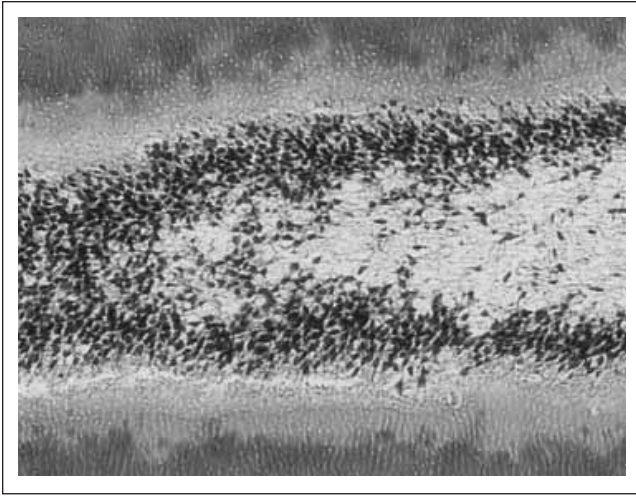


Figure 5. Histological aspect of the mesiodens. P (pulp), O (odontoblasts), PD(predentin), D (dentin).

DISCUSSION

It is widely recognized that the most supernumerary teeth are located in the anterior region of the maxilla,^{5,7,11,13} and many authors have reported the prevalence constantly favoring males (ranging from 1.3:1 to 6.5:1).^{6,11,12,16} Contradicting these well established statements, in the present case report the mesiodens was located in the incisor region of the mandible and the patient was a girl.

The extracted tooth could be classified as conical, single mesiodens in relation to morphology, number and location regarding proposed classification for supernumerary teeth.^{7,11,12} This mesiodens was smaller than the adjacent central incisors and was rotated 90° around along its long axis besides being impacted.

As inferred above, mesiodens might cause some clinical complications. Fortunately, in the case report described, the presence of mesiodens caused only a diastema, which did not produce any other aesthetic problem as crowding or displacement.

Since mesiodens may interfere with normal occlusal development, in the present case an early diagnosis could have prevented the lower diastema formation. Early diagnosis and treatment of patients with supernumerary teeth are important to prevent or minimize complications.¹³

A surgical removal after diagnosis of a mesiodens is indicated.^{7,13,17} It is in the best interest of the patient to have the tooth removed immediately on discovery unless the surgery would be unjustifiably hazardous to adjacent structures. In the present case there was a very low risk of iatrogenic damage to adjacent permanent incisors root according to clinical and radiographic findings since the root development of the central incisors was complete. Furthermore, an immediate surgical removal was indicated after diagnosis because intra- or post-operative complications were less likely

to occur once the patient was very young. Surgical procedure was simple and patient was cooperative.

Extraction is not always the treatment of choice for supernumerary teeth. Unerupted supernumerary teeth that are symptom less, do not appear to be affecting the dentition in any way and are found by chance are sometimes best left in place and kept under observation.¹¹

Mesiodens are familiar to pediatric dentists and orthodontists as one of the more common anomalies to affect the developing dentition and it demands a multidisciplinary assessment¹⁷ because of the complexity of many clinical aspects that may be encountered. In this case, after the extraction, the patient was referred to an orthodontic treatment because of the presence of diastema.

REFERENCES

- Mintz SM. Rare mandibular supernumerary tooth. *Oral Surg Oral Med Oral Pathology* 27: 359, 1969.
- Furman RL, Williams JJ. A supernumerary mandibular lateral incisor. *Oral Surg Oral Med Oral Pathology* 29: 395, 1970.
- Tanaka S, Murakami Y, Fukami Nakano M, Fujisawa S, Miyoshi S. A rare case of bilateral supernumerary teeth in the mandibular incisors. *Br Dent J* 185: 386-388, 1998.
- Fukuta Y, Totsuka M, Takeda Y, Yamamoto H. Supernumerary teeth with eumorphism in the lower incisor region: a report of five cases and review of the literature. *J Oral Sci* 41: 199-202, 1999.
- Stafne EC. Supernumerary teeth. *Dent Cosmos* 74: 653-659, 1932.
- Gallas MM, Garcia A. Retention of permanent incisors by mesiodens: a familiary affair. *Br Dent J* 188: 63-64, 2000.
- Scheiner MA, Sampson WJ. Supernumerary teeth: A review of literature and four case reports. *Aust Dent J* 42: 160-165, 1997.
- Koch H, Schwartz O, Klausen B. Indications of surgical removal of supernumerary teeth in the premaxilla. *Int J Oral Maxillo Surg* 15: 273-81, 1986.
- Buenviaje TM, Rapp R. Dental anomalies in children: a clinical and radiographic survey. *J Dent Child* 51: 42-6, 1984.
- Ripamonti U, Petit J, Thackeray JF. A supernumerary tooth in a 1.7 million-year-old *Australopithecus robustus* from Swartkrans, South Africa. *Eur J Oral Sci* 107: 317-321, 1999.
- Rajab LD, Hamdan MAM. Supernumerary teeth: review of the literature and a survey on 152 cases. *Int J Paed Dent* 12: 244-254, 2002.
- Stellzig A, Basdra EK, Komposch G. Mesiodentes: incidence, morphology, etiology. *J Orofac Orthopaedic* 58: 144-153, 1997.
- Huang W, Tsai TT, Su H. Mesiodens in the primary dentition stage: A radiographic study. *J Dent Child* 59: 186-189, 1992.
- Hattab FN, Yassin OM, Rawashdeh MA. Supernumerary teeth: report of three cases and review of the literature. *J Dent Child* 61: 382-394, 1994.
- Bonafe-Oliveira L; Faltin RM; Arana-Chavez VE. Ultrastructural and histochemical examination of alveolar bone at the pressure areas of rat molars submitted to continuous orthodontic force. *Eur J Oral Sci* 111: 410-416, 2003.
- Bodin I, Julin P, Thomsson M. Frequency and distribution of supernumerary teeth among 21,609 patients. *Dentomaxillofacial Radiol* 7: 15-17, 1978.
- Giancotti A, Grazzini F, De Dominicis F, Romanini G, Arcuri C. Multidisciplinary evaluation and clinical management of mesiodens. *J Clin Ped Dent* 26: 233-237, 2002.