

Spontaneous eruption of an occult incisor fragment from the lip after eight months: Report of a case

Dinesh Rao B.* / Sapna Hegde**

Large majorities of dental traumas are associated with soft-tissue injury and tooth fragments. They are often found embedded in the oral soft tissues, most commonly the lip. Early detection and complete removal of such fragments is critical in order to prevent infection and scarring. Adequate communication between medical and dental professionals involved is of considerable value in the management of such cases. This report presents a case of spontaneous extrusion of an occult incisor fragment from the lower lip, eight months after trauma.

J Clin Pediatr Dent 30(3): 195–198, 2006

INTRODUCTION

Oro-dental injury in children is a cause of much pain and distress, which will present a challenge for the dental professional that is often unparalleled.¹ There is perhaps no single dental disturbance that has greater psychological impact on both the parents and the child than the fracture or loss of an anterior tooth of a child, especially if the injury involves extensive loss of tooth structure. Oro-dental injury is an emergency. Prompt assessment and appropriate treatment are needed to ensure the best outcome.²

The more or less complete labial cover that shields the dentition is the reason for the large number of dental traumas being associated with injuries to the lip, gingiva, and oral mucosa. Andreasen and Andreasen found that more than half of all patients treated in a hospital emergency setting showed associated soft tissue injury.³

It has been commonly observed that an impact force towards the incisors leads to the fracture and causes laceration of the soft tissues, especially the lips and may lead to embedding of tooth fragments in the lip.⁴ Tooth

fragments in the tongue have also been reported, but are less common.⁵⁻⁷

The coincidence of both soft tissue trauma and the fracture or avulsion of teeth must lead the clinician to suspect that tooth fragments may be embedded in the soft tissues. Such fragments, if undetected at the time of emergency treatment, can lead to infection and disfiguring fibrosis in addition to causing medico-legal complications.⁴ Hence, it is imperative that every attempt be made to locate missing tooth structures before a wound is closed. This can be done through a detailed history of the accident, careful examination and roentgenograms, if necessary.⁸

What follows is a report of a case of spontaneous extrusion, after eight months, of a tooth fragment embedded in the lip following trauma to the maxillary central incisor.

CASE REPORT

A female patient aged fourteen years, visited the Department of Pediatric Dentistry at the Pacific Dental College and Hospital, Udaipur, India, with a complaint of lower lip swelling associated with intermittent purulent discharge.

Clinically, the oral mucosa appeared normal, except for a slight swelling in the lower lip, almost in the midline, through which a hard white mass was seen projecting out. The area around the object was slightly tender and hard on palpation. In addition, the labial mucosa showed the presence of a mucocele. Also, it was observed that the maxillary left central incisor had been restored with a jacket crown (Figure 1). These findings lead the examiner to suspect that the foreign body embedded in the lip may perhaps be a tooth fragment.

The patient, on being questioned about any previous

* Dr. Dinesh Rao B., Reader, Department of Pediatric Dentistry, Pacific Dental College & Hospital

** Dr. Sapna Hegde, Associate Professor, Department of Pediatric Dentistry, Pacific Dental College & Hospital,

All correspondence should be sent to: Dr. Dinesh Rao B., Department of Pediatric Dentistry, Pacific Dental College & Hospital, Debari, Udaipur 313024, Rajasthan, India.

Tel: +91 94141 58235, +91 294 2493109

Fax: +91 294 2491508

E-mail: dineshrao@rediffmail.com

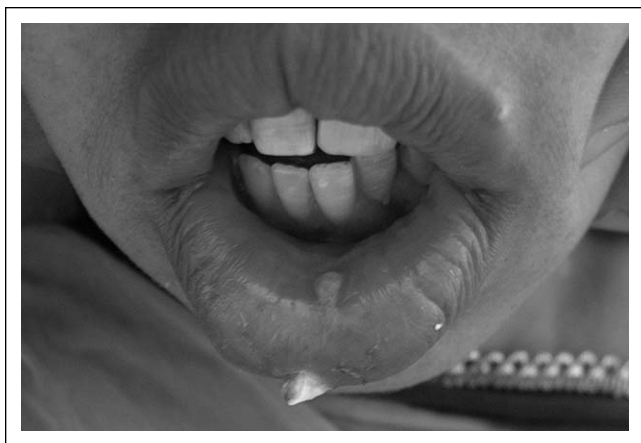

Figure 1. Lower lip showing presence of extruding foreign body and mucocele




Figure 2. Soft-tissue roentgenogram showing presence of radio-opaque fragment




Figure 3. Tooth fragment retrieved from lower lip

history of traumatic injury to the dentition, revealed that about eight months ago, she had sustained an injury to the maxillary left central incisor. The patient was struck, accidentally, on the chin by the handle of the pump, while pumping water from a tube well. The force of the blow lacerated the chin of the patient, cut her lower lip and fractured the maxillary incisor.

No attempt was made to locate the fractured tooth fragment at the site of the accident. The patient was taken to a general hospital, where the lip laceration was sutured and tetanus toxoid administered. The fractured tooth was later treated endodontically and a jacket crown placed by a dental practitioner.

A soft tissue roentgenogram, made by placing a peri-apical film in the labial sulcus just opposite to the white mass, revealed the presence of a radio-opaque fragment near the wound site (Figure 2).

The wound site and the surrounding tissue were cleansed with a wound detergent followed by saline. Under regional block anesthesia, small horizontal incisions were made on both ends of the extruded fragment, which was then carefully removed using a spoon excavator (Figure 3). The mucocele was also surgically

excised in the same sitting. The wounds were irrigated thoroughly with saline and sutures placed.

Examination of the foreign body confirmed that it was indeed a tooth fragment that had been embedded and undetected in the lip for almost eight months. Recovery was uneventful and the suture was removed on the fourth postoperative day. A postoperative radiograph failed to show evidence of any fragments remaining in the lip.

DISCUSSION

Broken, lost, swallowed or aspirated teeth can be a hazard in dental and medical practice.⁸ The coincidence of both soft tissue trauma and fracture of teeth must be carefully pursued in the process of taking the history and performing the initial examination. Because of the magnitude of soft tissue trauma associated with minor tooth fracture, the physician may often be the first to see the child. Adequate communication between medical and dental practitioners involved is of considerable value.⁸

Diagnosis consists of determining the extent of the wound and verifying the presence of foreign bodies. In that regard, a radiographic examination will be able to demonstrate a variety of typical foreign bodies such as tooth fragments, calculus, gravel, glass, metallic or non-metallic restoration and fragments of paint.^{4,8,9} However, other typical foreign bodies such as cloth and wood cannot be seen.⁸ Rowe and Killey,¹⁰ Allen¹¹ and Camilleri¹² have stressed the value of roentgenograms to exclude the presence of tooth fragments in the lips following dental or maxillofacial injuries.

The presence of foreign bodies in the wound significantly increases the risk of infection and retards healing, even in wounds initially free of infection. This finding emphasizes the importance of adequate cleansing of the wound prior to suturing. Complete removal of all foreign bodies is important, to prevent infection and to prevent disfiguring scarring and tattooing.⁵

In the present case, the undetected tooth fragment

caused the patient undue discomfort and anxiety because neither patient nor parents attempted to locate the tooth fragment at the site of injury. The medical and dental practitioners who first treated the patient also overlooked the possibility of embedding of tooth fragments in the soft tissues following trauma.

As in Allen's four cases⁸ and a case reported by Camilleri,⁹ the patient just described had a full thickness laceration of the lip. According to Camilleri, there seems to be a greater risk of tooth fragments being embedded in the lips when the wound is large.¹² If the patient does not locate the dental structures lost in an accident and in association with soft tissue trauma, some set of standard procedures may be warranted. It is incumbent upon the dental professional to preserve the vitality of injured teeth whenever possible and to restore them skillfully to their original appearance, without producing additional trauma or endangering the integrity of the teeth.

Every dental professional, who treats children, must be well prepared to meet these emergencies. In the case of dental traumas associated with soft tissue injuries, the following guidelines can be used for more favorable results:

- a) Clean the wound and surrounding areas with a wound detergent.
- b) Assess the nature, extent and contamination of the soft tissue lesion and find out the fate of the missing dental structures, if any.
- c) Obtain a short medical history to reveal possible allergies, blood dyscrasias, tetanus prophylaxis and other information, which would influence treatment.
- d) In the case of suspected foreign bodies in the lip, a radiograph of the lip is indicated, using a fraction π of the normal exposure time and low kilo voltage. If

- e) suspected, consider obtaining a chest radiograph, if tooth fragments cannot be accounted for, elsewhere.
- e) Use regional block anesthesia, since infiltration anesthesia may increase the risk of infection.
- f) Elevate wound edges, retrieve and remove foreign bodies.
- g) Carefully rinse the wound with saline and close the wound with fine sutures.
- h) Remove sutures following healing and obtain post-operative radiograph to rule out any remnants.

REFERENCES

1. Roberts G, Longhurst P. The problem, classification, epidemiology and aetiology. In: Oral and dental trauma in children and adolescents. 1st ed. New York: Oxford Medical Pub. Co, pp 3–9, 1996.
2. Ripa LW, Finn SB. The care of injuries to the anterior teeth of children. In: Clinical Pedodontics. 4th ed. Philadelphia: WB Saunders, pp 224–269, 2000.
3. Andreasen JO, Andreasen FM. Pattern of injury and diagnosis. In: Essentials of traumatic injuries of the teeth. 2nd ed. Copenhagen: Munksgaard, pp 143–154, 2000.
4. Wadkar MA, Dhusia HK, Narkhede PR. Foreign body in the lip: a case report. *J Indian Dent Assoc* 58: 147–148, 1986.
5. McDonnell DG, McKiernan EX. Broken tooth fragments embedded in the tongue: A case report. *British J of Oral Maxillofacial Surg* 24: 464–466, 1986.
6. Jacowski et Colas. Incarcération dentaire d'origine traumatique dans la langue et sous la muqueuse vestibulaire. *Revue de Stomatologie* 53: 909, 1952.
7. Snawder KD, O, Toole TJ, Bastawi AE. Broken tooth fragments embedded in soft tissue. *J Dent Child* 46: 145, 1979.
8. Snawder KD, Bastawi AE, O, Toole TJ. Tooth fragments lodged in unexpected areas. *JAMA* 236: 1378–1379, 1976.
9. Goodman JR. Fractured composite restoration embedded in the lip. *Br Dent J* 156: 293–294, 1984.
10. Rowe NL, Killey HC. Fractures of the facial skeleton. 1st ed. Edinburgh: Livingstone Ltd. 1955.
11. Allen FJ. Incisor fragments in the lip. *D. Practitioner & D. Record* 11: 390, 1961.
12. Camilleri GE. Incisor fragment in the lip- report of a case. *Oral Surg Oral Med Oral Path* 16: 1294–1296, 1963.

