

## Bleaching non vital primary teeth: case report

Sandra Kalil Bussadori\* /Fayna Roth\*\* /Carolina Cardoso Guedes\*\*\*

Kristiane Porta Fernandes\*\*\*\* /Manoela Martins Domingues\*\*\*\*\*

Márcia Turolla Wanderley\*\*\*\*\*

*Trauma and pulpal infections in primary dentition are part of the routine of the pediatric dentist. Common consequences in these cases are alterations in dental color, compromising patient's esthetics and his interaction in social environment. Bleaching intends to preserve dental structure already weakened and to show immediate esthetic results. This clinical case shows a bleaching technique in devitalized primary teeth using bleaching agent with 35% hydrogen peroxide activated by photo polymerizer. This technique is simple and shows immediate satisfactory results.*

J Clin Pediatr Dent 30(3): 179-182, 2006

### INTRODUCTION

Nowadays dental bleaching is the most conservative esthetic method of reestablishing and/or homogenizing dental color.<sup>14</sup> Other esthetic procedures such as the confection of facings or total crowns depend on the abrasion of healthy dental structures, besides having elevated cost due to the need of clinical and prosthetic steps.<sup>4,7,11</sup>

Many extrinsic factors, such as trauma to the

primary dentition, pulpal infections, iodoformed pastes used in endodontic fillings, medications used by the mother during pregnancy such as tetracycline, diseases in the newborn, hematological diseases such as congenital porphyria, can cause intrinsic discolorations, however pulpal hemorrhage from trauma is the most common cause of this type of stains.<sup>3,4,5,6,8,14</sup>

When alterations in dental color are found in the primary dentition, a differential diagnosis must be obtained between intrinsic and extrinsic pigmentations, the latter resulting mainly from food and products of oral usage, that have in their composition dyeing agents that when they pigment superficially the dental structure may be removed by means of a prophylaxis with sodium bicarbonate.<sup>3,5,14</sup> According to Consolaro,<sup>6</sup> localized blemishes covering several teeth, bilaterally, being seen in both arches simultaneously could suggest a systemic cause.

According to Bryan and Welbury's<sup>3</sup> protocol used to reverse dental color in devitalized teeth treated endodontically, is internal bleaching. They suggest to take an X-ray to confirm the proper root canal seal and the degree in physiological resorption, prior bleaching. Before beginning bleaching treatment, charting the tooth color must be done as well as a preoperative photograph of the tooth and adjacent ones is recommended.

In pediatric dentistry, the usage of absolute isolation and protective goggles both for patients and the professional is mandatory during bleaching, due to undesirable and unexpected movements that the child might make and the explicit danger from the concentration

\* Sandra Kalil Bussadori, PhD. Professor, Pedodontics Department in SOESP - (Sindicato dos Odontologistas do Estado de São Paulo) and UMC - (Universidade de Mogi das Cruzes), Professor and Chairman Dental Materials in UNIMES - (Universidade Metropolitana de Santos and UNINOVE - Centro Universitário Nove de Julho).

\*\* Fayanna Roth, DDS. Specialist in Pediatric Dentistry SOESP

\*\*\* Carolina Cardoso Guedes, DDS. Specialist in Pediatric Dentistry SOESP

\*\*\*\* Kristiane Porta Fernandes, PHD. Professor, Chairman of Endodontics Department in UNINOVE and UBC (Universidade Brás Cubas).

\*\*\*\*\* Manoela Martins Domingues, PhD. Professor, Pedodontics Department in UNINOVE

\*\*\*\*\* Márcia Turolla Wanderley, PhD. Professor, Pedodontics Department in USP (Universidade de São Paulo) and SOESP

All correspondence should be sent: Dr. Sandra Kalil Bussadori, Centro Universitário Nove de Julho, Campus Vergueiro, Rua Cotóxó, 303, conj 112/114, ZIP 05021-000, São Paulo - Brazil

Tel 55-11-3868-4130

Fax 55-11-3676-1958

e-mail skb@osite.com.br

and caustic properties of the bleaching agent. Contact of the bleaching agent with soft tissues and mucosa may cause immediate burning sensation and acquire a whitish aspect, characteristic of burns.<sup>1,9,15</sup>

Access for bleaching has to be larger than the conventional root canal access and all darkened dentin must be removed. Root canal seal at the stump may be done with conventional glass ionomer cement or resin-modified glass ionomer.<sup>3</sup> Sealing must have 2 mm thickness apically from the amelocementary junction.<sup>6,7</sup> Such care has to be taken as to prevent bleaching agent to flow to periapical and periodontal tissues, avoiding osteoclastic activity that may culminate in external root resorption due to the extremely acidic pH of the bleaching agent with concentrated hydrogen peroxide basis.<sup>3,4,12</sup>

The choice of the bleaching agent must take in consideration the availability, large quantities of free oxygen and the possibility of photoactivation, which will bear faster results.<sup>15</sup> Agent with such characteristics is hydrogen peroxide at 35%.<sup>5,9,10,11,14</sup>

Bleaching agent's chemistry is based in its ability to generate active oxygen, free radicals and solvents, particularly water. Dental bleaching is possible only due to the permeability of the dental structure to bleaching agents, capable of diffusing themselves freely into enamel and dentin. This is due to the low molecular weight (hydrogen peroxide 30g/mol). Such agents interact mainly with organic structures of highly pigmented carbon rings, through the addition of oxygen, opening and converting them in chains that are lighter in color. During treatment, bleaching material reaches saturation point, where whitening diminishes considerably because the material degrades and is converted into carbon dioxide and water (oxydation process).<sup>2,6</sup>

Cabral and Oliveira,<sup>4</sup> Nakamura<sup>10</sup> used the thermocatalytic technique where bleaching product must be manipulated according to the manufacturer's instructions and applied in the pulp cavity and vestibular face (combined bleaching technique). Photo activation of the bleaching agent may be done through various sources of luminous energy, such as halogen lamps conventional photopolimerizers, blue light emitting lamps, (LED type), ultra violet fonts, some laser emitting lights and plasma lights. Time of exposure should follow manufacturer's recommendations. The higher the power of light's font, the faster the bleaching effect will be obtained, consequently there will be less time of contact of the bleaching product with dental structure.<sup>1,6,9</sup>

The present paper shows a clinical case where an esthetic conservative technique in devitalized primary teeth was employed to modify dental color. This is a simplified procedure with immediate esthetic results, offering advantages in pediatric dentistry settings.

### CLINICAL CASE REPORT

A three-year-old patient presented at the Pediatric

Dentistry Clinic with a history of trauma from a fall to the anterior maxillary primary teeth. Clinical examination showed color changes more pronounced on tooth 51, presence of coronal fractures without pulpal involvement, vestibular hypoplastic stains, compromising teeth 51 and 61 (Figure 1). X-rays suggested the possibility of periapical abscesses involving the roots of both teeth. From data obtained and complementary exams a treatment plan was developed, performing root canals, external and internal bleaching (due to evident discoloration), microabrasion (if necessary, to remove hypoplastic spots) and finally placing esthetic restorations on teeth 51 and 61. After informed consent was signed, endodontic treatment of both teeth was performed, using Guedes-Pinto Paste as filling material.

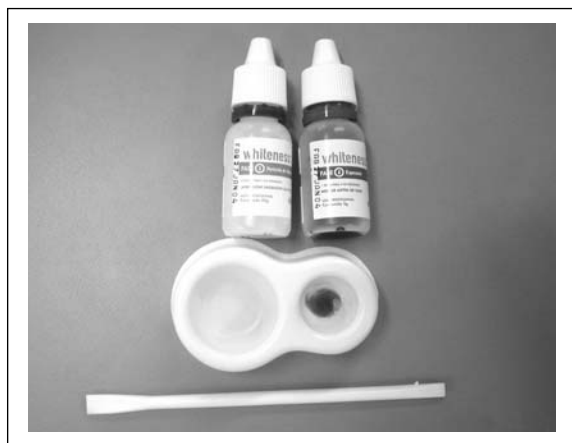
A week after endodontic treatment, both teeth received a pre-bleaching treatment consisting of prophylaxis, initial color verification using VITA shade, obtaining color A 3,5 for tooth 51 and color A2 for tooth 61. Photographic documentation was also

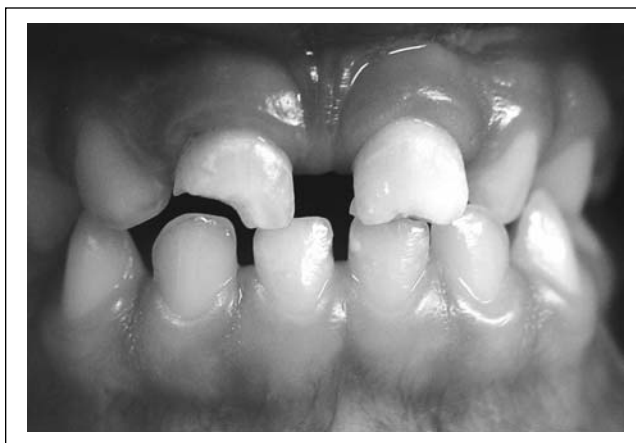

Figure 1. Initial aspect of maxillary central incisors of a three year old patient with color alterations more pronounced in tooth 51 and presence of coronal fractures without pulpar involvement and vestibular hypoplastic stains compromising teeth 51 and 61.

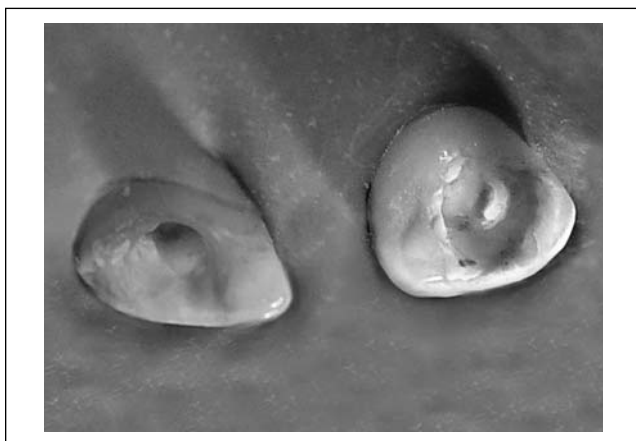

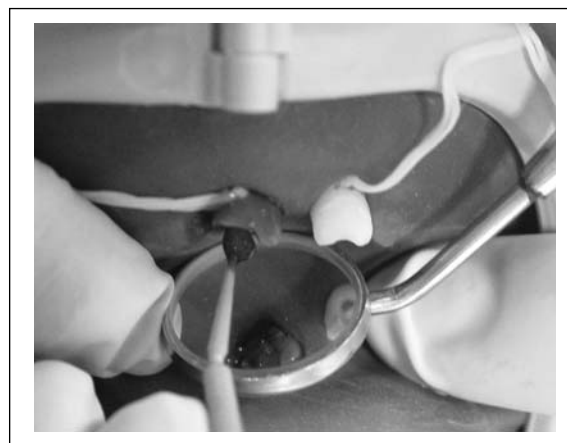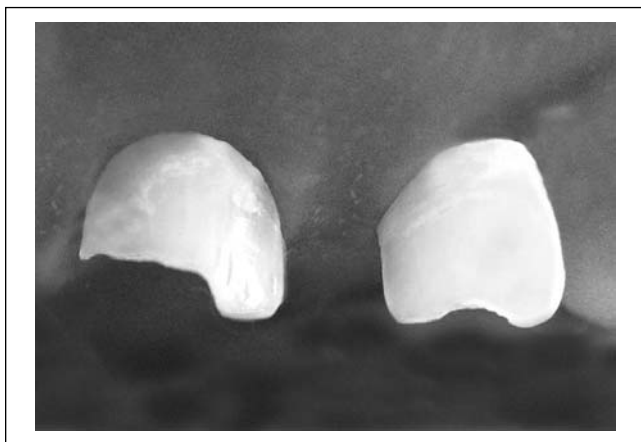
Figure 2. Under absolute isolation, note the increased coronal access.



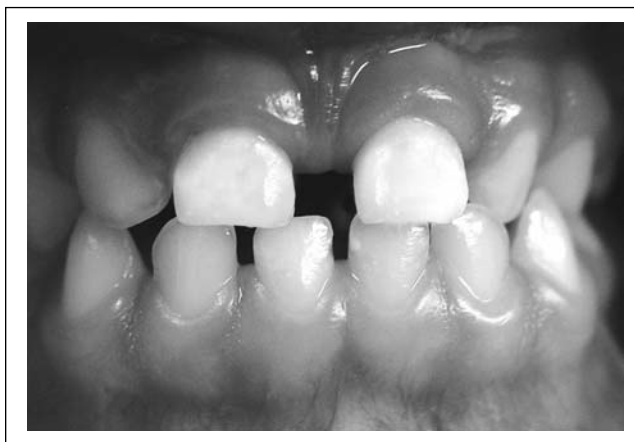**Figure 3.** Manipulation of the product - commercial name Whiteness-HP (FGM) -proportion of three drops of hydrogen peroxide to one drop of thickener (union of these two materials forms a dense paste, purple colored, that must be placed on dental surface to be bleached).



**Figure 4.** Application of the product internally and externally with aid of a microbrush; photoactivation for 40 seconds on each surface of the teeth (palatal and vestibular) waiting for complete discoloration of the material.



**Figure 5.** After microabrasion using 35% orthophosphoric acid in gel form at 35% with pumice (powder), placing the paste only on the hypoplastic stains with the aid of a spatula for resin, friction with a colorless wooden wedge and rubber cup.



**Figure 6.** Final aesthetic results.

obtained. Under absolute isolation, the root canal access was widened and a plug of Vidrion-R glass ionomer cement with 2mm thickness was inserted and access was sealed with a glass ionomer modified resin (Figure 2). In another visit, internal and external bleaching was done simultaneously. To do so, soft tissues were protected with solid petroleum jelly. After absolute isolation we removed the provisory seal and pumiced both teeth. We then placed Whiteness-HP (FGM) with a proportion of three drops of hydrogen peroxide to one drop of thickener (union of these two materials forms a dense purple colored paste to be placed on dental surface to be bleached) (Figure 3). 1,0mm thickness application of the product is done internally and externally with the aid of a microbrush. Photoactivation with an Optilight Digital, for forty seconds was done on the palatal and vestibular side of the teeth, waiting for total discoloration of the material (Figure 4). We then proceeded to remove the material washing it with abundant water and observing the color

obtained. Procedure was repeated twice in tooth 61 and four times in tooth 51. At the end of the bleaching, an A1 VITA shade was obtained with satisfactory esthetic results. The patient was dismissed after temporary sealing with glass ionomer cement (Vitremmer), topical application of neutral fluoride during one minute and recommendation to those responsible for the child to avoid or even eliminate ingestion of food and beverages that could stain teeth, such as sodas tea, grape juice, soybean sauce, coffee and colored candies.

In the next visit, as hypoplastic spots became evident, microabrasion was performed. Under absolute isolation we mixed an abrasive paste made of orthophosphoric acid in gel form at 35% with pumice (powder) in equal proportions. We placed the paste only on the hypoplastic stains with the aid of a resin spatula. We frictioned the area with a colorless wooden wedge and rubber cup mounted on a slow speed hand-piece alternating during one minute (Figure 5), washing with water and repeating the whole process twice on

each tooth. We then proceeded to rebuild the fractured teeth with satisfactory esthetic and functional results (Figure 6).

### COMMENTS

Acid conditioning with orthophosphoric acid at 35% is not necessary nor recommended before application of the bleaching agent as primary teeth are highly permeable due to the large diameter of the dental tubules.<sup>10</sup>

The material used in this technique, Whiteness HP (GM), with hydrogen peroxide at 35% has the advantage of a high active oxygen liberation, easy manipulation, relatively low cost, and dual activation (chemical and physical) accelerating the bleaching process.<sup>1,7,8,11</sup>

A minimal relapse in color in the first two days after bleaching was observed. Lorenzo<sup>8</sup> suggests that this phenomenon occurs due to subsequent rehydration of the dental structures, and the neoreduction of colored molecules.

Some authors suggest therefore after bleaching procedures, to polish the involved teeth with felt discs and polishing paste to create a smoother surface, avoiding that pigments deriving from diet or usage of oral products penetrate or impregnate the irregularities created after bleaching.<sup>1,13</sup>

Patient must return continuously to the dental office. If any evidence resorption is detected, treatment of calcium hydroxide must be immediately initiated.<sup>7,8</sup>

To place the final restoration in the bleached dental element, at least a week must elapse after bleaching, due to residual oxygen dissipating outside dental structure, which would inhibit adhesion and polymerization of the restorative materials.<sup>6,12,15</sup>

### CONCLUSION

Bleaching using the thermocatalytic technique is an esthetic conservative alternative, easy in the dental office. Results are immediate and very satisfactory

### REFERENCES

1. Balsamo M. Clareamento dental em dentes vitais: aplicação do Whiteness HP na prática diária. *Guia de Ofertas Dental Moretti* 5(15):20-21, 2004.
2. Baratieri LN. Clareamento de dentes. In: Baratieri LN, Monteiro JR, Andrada MAC, Vieira LCC, Ritter AV, Cardoso AC. *Odontologia Restauradora: fundamentos e possibilidades*. São Paulo: Santos, p. 673-722, 2002.
3. Bryan RA, Welbury RR. Treatment of aesthetic problems in pediatric dentistry. *Dent Update* 30:307-313, 2003.
4. Cabral BF, Oliveira NL. Uso combinado das técnicas de clareamento dental extracoronário e intracoronário. *Rev Assoc Paul Cir Dent* 55:105-107, 2001.
5. Carvalho EMOF, Robazza CRC, Marques JLSL. Análise espectrofotométrica e visual do clareamento dental interno utilizando laser e calor como fonte catalisadora. *Pesqui Odontol Bras* 16:337-342, 2002.
6. Consolaro A, Neuvald LR, Francisco R. Clareação dentária: implicações clínicas e sua relação com as reabsorções dentárias. In: Consolaro A. *Reabsorções dentárias nas especialidades clínicas: ortodontia, endodontia, odontopediatria, cirurgia e traumatologia, periodontia e prótese, radiologia, dentística, patologia, implantodontia*. 1st ed. Maringá: Dental Press, p.103-121, 2002.
7. Javaheri DS. Techniques for nonvital bleaching. *Pract Proced Aesthet Dent* 15:483-485, 2003.
8. Lorenzo JA, Gumbau GC, Sánchez CC, Navarro LF, Puy MCL. Clinical study of a halogen light-activated bleaching agent in nonvital teeth: Case reports. *Quintessence Int* 27:383-388, 1996.
9. Luk K, Tam L, Hubert M. Effect of light energy on peroxide tooth bleaching. *J Am Dent Assoc* 135:194-201, 2004.
10. Nakamura T, Saito O, Ko T, Maruyama T. The effects of polishing and bleaching on the colour of discoloured teeth in vivo. *J Oral Rehabil* 28:1080-1084, 2001.
11. Papatthanasidou A, Kastali S, Perry RD, Kugel G. Clinical evaluation of a 35% hydrogen peroxide in-office whitening system. *Compend Contin Educ Dent* 23:335-340, 2002.
12. Price RB, Sedarous M, Hiltz GS. The pH of tooth-whitening products. *J Can Dent Assoc* 66:421-426, 2000.
13. Spalding M, Taveira LA, Assis GJ. Scanning electron microscopy study of dental enamel surface exposed to 35% hydrogen peroxide: alone, with saliva, and with 10% carbamide peroxide. *J Esthet Restor Dent* 15:154-164, 2003.
14. Viscio D, Gaffar A, Fakhry-Smith S, Xu T. Present and future technologies of tooth whitening. *Compend Contin Educ Dent Suppl* 28:36-43, 2000.
15. Whitman FJ, Simon JF. A clinical comparison of two bleaching systems. *J Calif Dent Assoc* 23:59-64, 1995.