

Outcome of Dentigerous Cysts Treated with Marsupialization

Koca Huseyin */ Alpoz Esin** / Kazanc Aycan***

Objective: The aim of this study was to evaluate the results of dentigerous cysts in children treated with marsupialization. **Study design:** 35 dentigerous cysts from 35 children treated with marsupialization were included in the study. The age of the children ranged from 8 to 13 years old. **Results:** The findings of our study showed that the outcome of dentigerous cysts treated with marsupialization is successful resulting with the eruption of teeth and regeneration of bone. Accordingly a successful outcome was achieved either with or without the help of an orthodontic treatment. Postoperative follow-ups were un-eventful in all patients during a 5 year period. **Conclusion:** The results of the present study demonstrate that marsupialization may be a better choice of treatment for dentigerous cysts in children rather than the standard treatment.

Keywords: dentigerous cyst, children, marsupialization

J Clin Pediatr Dent 34(2): 165–168, 2009

INTRODUCTION

Several age-specific developmental processes in the maxillofacial skeleton take place during the pediatric period.^{1,2} Developmental cysts (keratocyst and dentigerous cyst) and inflammatory jaw cysts (radicular cyst) are the most frequently encountered pathological entities concerning this age interval with a high dynamic growth process.^{1,3} These cysts are usually symptomless and undetectable during their initial development. Due to the nature of jaw cysts attentive radiological evaluation (panoramic films or CT scans where panoramic films are exiguous) is often necessary for the early diagnosis of the lesion, before it reaches a considerable size which may cause destruction of jaw bones.⁴

Cystic lesions of maxillofacial region have been evaluated in several epidemiological studies³⁻⁶ and case reports.⁷⁻⁹ These studies however have mostly focused on adult populations^{3,5} while there are few retrospective studies focusing on oral maxillofacial biopsies in children.^{6,10,11} Regarding the few literature on the outcomes of dentigerous cysts in children treated with different surgical approaches, two basic

surgical procedures marsupialization and enucleation have been described.^{1,2} Marsupialization is defined as a conservative approach that is successful in treating large dentigerous cysts,⁸ whereas enucleation is considered as a more aggressive treatment type.¹²⁻¹⁵ Therefore the objective of this study was to evaluate the outcome of 35 dentigerous cysts treated with marsupialization and to compare the results of the present study to data obtained from previously published literature.

MATERIALS AND METHOD

Thirty-five dentigerous cysts from 35 children treated during a five-year period (21 males and 14 females, mean age 11.2 years) were evaluated in the study. All patients underwent clinical and radiological examination (periapical films, panoramic radiographs). In some of the patients CT scans were necessary for correct diagnosis and treatment planning. The diameter and localization of the cyst; age and gender of the children were also recorded.

Panoramic films were the preferred imaging procedures in all cases, while in 30% an additional CT scan was required. CT scans were the choice of imaging in large lesions extending to the nasal cavity, orbital or pterygomaxillary space.

All the patients were treated with marsupialization under local anesthesia and in every case the diagnosis of dentigerous cyst was confirmed by the histological examination of the removed tissue material.

Figures 1 and 2 illustrate the pre and post-treatment radiographs of a dentigerous cyst of mandible while Figure 3 shows treatment of a dentigerous cyst of maxilla. Following marsupialization once the epithelization is completed between cystic epithelium and oral mucosa a custom acrylic obturator was fabricated. This appliance is used to preserve permanent dentition while the cystic lesions are shrinking in size. During the healing period the adaptation of the

* Koca Huseyin Ege University Faculty of Dentistry Department Oral and MaxillofacialSurgery

** Alpoz Esin Ege University Faculty of Dentistry Department of Oral Diagnosis and Radiology

*** Kazanc Aycan, Ege University Faculty of Dentistry Department Oral and MaxillofacialSurgery

Send all correspondence to: Esin Alpoz, Ege University Faculty of Dentistry, Department of Oral Diagnosis and Radiology, Bornova/Izmir. 35100 Turkiye

Tel no: +90 232 3881081

Fax: +90 232 3880325

E-mail: esinalpz@yahoo.com

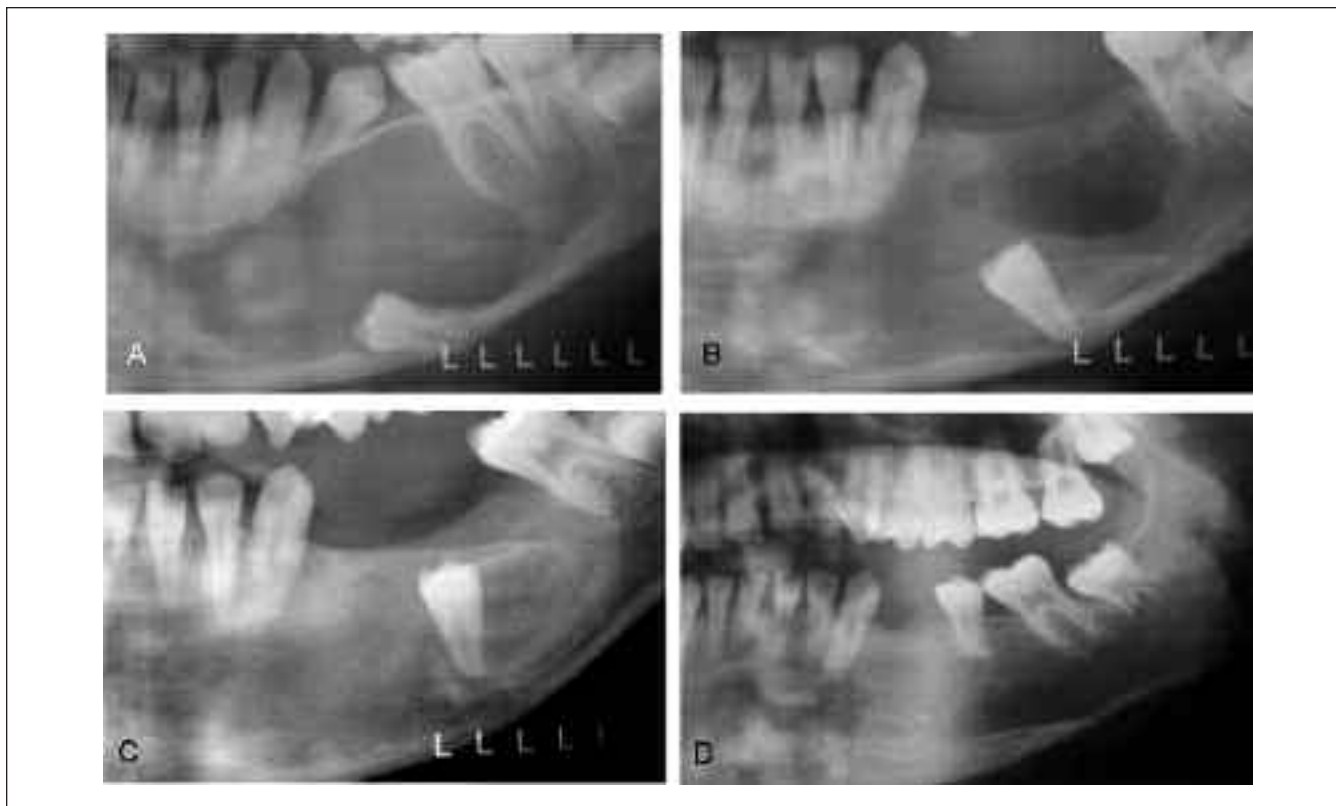


Figure 1. A. Dentigerous cyst in an 8 year-old girl, the radiolucent lesion around left premolar, displacing teeth due to cyst pressure. B. and C. Panoramic film one year after marsupialization showing the change in the eruption pattern and bone formation. D. Panoramic film 2 years after surgery, showing the premolar erupting in an upright position without orthodontic treatment.

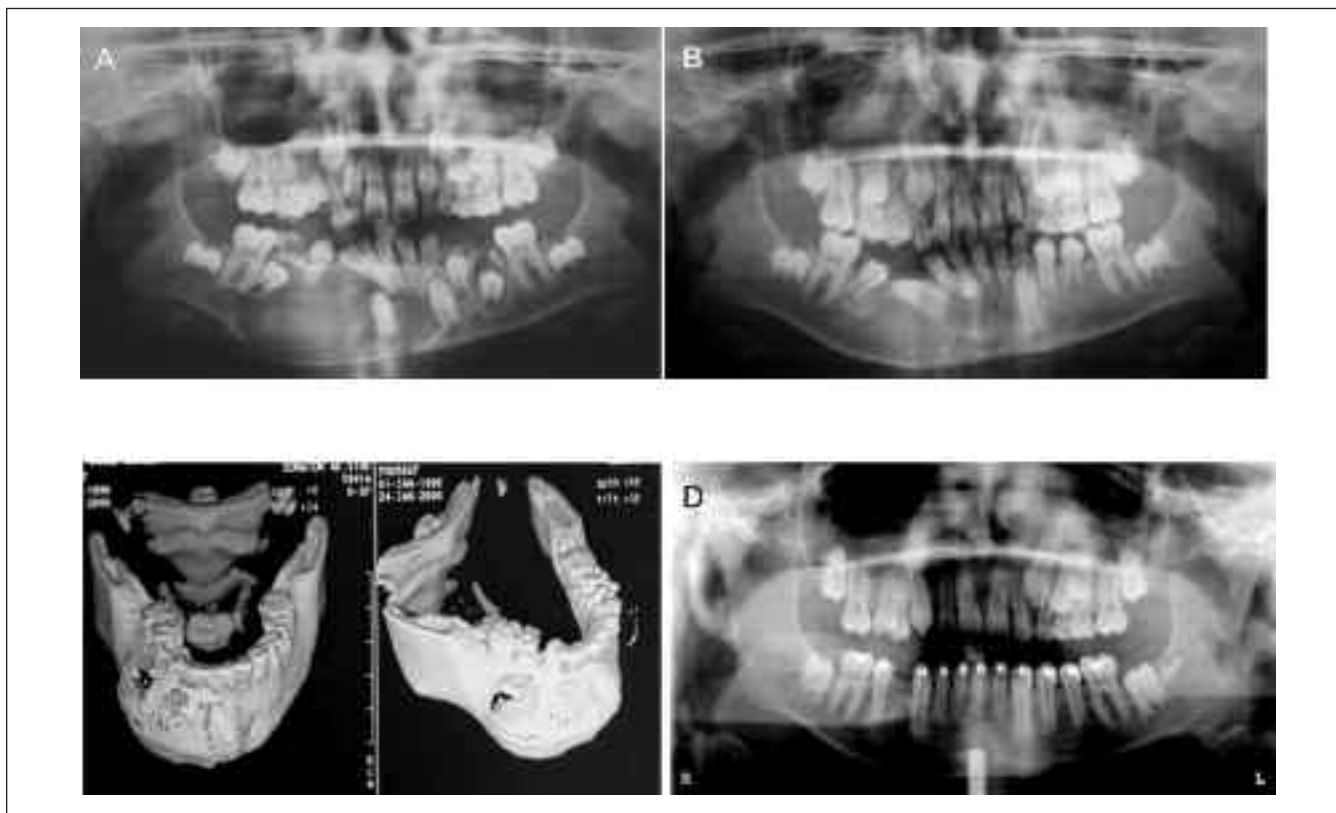


Figure 2. A. Panoramic film showing a dentigerous cyst in a 10 year-old boy, the radiolucent lesion around right mandibular canine, with tooth displacement due to cyst pressure. B. Panoramic film 6 months after marsupialization showing the change in tooth axis. C. CT scan of the same patient. D. The final panoramic film with the orthodontic treatment, the canine tooth positioned in the dental arch.

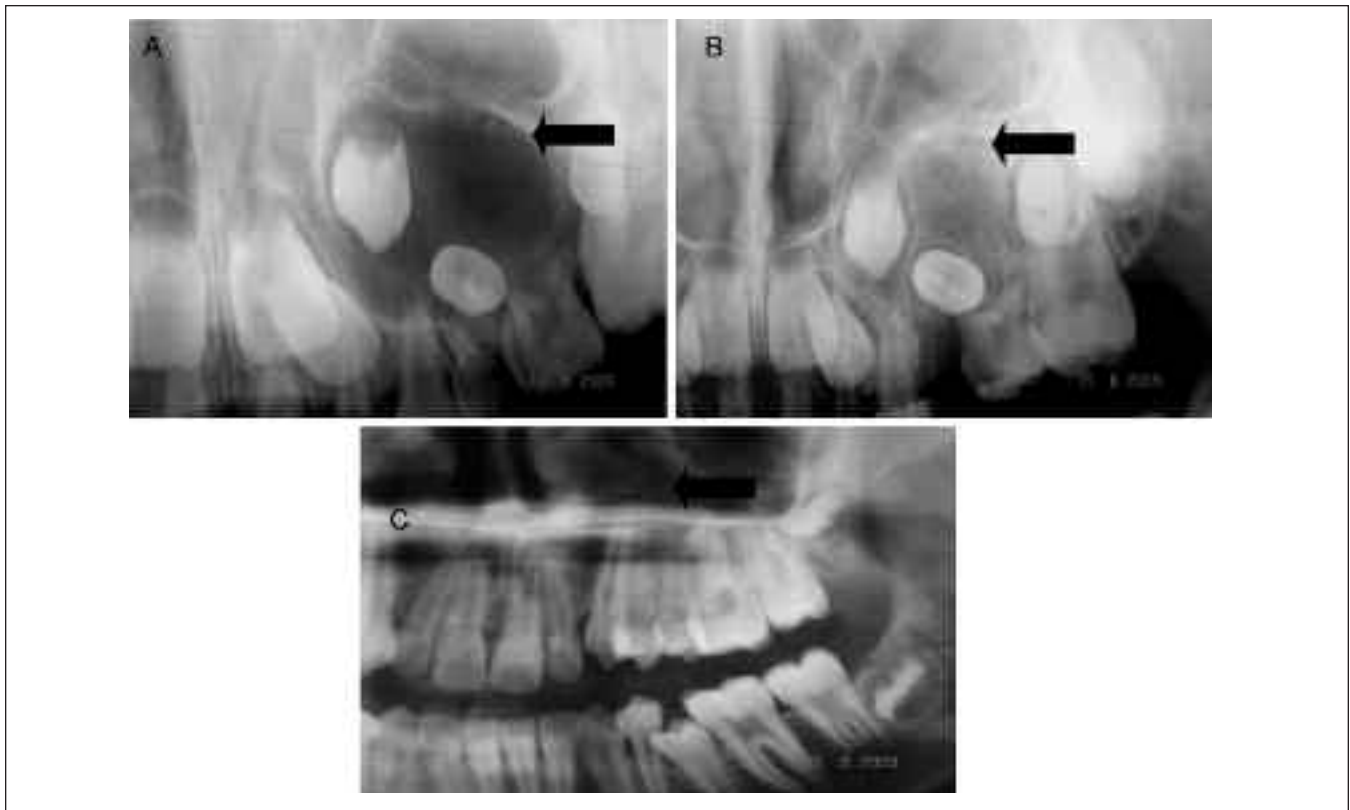


Figure 3. A. Left maxillary canine and premolars before treatment of the dentigerous cyst in 7 year old girl. B. Left maxillary canine and premolars after the treatment. C. The panoramic film of the same patient 1 year after the treatment with the teeth positioned in the arch.

obturator to the cyst cavity which is slowly decreasing in size is evaluated and the appliance modified whenever necessary. Also the parents are instructed to clean both the cystic cavity and the obturator (Figure 4).

After surgery, children were recalled for periodic follow-up visits (every three months, ranging from one to five years) and radiographs taken until all teeth erupted into the dental arch.

RESULTS

The number, mean diameter of dentigerous cysts and the mean age of patients included in the study are listed in Table 1.

Table 1. The table illustrates the mean diameter of dentigerous cysts and the demographic findings of the patients included in the study.

Total Number of patients	35
Mean diameter (cm)	7.6
Mean age	10.3
Female	14
Male	21

Of the 35 children in the study, 60% were male and 40% were female. The male to female ratio was 1.5:1. Mandible

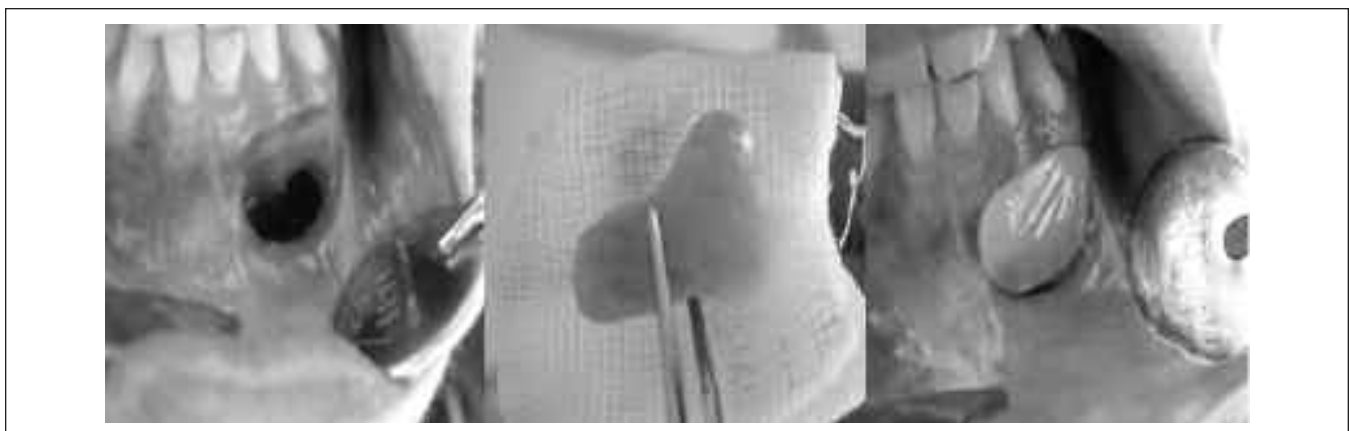

Figure 4. Following the completion of epithelization between oral mucosa and cystic epithelium, an impression of cavity is made with silicon impression material and an acrylic obturator is fabricated.

was involved in 49% and maxilla in 51%.

Swelling was the main complaint in 70% of the children, pain in 5%, while 25% had no symptoms.

In the present study, a more conservative approach marsupialization was favored and therefore special care was given to preserve the causative tooth. The outcome of cysts treated with marsupialization was successful in most of the cases. Of the 35 cysts treated 8 (24%) cases needed orthodontics to bring the unerupted tooth into the arch while in 12 cases (34%) permanent teeth erupted successfully into the alveolar arc without the need of an orthodontic treatment. In the remaining dentigerous cysts, 11(31%) cases presented a risk of morbidity to the adjacent anatomical structures; ie (mandibular fracture and damage to the mandibular canal, damage to the maxillary sinus) which were eliminated through marsupialization. On the other hand due to excessive alveolar bone loss and mobility, teeth were extracted in 4(11%) cases. Postoperative follow-ups were uneventful in all patients during a 5-year period.

DISCUSSION

The present study was conducted on a child population with a mean age of 11.2 years. Of the 35 cases treated the gender distribution was 1.5:1 (male: female), in accordance with the results of Iatrau.² On the contrary Bodner *et al*¹⁶ found an equal distribution between the genders.

Dentigerous cysts which are associated with an embedded or an unerupted tooth are among the most common jaw cysts in children.⁴ On radiographs they are seen as well defined radiolucent lesions of alveolar bone. Although they are often symptomless and found on routine dental radiographic examination, the pressure of the cyst may cause displacement of the tooth, effect eruption and reach considerable sizes, engendering facial deformities.^{12,13}

The standard treatment protocol for dentigerous cysts is enucleation and extraction of the involved tooth.⁷ Enucleation is indicated when there is no likelihood of damaging anatomical structures. On the other hand marsupialization can maintain impacted tooth in its cavity, promote its eruption and also minimize the risk of damage to important anatomical structures.^{1,14-16} Especially for young patients, the treatment modality should be as conservative as possible in order to decrease possible problems to the adjacent developing structures.¹³ Likewise in our study the outcome of marsupialization was successful in 31% of the cysts which were adjacent to anatomical structures (mandibular canal or maxillary sinus). Marsupialization has the advantage of reducing the cyst cavity and is effective in preserving the involved teeth. Therefore, it is recommended as an appropriate technique during the age when the eruptive power of teeth is strong and the capacity of bone repair process is high.¹⁹

Accordingly in the presented study orthodontic treatment was not necessary in 34% of the cases, and the teeth erupted spontaneously after marsupialization. On the contrary some investigators claim that marsupialization is not an appropriate surgical approach for dentigerous cysts since it

is a two stage procedure, and pathological tissue may be left behind or it may take a long time for the bone to regenerate after the surgical operation.^{1,16} In dentigerous cysts in a younger population however, the eruption of unerupted teeth makes the second stage surgical procedure unnecessary.⁷ Likewise, in all of our cases a successful bone regeneration and tooth eruption following marsupialization was achieved by one stage surgical procedure. Considering the ongoing growth process and with the aim of preserving the tooth buds of the permanent teeth in children, an aggressive surgical approach was not preferred.

CONCLUSION

The results of the present study conducted on children, reveal that the outcome of dentigerous cysts treated with marsupialization have successful outcomes. due to faster bone regeneration in children.

REFERENCES

1. Bodner L. Cystic lesions of the jaws in children. *Int J Pediatr Otorhinolaryngol*, 62: 25–29, 2002.
2. Iatrau I, Lygidakis NT, Leventis M. Intraosseous cystic lesions of jaws in children: A retrospective analysis of 47 consecutive cases. *Oral Surg Oral Med Oral Pathol Oral Radiol Endod*, 2008.
3. Köseoğlu BG, Atalay B, Erdem MA. Odontogenic cysts: a clinical study of 90 cases. *J Oral Sci*, 4: 253–257, 2004.
4. Oechsenius G, Escobar E, Godoy L, Christian P. Odontogenic Cysts: Analysis of 2.944 cases in Chile. *Med Oral Patol Cir Bucal*, 12:E85–91, 2007.
5. Meningaud JP, Oprean N, Pitak-Arnop P, Bertrand JC. Odontogenic cysts: a clinical study of 695 cases. *J Oral Sci*, 48: 59–62, 2006.
6. Lima GD, Fontes ST, Araujo LM, Etges A, Tarquinio SBC, Gomes APN. A survey of Oral and maxillofacial biopsies in children. A single center retrospective study of 20 years in Pelotas-Brazil. *J Appl Oral Sci*, 16: 397–402, 2008.
7. Martinez-Perez D, Varela-Morales M. Conservative Treatment of Dentigerous Cysts in Children: A Report of 4 Cases. *J Oral Maxillofac Surg*, 59: 331–334, 2001.
8. Clauser C, Zuccati G, Barone R, Villano A. Simplified Surgical-Orthodontic Treatment of a Dentigerous Cyst. *JCO*, 27: 103–106, 1994.
9. Agulio L, Gandia JL. Dentigerous cysts of mandibular second premolar in a five-year old girl, related to a non-vital primary molar removed one year earlier: a case report. *J Clin Pediatr Dent*, 22: 155–158, 1998.
10. Dhanuthai K, Banrai M, Limpanaputtajak S. A retrospective study of paediatric oral lesions from Thailand. *Int J Paediatr Dent*, 17: 248–253, 2007.
11. Gultelkin SE, Tokman B, Turkseven MR. A review of pediatric oral biopsies in Turkey. *Int Dent J*, 53: 26–32, 2003.
12. Jones AV, Franklin CD. An analysis of oral and maxillofacial pathology found in children over a 30-year period. *Int J Pediatr Dent*, 16: 19–30, 2006.
13. Welbury RR. *Paediatric Dentistry*. Oxford University Press, New York, pp. 328–330, 1997.
14. Ertaş U, Yavuz MS. Interesting eruption of 4 teeth associated with a large dentigerous cyst in mandible only by marsupialization. *J Oral Maxillofac Surg*, 61: 728–730, 2003.
15. Hyomoto M, Kawakami M, Inoue M, Kirita T. Clinical conditions for eruption of maxillary canines and mandibular premolars associated with dentigerous cysts. *Am J Orthod Dentofacial Orthop*, 124: 515–520, 2003.
16. Bodner L, Bar-Ziv J. Characteristics of bone formation following marsupialization of jaw cyst. *Dentomaxillofac Radiol*, 27: 166–171, 1998.