

## Soft Tissue Alterations Following Protraction Approaches with and without Rapid Maxillary Expansion

Canigur Bavbek N\* / Balos Tuncer B\*\* / Tortop T\*\*\*

**Objectives:** The aim of this study was to compare the soft tissue changes influenced by reverse headgear therapy with (RHg+RME) or without (RHg) rapid maxillary expansion with each other and with an untreated Class III control group (C). **Study design:** RHg group (10 girls, 6 boys, mean chronological age 11.1 years), RHg+RME group (12 girls, 4 boys, mean chronological age 10.8 years) and C group (7 girls, 11 boys, mean chronological age 10.2 years) comprised skeletally Class III patients with maxillary deficiency. Soft tissue measurements were made on lateral cephalograms at the beginning and at the end of the treatment and observation periods. Changes within each group and the differences between the groups were analyzed by paired t-test; the differences between the groups were determined by variance analysis and Duncan test with a significance level  $p < 0.05$ . **Results:** The sagittal depth of nose and maxilla, upper lip height and protrusion were significantly increased in treatment groups and the differences were significant when compared to control group ( $p < 0.05$ ). **Conclusion:** Forward movement of upper lip was more prominent in RHg group. Reverse headgear treatment with or without RME revealed significant soft tissue changes when compared with a growing Class III control group with the same skeletal characteristics.

**Keywords:** rapid maxillary expansion, reverse headgear, skeletal class III, soft tissue, orthodontics

### INTRODUCTION

The demands of patients seeking orthodontic treatment are generally focused on dentition, occlusal alignment and improvement of their soft tissue profiles. As the severity of the orthodontic problem increases, its reflection on soft tissues also increases. Class III skeletal problems may be based on a prognathic mandible, a retrognathic maxilla or a combination of both in which concave profiles, retrusive nasomaxillary areas and/or protrusive lower faces are seen.<sup>1-3</sup> For these patients, the challenge in soft tissues may become as important as skeletal and dentoalveolar corrections.

Regarding the etiology of Class III relationship and growth period of the patient, different treatment modalities can be chosen. Chin-cup has been used for the correction of Class III skeletal discrepancies due to mandibular prognathism<sup>4</sup>, whereas reverse headgear therapy has been the treatment choice for retrognathic maxilla in growing patients.<sup>5</sup> Adult patients are often enrolled in

surgical processes, unless the skeletal discrepancy cannot be camouflaged by fixed orthodontic treatment.<sup>6</sup>

Although Class III anomalies were identified as a problem of the mandible alone for a long period, the importance of maxillary protraction is now very well understood.<sup>1,3</sup> For this reason, numerous alterations in reverse headgear therapy have been made to improve the effects of the appliance.<sup>7,8</sup> Reverse headgear therapy has been assisted by rapid maxillary expansion (RME), in order to enhance forward maxillary growth by initiating activity in circummaxillary sutures.<sup>7</sup>

The effects of reverse headgear therapy with and without the assistance of RME on skeletal and dentoalveolar components of craniofacial region and the efficiency of maxillary protraction are well established and supported by the existing literature.<sup>7,9-12</sup> However, the studies analyzing soft tissue changes associated with these treatments in detail are limited.<sup>13-16</sup> Additionally, none of these studies specifically compared the effects of different treatment modalities on soft tissues with a growing Class III control group. Therefore, the aim of this study was to evaluate and compare soft tissue changes following reverse headgear (RHg) and reverse headgear plus rapid maxillary expansion (RHg+RME) therapies with each other and with an untreated Class III control group.

### MATERIALS AND METHOD

This retrospective study material consisted of lateral cephalograms of Class III subjects with maxillary deficiency, which were selected from the archives of Department of Orthodontics, Gazi University. The main inclusion criteria were presence of skeletal ( $ANB < 0^\circ$ ) and dental Class III malocclusion with maxillary retrusion ( $SNA < 82^\circ$ ;  $FH/NA < 87^\circ$ ), optimal mandibular plane angle (SN/

\* Nehir Canigur Bavbek, Research Assistant. Department of Orthodontics Faculty of Dentistry, Gazi University, Ankara, Turkey.

\*\* Burcu Balos Tuncer, Associate Professor. Department of Orthodontics Faculty of Dentistry, Gazi University, Ankara, Turkey.

\*\*\* Tuba Tortop, Professor. Department of Orthodontics Faculty of Dentistry, Gazi University, Ankara, Turkey.

Send all correspondence to: Nehir Canigur Bavbek, Gazi University, Faculty of Dentistry, Department of Orthodontics, 8.Cadde, 82. Sokak, 06510 Emek Ankara-Turkey

Phone: 0090-505-4282674

E-mail: ncanigur@yahoo.com

# Soft Tissue Alterations Following Protraction Approaches with and without Rapid Maxillary Expansion

**Table 1.** Changes in the treatment and control groups, and significance of changes in each group.

	RHg Group (n=16)					RHg+RME Group (n=16)					Control group (C) (n=18)				
	T1		T2		p	T1		T2		p	T1		T2		p
	Mean	SD	Mean	SD		Mean	SD	Mean	SD		Mean	SD	Mean	SD	
<b>Nose, Underlying skeleton</b>															
n'-prn'	42.3	0.89	43.3	1.45	NS	39.3	1.32	40.7	1.14	NS	39.4	0.84	39.3	0.75	NS
prn'-ans'	9.2	0.52	9.9	0.74	NS	12.3	0.44	11.4	0.25	NS	11.8	0.47	12.2	0.36	NS
prn'-prn	28.7	1.03	30.9	1.32	**	30.0	1.02	31.8	0.93	**	28.5	0.97	28.1	0.83	NS
PMV-prn'	49.1	1.05	50.0	0.87	*	44.1	0.85	45.4	1.07	NS	43.9	0.85	45.4	0.72	***
PMV-n'-prn	34.4	1.04	35.9	1.43	NS	37.7	1.23	38.7	1.13	NS	36.1	1.17	35.9	0.94	NS
PMV-ans'-prn	35.7	2.11	35.1	1.56	NS	35.8	1.87	35.3	1.60	NS	35.9	1.46	35.5	1.11	NS
<b>Maxilla, Upper lip</b>															
A-PMV	48.9	0.91	51.6	1.04	***	47.4	0.73	50.6	0.71	***	47.5	0.62	48.3	0.59	**
UL at A'-A	16.1	0.60	16.7	0.59	NS	15.6	0.27	15.5	0.46	NS	14.3	0.46	14.9	0.36	*
UL at A'-PMV	65.0	1.05	68.3	1.38	**	63	0.85	66.1	1.00	**	61.7	0.75	63.2	0.63	**
PMV-Ls'	53.8	0.91	58.1	1.25	***	53.1	0.86	56.7	0.78	***	51.7	0.75	53.0	0.78	**
UL at Ls'-Ls	13.3	0.69	13.2	0.41	NS	14.2	0.58	13.8	0.49	NS	14.3	0.57	14.2	0.68	NS
UL at Ls-PMV	67.1	1.16	71.3	1.39	**	67.3	1.06	70.4	0.92	**	65.9	0.89	67.2	0.68	*
UL-E	-3.2	0.33	-0.7	0.45	***	-2.2	0.34	-0.8	0.48	**	-1.6	0.51	-1.6	0.53	NS
Sn-ULstom	18.4	0.52	20.4	0.62	**	19.5	0.62	21.3	0.63	***	19.2	0.70	19.6	0.63	***
Cm-Sn-Ls	115.4	3.14	109.1	3.52	**	112.5	3.09	109.9	3.48	NS	111.1	3.31	109.8	3.22	NS
<b>Mandible, Lower lip</b>															
PMV-Li'	57.8	1.27	56.8	1.56	NS	56.9	0.82	56.7	0.97	NS	56.3	0.93	57.9	0.63	*
LL at Li-Li'	12.4	0.50	14.5	0.40	**	13.8	0.56	14.8	0.53	NS	13.3	0.41	13.2	0.33	NS
LL at Li-PMV	70.3	1.30	71.3	1.60	NS	70.7	0.99	71.5	1.09	NS	69.6	1.06	71.1	0.74	*
B-PMV	55.4	1.38	54.8	1.65	NS	56.7	0.99	56.2	1.19	NS	55.6	1.15	56.6	0.82	NS
LL at B'-B	11.6	0.46	11.3	0.35	NS	11.6	0.52	12.5	0.52	*	11.1	0.30	11.3	0.48	*
LL at B'-PMV	55.4	1.37	54.8	1.60	NS	68.3	1.10	68.7	1.34	NS	66.6	1.18	68	0.77	NS
LI-E	0.2	0.48	0.6	0.60	NS	0.6	0.42	0.0	0.52	NS	1.6	0.63	1.5	0.56	NS
B'-Llstom	20.5	0.51	20.8	0.48	NS	20.4	0.70	21.1	0.77	NS	19.2	0.49	19.3	0.51	NS
<b>Chin projection</b>															
Pg-Pg'	10.7	0.57	11.1	0.57	NS	10.9	0.55	10.8	0.62	NS	9.6	0.51	10.1	0.46	*
Pg-Pg''	12.2	0.43	11.9	0.54	NS	12.4	0.33	11.8	0.47	NS	13.0	0.36	12.8	0.35	NS
PMV-Pg'	68.5	1.35	67.9	1.90	NS	70.6	1.33	70.4	1.60	NS	68.4	1.42	69.9	1.06	NS
PMV-Pg''	45.6	1.47	45.0	1.80	NS	47.3	1.36	47.8	1.41	NS	45.8	1.47	47.0	1.11	NS
Pg-B-PMV	7.4	1.51	7.4	1.69	NS	11.2	1.56	12.6	1.54	NS	11.1	1.52	11.1	1.45	NS
Pg'-B'-PMV	7.3	1.26	7.1	1.75	NS	10.5	1.54	9.1	1.66	NS	7.7	1.32	9.6	1.30	*
Li-B'-Ct	145.6	3.10	139.8	3.07	*	138.6	2.07	131.6	2.59	**	146.2	2.04	145.8	1.94	NS

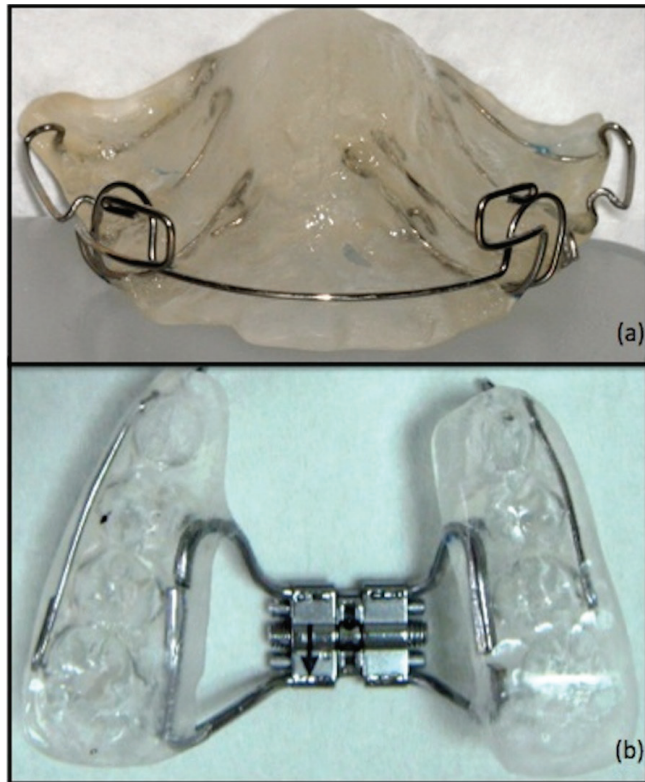
RHg, reverse headgear group; RHg+RME group, reverse headgear plus rapid maxillary expansion group; SD, standard deviation.

\*p<0.05; \*\*p<0.01; \*\*\*p<0.001; NS, not significant.

GoGn: 32±6°), anterior crossbite of all upper incisors with no functional shift, no congenital anomalies in the medical history. From 82 patients who fitted above criteria, patients with chronological age between 10-12 years and that were in prepubertal period according to the evaluation of their hand and wrist radiographs by Greulich and Pyle Atlas were chosen. The final group who fulfilled the whole criteria and enrolled in the study was composed of 50 subjects (29 girls, 21 boys). The written informed consent forms of all patients were present in the files.

Reverse headgear (RHg) group consisted of 16 patients (10 girls, 6 boys, mean chronological age: 11.1 years) who were treated with only reverse headgear for an average of 13.2 months. RHg+RME group included 16 skeletal Class III patients (12 girls, 4 boys, mean chronological age: 10.8 years) that were treated with reverse headgear with RME for an average of 14.7 months.

Patients were instructed to wear Delaire-type reverse headgear for 14-16 hours *per* day in both treatment groups. In RHg group, an acrylic removable appliance was used intraorally (Fig. 1A).

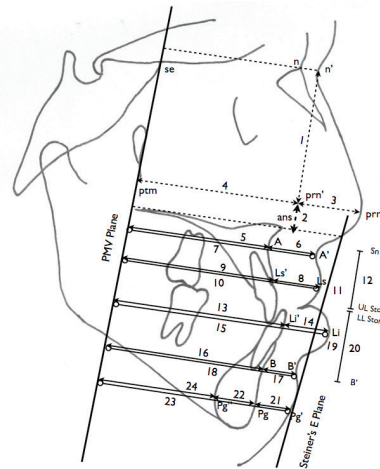


**Figure 1.** Intraoral appliances for the treatment groups: (a)RHg; (b) RHg+RME

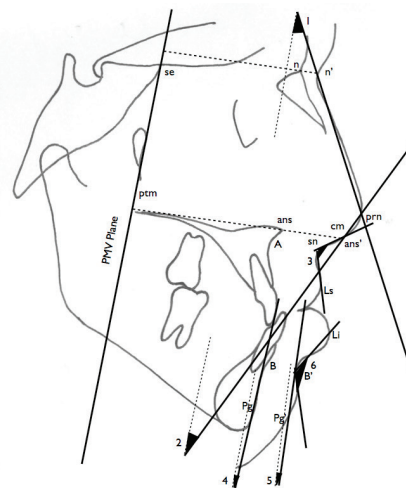
Patients who had transverse discrepancy in maxilla were included in RHg+RME group. Transverse discrepancy was first detected by the initial clinical examination and supported by the Ricketts analysis made on each patient's postero-anterior radiograph. These patients had a Hyrax expander with acrylic splint on maxillary posterior teeth (Fig. 1B), and were instructed to turn the screw one-turn per day until the palatal cusp of upper first molars were in contact with the buccal cusp of lower first molars. An average protraction force of 400-600g *per* side was applied by elastics from the hooks embedded inside the acrylic between the upper canines and lateral incisors in both groups, with an angle of approximately 20-30° downward from the occlusal plane and elastics were changed everyday. The therapy lasted until skeletal (ANB 0-4°) and dental Class I relationship and positive (>2mm) overjet were achieved.

The data of the control group, which were collected for a previous longitudinal study were matched with treatment groups according to their chronological age, and included 18 skeletal Class III patients (7 girls, 11 boys, mean chronological age: 10.2 years) who were observed for 9.7 months without any treatment.

The pre-treatment (T1) and post-treatment (T2) lateral cephalometric radiographs of the treatment groups, and two cephalometric radiographs of the control group for observation (T1 and T2, respectively) were achieved. All radiographs were taken with Trophy Instrumentarium Cephalometer (OP 100, Finland) at 70 KVp, 16 mA/sec. The lateral cephalometric radiographs were manually traced with a 0.03-mm mechanical pencil, and measurements were performed on the tracings. Linear and angular measurements concerning hard and soft tissues were made according to the definitions provided by Nanda et al.<sup>17</sup> at the beginning and at the end of treatment/observation time (Fig. 2 and Fig. 3). In order to understand the effects of treatment



**Figure 2.** Linear measurements: upper nose height (1); lower nose height (2); nose depth (3); skeleton underlying nose (4); sagittal depth of maxillary bone at A (5); upper lip thickness at A' (6); sagittal depth of upper lip at A' (7); upper lip thickness at Ls (8); sagittal depth of maxillary bone at Ls' (9); sagittal depth of upper lip at Ls (10); upper lip to Steiner's esthetic plane (11); upper lip height (12); hard tissue projection of lower lip (13); lower lip thickness at Li (14); sagittal depth of lower lip at Li(15); sagittal depth of mandibular bone at B (16); lower lip thickness at point B (17); sagittal depth of lower lip at B (18); lower lip to Steiner's esthetic plane (19); lower lip height (20); soft tissue chin thickness (21); thickness of the symphysis (22); sagittal depth of soft tissue pogonion (23); skeletal length of the mandibular corpus (24).



**Figure 3.** Angular measurements: angle of dorsum of the nose (1); inclination of the base of the nose (2); nasolabial angle (3); inclination of the hard tissue chin (4); inclination of the soft tissue chin (5); mentolabial angle (6)

modalities and growth during T1 and T2, a reference line passing from Se and ptm points (PMV) were drawn on the cephalograms at T1. Then, cephalograms at T1 and T2 were superimposed according to Bjork and Skieller<sup>18</sup> and PMV line was transferred to the cephalograms at T2. Defined linear and angular measurements were made on the cephalograms at T2 after this procedure.

Intraexaminer reliability was evaluated after the same examiner remeasured 10 randomly selected cephalometric radiographs among all groups, 30 days after the first measurements were made. This procedure consisted of landmark identification and measurements;

**Table 2.** Comparison of the mean differences between treatment and control groups.

	RHg Group (n=16)		RHg+RME Group (n=16)		Control (C) Group (n=18)		RHg-RH- g+RME	RHg+	RHg-C
	X	SD	X	SD	X	SD		RME-C p	
<b>Nose, Underlying skeleton</b>									
n'-prn' (upper nose height)	1.1	0.78	1.3	0.71	0.0	0.45	NS	NS	NS
prn'-ans' (lower nose height)	0.7	0.41	-0.8	0.49	0.4	0.45	NS	NS	NS
prn'-prn (nose depth)	2.2	0.67	1.8	0.45	-0.4	0.59	NS	*	*
PMV-prn' (skeleton underlying nose)	0.9	0.41	1.3	0.63	1.6	0.35	NS	NS	NS
PMV-n'-prn (angle of dorsum of the nose)	1.6	0.75	0.9	0.73	-0.2	0.63	NS	NS	NS
PMV-ans'-prn (inclination of base of the nose)	-0.6	1.23	-0.4	1.28	-0.4	1.19	NS	NS	NS
<b>Maxilla, Upper lip</b>									
A-PMV (sagittal depth of maxillary bone)	2.7	0.48	3.1	0.49	0.8	0.27	NS	*	*
UL at A'-A (upper lip thickness at point A)	0.6	0.57	-0.1	0.45	0.7	0.27	NS	NS	NS
UL at A'-PMV (sagittal depth of upper lip at point A')	3.3	0.86	3	0.61	1.5	0.40	NS	NS	NS
PMV-Ls' (hard tissue projection of upper lip)	4.3	0.75	3.6	0.63	1.3	0.44	NS	*	*
UL at Ls'-Ls (upper lip thickness at point Ls)	-0.1	0.50	-0.4	0.51	-0.1	0.37	NS	NS	NS
ULat Ls-PMV (sagittal depth of upper lip at point Ls)	4.2	0.98	3.2	0.67	1.2	0.48	NS	NS	*
UL-E (upper lip to Steiner esthetic plane)	2.6	0.47	1.4	0.38	0.0	0.21	*	*	*
Sn-ULstom (upper lip height)	1.9	0.51	1.7	0.34	0.4	0.37	NS	*	*
Cm-Sn-Ls (nasolabial angle)	-6.4	1.98	-2.7	2.52	-1.2	1.70	NS	NS	NS
<b>Mandible, Lower lip</b>									
PMV-Li' (hard tissue projection of lower lip)	-1.0	0.85	-0.2	0.65	1.7	0.57	NS	NS	*
LL at Li-Li' (lower lip thickness at point Li)	2.1	0.50	1.0	0.51	-0.2	0.33	NS	NS	*
LL at Li-PMV (sagittal depth of lower lip at point Li)	1.1	1.08	0.8	0.58	1.5	0.65	NS	NS	NS
B-PMV (sagittal depth of the mandible at B)	-0.6	1.09	-0.5	0.68	1.1	0.60	NS	NS	NS
LL at B'-B (lower lip thickness at point B)	-0.2	0.38	0.8	0.35	0.2	0.36	NS	NS	NS
LL at B'-PMV (sagittal depth of lower lip at point B')	-0.6	1.08	0.3	0.83	1.3	0.69	NS	NS	NS
LL-E (lower lip to Steiner esthetic plane)	0.4	0.57	-0.5	0.54	-0.2	0.28	NS	NS	NS
B'-LLstom (lower lip height)	0.3	0.33	0.7	0.39	0.1	0.49	NS	NS	NS
<b>Chin projection</b>									
Pg-Pg' (soft tissue chin thickness)	0.4	0.36	-0.1	0.27	0.5	0.21	NS	NS	NS
Pg-Pg'' (thickness of the symphysis)	-0.3	0.28	-0.7	0.35	-0.3	0.22	NS	NS	NS
PMV-Pg' (sagittal depth of soft tissue pogonion)	-0.5	1.21	-0.2	0.92	1.5	0.77	NS	NS	NS
PMV-Pg'' (skeletal length of the mandibular corpus)	-0.6	1.22	0.6	0.76	1.3	0.74	NS	NS	NS
Pg-B-PMV (inclination of the hard tissue chin)	0.0	0.86	1.4	1.23	-0.1	0.53	NS	NS	NS
Pgs-B'-PMV (inclination of the soft tissue chin)	-0.2	1.01	-1.4	1.25	1.9	0.66	NS	*	NS
Li-B'-Ct (mentolabial angle)	-5.9	2.42	-7.0	1.95	-0.4	1.36	NS	*	NS

RHg group, reverse headgear group; RHg+RME group, reverse headgear plus rapid maxillary expansion group

\*p<0.05; NS, not significant

and Pearson correlation analysis was used to assess the reliability and reproducibility of these variables. The reliability coefficients (r<sup>2</sup>) calculated for each parameter were between 0.90 and 0.99 with the lowest coefficient (0.90) belonged to mentolabial angle.

**Statistical Analysis**

All data were analyzed using SPSS for Windows, version 16.0 package (SPSS INC., Chicago, Illinois, USA). After checking the data normality using Shapiro-Wilk test, due to the normal distribution of data, parametric tests were used for analysis. Intergroup

comparisons of pretreatment values were made by variance analysis and Duncan test. Changes within each group were analyzed by paired t-test whereas the differences between the groups were determined by variance analysis and Duncan test. A p value less than 0.05 (p< 0.05) was considered as statistically significant in all tests.

**RESULTS**

Comparison of pretreatment values between groups was made. The means and standard deviations of each variable measured at the beginning and end of treatment or observation periods (T1, T2,

respectively) are presented in Table 1. The treatment and observation period changes (T2-T1), and comparison of mean differences between groups are presented in Table 2.

### Comparison of pretreatment values of RHg, RHg+RME and Control groups

Sagittal depth of maxillary bone (A-PMV;  $p<0.05$ ) and skeletal length of mandibular corpus (PMV-Pg<sup>''</sup>;  $p<0.05$ ) were significantly different between RHg and control groups. Inclination of base of the nose (PMV-ans'-prn;  $p<0.05$ ) was significantly different in both treatment groups compared to control group. Lower nose height (prn'-ans';  $p<0.05$ ) was different between treatment groups and RHg and control group. Nose depth (prn'-prn;  $p<0.05$ ) was different between treatment groups and RHg+RME group and control group.

#### Treatment changes in RHg group

The maxilla moved forward, revealed by the significant increases in the sagittal depth of the maxillary bone (PMV-A;  $p<0.001$ ) and the sagittal depth of the underlying skeleton (PMV-prn<sup>'</sup>;  $p<0.05$ ). Soft tissue findings indicated an increase in nose depth (prn-prn<sup>'</sup>;  $p<0.01$ ) and the protrusion of the upper lip (UL-E;  $p<0.001$ , A'PMV and Ls-PMV;  $p<0.01$ ). While the height of the upper lip increased (Sn-ULstom;  $p<0.01$ ), the thickness of the upper lip at point A (UL at A-A') didn't change significantly after treatment. Due to the sagittal movement of the upper lip, the nasolabial angle decreased ( $p<0.01$ ). Lower lip thickness at Li (LL at Li-Li') increased ( $p<0.01$ ) whereas mentolabial angle decreased significantly ( $p<0.05$ ).

#### Treatment changes in RHg+RME group

Significant increases in the sagittal depth of maxillary bone (PMV-A) and nose depth (prn-prn<sup>'</sup>) were found ( $p<0.001$ ,  $p<0.01$ , respectively). The upper lip protruded according to PMV line (Ls'-PMV and A'-PMV;  $p<0.01$ ) and Steiner's esthetic plane (UL-E;  $p<0.01$ ). The height of the upper lip (Sn-ULstom) increased significantly ( $p<0.001$ ) while the thickness of the lip at point A (UL at A-A') remained constant. Lower lip thickness at point B (LL at B-B') increased ( $p<0.05$ ) and accordingly there was a significant decrease in the mentolabial angle ( $p<0.01$ ).

#### Observation period changes in Control group

During the observation period, sagittal depth of the underlying skeleton (PMV-prn<sup>'</sup>) and maxillary bone (PMV-A) increased significantly ( $p<0.001$ ,  $p<0.01$ , respectively). Consecutively, upper lip thickness at point A (UL at A-A';  $p<0.05$ ) and the upper lip height (Sn-ULstom;  $p<0.001$ ) showed significant increases and the protrusion of the upper lip (A'-PMV;  $p<0.01$  and Ls-PMV;  $p<0.05$ ) was statistically significant. Lower lip thickness increased significantly (LL at B-B' and Li-PMV;  $p<0.05$ ). Soft tissue thickness of the chin at pogonion (Pg-Pg') increased significantly ( $p<0.05$ ). As a result, inclination of the soft tissue chin (Pg'-B'-PMV) became more prominent at the end of the observation period ( $p<0.05$ ).

#### Comparison of changes in RHg, RHg+RME and Control groups

Increasing changes in nose depth (prn-prn<sup>'</sup>), sagittal depth of maxillary bone (A-PMV) and upper lip length (Sn-ULstom) in RHg and RHg+RME groups were statistically different from control group. The protrusion of upper lip according to Steiner's esthetic plane was significantly different in all groups; RHg group being the highest

and the control group being the least. Ls-PMV distance, which supported the protrusion of the upper lip and the increase in its thickness was also significantly higher in RHg compared to the control group ( $p<0.05$ ). Inclination of the soft tissue chin (Pg'-B'-PMV) and mentolabial angle (Li-B'-Ct) in RHg+RME group decreased whereas inclination of the soft tissue chin decreased and mentolabial angle increased in control group and the difference between groups was statistically significant ( $p<0.05$ ).

### DISCUSSION

Precise knowledge of the soft tissue effects of any orthodontic treatment is required since the attention of patients and professionals on the esthetic aspects of orthodontic treatment has been increased. This phenomenon is specifically important while evaluating the treatment results of skeletal discrepancies such as retrognathic maxilla where both skeletal and dental components are forced to enhance and support soft tissues. There are numerous studies in literature that reported the skeletal and dental changes occurred after reverse headgear therapy<sup>7, 9-12, 19</sup> but the information on soft tissue changes is limited. Thus, this study was designed to evaluate the soft tissue changes following maxillary protraction with or without the assistance of RME compared to an untreated Class III control sample, which gave the opportunity to see the regular growth pattern and pure effects of the appliances.

The control group was closely matched with the treatment groups for chronological age and observation period. The presence of a Class III control group is crucial to compare the normal growth pattern of these patients and to understand how the original growth pattern of soft tissues could be influenced by reverse headgear therapy in Class III subjects. The advantages of using an untreated Class III control sample had been discussed in a previous literature.<sup>20</sup>

Prepubertal patients were selected in the study and the groups were compared with each other according to their chronological ages at T1 (11.1 years for RHg group and 10.8 years for RHg+RME group). As recommended by some authors,<sup>2, 21</sup> treatment of Class III subjects at earlier ages seems to be mandatory. However, studies designed to compare the effects of maxillary protraction at different ages showed similar results in pre-pubertal and pubertal peak stages.<sup>11, 19, 22</sup>

The measurements in the cephalograms at T2 were made according to the reference plane (PMV) which was transferred from the cephalograms at T1 when the radiographs were superimposed according to the directions of Bjork and Skieller.<sup>18</sup> According to Nanda *et al*,<sup>17</sup> in order to provide a stable, reproducible reference plane to study the changes in the soft tissue profile, the pterygomaxillary vertical plane can be used. It is also stated that pterygomaxillary (ptm) and spenoethmoidal (Se) points are relatively stable during growth.

Although there were differences in measurements about the nose, it can be concluded that this parameter is highly dependent on personal changes and heredity. Therefore, the changes about these parameters at T2 might not reflect the effects of treatment alone and discussing them can be misleading. In terms of pretreatment evaluation of A-PMV between RHg and control groups, a difference is reported at T1, but the treatment effect with RHg is obvious (2.7mm) compared to control group (0.8mm) at T2. Although a significant difference about this parameter at T1 was reported, the difference between the groups can be attributed to the treatment effects of RHg and protraction of maxilla.

Evaluation of the overall measurements remarked the increase in sagittal depth of the maxilla at point A in all groups in this study, and it was consistent with previous literature.<sup>8,23-25</sup> The change in RHg+RME and RHg groups, however, were more prominent and the difference between the treatment groups and the control group was statistically significant. This data supported the fact that the reverse headgear therapy increases the sagittal growth of maxilla when compared to a normal growth pattern. At the same time, results also pointed out that there was no significant difference between two therapies regarding the sagittal movement of the hard tissues. This finding is antithetical to the studies of some authors who believed that RME increases the sagittal movement of maxilla when it is combined with a reverse headgear.<sup>9,25</sup> On the other hand, it is supported with some other literature findings which found no difference between these two entities.<sup>26,27</sup> In this study, rapid maxillary expansion was applied to the children with transversal discrepancy. To discuss the pure effects of rapid maxillary expansion on the amount of protraction of maxilla, applying rapid palatal expander to the patients without transversal discrepancy would be a better study design. However, the results of this study showed that if indication for the treatment approach was correct, reverse headgear with or without rapid maxillary expansion would be effective methods for the protraction of the maxilla.

Previously, different studies pointed out that the soft tissue responses can be altered by maxillary protraction appliances in Class III malocclusion subjects, and significant improvements were reported.<sup>13-16, 22-24</sup> Current results showed that protrusion of the upper lip according to Steiner's esthetic plane was the most in RHg group, RHg+RME group and control group, respectively and the differences between groups were statistically significant. The change in A'-PMV and Ls-PMV distances observed on superimpositions corroborated with prior measurements but only the difference between the RHg and control groups were statistically significant. This also explains the significant decrease of nasolabial angle in RHg group at T2. Our results are in accordance with other studies<sup>13,16</sup> and support the findings showing the improvement on soft tissue profile reached by reverse headgear therapy.

The statistically significant increase of the upper lip height was more prominent in treatment groups when compared to the control group. A previous study declared a similar increase in upper lip length after reverse headgear therapy with a removable appliance.<sup>28</sup> This may suggest a possible reflection of anterior maxillary rotation on the soft tissue profile which is known to be induced by reverse headgear therapy.<sup>22,28</sup>

The inclination of the soft tissue chin increased in the control group while it decreased in the RHg+RME group and the difference between groups was statistically significant. In coordination with our results, Arman *et al*<sup>16</sup> previously reported that soft tissue chin moved downward significantly in patients treated with reverse headgear and rapid maxillary expansion. As it is well known, reverse headgear therapy causes a posterior rotation in the mandible<sup>19, 22, 25, 28</sup> and RME has a similar effect as well.<sup>29</sup> Ngan *et al*,<sup>24</sup> using maxillary expansion and reverse headgear therapy found that downward and backward movement of the soft tissues were 71-81% of the hard tissue mandible and the study made by Singh *et al*<sup>30</sup> also supported these findings. These variables are in agreement with the results of our study which show the unfavorable soft tissue reflection of the

posterior rotation of the mandible; especially in greater extent when a RME is added to reverse headgear therapy. On contrary, soft tissue chin thickness and inclination of the soft tissue chin increased in untreated control group. According to Nanda *et al*,<sup>17</sup> this angle tends to increase by time which indicates the slope of the chin became more oblique. In Class III subjects, chin prominence increases by age<sup>30</sup> and the concave soft tissue profile becomes more dominant.

Overall, like most of the studies the present results concerning soft tissue evaluations were based on two-dimensional cephalometric measurements, which cannot completely predict clinical efficiency due to the limitations of degrading three dimensions to two. Therefore, investigations with three-dimensional analysis could provide more beneficial input in evaluating changes of the craniofacial soft tissues after orthopedic treatments. However, regular usage of these methods are needed to be widely spread in order to become effectively comparable. Till that date, studies with two-dimensional data will continue to enlighten our knowledge about changes after different orthodontic modalities.

## CONCLUSIONS

Soft tissue changes in treatment groups may result from the underlying skeletal movements induced by orthodontic treatment.

Reverse Headgear treatment with or without RME revealed significant soft tissue changes in nose depth, position and the length of the upper lip and soft tissue chin when compared with a growing Class III control group with the same skeletal characteristics.

Forward movement of upper lip was more prominent with Reverse headgear treatment only.

The only significant difference between all study groups were the protrusion of upper lip according to Steiner's esthetic plane.

Further studies including fixed appliances after reverse headgear application for these patients would be beneficial for clinicians to evaluate the overall effects of orthodontic therapy.

## REFERENCES

- Guy EC, Ellis EE, 3rd, McNamara JA, Jr., Behrents RG. Components of class III malocclusion in juveniles and adolescents. *Angle Orthod* 56: 7-30, 1986.
- Campbell PM. The dilemma of Class III treatment. Early or late? *Angle Orthod* 53: 175-91, 1983.
- Ellis E, 3rd, McNamara JA, Jr. Components of adult Class III malocclusion. *J Oral Maxillofac Surg* 42: 295-305, 1984.
- Graber LW. Chin cup therapy for mandibular prognathism. *Am J Orthod* 72: 23-41, 1977.
- Delaire J. Maxillary development revisited: relevance to the orthopaedic treatment of Class III malocclusions. *Eur J Orthod* 19: 289-311, 1997.
- Bailey LJ, Dover AJ, Proffit WR. Long-term soft tissue changes after orthodontic and surgical corrections of skeletal class III malocclusions. *Angle Orthod* 77:389-96, 2007.
- Nartallo-Turley PE, Turley PK. Cephalometric effects of combined palatal expansion and facemask therapy on Class III malocclusion. *Angle Orthod* 68: 217-24, 1998.
- Takada K, Petdachai S, Sakuda M. Changes in dentofacial morphology in skeletal Class III children treated by a modified maxillary protraction headgear and a chin cup: a longitudinal cephalometric appraisal. *Eur J Orthod* 15: 211-21, 1993.
- Turley PK. Managing the developing Class III malocclusion with palatal expansion and facemask therapy. *Am J Orthod Dentofacial Orthop* 122: 349-52, 2002.
- Williams MD, Sarver DM, Sadowsky PL, Bradley E. Combined rapid maxillary expansion and protraction facemask in the treatment of Class III malocclusions in growing children: a prospective long-term study. *Semin Orthod* 3: 265-74, 1997.

11. Yuksel S, Ucem TT, Keykubat A. Early and late facemask therapy. *Eur J Orthod* 23:559-68, 2001.
12. Tanne K, Sakuda M. Biomechanical and clinical changes of the craniofacial complex from orthopedic maxillary protraction. *Angle Orthod* 61: 145-52, 1991.
13. Kilicoglu H, Kirlic Y. Profile changes in patients with class III malocclusions after Delaire mask therapy. *Am J Orthod Dentofac Orthop* 113: 453-62, 1998.
14. Kilic N, Catal G, Kiki A, Oktay H. Soft tissue profile changes following maxillary protraction in Class III subjects. *Eur J Orthod* 32: 419-24, 2010.
15. Lin JX, Huang JF, Zeng XL. A cephalometric evaluation of hard and soft tissue changes during class III traction. *Eur J Orthod* 7: 201-4, 1985.
16. Arman A, Toygar TU, Abuhijleh E. Profile changes associated with different orthopedic treatment approaches in Class III malocclusions. *Angle Orthod* 74: 733-40, 2004.
17. Nanda RS, Meng H, Kapila S, Goorhuis J. Growth changes in the soft tissue facial profile. *Angle Orthod* 60: 177-90, 1990.
18. Bjork A, Skieller V. Facial development and tooth eruption. An implant study at the age of puberty. *Am J Orthod* 62: 339-83, 1972.
19. Lee DY, Kim ES, Lim YK, Ahn SJ. Skeletal changes of maxillary protraction without rapid maxillary expansion. *Angle Orthod* 80: 504-10, 2010.
20. Shanker S, Ngan P, Wade D, Beck M, Yiu C, Hagg U, et al. Cephalometric A point changes during and after maxillary protraction and expansion. *Am J Orthod Dentofac Orthop* 110: 423-30, 1996.
21. Baccetti T, McGill JS, Franchi L, McNamara JA, Jr., Tollaro I. Skeletal effects of early treatment of Class III malocclusion with maxillary expansion and face-mask therapy. *Am J Orthod Dentofac Orthop* 113: 333-43, 1998.
22. Yavuz I, Halicioglu K, Ceylan I. Face mask therapy effects in two skeletal maturation groups of female subjects with skeletal Class III malocclusions. *Angle Orthod* 79: 842-8, 2009.
23. Arman A, Ufiuk Toygar T, Abuhijleh E. Evaluation of maxillary protraction and fixed appliance therapy in Class III patients. *Eur J Orthod* 28: 383-92, 2006.
24. Ngan P, Hagg U, Yiu C, Merwin D, Wei SH. Soft tissue and dentoskeletal profile changes associated with maxillary expansion and protraction headgear treatment. *Am J Orthod Dentofac Orthop* 109: 38-49, 1996.
25. Baik HS. Clinical results of the maxillary protraction in Korean children. *Am J Orthod Dentofac Orthop* 108: 583-92, 1995.
26. Kim JH, Viana MA, Graber TM, Omerza FF, BeGole EA. The effectiveness of protraction face mask therapy: a meta-analysis. *Am J Orthod Dentofacial Orthop* 115: 675-85, 1999.
27. Tortop T, Keykubat A, Yuksel S. Facemask therapy with and without expansion. *Am J Orthod Dentofac Orthop* 132: 467-74, 2007.
28. Ucuncu N, Ucem TT, Yuksel S. A comparison of chin cap and maxillary protraction appliances in the treatment of skeletal Class III malocclusions. *Eur J Orthod* 22: 43-51, 2000.
29. Kilic N, Kiki A, Oktay H, Erdem A. Effects of rapid maxillary expansion on Holdaway soft tissue measurements. *Eur J Orthod* 30: 239-43, 2008.
30. Singh GD, McNamara JA, Jr., Lozanoff S. Finite-element morphometry of soft tissue morphology in subjects with untreated Class III malocclusions. *Angle Orthod* 69: 215-24, 1999.

Downloaded from [http://meridian.allenpress.com/jcpd/article-pdf/38/3/277/1751146/jcpd\\_38\\_3\\_e370xpng57461375.pdf](http://meridian.allenpress.com/jcpd/article-pdf/38/3/277/1751146/jcpd_38_3_e370xpng57461375.pdf) by guest on 15 June 2024