

Tissue Engineering in Endodontics: Root Canal Revascularization

Palit M C*/ Hegde K S**/ Bhat S S***/ Sargod S S****/ Mantha S *****/ Chattopadhyay S*****

Root canal revascularization attempts to make necrotic tooth alive by the use of certain simple clinical protocols. Earlier apexification was the treatment of choice for treating and preserving immature permanent teeth that have lost pulp vitality. This procedure promoted the formation of apical barrier to seal the root canal of immature teeth and nonvital filling materials contained within root canal space. However with the success of root canal revascularization to regenerate the pulp dentin complex of necrotic immature tooth has made us to rethink if apexification is at the beginning of its end. The objective of this review is to discuss the new concepts of tissue engineering in endodontics and the clinical steps of root canal revascularization.

Key words: Apexification, Apexogenesis, Ca(OH)₂, MTA, Revascularization, Stem cells, Tissue engineering.

INTRODUCTION

Regenerative endodontics is a treatment revolution in dentistry - the era in which root canal therapy brings diseased teeth back to life, rather than leaving a “non-vital” or dead tooth in the mouth.

The literal meaning of regeneration is forming again (especially with improvements or removal of defects); renewing and reconstructing. In endodontics regeneration is the creation and delivery of tissues to replace diseased, missing, or traumatized pulp tissue. Hence it is a biologically based endodontic procedure designed to restore a functional pulp-dentin complex.

* Madhu Chanda Palit, BDS, MDS, Assistant Professor, Dept. of Pedodontics and Preventive Dentistry, Awadh Dental College and Hospital, Jamshedpur, Jharkhand, India.

**Sundeep Hegde K, Professor, Dept. Of Pedodontics and Preventive Dentistry, Yenepoya Dental College and Research Centre, Mangalore, Karnataka, India.

***Sham S Bhat, Vice Principal, Professor and Head, Dept. Of Pedodontics and Preventive Dentistry, Yenepoya Dental College and Research Centre, Mangalore, Karnataka, India.

****Sharan S Sargod, BDS, MDS, Professor, Dept. Of Pedodontics and Preventive Dentistry, Yenepoya Dental College and Research Centre, Mangalore, Karnataka, India.

***** Somasundar Mantha, BDS, MDS, Assistant Professor, Dept. of Pedodontics and Preventive Dentistry, Chhattishgarh Dental College and Research Institute, Rajnanadgaon, Chhattishgarh, India.

***** Sayan Chattopadhyay, BDS, MDS, Assistant Professor, Dept. of Oral Medicine and Radiology, Awadh Dental College and Hospital, Jamshedpur, Jharkhand, India.

Send all correspondence to: Dr. Madhu Chanda Palit Awadh Dental College and Hospital, NH-33, Danga, PO-Bhilaipahari, Jamshedpur, Jharkhand, India: 831012

Phone: 07677643989

E-mail: drmadhupalit85@gmail.com

Since ages the inflamed painful dental pulp containing nerves and blood vessels is removed by dentists and root canal system is obturated with *synthetic materials*, mainly gutta percha preventing any of the advantages that might be provided by regeneration of a functional pulp-dentin complex. Also when treating the necrotic but immature permanent tooth, the conventional treatments often leads to resolution of apical periodontitis, but the tooth remains susceptible to fracture as a result of interruption of apical and dentinal wall development. Thus, one alternative approach would be to develop and validate a biologic restorative procedure where the pulp dentin complex is regenerated to restore the vitality of the tooth without the use of synthetic materials i.e. the development and delivery of tissues to replace diseased or damaged dental pulp which has the potential to provide a revolutionary alternative to pulp removal.

Tissue engineering in endodontics

The concept of tissue engineering was conceived by Langer and Vacanti in the early 1990s to describe the technique for biological tissue regeneration¹. Tissue engineering refers to the science of generating new living tissues to replace, repair or augment the diseased/damaged tissue and restore tissue/organ function². It is a multidisciplinary field.

The objectives of tissue engineering procedures in endodontic are to regenerate pulplike tissue, ideally the pulp-dentin complex; regenerate damaged coronal dentin, such as following a carious exposure; and regenerate resorbed root, cervical or apical dentin. Hence, the tissue of interest in regenerative endodontics includes dentin, pulp, cementum and periodontal tissue³.

Key elements of tissue engineering⁴

1. Adult stem cells which are capable of self replication and differentiation into specialized cells and also has ability to respond to morphogens by dividing or specializing.
2. Morphogens/Growth factors which are biological agents

that regulate stem cells to form the desirable cell type. There are five major families BMPs, FGFs, Wnts, Hhs and TNFs, among which BMPs are mainly related to tooth regeneration.

3. Scaffolds which provide a biocompatible three dimensional structures for cell adhesion and migration. Scaffolds are either biological (e.g. collagen, glycosaminoglycan) or artificial (e.g. PLA, PGA, PLGA)

Techniques of tissue engineering in endodontics

a) Root canal revascularization via blood clotting b) postnatal stem cell therapy c) pulp implantation d) scaffold implantation e) injectable scaffold delivery f) three dimensional cell printing and g) gene therapy. These techniques are based on the basic tissue engineering principles and include specific consideration of stem cells, growth factors and scaffolds.

a) Root canal revascularization via blood clotting

This technique makes the use of intracanal irrigants sodium hypochlorite, chlorhexidine with placement of antibiotics (a mixture of ciprofloxacin, metronidazole, and minocycline paste) for several weeks. This particular combination of antibiotics effectively disinfects root canal system and increases revascularization of avulsed and necrotic tooth^{5,6}.

Tetracyclin enhances growth of host cells on dentin, not by an antimicrobial action but via exposure of embedded collagen fibers or growth factors. It has been noted that reimplantation of avulsed tooth with an apical opening of 1.1 mm evidences greater likelihood of revascularization⁷. This approach is being most commonly used as its technically simple and can be completed using currently available instruments and medicaments without expensive biotechnology. Hence it is also cost effective. Also the regeneration of tissue in root canal systems occurs by a patient's own blood cells avoids the possibility of immune rejection and pathogen transmission from replacing the pulp with a tissue engineered construct. However there is potential risk of necrosis if the tissue becomes infected during or inbetween the procedure. Despite the simple technique of revascularization several concerns need to be still addressed. The case reports of a blood clot having the capacity to regenerate pulp tissue are exciting, but caution is required, because the source of the regenerated tissue has not been identified. The concentration and composition of regenerated cells are also not known. Hence it is very possible that variations in cell concentration and composition, particularly in older patients (where circulating stem cell concentrations may be lower) may lead to variations in treatment outcome. Enlargement of the apical foramen is also necessary to promote vascularization and to maintain initial cell viability via nutrient diffusion in older patients. Hence a universally acceptable guideline should be prepared to make this procedure more clinically acceptable and efficient.

b) Post natal stem cell therapy

The simplest method to administer cells of appropriate regenerative potential is to inject post natal stem cell into disinfected root canal system after apex is opened. Post natal stem cell can be derived from multiple tissues, including skin, buccal mucosa, fat, bone and pulp⁸. This approach is quick, easy to deliver, least painful and the cells easy to harvest. However there is also high

risk of complication and low survival of stem cells. Whether the postnatal stem cells are producing new functioning pulp is still not clearly known hence requiring further research.

c) Pulp implantation

In pulp implantation, replacement pulp tissue is transplanted into cleaned and shaped root canal system. The source of pulp tissue may be a purified stem cell line that is disease or pathogen free or created from cells taken from biopsy that has been grown in laboratory. The cultured pulp tissue is grown in sheets in vitro on bio degradable polymer nano fibers or on sheet of extracellular matrix protein such as collagen I or fibronectin⁹. These cultured pulp tissue in sheets will be required to be rolled together to form a three dimensional pulp tissue, which can be implanted into disinfected root canal systems. These sheets are easy to grow and more stable than an injection of dissociated cells. However it is not much feasible as specialized procedures may be required to ensure that the cells properly adhere and fit to root canal walls. Sheets of cells also lack vascularity, so only the apical portion of the canal systems would receive these cellular constructs¹⁰. Then the coronal canal systems must be filled with scaffolds capable of supporting cellular proliferation. Hence much precision is needed for this technique. Also because the filters are very thin layers of cells, they are extremely fragile, and this could make them difficult to place in root canal systems without breakage. Hence reliable pulp implantation techniques must be developed before this procedure comes to clinical use.

d) Scaffold implantation

To create a more practical endodontic tissue engineering therapy, pulp stem cells must be organized into a three dimensional structure that can support cell organization and vascularization. This can be accomplished using a porous polymer scaffold seeded with pulp stem cells¹¹. A scaffold contains growth factors to aid stem cell proliferation and differentiation, leading to improved and faster tissue development¹². The scaffold may also contain nutrients promoting cell survival and growth and possibly antimicrobials to prevent any bacterial growth in canal system. In addition scaffold may exert essential mechanical and biological functions needed by replacement tissues¹³.

However to achieve pulp tissue regeneration, the scaffold must be resorbable by the surrounding tissue so that it need not be removed by another surgery¹⁴. It should also have high porosity with adequate pore size such that the cell and nutrients are easily diffused throughout the scaffold¹⁵. The rate of degradation should also match the rate of tissue formation. Most of the scaffolds in tissue engineering used in medicine are as bioresorbable sutures and as meshes used in wound dressings¹⁶. The type of scaffold materials is available as natural or synthetic, biodegradable or permanent. The synthetic materials include polylactic acid (PLA), polyglycolic acid and polycaprolactone¹⁷. Natural materials used are collagen or fibrin, chitosan and glycosaminoglycans¹⁸. However early results are promising, immune rejection should always be considered before using this technique. Advantages of this technique are the scaffold structure supports cell organization and some materials may promote vascularisation as well. However they do have a low survival rate after implantation and must be engineered precisely to fit in root canal space.

e) Injectable scaffold delivery

Rigid tissue engineered scaffold provide excellent support for cells used in bone and other body areas where engineered tissue is required to provide physical support¹⁹. However in root canal system a tissue engineered pulp is not required to provide structural support of the tooth. This will allow tissue engineered pulp tissue to be administered in a soft three dimensional scaffold matrix such as hydrogel. Hydrogel are injectable scaffold that can be delivered by syringe²⁰. Hydrogel have the potential to be non-invasive and easy to deliver into root canal system. It promotes pulp regeneration by providing a substrate for cell proliferation and differentiation into an organized tissue structure²¹. To make hydrogel more practical research is focusing on making them photopolymerisable to form rigid structures once they are implanted into the tissue site²². Advantages of this technique are easily delivered and promotes regeneration by providing substitute for extracellular matrix. However there is a limited control over tissue formation with a low cell survival and at early stage. Research has yet to prove functional importance in vivo.

f) Three dimensional cell printing

The final approach for creating replacement pulp tissue might be to create it using three this technique. Ink jet device is used theoretically to dispense layers of cell suspended in a hydrogel which recreates the structure of tooth pulp tissue.

The pulp tissue construct formed by this is technique resembles the natural tooth pulp maximum. The ideal positioning of cells will be when odontoblastoid cells are places around the periphery to maintain and repair dentin, with fibroblasts in the pulp core supporting a network of vascular and nerve cells. The three dimensional cell printing technique can be used to precisely position cells²³. Advantages are multiple cell types can be precisely positioned. Disadvantages are they must be engineered to fit root canal precisely; coronal and radicular asymmetry in the orientation of natural pulp tissue must be maintained. Early stage research has yet to prove the functional importance in vivo and the low cell survival is also a major drawback.

g) Gene therapy

This technique involves viral and non viral vectors to deliver genes for growth factors, morphogens, transcription factors, and ECM (extra cellular matrix) into target cells populations. Viral vectors are modified including retrovirus, adenovirus, adeno associated virus, herpes simplex virus and lentivirus²⁴. Non viral gene delivery systems include plasmids, peptides gene guns, DNA ligand complex, electroporation, sonoporation and cationic liposomes²⁵. The choice of gene delivery system depends on accessibility and physiological characteristics of target cell population. One use of gene delivery in endodontics would be to deliver mineralizing genes into pulp tissue to promote tissue mineralization. However there has been little or no research in this field and also not approved by FDA. This technique avoids the need of cleaning and shaping of root canal system, and the need to implant stem cells. However, it has a potential risk of health hazard.

Protocol for regenerative endodontic treatment (RET) via blood clotting

As revascularization is most widely used simple clinical

techniques of tissue engineering in endodontics we are describing its clinical steps. Revascularization should include appropriate case selection, with a strict disinfection protocol and use of antimicrobial paste to achieve complete asepsis and blood clot formation in canal space followed by placement of an MTA barrier, or equivalent over blood clot with a final restoration and follow-up at regular intervals.

i) Case selection

Currently there is no evidence-based guideline to help clinicians determine which condition of cases can be treated with this conservative approach. The presence of radiolucency at the periradicular region can no longer be used as a determining factor, nor is the vitality test as in both situation, vital pulp tissue or apical papilla may still present in the canal and at the apex. Logically, any remnant of visible soft tissue that can be visualized under the dental microscope should give the clinician an incentive to take the conservative approach, even though the soft tissue may be purely granulation tissues. However, one can also not rule out the possibility that there are not any remaining pulp tissues in the very apical part of the canal only because it cannot be detected clinically²⁶.

Although case reports on revascularization are largely from teeth with incomplete apical closures, it has also been noted that reimplantation of avulsed teeth with an apical opening of approximately 1.1 mm demonstrate a greater likelihood of revascularization²⁷. This is mainly because in enlarged apical foramen there is a high chance of survival of remaining vital pulp in the canal since open apex provides a good communication from pulp space to the periapical tissues, therefore it may be possible for periapical disease to occur while the pulp is only partially necrotic and infected. It is necessary to promote vascularization and maintain initial cell viability via nutrient diffusion and oxygen supply. This finding suggests that revascularization of necrotic pulps with fully formed (closed) apices might require instrumentation of the tooth apex to approximately 1 to 2mm in apical diameter to allow systemic bleeding into root canal systems²⁷.

Another obvious consideration is the duration of the infection. The longer the duration of infection lesser will be the no. of survived remaining pulp tissue and stem cells. Additionally, the longer the infection there is in the canal, the more likelihood of a deeper penetration of microbial colonies into dentinal tubules. This renders the disinfection more difficult to accomplish²⁶. The technique also shows maximum positive outcome in young adults as younger adult patients generally have a greater capacity for healing.

Since there is a lack of clinical studies on the success rate of treating immature teeth with periradicular bone resorption, the conservative approach should considered first. Apexification is only undertaken when the attempt is failed²⁶. If no signs of regeneration are present after three months, then more traditional treatment methods can be initiated²⁸. Finally patient compliant and informed consent need to be taken before starting the procedure, as the outcome of the procedure is not definite until now.

ii) Disinfection protocol

The management of immature teeth by revascularization should have minimal or no instrumentation, irrigation with sodium hypochlorite, hydrogen peroxide and/or Peridex; and intra-canal medication with antimicrobial agents consisting of equal parts of metronidazol, minocycline and ciprofloxacin in a paste form. A successful vital pulp treatment requires a good sealant against bacteria, no

severe inflammatory reactions, and stable haemodynamic within the pulp. Use of intracanal irrigants (NaOCl and chlorhexidine) with placement of antibiotics (e.g. a mixture of ciprofloxacin, metronidazole, and minocycline paste) for several weeks as a means of disinfection of the canal is a very important step to achieve revascularization. NaOCl has been used between 2.5–5.25% concentrations. 3% hydrogen peroxide and/or Peridex(chlorhexidine gluconate rinse) has also been used²⁶. One study has also used 10% Povidine iodine²⁹.

Calcium hydroxide is not recommended as intra-canal medicament

1. To prevent damage of the remaining pulp tissue, apical papilla and HERS(Heartwig's epithelial root sheath). Ca(OH)₂ may damage and thereby destroy the ability to induce the nearby undifferentiated cells to become odontoblasts³⁰.
2. Direct contact of Ca(OH)₂ paste with the tissue which will induce the formation of a layer of calcific tissue which may occlude the pulp space, therefore preventing pulp tissue from regeneration³¹.

The gentle treatment regimen is an attempt to conserve any viable tissues that may be remained in the canal system which harbor stem cells, i.e., SCAP in the apical papilla and DPSCs (dental pulp stem cells) in the pulp. Avoidance of trauma to the tissue around the apex is advised. After proper disinfection, the remnants of the survived HERS at the apices of immature teeth may organize the apical mesodermal tissue into root components.

In the first appointment continuous irrigation with NaOCl should be carried out for 30 min at every 5 minutes. This continuous procedure completely disinfects the root canal, as the survival of microorganisms or its toxins will prevent the revascularization procedure. In the next appointment, after 1 week irrigation of the canal is again carried out for 15 min. If vital tissue is present in the canal the concentration of NaOCl used is 5.25% and if it is not present and revascularization is carries by blood clot, then the concentration used by most authors is 1.25-2.5%^{29,31,32}.

Revascularization procedure has also been carried out only with the copious irrigation of the canal without instrumentation^{31,33}. The noninstrumentation procedure using 6% NaOCl and 2% chlorhexidine coronal irrigation has shown to preserve the remaining vital dental pulp stem cells in single step revascularization procedure. Hence it is believed to be critical for pulp revascularization³³. However Rossi-Fedele et al have showed that formation of precipitate when CHX and NaOCl are mixed leading to discoloration and other side effects³⁴. Combination of 17% EDTA with 6% NaOCl is safe till now and has shown to be effective for regeneration of pulpal stem cells³⁵. Ethylenediaminetetraacetic acid (EDTA) very effectively releases growth factors from human dentin as well as help in the survival of stem cells of apical papilla^{36,37}.

iii) The use of antimicrobial paste

As calcium hydroxide has its own disadvantages in revascularization process, combination of antibiotic paste has been used as an intracanal medicament. By using the antibiotic paste, the pulp tissue is able to fill in the remaining canal space. There is a particular combination of antibiotics which effectively disinfects root canal systems and increases revascularization of avulsed and necrotic teeth. This combination includes metronidazol, minocycline and ciprofloxacin,

which is known as triple antibiotic paste. The triple-antibiotics regimen was first tested by Sato et al. to be effective against the Escherichia coli infected dentin in vitro⁵. The same research group also tested their bactericidal efficacy against microbes from carious dentin and infected pulp. They found that the mixture of antibiotics is sufficiently potent to eradicate the bacteria⁶.

The application of antibacterial drugs may represent one method of eradicating bacteria in root canal treatment. This concept is also known as **Lesion Sterilization and Tissue Repair (LSTR) therapy**.

This technique has been developed by Cariology Research Unit of Nigata University School of Dentistry, Japan³⁸. Composition and mixing instructions for the tri-antibiotic paste is adapted from Hashino et al.⁶ Antibiotics (3M mix-MP) combines Ciprofloxacin 200mg, Metronidazole 500mg, Minocyclin 100mg and a carrier (MP): Macrogol ointment or Propylene glycol is used. The combination of drugs has been shown to penetrate efficiently through dentine from prepared root canals, suggesting that topical application of the drug combination may be potent in sterilizing lesions in root canal treatment⁶.

Disadvantages of using antimicrobial paste

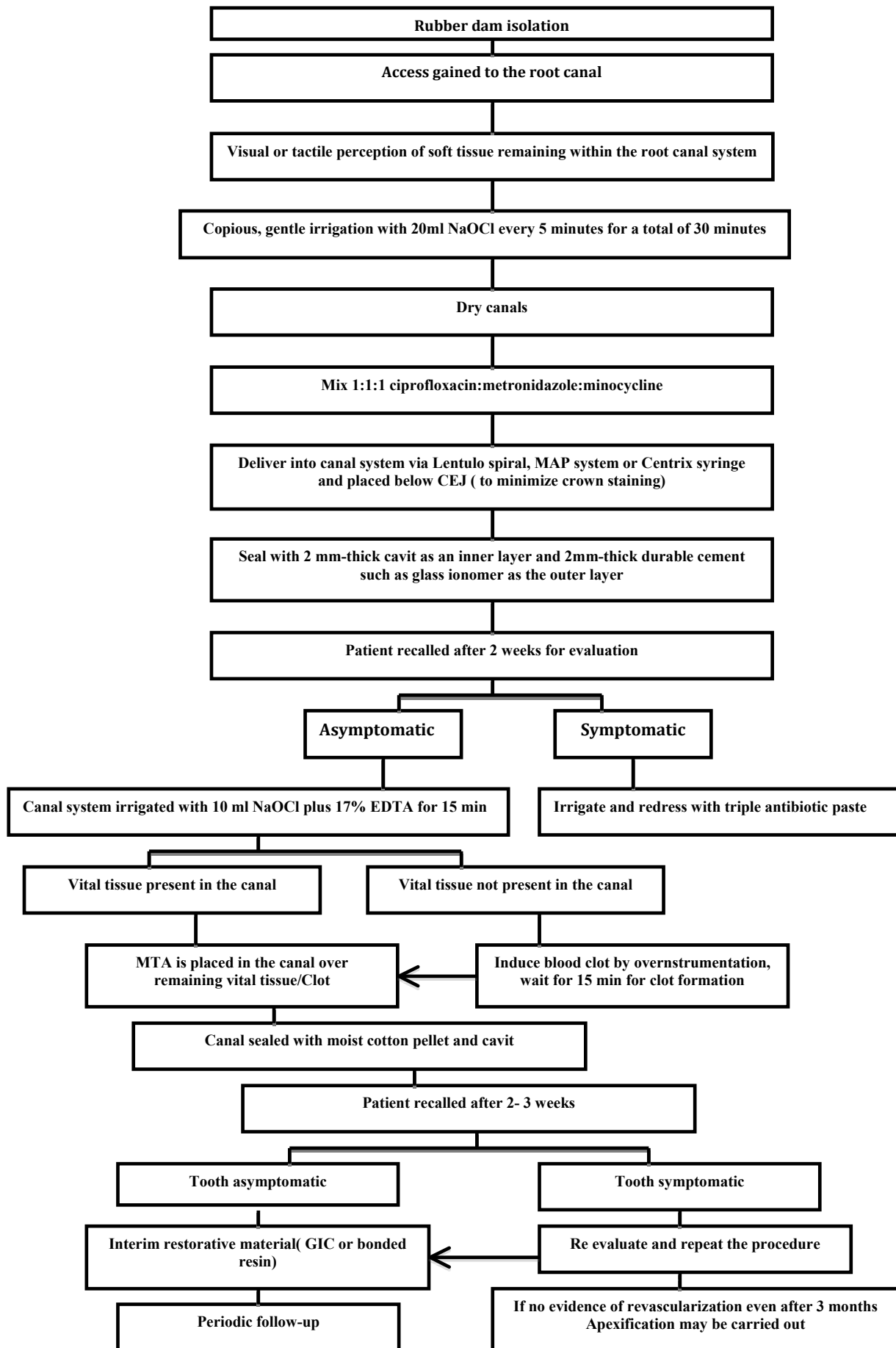
The concern of the antibiotic paste is that it may cause bacterial resistance. Also, the paste contains both bactericidal (metronidazol and ciprofloxacin) and bacteriostatic (minocycline) antibiotics²⁶. Additionally, minocycline may cause tooth discoloration. A case report has shown dark discoloration of anterior tooth after use of triple antibiotic paste³⁹. However the use of dentin banding agent reduces the intensity of discoloration, but it does not eliminate the problem. Hence the possible esthetic problems with the tooth colour should be considered when using minocycline as a canal medication. Also the effect of minocycline in inducing growth factor and exposure of embedded collagen has to be further verified.

iv) Blood clot formation in canal space

Revascularization can be carried out with or without the formation of blood clot. As until now no guideline has been proposed for revascularization, it is completely on the clinician to decide whether the canal should be instrumented for inducing blood clot or not depending on the visual or tactile perception of soft tissue remaining within the root canal system. Lack of responsiveness to cold or electric testing is not considered to be indication of loss of vitality, as most of the revascularization procedures are carried out in immature tooth with open apex. Despite the preoperative irresponsiveness of vitality testing of the tooth, if some vitality is noted during treatment either by sensitivity to instrumentation within the root canal system or by the visual or tactile perception of soft tissue remaining within the root canal system then blood clot is not induced within the canal space, as the remaining vital pulp supplies the stem cells and growth factor responsible for revascularization³².

However if there is lack of evidence of residual vital pulp tissue within the root canal system either by tactile or visual perception then treatment is administered with the addition of evoking an intracanal blood clot. Induction of bleeding to facilitate healing is a common surgical procedure. It was first proposed by Ostby in 1961 to induce hemorrhage and form blood clot in the canal space of mature teeth in the hope to guide the tissue repair in the canal⁴⁰. Later in 1974 Myers and Fountain attempted to regenerate dental pulp with blood clot filled in the canal⁴¹. The mechanism of how a

SCHEMATIC REPRESENTATION OF STEPS OF REVASCULARIZATION:



Downloaded from http://jendian.allenpress.com/jcpd/article-pdf/38/4/291/1748183/jcpd_38_4_15285857278615r1.pdf by guest on 24 June 2024

blood clot benefits the root canal revascularization is not entirely clear, although the possible reasons could be that blood clot may act as a natural fibrin scaffold for cell attachment, proliferation, and differentiation to facilitate the regeneration and repair of tissues into the canal³². SCAP cells from the apical papilla may migrate into the root canal and produce dentin-pulp complex-like tissue and delivers abundant growth factors within the blood clot, such as platelet-derived growth factor which will aid in revascularization.

Haemorrhage is induced by over instrumentation with either endodontic files or an endodontic explorer penetrating slightly into the remaining pulp tissue or periapical tissue. This procedure induces bleeding into the canal and the bleeding is left for 15 minutes so that the blood would clot in the canal and stopped at a level 3mm below CEJ. MTA is then placed over the blood clot³².

At this point, it is unsure of which factors in the blood clot are important. When these factors are isolated, they can be incorporated into a synthetic scaffold that will be easier to for clinicians to manipulate compared with a blood clot²⁸. However platelet rich plasma has been tried as an successful clinical alternative. Ding et al. discussed the value of use of PRP in whom it is difficult to produce bleeding in the canal with a file⁴². A recent case report has suggested the possibility of PRP as a potentially ideal scaffold for pulp revitalization in tooth with necrotic pulp and a periapical lesion⁴³.

Currently, there is lack of histological evidence showing that blood clot is required for the formation of repaired tissues in the canal space, nor are there systematic clinical studies to show that this approach is significantly better than without it²⁶. One study using a dog model showed no statistical significance of healing by inducing blood clot into the canal, although the authors of the study suggested the inclusion of blood clot to improve the chance of healing⁴⁴.

v) MTA barrier, or equivalent, placed over blood clot, Final restoration and follow-up

Once the intracanal infection is controlled and a physical scaffold to promote cell growth and differentiation has been achieved, next important step is coronal seal to prevent reinfection⁴³. In revascularization after inducing blood clot, MTA is placed over the clot. If revascularization is carried out without the use of blood clot then after drying the canal with paper point, MTA is placed carefully over the tissues in the root canal. A small piece of collacote may be placed at the pulp chamber to support the MTA cement which is to be placed over it. This is followed by the placement of a wet cotton pellet and temporary filling material. Patient is then recalled after 2- 3 weeks and if the tooth is asymptomatic then the temporary filling material and the cotton pellet is replaced with a bonded resin restoration or glss ionomer cement³². Some authors suggest the direct placement of resin restoration after the MTA is set²⁹. The use of MTA is for its excellent microleakage-proof property and biocompatibility. Additional placement with glass ionomer/resin provides a double seal, further securing the sealing ability and the integrity of the filled access.

The tooth should be followed up periodically to observe the maturation of the root. If after several rounds of intra-canal irrigation and medication the clinical symptoms show no sign of improvement, i.e., persistent presence of sinus tract, swelling and/or pain, apexification procedure should then be carried out. If no signs of regeneration are present after 3 months, then more traditional treatment methods can be initiated²⁸.

CONCLUSION

Hence due to the emergence of regenerative endodontics concept, clinicians should re-evaluate current clinical protocols when treatment planning of certain clinical cases. This is especially important in dealing with immature teeth, as they are still at the growing phase and likely to carry potent stem cells that enables the tissue to regenerate and repair better than matured tissues. Therefore, a clinical protocol that favours the reservation and conservation of the harboured stem cells in the tissue should be considered, i.e., conservation of stem cells to allow endodontic tissue self-regeneration in disinfected immature permanent teeth.

Several technologies have been developed for delivering regeneration of pulp dentin complex e.g. root canal revascularization via blood clot, postnatal stem cell therapy, pulp implantation, scaffold implantation, injectable scaffold delivery, gene therapy and three dimensional cell printing. Most recently interesting animal experiments have been reported in which a gel of collagen and biologically active chemicals was applied in the root canal. But probably the most interesting experiments in this regard, however are the attempt to induce ingrowth of new connective tissue into the root canal by means of a blood clot.

REFERENCES

1. Langer R, Vacanti JP. Tissue engineering. *Science*; 260 (5110): 920–6. 1993.
2. A. Curtis, M. Riehle. Tissue engineering: the biophysical background. *Phys Med Biol*;46(4):47-65. 2001.
3. Huang GT. A paradigm shift in endodontic management of immature teeth: conservation of stem cells for regeneration. *J Dent* ;36(6):379-86. 2008.
4. Role of morphogenetic proteins in skeletal tissue engineering and regeneration. *Nat Biotechnol* ;16:247-52. 1998.
5. Sato I, Ando-Kurihara N, Kota K, Iwaku M, Hoshino E. Sterilization of infected root-canal dentine by topical application of a mixture of ciprofloxacin, metronidazole and minocycline in situ. *Int Endod J* ;29:118–24. 1996.
6. Hoshino E, Kurihara-Ando N, Sato I, et al. In-vitro antibacterial susceptibility of bacteria taken from infected root dentine to a mixture of ciprofloxacin, metronidazole and minocycline. *Int Endod J* ;29:125–30. 1996.
7. Kling M, Cvek M, Mejare I. Rate and predictability of pulp revascularization in therapeutically reimplanted permanent incisors. *Endod Dent Traumatol* ;2:83–9. 1986.
8. Kindler V. Postnatal stem cell survival: does the niche, a rare harbor where to resist the ebb tide of differentiation, also provide lineage-specific instructions? *J Leukoc Biol* ;78:836–44. 2005.
9. Venugopal J, Ramakrishna S. Applications of polymer nanofibers in biomedicine and biotechnology. *Appl Biochem Biotechnol* ;125:147–58. 2005.
10. Peter SJ, Miller MJ, Yasko AW, Yaszemski MJ, Mikos AG. Polymer concepts in tissue engineering. *J Biomed Mater Res* ;43:422–7. 1998.
11. Nakashima M. Tissue engineering in endodontics. *Aust Endod J* ;31:111–3. 2005.
12. Oringer RJ Biological mediators for periodontal and bone regeneration. *Compend Contin Educ Den* ;23:501–4. 2002.
13. Boccaccini AR, Blaker JJ. Bioactive composite materials for tissue engineering scaffolds. *Expert Rev Med Devices* ;2:303–17. 2005.
14. Schopper C, Ziya-Ghazvini F, Goriwoda W, et al. HA/TCP compounding of a porous CaP biomaterial improves bone formation and scaffold degradation: a long-term histological study. *J Biomed Mater Res B Appl Biomater* ;74:458–67. 2005.
15. Sachlos E, Czernuszka JT. Making tissue engineering scaffolds work. Review: the application of solid freeform fabrication technology to the production of tissue engineering scaffolds. *Eur Cell Mater* ;30:29–39. 2003.
16. Athanasiou KA, Niederauer GG, Agrawal CM. Sterilization, toxicity, biocompatibility and clinical applications of polylactic acid/polyglycolic acid copolymers. *Biomaterials* ;17:93–102. 1996.
17. Taylor MS, Daniels AU, Andriano KP, Heller J. Six bioabsorbable polymers: in vitro acute toxicity of accumulated degradation products. *J Appl Biomater* ;5:151–7. 1994.
18. Griffon DJ, Sedighi MR, Sendemir-Urkmez A, Stewart AA, Jamison R. Evaluation of vacuum and dynamic cell seeding of polyglycolic acid and chitosan scaffolds for cartilage engineering. *Am J Vet Res* ;66:599–605. 2005.
19. Elisseeff J, Puleo C, Yang F, Sharma B. Advances in skeletal tissue engineering with hydrogels. *Orthod Craniofac Res* ;8:150–61. 2005.
20. Trojani C, Weiss P, Michiels JF, et al. Three-dimensional culture and differentiation of human osteogenic cells in an injectable hydroxypropylmethylcellulose hydrogel. *Biomaterials* ;26:5509–17. 2005.
21. Alhadlaq A, Mao JJ. Tissue-engineered osteochondral constructs in the shape of an articular condyle. *J Bone Joint Surg Am* ;87:936–44. 2005.
22. Luo Y, Shoichet MS. A photolabile hydrogel for guided three-dimensional cell growth and migration. *Nat Mater* ;3:249–53. 2004.
23. Barron JA, Krizman DB, Ringeisen BR. Laser printing of single cells: statistical analysis, cell viability, and stress. *Ann Biomed Engl* ;33:121–30. 2005.
24. Heller LC, Ugen K, Heller R. Electroporation for targeted gene transfer. *Expert Opin Drug Deliv* ;2:255–68. 2005.
25. Nakashima M, Reddi AH. The application of bone morphogenetic proteins to dental tissue engineering. *Nat Biotechnol* ;21:1025–32. 2003.
26. Huang GT. A paradigm shift in endodontic management of immature teeth: Conservation of stem cells for regeneration. *J Dent* ;36(6):379-86. 2008.
27. Kling M, Cvek M, Mejare I. Rate and predictability of pulp revascularization in therapeutically reimplanted permanent incisors. *Endod Dent Traumatol* ;2(3):83–9. 1986.
28. Trope M. Regenerative Potential of Dental Pulp. *Pediatr Dent* ;30(3):206-10. 2008.
29. Thibodeau B. Case report: pulp revascularization of a necrotic, infected, immature, permanent tooth. *Pediatr Dent* ;31(2):145-8. 2009.
30. Banchs F, Trope M. Revascularization of immature permanent teeth with apical periodontitis: new treatment protocol? *J Endod* ;30(4):196-200. 2004.
31. Chueh LH, Huang GT. Immature teeth with periradicular periodontitis or abscess undergoing apexogenesis: a paradigm shift. *J Endod* ;32(12):1205-13. 2006.
32. Jung IY, Lee SJ, Hargreaves KM. Biologically based treatment of immature permanent teeth with pulpal necrosis: a case series. *J Endod* ;34(7):876-87. 2008.
33. Shin SY, Albert JS, Mortman RE. One step pulp revascularization treatment of an immature permanent tooth with chronic apical abscess: a case report. *Int Endod J* ;42(12):1118-26. 2009.
34. Rossi-Fedele G, Doğramaci EJ, Guastalli AR, Steier L, de Figueiredo JA. Antagonistic interactions between sodium hypochlorite, chlorhexidine, EDTA, and citric acid. *J Endod* ;38(4):426-31. 2012.
35. Trevino EG, Patwardhan AN, Henry MA, Perry G, Dybdal-Hargreaves N, Hargreaves KM, Diogenes A. Effect of irrigants on the survival of human stem cells of the apical papilla in a platelet-rich plasma scaffold in human root tips. *J Endod* ;37(8):1109-15. 2011.
36. Hargreaves KM, Giesler T, Henry M, Wang Y. Regenerative potential of the young permanent tooth: what does the future hold? *J Endod* ;34(7 Suppl):S51-6. 2008.
37. Galler KM, D'Souza RN, Federlin M, Cavender AC, Hartgerink JD, Hecker S, Schmalz G. Dentin conditioning codetermines cell fate in regenerative endodontics. *J Endod* ;37(11):1536-41. 2011.
38. Takushige T, Cruz EV, Asgor Moral A, Hoshino E. Endodontic treatment of primary teeth using a combination of antibacterial drugs. *Int Endod J* ;37(2):132-8. 2004.
39. Kim JH, Kim Y, Shin SJ, Park JW, Jung IY. Tooth discoloration of immature permanent incisor associated with triple antibiotic therapy: a case report. *J Endod* ;36(6):1086-91. 2010.
40. Ostby BN. The role of the blood clot in endodontic therapy. An experimental histologic study. *Acta Odontol Scand* ;19:324–53. 1961.
41. Myers WC, Fountain SB. Dental pulp regeneration aided by blood and blood substitutes after experimentally induced periapical infection. *Oral Surg Oral Med Oral Pathol* ;37(3):441–50. 1974.
42. Ding RY, Cheung GS, Chen J, Yin XZ, Wang QQ, Zhang CF. Pulp revascularization of immature teeth with apical periodontitis: a clinical study. *J Endod* ;35(5):745-9. 2009.
43. Torabinejad M, Turman M. Revitalization of tooth with necrotic pulp and open apex by using platelet-rich plasma: a case report. *J Endod* ;37(2):265-8. 2011.
44. Thibodeau B, Teixeira F, Yamauchi M, Caplan DJ, Trope M. Pulp revascularization of immature dog teeth with apical periodontitis. *J Endod* ;33(6):680–9. 2007.