

Assessment of Skeletal Maturation using Mandibular Second Molar Maturation Stages

Goyal S*/ Goyal S**/ Gugnani N***

Objectives: To investigate the relationship between cervical vertebrae maturation and mandibular second molar calcification stages. **Study design:** The study was designed as a retrospective, descriptive and cross-sectional research project. Pre-treatment lateral cephalograms and panoramic radiographs of 99 males and 110 females in the age range of 7 to 18 years 7 months were evaluated with Demirjian Index (DI) and cervical vertebrae maturation indicators (CVMI) of Hassel and Farman. A null hypothesis was proposed that there is no relation between CVMI and DI. **Results:** A highly significant association (Pearson's contingency coefficient 0.713 for males and 0.863 for females) was found between DI and CVMI. In males, the DI stage E corresponded to stage 2 of CVMI (pre-peak of pubertal growth spurt) and DI stages F and G corresponded to stages 3 and 4 of CVMI (peak of pubertal growth spurt). DI stage H was associated with stages 5 and 6 of CVMI (end of pubertal growth spurt). In females, the DI stages C, D corresponded to CVMI stages 1, 2; DI stages E, F with CVMI stages 3, 4; DI stages G, H with CVMI stages 5, 6.

Conclusion: Mandibular second molar calcification stages can be used as indicators for assessment of skeletal maturity.

Key words: Skeletal maturation, Cervical vertebrae maturation indicators, Demirjian Index, Mandibular second molar.

INTRODUCTION

Knowledge of the maturation status and the ensuing cranio-facial growth of a patient is of utmost importance for a clinician. These factors influence the interdisciplinary clinical decisions, treatment plan, and eventual outcomes of the dentofacial orthopaedic, prosthetic, and orthognathic surgical treatment.^{1,2} A timely analysis of the patient's growth potential helps the pedodontists and orthodontists take advantage of active growth and achieve more skeletal changes in dentofacial structures. The adolescent growth spurt is a period of sudden increase in growth when the

maximum skeletal changes are seen in the body and the face and, thus, any dentofacial orthopaedic intervention during that period helps to achieve more skeletal effects and stable treatment results.^{3,4}

Determination of biologic age is the most reliable method for the assessment of skeletal maturation.⁵ Hand-wrist x-rays have been used for many decades to study ossification-related events as the skeletal maturity indicators.⁶⁻⁹ Hassel and Farman proposed cervical vertebrae maturation indicators (CVMI) observed on the lateral cephalograms to assess the skeletal maturity levels and correlated it with Fishman's skeletal maturity indicators (SMI) as assessed on hand-wrist x-rays.⁵ Further studies confirmed that the CVMI stages are consistently correlated with skeletal maturity indicators in the hand. CVMI is, thus, considered a reliable indicator for assessment of skeletal maturity of an individual.¹⁰⁻¹⁵

Dental calcification stages have also been suggested to assess the skeletal maturity level of an individual. Morris and Park concluded that there is a strong relation between dental maturity and skeletal maturity as assessed from the radiographs. The study indicated that dental maturation can be used as an initial estimator and an adjunct in evaluating the skeletal growth status of the individuals.² Examination of the dental calcification stages is the quickest and most accessible method to assess the skeletal maturity. It can be done using the routine radiographs e.g. intra-oral periapical view (IOPA) for the initial estimation of skeletal growth.² Studies have found that assessment of mandibular second molars calcification stages can be

*Sandeep Goyal, BDS, MDS, PGDBA, Senior Consultant Orthodontist King Faisal Hospital and Research Centre, Rwanda Biomedical Centre Kigali, Rwanda.

**Sonia Goyal, BDS, MDS, Consultant Stomatologist, Polyclinique LaMedicale, Kigali.

***Neeraj Gugnani, BDS, MDS, Professor, Dept of Pedodontics, DAV Dental College, Yamunanagar, Haryana, India.

Send all correspondence to

Sandeep Goyal
King Faisal Hospital and Research Centre, Rwanda Biomedical Centre
Kigali, Rwanda.

Phone: +250783012622

E-mail: goyalsandeep2000@rediffmail.com

used as predictors of skeletal maturation.^{1,16,17} It can be performed on an IOPA or panoramic radiograph (OPG), which will avoid additional radiation exposure to obtain hand - wrist radiograph.

The lateral cephalograms and OPGs are routine pre-treatment diagnostic radiographs taken for orthodontic treatment and can be used to assess the skeletal maturation levels.⁵ Limited published evidence is available on the correlation of mandibular second molar calcification stages and skeletal maturity. This study was carried out to evaluate the mandibular second molar calcification stages as predictors of skeletal maturity.

The objective of this study was to investigate the relationships between the cervical vertebra maturation and the mandibular second molar calcification stages. A null hypothesis was proposed that there is no significant relationship between cervical vertebrae maturation and mandibular second molar calcification stages.

MATERIALS AND METHOD

This study was designed as a retrospective, descriptive, and cross-sectional research project.

Traditional films of pre-treatment OPGs and lateral cephalograms of 209 subjects (99 male and 110 female) of Rwanda origin were randomly selected from the records of orthodontic patients at King Faisal Hospital, Rwanda Biomedical Centre, affiliate of National University of Rwanda, Rwanda. Only one set of the radiographs of each subject were selected for this study. The serial radiographs of the same subject were not included in this study.

The subjects within the age range of 7 to 19 years were selected in this study, because most of the patients seeking orthodontic treatment belong to this age group, and are at different stages of skeletal maturity. Subjects having normal overall growth and development and absence of previous orthodontic treatment were considered for the study. Any subject having abnormal dental conditions such as impaction, transposition, and congenitally missing teeth, and previous history of trauma were not selected. Subjects with any gross skeletal deformities e.g. clefts, hemiatrophy, hypertrophy and gross facial asymmetry were also not included in the study.

Radiographic assessments were performed on a back-illuminated radiographic view box in a darkened room by a single examiner.

Evaluation of cervical vertebrae maturity (CVMI) on lateral cephalogram

CVMI was evaluated by using the method proposed by Hassel and Farman (Table 1).⁵

Evaluation of dental maturity (DI) on panoramic radiograph

The mandibular left second molar calcification stages were assessed according to method proposed by Demirjian et al (DI) (Table 2).⁹ If the left side tooth was not clear, then its counterpart on the right side was evaluated.

Randomly selected records of 15 patients were re-evaluated after 2 weeks of first evaluation to test the reproducibility of assessments of DI and CVMI, and data was evaluated in terms of the weighted kappa statistics. The kappa statistics for intra-observer agreement were 0.86 for DI assessments and 0.89 for CVMI assessments, showing acceptable intra-observer agreement.

Statistical analysis

Statistical analyses were performed using SPSS 13.0, SPSS Inc, Chicago, Ill., and Epi Info 3.4.3 (CDC, Illinois). Descriptive statistics were calculated for both genders to determine the sample distribution, the means and the standard deviations of the mean ages for the CVMI stages and the DI stages of mandibular second molars. Cross-tabulation was done to find distribution of DI stages among CVMI stages stratified by the gender. Mann Whitney / Wilcoxon Two-sample test (Kruskal Wallis test for 2 groups), the Pearson chi-square test values (χ^2) and Pearson contingency coefficient were also estimated to determine the relationships between DI and CVMI among the genders. A p-value of < 0.01 was considered as statistically significant.

Table 1: Cervical vertebra maturation indicators (CVMI, Hassel and Farman)⁵

Stage	Stage	Amount of growth expected	Characteristics
1	Initiation	80% - 100%	C2, C3, and C4 inferior vertebral body borders are flat. Vertebrae are wedge-shaped. Superior vertebral borders are tapered posterior to anterior.
2	Acceleration	65% - 85%	Concavities are developing in the inferior borders of C2 and C3. The inferior border of C4 is flat. The bodies of C3 and C4 are nearly rectangular in shape.
3	Transition	25% - 65%	Distinct concavities are seen in the inferior borders of C2 and C3. A concavity is beginning to develop in the inferior border of C4. The bodies of C3 and C4 are rectangular in shape.
4	Deceleration	10% - 25%	Deceleration of adolescent growth spurt. Small amount of adolescent growth expected. Distinct concavities in the inferior borders of C2, C3, and C4. C3 and C4 are nearly square in shape.
5	Maturation	5% - 10%	Final maturation of the vertebrae takes place during this stage. Insignificant amount of adolescent growth expected. Accentuated concavities of inferior vertebral body borders of C2, C3, and C4. C3 and C4 are square in shape.
6	Completion	Little or no growth	Adolescent growth is completed. Deep concavities are seen in inferior border of C2, C3, and C4. C3 and C4 heights are greater than widths.

RESULTS

The study involved records of 47.4% (n=99) males and 52.6% (n=110) females. The age range of the study sample was from 7 years to 18 years 7 months. The mean age of the males was 13.27 years (SD = 2.1 years), of the females was 12.9 years (SD = 2.26 years), and of the total sample was 13.08 years (SD = 2.18 years).

Table 3 shows the percentage distribution and mean ages of all the subjects grouped by CVMI stages and gender. Each stage appeared earlier in the females as compared to the males (Figure 1). Mann Whitney / Wilcoxon Two-sample test (Kruskal Wallis test for 2 groups) showed highly significant differences among various CVMI stages in both the genders. The chi square values were $\chi^2(5) = 81.57, p < 0.001$, and $\chi^2(4) = 59.08, p < 0.001$ for the females and the males respectively.

Table 4 shows the mean ages at different DI stages of mandibular second molar in both the genders. Females achieved subsequent maturation stage of second molar earlier than males (Figure 2). Mann Whitney / Wilcoxon Two-sample test (Kruskal Wallis test for 2 groups) showed significant differences among various DI stages in both the genders. The chi square values were $\chi^2(5) = 77.23, p < 0.001$, and $\chi^2(4) = 56.68, p < 0.001$ for the females and the males respectively.

Table 5 shows the association and distribution between CVMI stages and the DI stages of mandibular second molar in males. The chi square value $\chi^2(16)$ was 72.8 ($p < 0.001$). The Pearson contingency coefficient was 0.713 and showed a significant association between DI and CVMI. In males, the DI Stage E showed the highest distribution at CVMI stage 2 (pre-peak of pubertal growth spurt) and DI stages F and G showed a large distribution in CVMI stages 3 and 4 (peak of pubertal growth spurt). Stages F and G were almost equally distributed in CVMI stage 4. DI stage H was associated with stages 5 and 6 of CVMI (end of pubertal growth spurt).

Table 6 shows the association and distribution between CVMI stages and the DI stages of mandibular second molar in females. The chi square value $\chi^2(25)$ was 179.64 ($p < 0.001$). The Pearson contingency coefficient was 0.863 and showed a significant association between DI and CVMI. The statistical values for the females were higher than the males showing stronger association in females. It was also observed that the lower CVMI stages were more frequently associated with lower DI stages in both genders and vice versa. In females, the DI stages C, D corresponded to CVMI stages 1, 2; DI stages E, F with CVMI stages 3, 4; DI stage G with CVMI stage 5, and DI stages G, H with CVMI stage 6.

Table 2: Dental Calcification Stages Using Demirjian Index (DI)¹⁹

Stage	Characteristics
A	Calcification of single occlusal points without fusion of different calcifications.
B	Fusion of mineralization points; the contour of the occlusal surface is recognizable.
C	Enamel formation has been completed at the occlusal surface, and dentin formation has commenced. The pulp chamber is curved, and no pulp horns are visible.
D	Crown formation has been completed to the level of the cemento-enamel junction. Root formation has commenced. The pulp horns are beginning to differentiate, but the walls of the pulp chamber remain curved.
E	The root length remains shorter than the crown height. The walls of the pulp chamber are straight, and the pulp horns have become more differentiated than in the previous stage. In molars, the radicular bifurcation has commenced to calcify.
F	The walls of the pulp chamber now form an isosceles triangle, and the root length is equal to or greater than the crown height. In molars, the bifurcation has developed sufficiently to give the roots a distinct form.
G	The walls of the root canal are now parallel, but the apical end is partially open. In molars, only the distal root is rated.
H	The root apex is completely closed (distal root in molars). The periodontal membrane surrounding the root and apex is uniform in width throughout.

Table 3: Percentage distribution and the mean chronological ages of all the subjects grouped by various CVMI stages

CVMI stages	Females n (%)	Males n (%)	Mean age males Years ± SD	Mean age females Years ± SD
1	2(1.8)	0(0)		7.33±0.47
2	8(7.3)	10(10.1)	11.05±1.7	9.9±1.17
3	13(11.8)	38(38.4)	12.13±1.28	10.8±1.05
4	23(20.9)	19(19.2)	13.4±1.37	11.9±1.75
5	25(22.7)	15(15.2)	14.1±1.06	12.8±0.9
6	39(35.5)	17(17.2)	16.2±1.45	15.15±1.45

Mann Whitney / Wilcoxon Two-sample test (Kruskal Wallis test for 2 groups): (For females, $\chi^2(5) = 81.57, p < 0.001$; For males, $\chi^2(4) = 59.08, p < 0.001$)

Table 4: Mean age of different DI stages of mandibular second molar in genders and the gender difference

DI stages of mandibular second molar	Males mean age ± SD, years	Females mean age ± SD, years
C		7
D	9.6 ± 1	9.0 ± 0.95
E	11.28 ± 1.3	10.78 ± 1.2
F	12.66 ± 1.1	11.71 ± 1
G	14.05 ± 1.6	13.4 ± 1.25
H	15.46 ± 1.64	15.64 ± 1.44

Mann Whitney / Wilcoxon Two-sample test (Kruskal Wallis test for 2 groups): (For females, $\chi^2(5) = 77.23, p < 0.001$; For males, $\chi^2(4) = 56.68, p < 0.001$)

Table 5: Contingency table showing association and distribution between DI for mandibular second molar and CVMI stages for males

CVMI stages		DI for mandibular second molar						Total
		C	D	E	F	G	H	
1	Frequency							
2	Frequency		2	5	2	1		10
3	Frequency		2	9	18	9		38
4	Frequency			2	7	9	1	19
5	Frequency				4	3	8	15
6	Frequency					6	11	17
Total	Frequency	0	4	16	31	28	20	99

($\chi^2(16) = 72.8, p < 0.001$, Pearson's contingency coefficient between CVMI & DI is 0.713 at $p < 0.001$)

Table 6: Contingency table showing association and distribution between DI for mandibular second molar and CVMI stages for females

CVMI stages		DI for mandibular second molar						Total
		C	D	E	F	G	H	
1	Frequency	1	1					2
2	Frequency		4	2		2		8
3	Frequency			6	7			13
4	Frequency		1	2	12	6	2	23
5	Frequency			1	8	15	1	25
6	Frequency				1	17	21	39
Total	Frequency	1	6	11	28	40	24	110

($\chi^2(25) = 179.64, DF = 25, p < 0.001$, Pearson's contingency coefficient between CVMI & DI is 0.863 at $p < 0.001$);

Figure 1: Mean age at each CVMI stage in both genders.

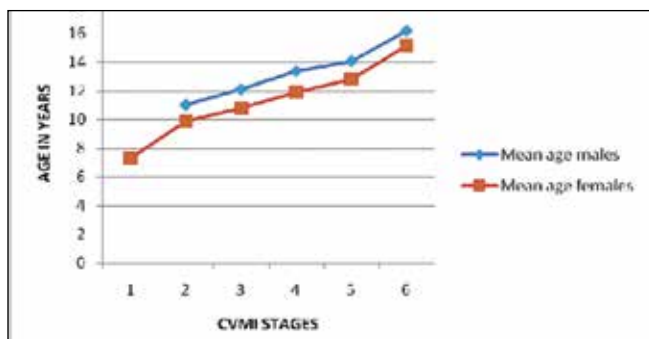
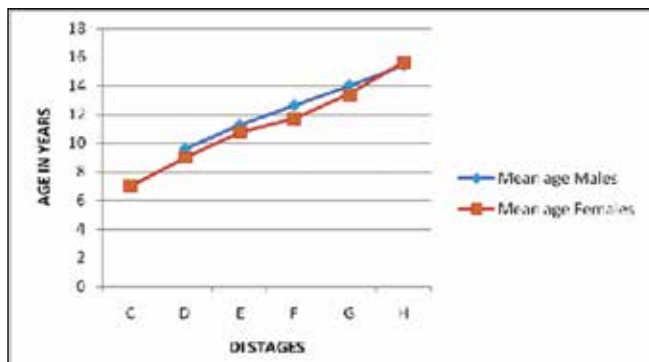


Figure 2: Mean age at each DI stage in both genders.



For the pooled sample, the chi square value $\chi^2(25)$ was 272.36 ($p < 0.001$), and the Pearson contingency coefficient between CVMI and DI was 0.752 at $p < 0.001$. Thus, a significant relationship was found to exist between CVMI stages and mandibular second molar DI stages in both the genders. Comparison of Tables 5 and 6 also shows that the DI in male subjects was more advanced than in female subjects with respect to CVMI stages.

DISCUSSION

Many methods have been suggested by researchers for prediction of skeletal maturity level of an individual.^{5,20-25} Use of hand-wrist radiographs leads to unnecessary radiation exposure. Lateral cephalograms and the OPGs taken as pre-treatment records for the orthodontic patients can be used to assess skeletal maturity by studying the cervical vertebrae maturation and the dental calcification events.

Studies^{1,16,17,20} have reported that the tooth calcification stages assessed from panoramic radiographs might be clinically useful as skeletal maturity indicators. The mandibular second molar calcification stages have shown strong correlation with skeletal maturity.^{1,16,17}

Many studies have evaluated mandibular canine²⁵⁻²⁷ or third molar²⁸⁻³⁰ calcification stages using OPGs and the hand-wrist x-rays to assess the skeletal maturity. Only one study could be found to evaluate relationship of CVMI and DI stages of mandibular second molars for skeletal maturity assessment.⁷ Since the data on mandibular second molars for prediction of skeletal maturity is scarce, the present study was conducted to assess the reliability of mandibular second molars calcification stages as an indicator of skeletal maturity. Certain advantages of this tooth over other teeth are that its development tends to continue over a longer period of time, and it can be easily identified on OPG as compared to the maxillary teeth.³⁰

Dental eruption is much more variable in its timing than dental maturation^{31,32} and is influenced by local and environmental factors.¹⁹ Therefore, the assessment of the maturation stages of teeth was the method of choice for this study. Dental maturity was assessed with the method proposed by Demirjian *et al*¹⁹ It records the distinct details based on shape and proportions of root length relative to crown height, rather than on absolute length, thus, avoiding the errors of faulty projections of images.¹ It also shows low intraexaminer and interexaminer error.²

Previous studies have concluded that the girls mature faster than boys.^{1,16,17} The observations of the present study are in corroboration with earlier studies, as each CVMI stage consistently appeared earlier in girls than boys (Table 3). Also, each DI stage of mandibular second molar appeared at an earlier age in the females as compared to the males, which shows an early maturation of mandibular second molar in females (Table 4). When the mean age of CVMI stages of the present study was compared to other populations,^{33,34} it was observed that Rwandese children achieved each CVMI stage at an earlier age than the other populations. It can be inferred that the Rwandese children have a tendency to mature early.

In this study, the DI was evaluated relative to CVMI for both genders which revealed a highly significant association between the DI and CVMI (Tables 5 and 6). This association was stronger in the females.

The previous studies^{1,16,17} had indicated that the maturation level of tooth development is more advanced in males as compared to the

females in relation to skeletal maturity stages. In the present study, it was also found that at the same CVMI stage, the males had a more advanced trend in DI of mandibular second molars than the females.

The relationship between skeletal maturity and peak height velocity (PHV) is well established.^{22,23,35} Fishman,²² Haegg and Taranger,²³ and Bjork and Helm³⁵ found that the appearance of adductor sesamoid of thumb as seen on hand – wrist x-rays indicates the beginning of pubertal growth spurt (the pre-peak of pubertal growth spurt or onset of PHV), which corresponds to stage 2 of CVMI.⁵ In our study, the DI stage E in males and stage D in females showed highest distribution in CVMI 2 stage.

Bjork and Helm³⁵ found that the MP3cap stage (epiphyseal capping of diaphysis of the middle phalanx of third finger as seen on hand wrist radiograph) heralds the peak of pubertal growth spurt, which corresponds to stage 3 of the CVMI.⁵ In the present study, the DI stages F, G in males and E, F in females corresponded to the CVMI stages 3 and 4. These findings indicate that the DI stages F, G in males and E, F in females represent the peak of the pubertal growth spurt.

Hassel and Farman studied cervical vertebra on lateral cephalograms and found that Fishman's²² skeletal maturity indicator 10 (fusion of epiphysis with diaphysis of distal phalanx of 3rd finger) corresponds to CVMI stage 5, and the fusion of the epiphysis and the diaphysis of the radius signifying the end of growth corresponds to CVMI stage 6.⁵ In our study, the DI stage H in males and DI stages G and H in females corresponded to the CVMI stages 5 and 6, showing the end of pubertal growth spurt. Stage G of mandibular second molar showed a scattered distribution in females in CVMI 5 and 6 stages. It indicates that the DI stage H implies an insignificant/no remaining adolescent growth.

In view of above findings, the mandibular second molar calcification stages can be used as an initial tool to predict the skeletal maturity level of the individuals. It can be advantageous in clinical settings when only IOPA of second molar region can be used for this purpose, rather than resorting to OPG. It can also be commented that the results of this study should not be applied to all racial/ethnic groups at global level. We observed that due to a small sample size the distribution of subjects in different CVMI and DI stages was not adequate, thus limiting the significance of the findings. Therefore, future studies are recommended with larger sample size to corroborate the findings.

CONCLUSIONS

A significant association was found between mandibular second molar calcification stages and CVMI stages, with a stronger association in females than males. It can be concluded that mandibular second molar calcification can be used as an indicator to assess the skeletal maturity. An IOPA view of second molar region can be used to assess the calcification stages before taking OPG or lateral cephalogram. Further studies are recommended with larger sample size to corroborate the findings.

REFERENCES

1. Krailassiri S, Anuwongnukroh N, Dechkunakorn S. Relationship between dental calcification stages and skeletal maturity indicators in Thai individuals. *Angle Orthod*, 72: 155–166, 2002.
2. Morris JM, Park JH. Correlation of dental maturity with skeletal maturity from radiographic assessment: a review. *J Clin Pediatr Dent*, 36: 309–314, 2012.
3. Bjork A. Timing of interceptive orthodontic measures based on stages of maturation. *Trans Eur Orthod Soc*, 48: 61–74, 1972.
4. Moore RN, Moyer BA, DuBois LM. Skeletal maturation and craniofacial growth. *Am J Orthod Dentofacial Orthop*, 98: 33–40, 1990.
5. Hassel B, Farman AG. Skeletal maturation evaluation using cervical vertebrae. *Am J Orthod Dentofacial Orthop*, 107: 58–66, 1995.
6. Hunter CJ. The correlation of facial growth with body height and skeletal maturation at adolescence. *Angle Orthod*, 36: 44–54, 1966.
7. Fishman LS. Radiographic evaluation of skeletal maturation. A clinically oriented method based on hand-wrist films. *Angle Orthod*, 52: 88–112, 1982.
8. Flores-Mir C, Nebbe B, Major PW. Use of skeletal maturation based on hand-wrist radiographic analysis as a predictor of facial growth: a systematic review. *Angle Orthod*, 74: 118–124, 2004.
9. Sidlauskas A, Zilinskaite L, Svalkauskiene V. Mandibular pubertal growth spurt prediction. Part one: Method based on the hand-wrist radiographs. *Stomatologija*, 7: 16–20, 2005.
10. Baccetti T, Franchi L, McNamara JA. An improved version of the cervical vertebral maturation (CVM) method for the assessment of mandibular growth. *Angle Orthod*, 72: 316–323, 2002.
11. San Roman P, Palma JC, Oteo MD, Nevado E. Skeletal maturation determined by cervical vertebrae development. *Eur J Orthod*, 24: 303–311, 2002.
12. Kamal M, Goyal S. Comparative evaluation of hand wrist radiographs with cervical vertebrae for skeletal maturation in 10-12 years old children. *J Indian Soc Pedod Prev Dent*, 24: 127–135, 2006.
13. Gandini P, Mancini M, Andreani F. A comparison of hand-wrist bone and cervical vertebral analyses in measuring skeletal maturation. *Angle Orthod*, 76: 984–989, 2006.
14. Başaran G, Ozer T, Hamamci N. Cervical vertebral and dental maturity in Turkish subjects. *Am J Orthod Dentofacial Orthop*, 131: 447.e13–20, 2007.
15. Lai EH, Liu J, Chang JZ, et al. Radiographic assessment of skeletal maturation stages for orthodontic patients: hand-wrist bones or cervical vertebrae? *J Formos Med Assoc*, 107: 316–325, 2008.
16. Uysal T, Sari Z, Ramoglu SI, Basciftci FA. Relationships between dental and skeletal maturity in Turkish subjects. *Angle Orthod*, 74: 657–664, 2004.
17. Kumar S, Singla A, Sharma R, Viridi MS, Anupam A, Mittal B. Skeletal maturation evaluation using mandibular second molar calcification stages. *Angle Orthod*, 82: 501–506, 2012.
18. Mappes MS, Harris EF, Behrents RG. An example of regional variation in the tempos of tooth mineralization and hand-wrist ossification. *Am J Orthod Dentofacial Orthop*, 101: 145–151, 1992.
19. Demirjian A, Goldstein H, Tanner JM. A new system of dental age assessment. *Human Biol*, 45: 211–227, 1973.
20. Chertkow S. Tooth mineralization as an indication of the pubertal growth spurt. *Am J Orthod*, 77: 79–91, 1980.
21. Sierra AM. Assessment of dental and skeletal maturity. A new approach. *Angle Orthod*, 57: 194–198, 1987.
22. Fishman LS. Radiographic evaluation of skeletal maturation. *Angle Orthod*, 52: 88–112, 1982.
23. Ha'gg U, Taranger J. Skeletal stages of the hand and wrist as indicators of the pubertal growth spurt. *Acta Odontol Scand*, 38(3): 187–200, 1980.
24. Grave KG. Physiological indicators in orthodontic diagnosis and treatment planning. *Aust Orthod J*, 5: 114–122, 1978.
25. Grave K. The use of the hand and wrist radiograph in skeletal age assessment; and why skeletal age assessment is important. *Aust Orthod J*, 13: 96, 1994.
26. Coutinho S, Buschang PH, Miranda F. Relationship between mandibular canine calcification stages and skeletal maturity. *Am J Orthod Dentofacial Orthop*, 104: 262–268, 1993.
27. Hareesha KB, Babu NC. Co-relation between mandibular canine calcification stages and skeletal maturity. *J Int Oral Health*, 2(3): 41–47, 2010.
28. Demisch S, Wartmann C. Calcification of mandibular third molar and its relationship to skeletal and chronological age in children. *Child Dev*, 27: 459–473, 1956.
29. Engström C, Engström H, Sagne S. Lower third molar development in relation to skeletal maturity and chronological age. *Angle Orthod*, 53: 97–106, 1983.
30. Cho SM, Hwang CJ. Skeletal maturation evaluation using mandibular third molar. *Korean J Orthod*, 39(2): 120–129, 2009.
31. Nolla CM. The development of the permanent teeth. *J Dent Child*, 27: 254–263, 1960.
32. Van der Linden FP. Transition of the Human Dentition. Ann Arbor, Mich: Center for Human Growth and Development, University of Michigan, 1979.
33. Soegiharto BM, Moles DR, and Cunningham SJ. Discriminatory ability of the skeletal maturation index and the cervical vertebrae maturation index in detecting peak pubertal growth in Indonesian and white subjects with receiver operating characteristics analysis. *Am J Orthod Dentofacial Orthop*, 134: 227–37, 2008.
34. Dabla N, Sehgal V, Gupta R, Chandna AK, Pradhan KL. A comparative evaluation of modified MP3 and CVMI stages as maturation indicators. *J Ind Orthod Soc*, 39: 147–154, 2006.
35. Bjork A, Helm S. Prediction of the age of maximum pubertal growth in body height. *Angle Orthod*, 37: 134–143, 1967.

Downloaded from http://enrlian.allenpress.com/jcpd/article-pdf/39/1/79/1742841/jcpd_39_1_9224022173577151.pdf by guest on 14 June 2024