

Zirconia Crowns for Rehabilitation of Decayed Primary Incisors: An Esthetic Alternative

Ashima G*/ Sarabjot K Bhatia**/ Gauba K***/ Mittal HC****

Esthetic management of extensively decayed primary maxillary anterior teeth requiring full coronal coverage restoration is usually challenging to the pediatric dentists especially in very young children. Many esthetic options have been tried over the years each having its own advantages, disadvantages and associated technical, functional or esthetic limitations. Zirconia crowns have provided a treatment alternative to address the esthetic concerns and ease of placement of extra-coronal restorations on primary anterior teeth. The present article presents a case where grossly decayed maxillary primary incisors were restored esthetically and functionally with readymade zirconia crowns (ZIRKIZ, HASS Corp; Korea). After endodontic treatment the decayed teeth were restored with zirconia crowns. Over a 30 months period, the crowns have demonstrated good retention and esthetic results. Dealing with esthetic needs in children with extensive loss of tooth structure, using Zirconia crowns would be practical and successful. The treatment described is simple and effective and represents a promising alternative for rehabilitation of decayed primary teeth.

Key words: Esthetics, children, zirconia

INTRODUCTION

Esthetic management of decayed, deformed or traumatized primary maxillary anterior teeth in children often requiring restorations with full coronal coverage is challenging especially due to their small size, close proximity of the pulp to the tooth surface, relatively thin enamel, reduced surface area for bonding coupled with behaviour management problems especially in very young children.¹ While there is limited information on the potential psychosocial impact of anterior caries or un-esthetic restorations in primary teeth, optimal esthetics should clearly be the treatment goal whenever possible.² An ideal anterior restoration should be easy to place, durable, esthetically pleasing and inexpensive. Over the years, several available options have been tried for providing full coverage restoration for anterior primary teeth each having its own advantages and associated technical, functional or esthetic limitations.^{3,4}

Published literature shows success of many restorative techniques that dentists used to restore primary anterior teeth however, there is insufficient evidence related to scientifically proven outcome.⁴ The technological advances in dental materials and techniques for use on children, which have occurred in the past decades, make constant re-evaluation of treatment philosophies and techniques a necessity.⁵ Over the last decade, keeping in mind the esthetic requirement of pediatric population readymade zirconia crowns for primary anterior teeth have been introduced. The purpose of this article was to describe the rehabilitation of grossly decayed primary maxillary incisors in a four year old boy using readymade zirconia crowns (ZIRKIZ, HASS Corp; Korea).

Case report

A 4 year old boy accompanied by his parents presented to the pediatric dentistry clinic with concern of discoloured upper front teeth. The child had completely destroyed coronal portion of maxillary incisors due to progressive decay and carious primary canines and molar (Fig 1A). The patient's history was taken; a clinical and radiographic evaluation was performed. There were no pathological alterations of the root, periodontal ligament space or alveolar bone evident on the intraoral periapical radiograph (Fig 1B) and none of the incisors was mobile or sensitive to percussion or digital manipulation. Intra-oral radiograph also reveals presence of two inverted supernumerary teeth in relation to tooth buds of permanent central incisors (Fig 1B). Medical history was non-contributory. Also there was no significant history of parafunctional habit or bruxism. Diet analysis and counselling was done and prophylaxis was carried out. The carious primary canine and molars were planned to be restored with composite. Restoration of carious primary incisors using Zirconia crowns was planned keeping in mind the esthetic concerns of the child and parents. The parents were informed of

From the Department of Pediatric and Preventive Dentistry
Oral Health Sciences Center, Post Graduate Institute of Medical Education
and Research
Chandigarh, India.

*Ashima Goyal, MDS, Professor.

**Sarabjot Kaur Bhatia, MDS, Assistant Professor.

***K Gauba, MDS, Professor.

****Hitesh Chander Mittal, MDS, Ex-Resident.

Send all correspondence to:

Sarabjot K Bhatia,

Department of Pediatric and Preventive Dentistry, Oral Health Sciences
Centre, Post Graduate Institute of Medical Education and Research, Sector
12, Chandigarh India

Phone: +919815027746

E-mail: docsarab2005@rediffmail.com

Figure 1. A- Frontal view of maxillary incisors
B- Initial radiograph of the anterior primary teeth

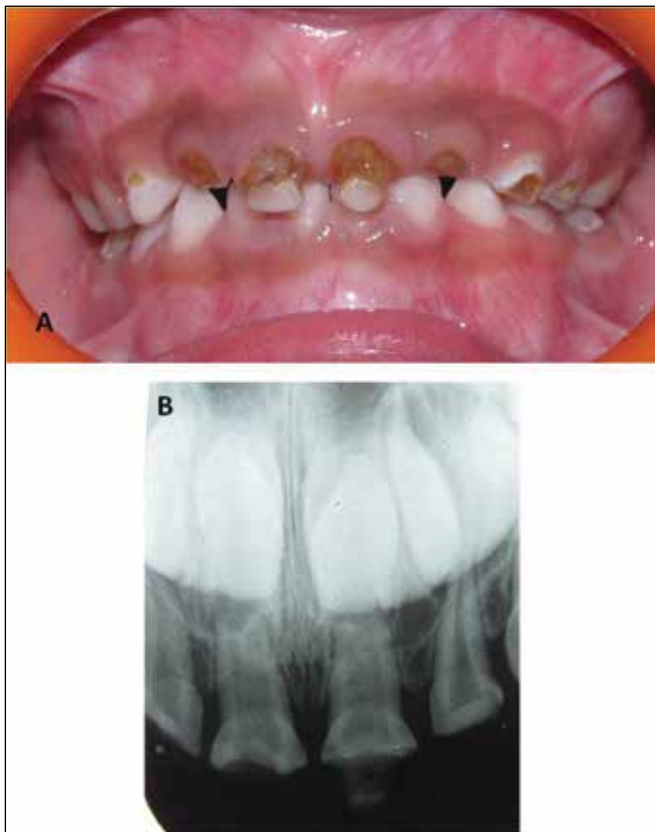

Figure 3. Diagrammatic representation of crown cutting for "passive fit" as per manufacturer instructions

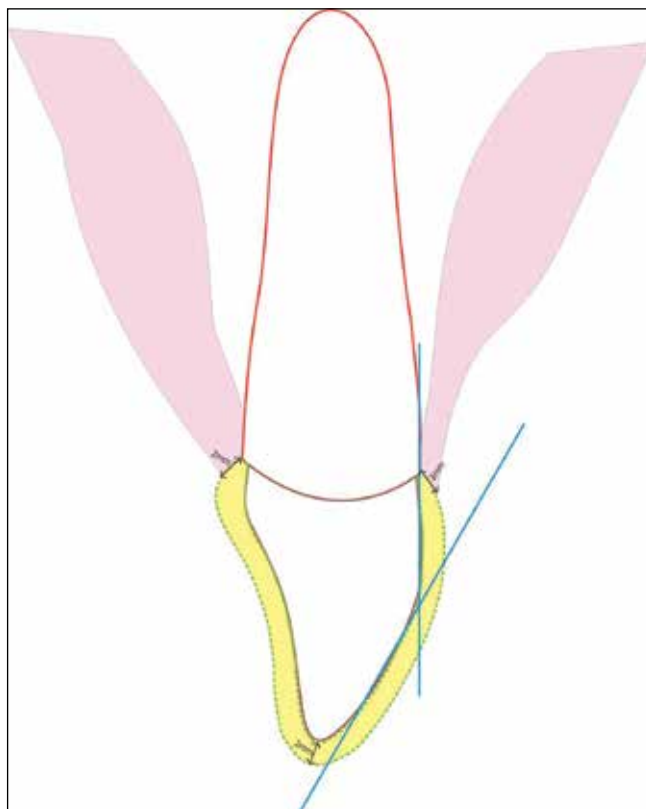


Figure 2. Sealing of the root canals with glass-ionomer cement after endodontic treatment

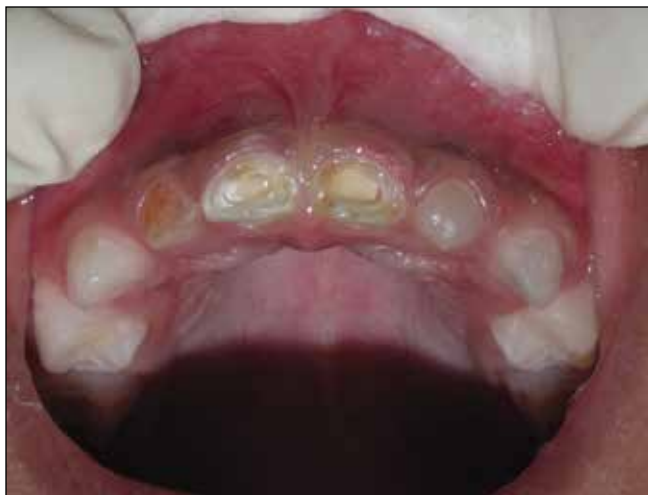
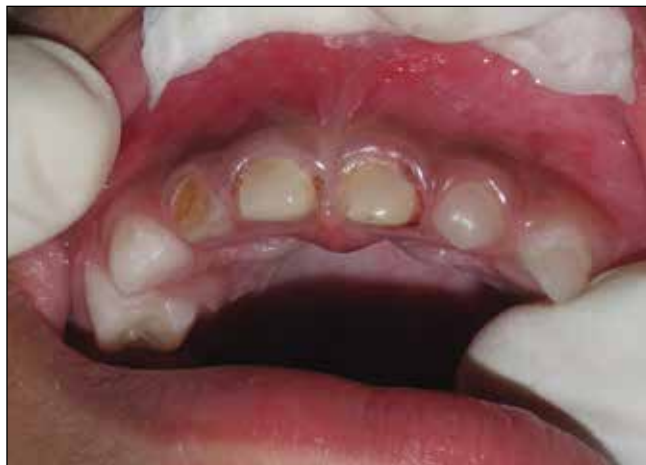
Figure 4. Prepared primary teeth for "Passive fit" of zirconia crowns



the selected technique. As the co-operation profile of the child was satisfactory, in the first appointment after restoration of the carious primary molars and canines with composite resin (Z 350^{XT} 3M ESPE) and after administration of local anaesthesia the maxillary central incisors were submitted to a pulpectomy technique and were filled with calcium hydroxide paste (ApexcalTM Ivoclar Vivadent) using lentulospiral. The canal was further prepared by removing root canal filling material by one-third of the canal length. A thin layer of glass ionomer cement was placed to isolate the root canal filling material (Fig 2) and the root canal was further sealed with light cured resin composite (Z 350^{XT} 3M ESPE).

During the next visit, zirconia crowns (ZirkizTM) were used to build up the teeth. The crowns were selected beforehand based on the mesio- distal width of the teeth. After application of local anaesthesia jelly, the tooth structure was cut for “passive fit” as the zirconia crowns do not flex. As per the manufacturer instructions, incisal edge was reduced to provide clearance of about 2mm. For the labial surface: the 2-plane reduction was made close to natural tooth and for proximal surface the distance to the adjacent teeth was considered and parallel mesial and distal walls were created extending 1-2 mm subgingivally. Enough reduction of cingulum was done on the palatal surface (Fig 3). Feather-edge margins were provided about 1-2 mm subgingivally (Fig 4). After being evaluated for marginal fit, the zirconia crowns were cemented with light cure resin cement (Rely X/3M ESPE) and were held with firm consistent pressure at proper position on the teeth till the initial set. The occlusion was checked and removal of interferences and shape modification required was done with high speed diamond bur. The post operative periapical X- ray confirmed the proper fit of the crowns (Fig 5)

The child and parents were instructed on the importance of oral hygiene and diet. They were also motivated to maintain regular recall appointments every 3 months (Fig 6). During follow up visits crowns were evaluated for any discoloration or fracture. Also the mandibular incisors were evaluated for any wear. No wear of opposing teeth was noted. A 30 month post-operative evaluation of the restored teeth revealed proper functioning of the crowns with no discoloration or loss of restoration (Fig 7).

DISCUSSION

Despite attempts to improve the dental health and to minimize the effects of caries, pediatric dentists still deal with cases of extensive destruction of primary teeth. One of the most challenging tasks for the pediatric dentists is to restore grossly decayed primary anterior teeth with full coverage restorations which are durable esthetic and retentive. For decades, stainless steel crowns have been considered the most easily placed and the most durable of all restorations outperforming amalgam and direct composites.⁶ However, because of their un-esthetic appearance these crowns are no longer acceptable to the patient and/or their parents. Esthetic alternatives in the form of open faced stainless steel crowns, pre-veneered stainless steel crown and bonded strip crowns have been developed over the years.⁷ Open faced stainless steel crowns are durable and esthetic however, the technique is time consuming and requires additional preparation and use of multiple materials.⁸ Also, poor gingival health, haemorrhage of gingival tissue and visibility of metal margin around composite remains an issue.⁷ Pre-veneered or resin veneered

crowns resolve some problems associated with other crowns as these can be placed in single, short appointment and esthetics are not affected by saliva/haemorrhage but the relatively inflexible and brittle resin facing material tends to chip off when subjected to heavy forces.⁸

Bonded celluloid strip crowns have been considered most esthetic, natural looking complete coverage restorations available for primary incisors⁹ but have the inherent drawback of being technique sensitive and a low colour stability. Even when placed under ideal conditions, strength and resistance to wear are far from that of stainless steel crowns.¹⁰ Also, they require extensive reduction of the tooth structure to provide the required passive fit. Another esthetic option is the use of biological crowns made from extracted primary teeth. The disadvantages of this technique include the need for a tooth bank, parental and child agreement by the donors and recipients of tooth fragments and the technique may also not comply with stringent cross-infection control policies of the twenty-first century.¹¹

Many such options exist to repair carious primary incisors, but there are insufficient controlled clinical data to suggest that one type of restoration is superior to another. This does not discard the fact that dentists have been using many of these crowns for years with success. Clinician's preferences, esthetic demands by parents, the child's behaviour, as well as moisture and haemorrhage control are all variables which affect the decision and ultimate outcome of whatever restorative treatment is chosen.⁴

Zirconia crowns also known as “ceramic steel” as it provides tooth like esthetics and strength close to available metal crowns have been in use in dentistry for the last one decade and is commonly used for restoration of permanent teeth in the form of Crowns, Fixed partial denture, Implant abutment, fixture, inlay, onlay, CAD/CAM etc. Zirconia is a crystalline dioxide of zirconium. The Zirconia Crowns not only look more translucent, but are almost five times stronger than the Porcelain fused to the Metal crowns as the Zirconia crowns are milled from a single densely sintered block of crystal. Zirconia crowns provide more strength in less volume, are thermo-stable with low heat conductivity, low thermal expansion and stable chemical resistance. Cyclical stresses are also well tolerated by this extremely biocompatible material.¹²

Thin labial structure of the available readymade zirconia crowns (ZIRKIZ) resembles natural primary anterior tooth providing better gingival tissue adaptation. Because of no additional steps required in facing placement unlike open faced stainless steel crowns, chair side time is decreased and additional step of laboratory fabrication is eliminated. The zirconia crowns manufactured for use in pediatric dentistry are available in different sizes for maxillary anterior teeth which allow better fit and reduced chair side time. Zirconia provides highly polished surface thus preventing staining and plaque accumulation unlike composite strip crowns. The zirconia crowns can be placed by simple technique. A moderate level of translucency makes it suitable for esthetically demanding clinical cases, such as restoring maxillary anterior teeth. The zirconia crowns presents superior durability as is reported in the present case and there are no chances of facing loss as in pre-veneered stainless steel crowns. A good balance of strength, precision, and translucency allows zirconia-based restorations to accommodate a variety of clinical situations.¹³

Figure 5. A- Final view after crown cementation
B- Radiograph showing endodontically treated maxillary central incisors and cemented zirconia crowns

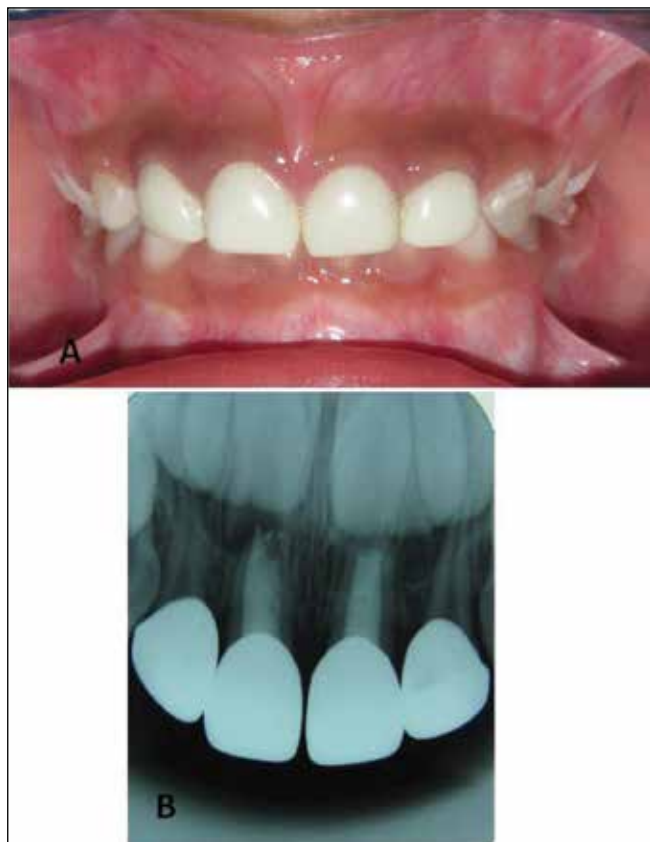

Figure 7. A-Crowns after 30 months of cementation.
B- Radiograph showing normal root resorption

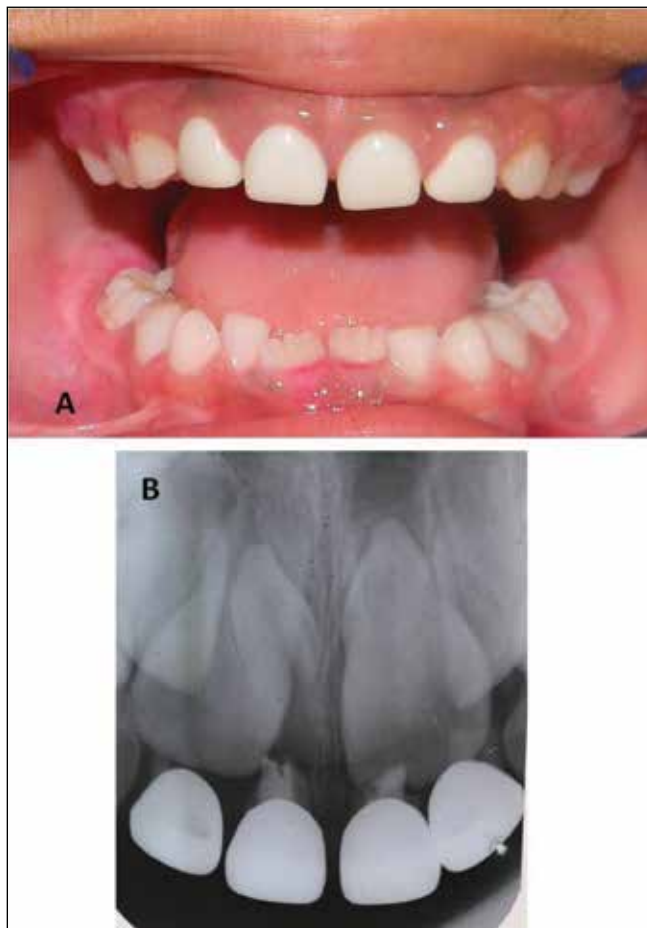
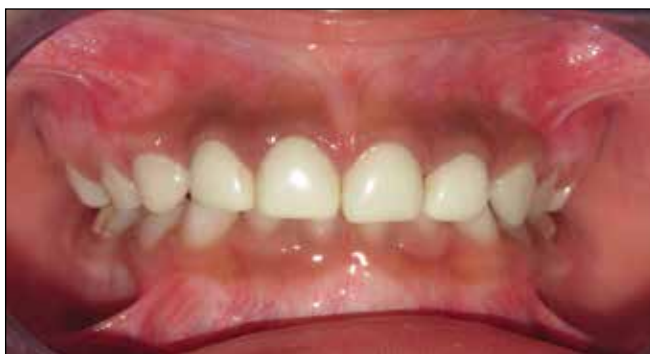

Figure 6. Crown after 12 months of cementation



Although the technique of placement of zirconia crowns is simple, long term follow up to study the durability and fracture resistance of the zirconia crowns is required to label it as an ideal technique for the management of grossly decayed primary teeth. Also, the abrasive effect of the material against the other teeth, and onto the existing root needs to be considered.

CONCLUSION

The treatment described in the case report is simple and effective and represents a promising alternative for rehabilitation of severely decayed or fractured primary anterior teeth. The technique presented here can be added as a treatment option to restore primary incisors for pediatric dentists due to their unparalleled advantages, including working time, esthetics and improved microstructure. When choosing a material, however, costs should be thoroughly compared with other alternative methods.

REFERENCES

1. Shah PV, Lee JY, Wright JT. Clinical success and parental satisfaction with anterior preveneered primary stainless steel crowns. *Pediatr Dent*; 26: 391-395.2004.
2. Judd PL, Csasa MJ. Psychosocial perceptions of premature tooth loss in children. *Ont Dent*;72:16-18.1995.
3. Lee JK. Restoration of primary anterior teeth: Review of the literature. *Pediatr Dent*.;24: 506-510.2002.
4. Waggoner WF. Anterior crowns for primary anterior teeth: An evidence based assessment of the literature. *Eur Arch Paediatr Dent*. 7(2) :53-57.2006.
5. Mortada A King NM. Simplified technique for the restoration of severely mutilated primary anterior teeth. *J Clin Pediatr Dent*;28:187-192.2004.
6. Croll T, Helpin M. Preformed raesin veneered stainless steel crowns for restoration of primary incisors. *Quintessen Int*;27:309-313.1996.
7. Maclean JK, Champagne GE, Waggoner WT, Ditmyer MM, Casamassirno P. Clinical outcomes for primary anterior teeth treated with preeneered stainless steel crowns. *Pediatr Dent*, 29: 377-378.2007.
8. Waggoner WF, Cohen H. Failure strength of four veneered primary stainless steel crown. *Pediatr Dent*; 17: 36-40.1995.
9. Waggoner WF. Restoring primary anterior teeth. *Pediatr Dent*, 24:511-516. 2002.
10. Tate AR, Ng MW, Needleman HL, Asc G. Failure rates of restorative procedures following dental rehabilitation under general anesthesia. *Pediatr Dent*;24: 69-71.2002.
11. Ramires-Romito ACD, Wanderley MT, Oliveira MD, Imparato JC, Correa MS. Biologic restoration of primary anterior teeth. *Quintessence Int*; 31: 405-411. 2000.
12. Al-Amleh B, Lyons K, Swain M. Clinical trials in zirconia: a systematic review. *J Oral Rehabil*;37(8):641-52. 2010.
13. Chang YY. Maximizing esthetic results on zirconia-based restorations. *Gen Dent*;59(6):440-5 .2011.