

# Neural Substrates of Visuospatial Processing in Distinct Reference Frames: Evidence from Unilateral Spatial Neglect

Jared Medina<sup>1,3</sup>, Vijay Kannan<sup>2</sup>, Mikolaj A. Pawlak<sup>3,4</sup>,  
Jonathan T. Kleinman<sup>2</sup>, Melissa Newhart<sup>2</sup>, Cameron Davis<sup>2</sup>,  
Jennifer E. Heidler-Gary<sup>2</sup>, Edward H. Herskovits<sup>3</sup>, and Argy E. Hillis<sup>1,2</sup>

## Abstract

■ There is evidence for different levels of visuospatial processing with their own frames of reference: viewer-centered, stimulus-centered, and object-centered. The neural locus of these levels can be explored by examining lesion location in subjects with unilateral spatial neglect (USN) manifest in these reference frames. Most studies regarding the neural locus of USN have treated it as a homogenous syndrome, resulting in conflicting results. In order to further explore the neural locus of visuospatial processes differentiated by frame of reference, we presented a battery of tests to 171 subjects within 48 hr after right supratentorial ischemic stroke before possible structural and/or functional reorganization. The battery

included MR perfusion weighted imaging (which shows hypo-perfused regions that may be dysfunctional), diffusion weighted imaging (which reveals areas of infarct or dense ischemia shortly after stroke onset), and tests designed to disambiguate between various types of neglect. Results were consistent with a dorsal/ventral stream distinction in egocentric/allocentric processing. We provide evidence that portions of the dorsal stream of visual processing, including the right supramarginal gyrus, are involved in spatial encoding in egocentric coordinates, whereas parts of the ventral stream (including the posterior inferior temporal gyrus) are involved in allocentric encoding. ■

## INTRODUCTION

An influential model of visual processing specifies three different levels of representation (Marr, 1982). The primal sketch is the first level. Computations at this level include basic processes that detect edges and blobs, and its frame of reference is retina-centered. The second level, the 2.5-D sketch, is a surface-based representation with the left and the right of the stimulus defined by the viewer's left and right. Finally, the third level (3-D sketch) represents objects as three-dimensional, without any viewer-centered reference point. This level of visual processing is in an object-centered reference frame. Monk (1985) proposed a multilevel model of word and object recognition based roughly on Marr's theory of visual processing, later elaborated by Hillis and Caramazza (1995). Studies of stroke patients with dissociable forms of unilateral spatial neglect (USN) have provided evidence for these different levels of representation in visuospatial processing.

USN is characterized by an inability to attend or respond to stimuli or space on the contralesional side (Heilman,

Watson, & Valenstein, 1993). USN is separable into distinct subtypes of neglect (e.g., near vs. far, intentional vs. attentional), each reflecting damage affecting a specific component of attentional and/or representational processing. Subjects have manifest neglect in three coordinate frames that are broadly consistent with Marr's proposal. The first coordinate frame is called "viewer-centered." The midlines of viewer-centered frames of reference are projected from the center of the body part on which the reference frame is centered. For example, these egocentric frames of reference can acquire a midline projected from the center of the viewer's head, torso, or retina. Reports from subjects with USN support the existence of this reference frame. Karnath, Schenkel, and Fischer (1991) reported four patients with left "trunk-based" neglect. Hillis, Rapp, Benzing, and Caramazza (1998) presented a subject with a tachistoscopic reading task decoupling various viewer-centered frames of reference, and found that this subject demonstrated retina-centered neglect (see also Ladavas, 1987; Bisiach, Capitani, & Porta, 1985).

Allocentric frames of reference are not centered with respect to the viewer but are instead centered with respect to the stimulus. Two different types of allocentric reference frame are "stimulus-centered" and "object-centered." The midline of a stimulus-centered frame of

<sup>1</sup>Johns Hopkins University, <sup>2</sup>Johns Hopkins Medical Institutions, <sup>3</sup>University of Pennsylvania, <sup>4</sup>Poznan University of Medical Sciences

reference is defined by the center of the target stimulus, regardless of where the stimulus is positioned relative to the viewer. For example, a hypothetical subject with left stimulus-based neglect presented with an object in his left body field would not neglect the entire stimulus, as would a hypothetical subject with left viewer-based neglect. Instead, the subject would neglect only the left side of that stimulus. Moreover, the patient would equally neglect the left side of the stimulus presented on the left or the right side of the body.

Hillis and Caramazza (1995) reported a patient who demonstrated stimulus-centered neglect in both word and object processing. B. P. N., a patient with right temporal, parietal, and inferior frontal lobe damage, made neglect errors at the beginning of words that were presented horizontally. B. P. N.'s deficit was not viewer-centered (head or trunk-centered), as he made errors on the left sides of words on both sides of the page/trunk while his head remained fixed. On an object recognition task of chimeric figures, B. P. N. neglected the left side of objects presented both to the left or right of fixation, thus not being a retina-centered deficit. Furthermore, B. P. N. neglected the left side of mirror-reversed words, even though the orientation of the word had changed such that the left side of the stimulus was now the final letters (i.e., the canonical right side of the word) (see also Subbiah & Caramazza, 2000; Behrmann & Tipper, 1999; Arguin & Bub, 1993; Ellis, Flude, & Young, 1987). His pattern of performance across tasks can be explained by impaired visual processing in a left stimulus-centered reference frame (Figure 1).


A canonical orientation can be defined as an orientation in which a viewer normally sees a particular object. For example, a person usually sees a camel with its humps and head above its feet, and thus, has a canonical up-down orientation. However, camels are often viewed either facing the right or facing the left. Camels (and most other objects) do not have a canonical left-right orientation.

Words are different in that they have a canonical up-down and canonical left-right orientation. The left side of the word in object-centered coordinates (canonical view) corresponds to the beginning of the word in English, regardless of whether it is presented upside-down (rotated 180°), mirror-reversed, or vertically (with initial letters at the top or bottom).

An object-centered frame of reference frame, like a stimulus-centered one, is centered on a particular item, irrespective of its location with respect to the viewer. However, the left-right orientation of the object is based on its canonical orientation, not its orientation with respect to the viewer. A patient with right object-centered neglect would make errors at the end of the word, regardless of how it is presented to the subject. For example, a left-handed patient with a left cortical stroke, N. G., made errors on the contralesional side of the canonical representation, such as reading *habitual* as "habit" on vertically presented words (printed either top to bottom or bottom to top). She made the identical type of errors, such as *common* read as "comet" and *dashes* as "dash" on mirror-reversed words. Her neglect was even manifested by errors on the final letters in oral and written spelling and in recognition of orally spelled words, providing evidence that her deficit was not limited to visually presented stimuli. Patients with object-based neglect also neglect one side of individual objects in a scene, not the entire array. Object-centered neglect, although relatively rare, has been observed in other patients (Miceli & Capasso, 2001; Driver & Halligan, 1991; Baxter & Warrington, 1983).

Disambiguating various types of USN defined by reference frames requires manipulations of either the position of the viewer (head, body, or line of sight) with respect to the object, or the object with respect to the viewer. In order to distinguish viewer-centered neglect from stimulus-centered neglect, one can manipulate the location of the stimulus relative to the midline of the viewer. For example, one can disambiguate trunk-centered ne-

**Figure 1.** Patterns of performance for different types of USN. Dotted line refers to midline of the subject's body (adapted from Subbiah & Caramazza, 2000).



glect from stimulus-centered neglect by presenting a stimulus  $45^\circ$  left of the subject's body, at the center of the subject's body, and  $45^\circ$  right of the subject's body. If the subject has left trunk-centered neglect, then he or she will tend to fail to respond to stimuli presented in his left trunk field while responding to stimuli presented in the right trunk field. However, subjects with left stimulus-centered neglect will tend not to respond to the left side of the stimulus, regardless of where it is presented with respect to the subject. Administering various neglect tests to the left and right of the viewer's midline can be used to distinguish between viewer- and stimulus-centered neglect.

Separating stimulus-centered neglect from object-centered neglect requires manipulations of the actual stimulus, not its position with respect to the viewer. In stimulus-centered neglect, subjects fail to respond to one side of the stimulus regardless of its orientation. For example, when presenting a map of the United States at midline to someone with left stimulus-centered neglect, he or she will fail to attend to the West Coast when the map is presented canonically. However, if that same map was presented to the subject rotated  $180^\circ$ , then the subject would fail to attend to the East Coast. Object-centered neglect is characterized by a failure to attend to one side of the object as defined by its canonical left–right orientation. When presenting a map of the United States to a subject with left object-centered neglect, he or she will fail to attend to the West Coast, regardless of whether the map is presented canonically or rotated  $180^\circ$ . To distinguish between the two, the stimulus must be oriented such that the object's canonical left–right orientation is not aligned with its left–right orientation with respect to the viewer. Objects with canonical left–right sides (such as words, some flags, maps, paper money, computer keyboards, etc.) can be manipulated in such a manner, and can be used to distinguish between stimulus- and object-centered neglect.

Studying subjects with USN due to focal brain damage can provide evidence for the neural correlates of different forms of visuospatial processing, if particular lesion sites are associated with USN affecting visual processing in distinct reference frames. Previous studies on the neural locus of neglect have found evidence for USN subsequent to damage to various brain regions. Most studies of lesion location in USN have implicated right posterior parietal cortex (PPC) as the likely cortical candidate for USN (Mort et al., 2003; Vallar, Bottini, & Paulesu, 2003; Maguire & Ogden, 2002; Vallar & Perani, 1986; Heilman, Watson, Valenstein, & Damasio, 1983). However, other studies have identified lesions outside of the right parietal lobe associated with USN. Karnath and colleagues reported that the right superior temporal gyrus (STG) is most likely to be infarcted in patients with USN and no evidence of hemianopia or other primary visual deficit (Karnath et al., 2005; Karnath, 2001). Another study found lesions in the right middle temporal gyrus (MTG) to be

most frequently associated with neglect, with 12 out of 18 neglect patients having damage to that area (Samuelsson, Jensen, Ekholm, Naver, & Blomstrand, 1997). Mort et al. (2003) reported that the right angular gyrus is associated with neglect after middle cerebral artery stroke, whereas the medial-temporal lobe is associated with neglect after posterior cerebral artery stroke. In studies using CT and SPECT, Leibovitch et al. (1998, 1999) found that neglect was associated with hypoperfusion of right lateral occipital and posterior inferior temporal cortex, along with right PPC and STG. The right frontal lobe has also been implicated as a region associated with USN (Karnath et al., 2005; Heilman et al., 1983).

A possible reason for these differing results could be the manner in which neglect has been defined. USN has been treated as a homogenous syndrome in previous localization studies. However, USN is separable into distinct subtypes divisible by reference frame, each reflecting disruption of specific cognitive mechanisms dedicated to attending to and/or representing visual stimuli. If different forms of USN have different neural substrates, studies that group all USN patients together or that identify patients with only one subtype are likely to obtain results that implicate different regions of the brain.

Identifying brain regions involved in USN in different frames of reference is difficult when evaluating chronic lesions associated with USN. First, studies associating lesion location with neglect are usually carried out months or years after the initial stroke. Between stroke and testing, there can be cortical reorganization such that the original correlation between structure and function is altered (Jenkins & Merzenich, 1987). That is, even if an area of the brain was initially essential for some cognitive function, other areas might assume that function months or years after stroke. Second, many stroke patients have neglect in the acute stage that resolves within a few weeks of stroke (Samuelsson et al., 1997; Stone, Patel, Greenwood, & Halligan, 1992). Other lesion studies have only included patients with chronic neglect. Patients with chronic neglect tend to have relatively large lesions, as those with small lesions generally show resolution of neglect in the acute stage. Studying only chronic neglect biases the patient population toward patients with larger infarcts.

We propose that it would be useful to study neglect in the acute stage before extensive reorganization. Although reorganization may start soon after stroke onset, we have demonstrated that recovery of complex cognitive functions in the first few days of stroke only occurs in patients who show recovery of tissue function due to reperfusion (Hillis et al., 2002). However, conventional MRI (e.g., T1, T2, Fluid Attenuated Inversion Recovery [FLAIR] sequences) and CT have high false-negative rates in diagnosing ischemia/damage shortly after stroke (Warach, Dashe, & Edelman, 1996). Magnetic resonance perfusion imaging (PWI) and diffusion weighted imaging (DWI) are recent neuroimaging methods that can more

accurately identify dysfunctional and/or damaged brain regions at an acute stage. Diffusion weighted imaging identifies areas of dense ischemia that are unlikely to survive (Fisher, 1995). After cell death, ion channel pumps on the cell membrane that maintain cellular equilibrium cease to function. Water permeates the cell (cytotoxic edema) and cellular diffusion is reduced. DWI records this decrease in cellular diffusion, and allows areas of cytotoxic edema to be identified shortly poststroke (Beaulieu et al., 1999). In MR perfusion imaging, the rate of passage of an intravenously administered contrast agent is measured to estimate the amount of blood delivered to a certain area of tissue over a period of time (Fisher & Albers, 1999). Areas of significantly delayed contrast arrival have been identified as dysfunctional regions (Hillis, Kane, et al., 2001; Beaulieu et al., 1999). Areas of brain that are abnormal on either DWI or PWI can be responsible for deficits in acute stroke.

Hillis et al. (2005) previously used PWI in order to examine areas of cortical dysfunction associated with allocentric versus egocentric neglect in 50 subjects with infarcts on DWI limited to right subcortical structures. In an ROI analysis, they found that left egocentric neglect was strongly associated with hypoperfusion of right BA 39 (angular gyrus), whereas left allocentric (stimulus-centered or egocentric) neglect was associated with hypoperfusion of right BA 22 (STG). The present study differs in that this set of subjects consisted of patients with any right supratentorial infarct, consisting mainly of patients with cortical stroke (with or without subcortical damage). We used DWI and PWI to identify dysfunctional brain regions in patients with any right supratentorial infarct in order to study the neural correlates of viewer-, stimulus-, and object-centered visuospatial processing. In this study, we used voxel-based analyses to identify specific cortical and subcortical voxels where tissue dysfunction is associated with distinct subtypes of neglect in acute stroke, before the opportunity for reorganization or rehabilitation.

## METHODS

### Subjects

A consecutive series of 171 subjects with acute right supratentorial ischemic stroke admitted to Johns Hopkins Hospital were enrolled in the study. Inclusion criteria were: age 21 years or older, admittance to the hospital within 24 hr after onset of symptoms, and the ability to provide informed consent or have a relative/caregiver provide informed consent. Exclusion criteria included hemorrhage on initial MRI and or CT scan, brainstem or cerebellar stroke, allergic reaction to gadolinium, diminished level of consciousness, need for ongoing intravenous sedation, and contraindication for MRI (e.g., claustrophobia, pregnancy, metallic implants, and cardiac pacemaker). The ages of the subjects (79 men and 92 women) ranged from

25 to 91 years, with a mean age of  $65.0 \pm 14.0$  years. All subjects were right handed.

### Neglect Testing

A battery of tests was designed to evaluate the presence of USN and the frame of reference in which USN was manifested. The battery was administered to the patient at bedside. Tests included:

- (i) Lexical tasks. Subjects were presented a list of words ( $n = 30$ ) for oral reading and for spelling. This list was divided into two columns for the oral reading task. Subjects were also presented with five sentences consisting of 34 words. Both tests were presented at midline of the subject's body. Patients who consistently made errors on one side of words were presented with vertical and mirror-reversed words, in order to disambiguate between stimulus- and object-centered neglect. These patients were also tested on recognition of words spelled aloud.
- (ii) Visuomotor tasks. Subjects were instructed to copy a line drawing of a clock and the "Ogden scene" (Ogden, 1985). Both the clock and Ogden scene were presented at midline of the subject's body. Patients were also administered a horizontal and vertical line bisection task, a standard line cancellation task, and the Bells test (Gauthier, Dehaut, & Joanette, 1989). These tasks were presented to the left (left body field), middle, and right (right body field) of midline of the subject's body. Also, patients were given a gap detection task (Ota, Fujii, Suzuki, Fukatsu, & Yamadori, 2001). In this test, a sheet of paper filled with 10 whole circles, 10 circles with gaps on the left, and 10 circles with gaps on the right was presented to the patient. Patients were instructed to cross out the circles with the gaps and to circle the full circles on the paper. This test was administered at midline of the patient's body.

The neglect battery was administered and scored by either a trained neuropsychology technician or one of the authors. Interrater reliability for scoring on 17 selected batteries was >99% over all subtests.

### Criteria for Impairment

For each task, the number of correct responses and the total number of stimuli were tabulated. Accuracy on each side of the page and/or stimulus was also recorded in order to distinguish between different types of USN. Because the canonical left side of the word/object is aligned with the left side of the stimulus when presented in canonical orientation, patients who neglect one side of each word/object could have either stimulus-centered or object-centered neglect. In order to disambiguate stimulus- from object-centered neglect, performance

with words presented in noncanonical orientations was examined. Error rates for each side of the stimulus (stimulus-centered reference frame) and each side of the canonical orientation of the word, namely, the initial and final letters (object-centered reference frame), were identified.

The following criteria were used to determine the frame of reference in which neglect was manifested. For each of the criteria listed in Table 1, significant differences between error rates in different conditions or on different sides of stimuli/objects were evaluated with Fisher's Exact Test.

Subjects were classified as having no neglect, neglect, or indeterminate neglect in each frame of reference. Subjects who made 0% to 5% errors on all criteria for each frame of reference were considered to have no neglect for that frame of reference. Patients with indeterminate neglect showed impaired performance (i.e., made >5% errors) on at least one neglect test, but did not demonstrate significantly more errors in contralesional space versus ipsilesional space in a specified reference frame on each task (see Table 1 for criteria). Significance was determined using Fisher's Exact Test, comparing performance in contralesional versus ipsilesional space in the specified reference frame on each task. Only patients who could be classified with neglect or no neglect in that frame of reference were included in the analysis for neglect in each coordinate frame.

### Imaging Protocol

The MR protocol included DWI, PWI, and conventional MRI (sagittal T1-weighted; axial fast spin-echo, axial T2-weighted; and axial FLAIR sequences). Scans were obtained on a GE Signa 1.5-Tesla echo-planar imaging (EPI) system (GE Healthcare, Chalfont St. Giles, UK), with whole-brain coverage and 5 mm slice thickness. DWI images were obtained using a multislice, isotropic, single-shot EPI sequence, with a  $B_{\max}$  of 1000 sec/mm<sup>2</sup>. Apparent diffusion coefficient maps were generated from the  $b = 1000$  and  $b = 0$  images in order to confirm the acuity of the DWI lesion. An infarcted region was defined as bright on DWI maps and dark on apparent diffusion coefficient maps. Single-shot, gradient-echo EPI perfusion images (repetition time [TR]/echo time [TE] = 2000/60 msec) were obtained with a 20-cc gadolinium-diethylenetriamine penta-acetic acid (Gd-DTPA) bolus, power injected at 5 cc/sec. Areas of hypoperfusion were identified by analysis of 20-color time-to-peak (TTP) maps, where each color change corresponds to a 2-sec range in tracer time to peak concentration for each voxel. Hypoperfusion was defined as areas of at least two color differences (at least a 4-sec delay in TTP) compared to the homologous region in the opposite hemisphere. Hypoperfusion defined in this manner has been shown to correspond to tissue dysfunction and functional deficits (Hillis, Wityk, et al., 2001; Neumann-Haefelin et al., 1999).

**Table 1.** Criteria for Impairment for Each Type of Neglect

---

*Criteria for impairment, viewer-centered neglect*

1. Significantly more errors on stimulus presentation in the left body field versus the right body field on at least one of the following tasks
  - a. Line cancellation
  - b. Gaps
  - c. Bells
  - d. Line bisection
2. AND/OR Significantly more errors on the left versus the right side of the page on at least one of these tasks administered at midline
  - a. Ogden scene
  - b. Gap detection task
  - c. Passage reading

*Criteria for impairment, stimulus-centered neglect*

1. Significantly more errors on the left versus the right side of the page on at least one of the following tasks, presented both at midline of the patient's body AND in at least one of the other body fields (LBF or RBF)
  - a. Line cancellation
  - b. Bells
2. AND/OR Significantly more errors on the left side of the stimulus versus the right side of the stimulus on at least one of the following tasks
  - a. Ogden scene (left side of objects in scene vs. right side of objects in scene)
  - b. Gap detection task (left side of circle vs. right side of circle)
  - c. Sentence reading (left side of word vs. right side of word)
  - d. Gaps


*Criteria for impairment, object-centered neglect*

1. Significantly more errors on the contralesional side versus the ipsilesional side of the canonical representation of words in the vertical word reading task
  2. AND/OR Significantly more errors on the contralesional side versus the ipsilesional side of words in single word reading AND in mirror-reversed word reading
  3. AND/OR Significantly more errors on the contralesional side versus the ipsilesional side of words in recognition of oral spelling
-

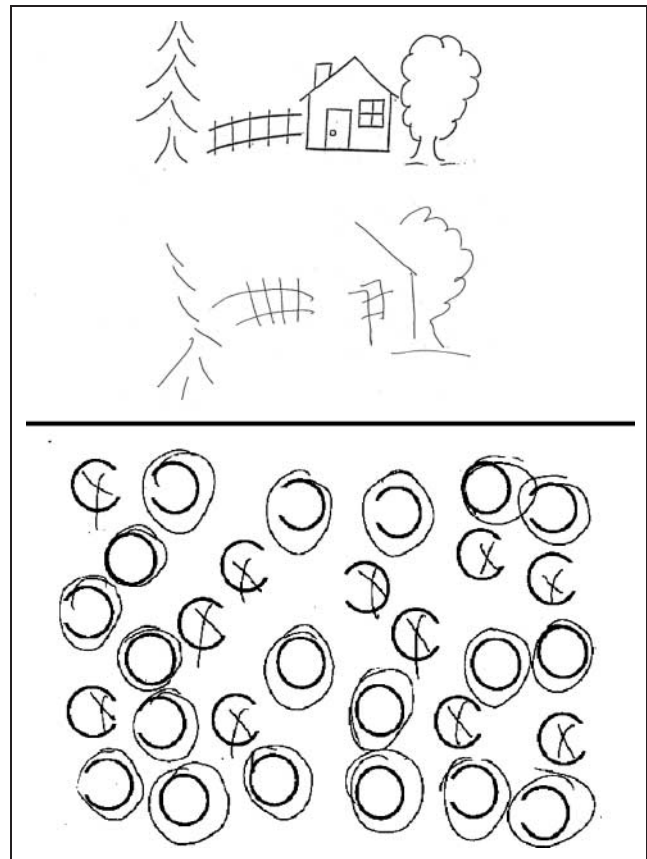
## Data Analysis

A brain region was labeled as dysfunctional if it was hypoperfused (PWI), infarcted (DWI), or both. We performed voxelwise analyses of the association between each type of neglect, and infarction and/or hypoperfusion of brain regions using voxelwise Fisher's Exact Test. Information about the location of the infarcted region was registered on a three-dimensional brain atlas concordant with the Montreal Neurological Institute (MNI) atlas in order to compute voxelwise statistics across subjects. Using MRICro ([www.sph.sc.edu/comd/rorden/mricro.html](http://www.sph.sc.edu/comd/rorden/mricro.html)), a trained technician or neurologist drew ROIs onto the atlas. Binary ROIs created by adding information from restricted diffusion and low perfusion ROIs/hypoperfusion were analyzed using Brain Image Database (BRAID; [sbia.uphs.upenn.edu/braid/](http://sbia.uphs.upenn.edu/braid/)).

We then used these ROIs to analyze what brain regions are associated with neglect in various subtypes. First, Brodmann's areas were delineated using MRICro, and a region was classified as dysfunctional if more than 25% of voxels in that region were infarcted and/or hypoperfused. We then used stepwise linear regression analyses to identify those Brodmann's areas where dysfunction independently predicted each subtype of neglect. Second, we created Fisher's Exact maps to reveal voxels where ischemia on DWI and PWI lesions were



**Figure 2.** Examples of performance on the Ogden scene copying task (top) and the gaps task (bottom) illustrating egocentric (viewer-centered) neglect.



**Figure 3.** Examples of performance on the Ogden scene copying task (top) and the gaps task (bottom) illustrating allocentric left neglect (in patients with stimulus-centered neglect).

associated with viewer-, stimulus-, and object-centered neglect, to visualize more precise areas within these Brodmann's areas, as well as subcortical regions that were critical for computing spatial representations in each reference frame.

## RESULTS

Thirty-two patients met criteria for only viewer-centered neglect, 108 patients met criteria for no viewer-centered neglect, and 19 patients met neither criteria for presence or absence of viewer-centered neglect (and thus were recorded as "indeterminate" for this type of neglect; see Figure 2 for examples of patient performance showing viewer-centered neglect). Seven patients met criteria for only stimulus-centered neglect, whereas 122 patients met criteria for no stimulus-centered neglect and 29 patients were indeterminate for stimulus-centered neglect. Figure 3 shows examples of performance by patients with stimulus-centered neglect. Five patients demonstrated only object-centered neglect, 79 subjects met criteria for no object-centered neglect, and 86 subjects were indeterminate for object-centered neglect (e.g., showed no significant difference between the canonical right and left sides of the objects/words in vertical and mirror-reverses

reading, spelling, and recognition of orally spelled words, but made >5% total errors on these tasks). Twelve subjects demonstrated both viewer- and stimulus-centered neglect, and one subject showed both stimulus- and object-centered neglect; these subjects were excluded from our analyses below.

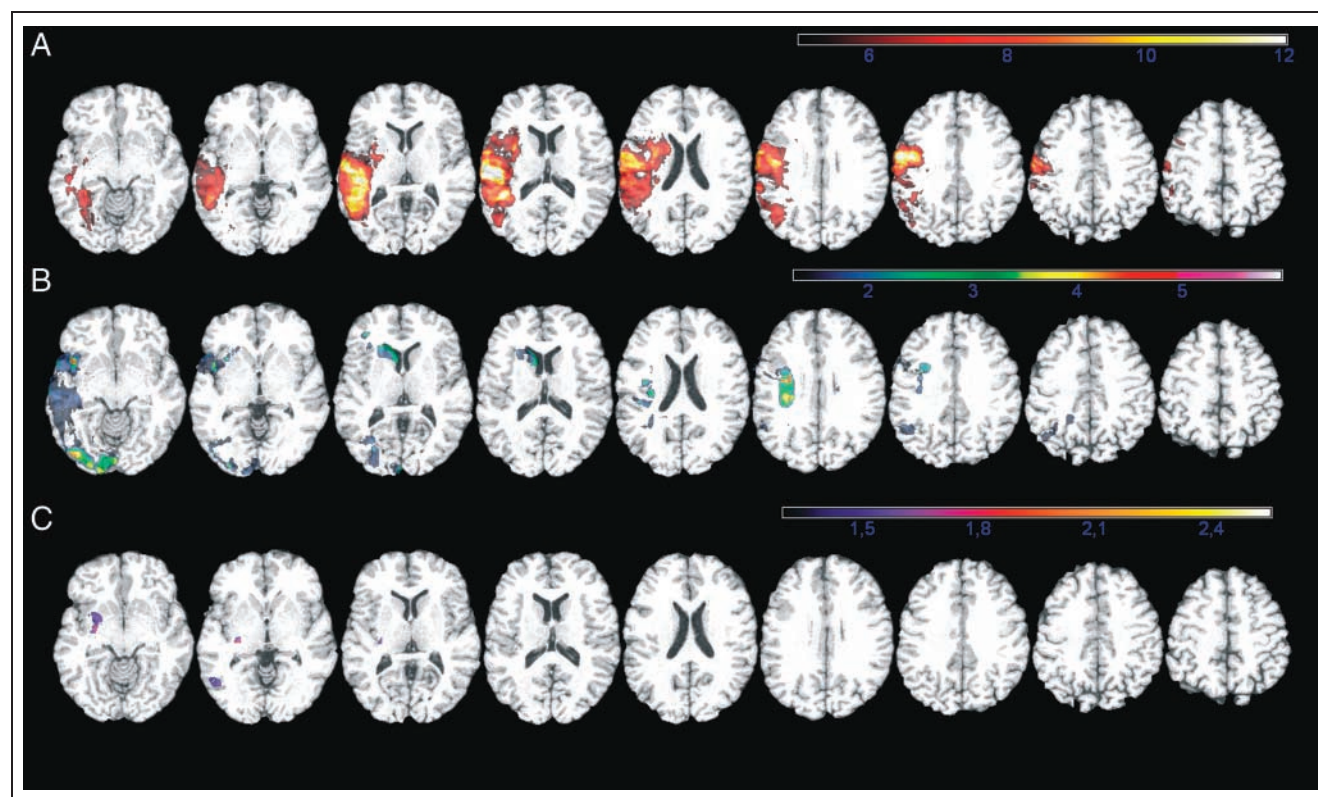
A stepwise linear regression analysis (criteria: probability-of- $F$ -to-enter < .05, probability-of- $F$ -to-remove > .10) was performed in order to account for the areas of hypoperfusion and/or infarct that predicted different subtypes of neglect. The regression model with the best-fitting coefficients ( $r = .22, p = .016$ ) for viewer-centered neglect was: BA 40 (.128) + constant (.032). For stimulus-centered neglect, the regression model with the best-fitting coefficients ( $r = .53, p < .0001$ ) was: BA 37 (.294) – BA 20 (.223) + constant (.002). There were too few subjects to identify areas significantly associated with object-centered neglect. Collinearity diagnostics confirmed that the independent variables were not strongly correlated with one another. Values of the variance inflation factor <0.01 or >10 would indicate significant problems with collinearity in the model. The highest variance inflation factor for included variables was 1.29 and for excluded variables was 1.77.

We also performed voxelwise analyses in order to visualize brain regions that are associated with different neglect subtypes. Figure 4 displays the brain regions that are associated with different subtypes of neglect. Viewer-

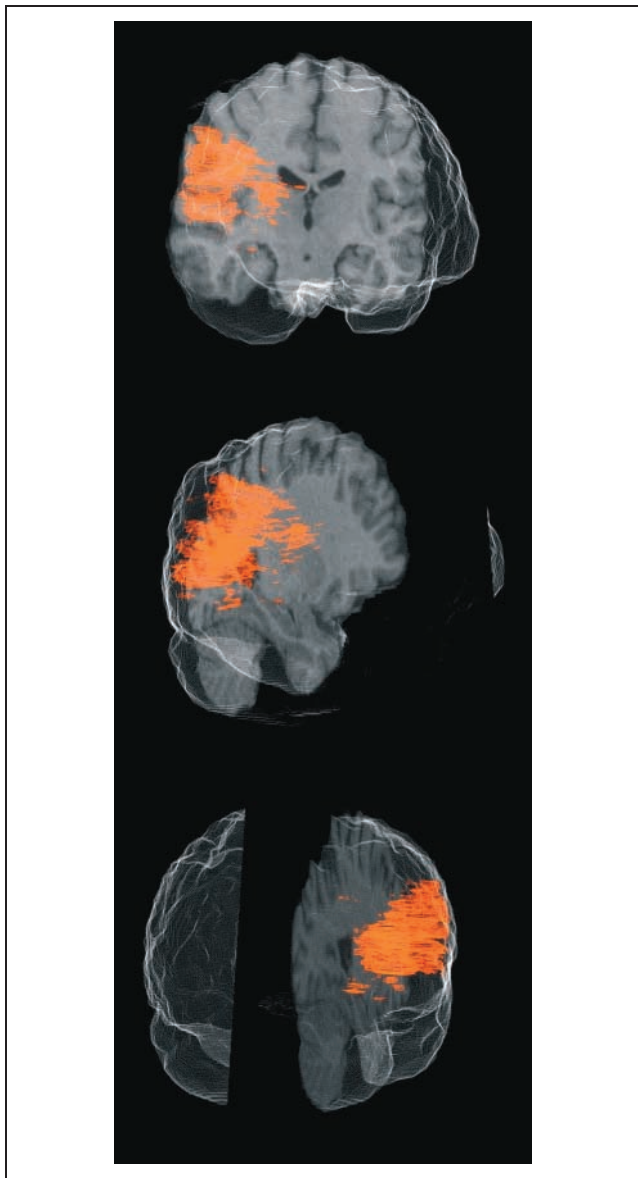
centered neglect was associated with hypoperfusion and/or infarct of voxels within right fronto-parietal cortex, including the precentral and supramarginal gyrus (BA 40). Furthermore, this region associated with viewer-centered neglect extends ventrally into both the superior temporal (BA 22) and MTG (see Figure 5). Stimulus-centered neglect was associated with hypoperfusion/infarct of the right inferior occipital gyrus, primary visual cortex, right posterior inferior temporal gyrus, as well as the right caudate nucleus, and small regions of the right inferior frontal and middle frontal gyri. Object-centered neglect was associated with hypoperfusion and/or infarct of posterior middle and inferior temporal cortex (BA 37) and posterior insula.

## DISCUSSION

Using PWI and DWI, we have identified brain regions that are associated with specific types of neglect after acute, right supratentorial ischemic stroke, before significant poststroke reorganization and recovery have taken place. Functional inactivation of the right supramarginal gyrus (BA 40) was most predictive of viewer-centered neglect, whereas functional inactivation of posterior inferior temporal (BA 37) and lateral occipital areas (BA 19) was most predictive of stimulus-centered neglect. Furthermore, object-centered neglect was also associated with posterior middle/inferior temporal regions (BA 37).



**Figure 4.** Voxels that are significantly associated (via Fisher's Exact Test) with viewer-centered (A), stimulus-centered (B), and object-centered (C) neglect. Color intensity corresponds to  $-\log(p)$  of the Fisher's Exact Test value.



**Figure 5.** Three-dimensional rendering of the region associated with viewer-centered neglect.

In previous localization studies, the supramarginal gyrus has often been implicated as a region associated with USN (Maguire & Ogden, 2002; Leibovitch et al., 1999; Vallar & Perani, 1986). Our results, showing that the supramarginal gyrus is highly associated with viewer-centered neglect, support these earlier studies. Furthermore, subjects with acute subcortical stroke affecting the right supramarginal gyrus have also demonstrated viewer-centered neglect (Hillis et al., 2005). In our previous study, we also found a significant relationship between viewer-centered neglect and angular hypoperfusion, which was not confirmed in the present study. A possible explanation for the discordant findings (that angular gyrus hypoperfusion was a significant predictor of viewer-centered neglect in the 2005 study and not in this study) is the following. Patients in the current study had larger strokes on average, and so a

greater percentage of the 171 subject dataset, compared to the 50 subcortical subjects in Hillis et al. (2005) who had angular hypoperfusion/infarct, also had supramarginal gyrus hypoperfusion. Conversely, there was a greater percentage of cases of supramarginal hypoperfusion without angular hypoperfusion among the 50 subcortical strokes than in this dataset, thus making it more likely that those two areas were independent predictors in a regression analysis. If this is correct, then angular gyrus dysfunction is associated with viewer-centered neglect, but we failed to identify the independent association with regression analysis in the current study because too few patients had hypoperfusion/infarct of just the angular gyrus (without the supramarginal gyrus).

Our results also reveal that hypoperfusion/infarct of primary sensory and motor areas, and STG and MTG are associated with viewer-centered neglect. It is possible that these regions, in addition to the supramarginal gyrus, are involved in viewer-centered (egocentric) processing. In the linear regression analysis, only hypoperfusion/infarct of the right supramarginal gyrus was independently predictive of viewer-centered neglect, whereas our voxel-based analysis shows additional areas of hypoperfusion/infarct that are associated with only viewer-centered neglect. These other regions implicated in the voxel-based analysis (e.g., right BA 22) may have no independent contribution to predicting viewer-centered neglect; they might show an association because they are in the same vascular distribution as the right supramarginal gyrus.

The posterior inferior parietal lobule (IPL), which includes both the supramarginal and angular gyri, is part of the dorsal stream of visual processing, which is involved in perception for action (Goodale & Milner, 1992). Areas responsible for vision for action encode space in egocentric reference frames. Therefore, it makes sense that tissue dysfunction in this region would impair egocentric (viewer-centered) spatial representation or processing. Additional evidence that neurons in this region are important for egocentric spatial processing comes from electrophysiological studies in primates (Andersen, Bracewell, Barash, Gnadt, & Fogassi, 1990) and some fMRI studies (Galati et al., 2000; Vallar et al., 1999), as briefly reviewed later.

We found that hypoperfusion and/or infarct of posterior middle and inferior temporal cortex (BA 37) was predictive of stimulus-centered neglect. Furthermore, our voxel-based analyses showed an association between stimulus-centered neglect and hypoperfusion/infarct of the right posterior inferior temporal gyrus and right lateral occipital cortex. The posterior inferior temporal gyrus and lateral occipital cortex are both part of the ventral stream of the visual system (Goodale & Milner, 1992). Left and right BA 37 are involved in object recognition (Stewart, Meyer, Frith, & Rothwell, 2001), and lateral occipital cortex is object selective, involved in perception of object shape and object recognition (Kourtzi & Kanwisher, 2001). Our results suggest that attention to



and/or processing of the contralesional side of stimulus-centered representations is disrupted by damage to these regions, resulting in stimulus-centered neglect.

Previous lesion analyses have implicated the temporal lobe in USN (STG: Karnath et al., 2005; Karnath, 2001; Karnath, Ferber, & Himmelbach, 2001; MTG: Mort et al., 2003; Samuelsson et al., 1997). More specifically, studies examining the neural correlates of specific subtypes of neglect have implicated various parts of the ventral stream of visual processing in allocentric neglect (Kleinman et al., 2007; Hillis et al., 2005). Similarly, using a lesion overlap approach in subjects with right hemisphere stroke, Grimsen, Hildebrandt, and Fahle (2008) found ventromedial temporal damage to be related to allocentric deficits in a modified visual search task. There are also case reports in the literature of subjects with temporal damage and allocentric neglect. For example, Ota et al. (2003) report an individual who, after a right occipito-temporal posterior cerebral artery stroke demonstrated stimulus-centered neglect. The subject then suffered a second stroke which infarcted IPL, and then demonstrated viewer-centered neglect (see also Grossi, Esposito, Cuomo, Conchiglia, & Trojano, 2007; Hillis & Caramazza, 1995).

Evidence that processing within different frames of reference takes place in distinct neural substrates comes from primate single-cell recording studies. Neurons in the PPC of macaque monkeys respond in different viewer-centered frames of reference. Duhamel, Bremner, BenHamed, and Graf (1997) reported that some neurons in the ventral intraparietal area of the macaque monkey encode space in a retina-centered frame of reference, whereas other ventral intraparietal area neurons encode space in a head-centered frame of reference (Brotchie, Andersen, Snyder, & Goodman, 1995; Andersen et al., 1990). Other neurons respond in a stimulus-centered frame of reference. Olson and Gettner (1995) trained macaques on a task designed to dissociate stimulus-centered eye movements from retina-centered eye movements. Neurons in the supplementary eye fields were found that coded for stimulus-centered movements. Other studies have implicated neurons in the temporal lobe and dorso-lateral prefrontal cortex for stimulus-based vision and attention (see Olson, 2001 for a review).

Functional imaging has also been utilized to understand the neural locus of different frames of reference in human visual processing. Fink, Dolan, Halligan, Marshall, and Frith (1997) proposed that visual attention is dissociable into attention to location ("space-based" or viewer-centered) and attention to object structure (stimulus- or object-based). To examine the neural correlates of these types of attention, subjects in this PET study fixated the end of line segments presented to either the left or the right of the center of the screen. Subjects were instructed to judge the location of a box on a line with respect to either the center of the screen (space-based) or the center of the line (stimulus- or object-based).

The positions were selected to distinguish between a space-centered frame of reference (left or right of the center of the screen) and an object-centered frame of reference (left or right side of the line). Fink et al. found increased activation for stimulus- or object-based attention in this task in left striate and prestriate cortex, whereas space-based attention in this task activated right prefrontal cortex and inferior temporal-occipital cortex.

Results from a PET study designed to distinguish locations of neural activation associated with object-centered and viewer-centered processing yielded results consistent with our voxel-based analysis of right hemisphere regions associated with each neglect type (Honda, Wise, Weeks, Deiber, & Hallett, 1998). Neurologically intact subjects moved a joy stick to indicate the location of a target in object/stimulus-centered coordinates (within objects on either side of a screen) or in viewer-centered coordinates (location on the screen). In both a visuomotor task and a matching to sample task, activation of bilateral occipito-temporal cortex and left superior occipital cortex was associated with object-centered processing, and right PPC, as well as left posterior frontal (motor and premotor) regions, was associated with viewer-centered decisions. In our study, we did not evaluate left hemisphere regions. However, in a previous study of neglect after left hemisphere stroke in right-handed individuals, Kleinman et al. (2007) reported more allocentric neglect than egocentric neglect after left hemisphere stroke, particularly in patients with left inferior temporal/occipital regions, consistent with the report of left occipital activation in addition to bilateral occipito-temporal activation associated with object-centered processing in the Honda et al. (1998) study. It is plausible that the left hemisphere is more critical for object-centered spatial representations because of its role in naming, reading, and spelling, which all require object-centered processing. In contrast, egocentric neglect is more common than allocentric neglect after right hemisphere stroke (in this and previous studies), consistent with a specialized role of the right hemisphere in representing locations of objects with respect to the viewer in egocentric space.

Galati et al. (2000) asked subjects in an fMRI task to judge the location of a stimulus based on either their own position or the position of the object. Horizontal lines bisected with a vertical line were presented to the subjects. The subjects were asked to judge whether the vertical line was to the left or right of either the mid-sagittal plane of the subjects' body (egocentric) or the midpoint of the horizontal line. Coding in egocentric coordinates coincided with activation of a bilateral fronto-parietal network with primarily right hemisphere activation. Allocentric coding coincided with less extensive activation of only right hemisphere fronto-parietal regions. The bilateral fronto-parietal network implicated in egocentric coding was also evident in fMRI studies that examined encoding of body-centered coordinates (Galati,

Committeri, Sanes, & Pizzamiglio, 2001), whereas allocentric spatial judgments involved activation in ventrolateral occipital–temporal cortex (Committeri et al., 2004).

Functional imaging studies show brain regions that are active for egocentric and allocentric encoding. PET and fMRI studies may identify regions that are active during a particular task, but may not be necessary for the task or function being studied. That is, activation studies do not inform us as to regions that are *essential* for visuospatial processing in different frames of reference. In order to identify essential regions, one must observe task performance after damage to the area. If performance is unimpaired when the region is damaged or dysfunctional, then the region is not essential for the task. Conversely, impairment following damage (or hypoperfusion) to a brain region shows that some of the compromised brain region is essential for the task. Thus, our results complement the functional imaging results by showing that many of the regions that show activation in association with either object-centered or viewer-centered processing in normal subjects are, in fact, essential for that type of processing.

Interestingly, we also found a relationship between infarct of right caudate nucleus and stimulus-centered neglect. Right caudate nucleus has been associated with neglect in previous studies (Karnath, Himmelbach, & Rorden, 2002; Kumral, Evyapan, & Balkir, 1999). In rhesus monkeys, there are a variety of connections between the caudate nucleus and the ventral stream of visual processing, including inferotemporal cortex (Saint-Cyr, Ungerleider, & Desimone, 1990) and STG (Yeterian & Pandya, 1998), a region previously associated with stimulus-centered neglect (Hillis et al., 2005). We can speculate that the association between damage/infarct to right caudate nucleus and stimulus-centered neglect is due to projections between the caudate nucleus and regions dedicated to allocentric processing. However, we did not find an association between any subcortical structure and either egocentric or allocentric neglect in our previous study of 50 patients with purely subcortical stroke (Hillis et al., 2005). Future studies using diffusion tensor imaging and tractography to identify disruptions in specific white matter tracts are needed to test this hypothesis.

Our voxel-based analysis showed that hypoperfusion and/or infarct of primary visual cortex is also associated with stimulus-centered neglect. One explanation of this result is that our subjects with stimulus-centered neglect had hemianopia rather than neglect. However, this explanation seems unlikely as subjects were allowed to freely move their heads and change their point of fixation during the experiment. Subjects with homonymous hemianopia and no neglect perform as well as controls on neglect tasks, due to their intact ability to move and orient to relevant locations and stimuli (see SWR; Hillis et al., 1998). We have observed this compensation for acute homonymous hemianopia even in the first 48 hr of stroke onset. We therefore believe that

it is more likely that damage to primary visual cortex is coincident with damage to BA 37, due to shared vascular distribution, or that it is important for object-centered processing as indicated by the PET study by Honda et al. (1998).

Our results suggest a distinction between stimulus-centered and object-centered neglect, with object-centered neglect associated with more anterior and superior damage within occipito-temporal cortex compared to stimulus-centered neglect. In object-centered neglect, subjects fail to respond to the contralesional side of an object based on its canonical orientation, whereas in stimulus-centered neglect, subjects fail to respond to the contralesional side of the object with right and left defined by the viewer. Neurons near the end of the ventral stream (inferotemporal cortex) of macaques respond to objects regardless of their orientation or location (Gross, Rocha-Miranda, & Bender, 1972). Our data suggest that object-centered neglect is associated with a more anterior location of dysfunction within occipito-temporal cortex than stimulus-centered neglect. This may reflect increased viewpoint-independent processing farther down the ventral stream.

Object-centered neglect is far less common than viewer- or stimulus-centered neglect, as observed in our study and the case literature. Although the reason is not entirely clear, object-centered neglect also seems to occur mostly in left-handed patients (Hillis & Caramazza, 1995).

Using evidence from subjects with neglect and other domains, various parts of the ventral stream have been implicated in allocentric processing. It is possible that these regions are all generally involved in attending to stimulus/object representations, or that each subregion contributes in a different manner to representing or attending to object representations. Unfortunately, the tests presented to subjects in our study do not aid in differentiating between deficits in representing versus allocating attention to the contralesional side of a stimulus, or other distinctions. It is possible that different regions in the ventral stream may be dedicated to different processes that, when disrupted, all lead subjects to fail to respond to the contralesional side of stimuli. We cannot make claims regarding how various parts of the ventral stream are involved in the representing and attending to objects, given current evidence from lesion–behavior analyses. However, the evidence from this and other studies support the general hypothesis that egocentric neglect is associated with tissue dysfunction in parietal regions in the dorsal stream of visual processing, whereas allocentric (both stimulus- and object-centered) neglect is associated with tissue dysfunction within the ventral stream of visual processing.

### Acknowledgments

The research reported in this article was supported by NIH R01 NS047691 to A. H.

Reprint requests should be sent to Jared Medina, 3 West Gates, Department of Neurology, Hospital of the University of Pennsylvania, or via e-mail: jared.medina@uphs.upenn.edu.

## REFERENCES

- Andersen, R. A., Bracewell, R. M., Barash, S., Gnadt, J. W., & Fogassi, L. (1990). Eye position effects on visual, memory, and saccade-related activity in areas lip and 7a of macaque. *Journal of Neuroscience*, *10*, 1176–1196.
- Arguin, M., & Bub, D. N. (1993). Evidence for an independent stimulus-centered spatial reference frame from a case of visual hemineglect. *Cortex*, *29*, 349–357.
- Baxter, D. M., & Warrington, E. K. (1983). Neglect dysgraphia. *Journal of Neurology, Neurosurgery, and Psychiatry*, *46*, 1073–1078.
- Beaulieu, C., de Crespigny, A., Tong, D. C., Moseley, M. E., Albers, G. W., & Marks, M. P. (1999). Longitudinal magnetic resonance imaging study of perfusion and diffusion in stroke: Evolution of lesion volume and correlation with clinical outcome. *Annals of Neurology*, *46*, 568–578.
- Behrmann, M., & Tipper, S. P. (1999). Attention accesses multiple reference frames: Evidence from visual neglect. *Journal of Experimental Psychology: Human Perception and Performance*, *25*, 83–101.
- Bisiach, E., Capitani, E., & Porta, E. (1985). Two basic properties of space representation in the brain: Evidence from unilateral neglect. *Journal of Neurology, Neurosurgery, and Psychiatry*, *48*, 141–144.
- Brochic, P. R., Andersen, R. A., Snyder, L. H., & Goodman, S. J. (1995). Head position signals used by parietal neurons to encode locations of visual-stimuli. *Nature*, *375*, 232–235.
- Committeri, G., Galati, G., Paradis, A. L., Pizzamiglio, L., Berthoz, A., & LeBihan, D. (2004). Reference frames for spatial cognition: Different brain areas are involved in viewer-, object-, and landmark-centered judgments about object location. *Journal of Cognitive Neuroscience*, *16*, 1517–1535.
- Driver, J., & Halligan, P. W. (1991). Can visual neglect operate in object-centered coordinates—An affirmative single-case study. *Cognitive Neuropsychology*, *8*, 475–496.
- Duhamel, J. R., Bremner, F., BenHamed, S., & Graf, W. (1997). Spatial invariance of visual receptive fields in parietal cortex neurons. *Nature*, *389*, 845–848.
- Ellis, A. W., Flude, B. M., & Young, A. W. (1987). Neglect dyslexia and the early visual processing of letters in words and nonwords. *Cognitive Neuropsychology*, *4*, 439–464.
- Fink, G. R., Dolan, R. J., Halligan, P. W., Marshall, J. C., & Frith, C. D. (1997). Space-based and object-based visual attention: Shared and specific neural domains. *Brain*, *120*, 2013–2028.
- Fisher, M. (1995). Diffusion and perfusion imaging for acute stroke. *Surgical Neurology*, *43*, 606–609.
- Fisher, M., & Albers, G. W. (1999). Applications of diffusion-perfusion magnetic resonance imaging in acute ischemic stroke. *Neurology*, *52*, 1750–1756.
- Galati, G., Committeri, G., Sanes, J. N., & Pizzamiglio, L. (2001). Spatial coding of visual and somatic sensory information in body-centred coordinates. *European Journal of Neuroscience*, *14*, 737–746.
- Galati, G., Lobel, E., Vallar, G., Berthoz, A., Pizzamiglio, L., & Le Bihan, D. (2000). The neural basis of egocentric and allocentric coding of space in humans: A functional magnetic resonance study. *Experimental Brain Research*, *133*, 156–164.
- Gauthier, L., Dehaut, F., & Joanette, Y. (1989). The bells test—A quantitative and qualitative test for visual neglect. *International Journal of Clinical Neuropsychology*, *11*, 49–54.
- Goodale, M. A., & Milner, A. D. (1992). Separate visual pathways for perception and action. *Trends in Neurosciences*, *15*, 20–25.
- Grimsen, C., Hildebrandt, H., & Fahle, M. (2008). Dissociation of egocentric and allocentric coding of space in visual search after right middle cerebral artery stroke. *Neuropsychologia*, *46*, 902–914.
- Gross, C. G., Rocha-Miranda, C. E., & Bender, D. B. (1972). Visual properties of neurons in inferotemporal cortex of macaque. *Journal of Neurophysiology*, *35*, 96–111.
- Grossi, D., Esposito, D., Cuomo, C., Conchiglia, G., & Trojano, L. (2007). Object-based neglect for the near peripersonal space in drawing tasks. *European Journal of Neurology*, *14*, 933–936.
- Heilman, K. M., Watson, R. T., & Valenstein, E. (1993). Neglect and related disorders. In K. M. Heilman & E. Valenstein (Eds.), *Clinical neuropsychology* (pp. 279–336). London: Oxford University Press.
- Heilman, K. M., Watson, R. T., Valenstein, E., & Damasio, A. R. (1983). Localization of lesions in neglect. In A. Kertesz (Ed.), *Localization in neuropsychology* (pp. 471–492). New York: Academic Press.
- Hillis, A. E., & Caramazza, A. (1995). A framework for interpreting distinct patterns of hemispatial neglect. *Neurocase*, *1*, 189–207.
- Hillis, A. E., Kane, A., Barker, P., Beauchamp, N., Gordon, B., & Wityk, R. (2001). Neural substrates of the cognitive processes underlying reading: Evidence from magnetic resonance perfusion imaging in hyperacute stroke. *Aphasiology*, *15*, 919–931.
- Hillis, A. E., Newhart, M., Heidler, J., Barker, P. B., Herskovits, E. H., & Degaonkar, M. (2005). Anatomy of spatial attention: Insights from perfusion imaging and hemispatial neglect in acute stroke. *Journal of Neuroscience*, *25*, 3161–3167.
- Hillis, A. E., Rapp, B., Benzing, L., & Caramazza, A. (1998). Dissociable coordinate frames of unilateral spatial neglect: “Viewer-centered” neglect. *Brain and Cognition*, *37*, 491–526.
- Hillis, A. E., Wityk, R. J., Barker, P. B., Beauchamp, N. J., Gailloud, P., Murphy, K., et al. (2002). Subcortical aphasia and neglect in acute stroke: The role of cortical hypoperfusion. *Brain*, *125*, 1094–1104.
- Hillis, A. E., Wityk, R. J., Tuffiash, E., Beauchamp, N. J., Jacobs, M. A., Barker, P. B., et al. (2001). Hypoperfusion of Wernicke’s area predicts severity of semantic deficit in acute stroke. *Annals of Neurology*, *50*, 561–566.
- Honda, M., Wise, S. P., Weeks, R. A., Deiber, M. P., & Hallett, M. (1998). Cortical areas with enhanced activation during object-centred spatial information processing—A PET study. *Brain*, *121*, 2145–2158.
- Jenkins, W. M., & Merzenich, M. M. (1987). Reorganization of neocortical representations after brain injury: A neurophysiological model of the bases of recovery from stroke. In F. J. Seil, E. Herbert, & B. M. Carlson (Eds.), *Progress in brain research* (pp. 249–266). Amsterdam: Elsevier.
- Karnath, H. O. (2001). New insights into the functions of the superior temporal cortex. *Nature Reviews Neuroscience*, *2*, 568–576.
- Karnath, H. O., Ferber, S., & Himmelbach, M. (2001). Spatial awareness is a function of the temporal not the posterior parietal lobe. *Nature*, *411*, 950–953.
- Karnath, H. O., Himmelbach, M., & Rorden, C. (2002). The subcortical anatomy of human spatial neglect: Putamen, caudate nucleus and pulvinar. *Brain*, *125*, 350–360.

- Karnath, H. O., Schenkel, P., & Fischer, B. (1991). Trunk orientation as the determining factor of the contralateral deficit in the neglect syndrome and as the physical anchor of the internal representation of body orientation in space. *Brain, 114*, 1997–2014.
- Karnath, H. O., Zopf, R., Johannsen, L., Berger, M. F., Nagele, T., & Klose, U. (2005). Normalized perfusion MRI to identify common areas of dysfunction: Patients with basal ganglia neglect. *Brain, 128*, 2462–2469.
- Kleinman, J. T., Newhart, M., Davis, C., Heidler-Gary, J., Gottesman, R. F., & Hillis, A. E. (2007). Right hemispatial neglect: Frequency and characterization following acute left hemisphere stroke. *Brain and Cognition, 64*, 50–59.
- Kourtzi, Z., & Kanwisher, N. (2001). Representation of perceived object shape by the human lateral occipital complex. *Science, 293*, 1506–1509.
- Kumral, E., Evyapan, D., & Balkir, K. (1999). Acute caudate vascular lesions. *Stroke, 30*, 100–108.
- Ladavas, E. (1987). Is the hemispatial deficit produced by right parietal lobe damage associated with retinal or gravitational coordinates. *Brain, 110*, 167–180.
- Leibovitch, F. S., Black, S. E., Caldwell, C. B., Ebert, P. L., Ehrlich, L. E., & Szalai, J. P. (1998). Brain-behavior correlations in hemispatial neglect using CT and SPECT—The Sunnybrook Stroke Study. *Neurology, 50*, 901–908.
- Leibovitch, F. S., Black, S. E., Caldwell, C. B., McIntosh, A. R., Ehrlich, L. E., & Szalai, J. P. (1999). Brain SPECT imaging and left hemispatial neglect covaried using partial least squares: The Sunnybrook Stroke Study. *Human Brain Mapping, 7*, 244–253.
- Maguire, A. M., & Ogden, J. A. (2002). MRI brain scan analyses and neuropsychological profiles of nine patients with persisting unilateral neglect. *Neuropsychologia, 40*, 879–887.
- Marr, D. (1982). *Vision*. New York: Freeman.
- Miceli, G., & Capasso, R. (2001). Word-centred neglect dyslexia: Evidence from a new case. *Neurocase, 7*, 221–237.
- Monk, A. F. (1985). Theoretical note: Coordinate systems in visual word recognition. *Quarterly Journal of Experimental Psychology, 37A*, 613–625.
- Mort, D. J., Malhotra, P., Mannan, S. K., Rorden, C., Pambakian, A., Kennard, C., et al. (2003). The anatomy of visual neglect. *Brain, 126*, 1986–1997.
- Neumann-Haefelin, T., Wittsack, H. J., Wenserski, F., Siebler, M., Seitz, R. J., Modder, U., et al. (1999). Diffusion- and perfusion-weighted MRI—The DWI/PWI mismatch region in acute stroke. *Stroke, 30*, 1591–1597.
- Ogden, J. A. (1985). Contralateral neglect of constructed visual images in right and left brain-damaged patients. *Neuropsychologia, 23*, 273–277.
- Olson, C. R. (2001). Object-based vision and attention in primates. *Current Opinion in Neurobiology, 11*, 171–179.
- Olson, C. R., & Gettner, S. N. (1995). Object-centered direction selectivity in the macaque supplementary eye field. *Science, 269*, 985–988.
- Ota, H., Fujii, T., Suzuki, K., Fukatsu, R., & Yamadori, A. (2001). Dissociation of body-centered and stimulus-centered representations in unilateral neglect. *Neurology, 57*, 2064–2069.
- Ota, H., Fujii, T., Tabuchi, M., Sato, K., Saito, J., & Yamadori, A. (2003). Different spatial processing for stimulus-centered and body-centered representations. *Neurology, 60*, 1846–1848.
- Saint-Cyr, J. A., Ungerleider, L. G., & Desimone, R. (1990). Organization of visual cortical inputs to the striatum and subsequent outputs to the pallidum complex in the monkey. *Journal of Comparative Neurology, 298*, 129–156.
- Samuëlsson, H., Jensen, C., Ekholm, S., Naver, H., & Blomstrand, C. (1997). Anatomical and neurological correlates of acute and chronic visuospatial neglect following right hemisphere stroke. *Cortex, 33*, 271–285.
- Stewart, L., Meyer, B. U., Frith, U., & Rothwell, J. (2001). Left posterior BA37 is involved in object recognition: A TMS study. *Neuropsychologia, 39*, 1–6.
- Stone, S. P., Patel, P., Greenwood, R. J., & Halligan, P. W. (1992). Measuring visual neglect in acute stroke and predicting its recovery—The visual neglect recovery index. *Journal of Neurology, Neurosurgery, and Psychiatry, 55*, 431–436.
- Subbiah, I., & Caramazza, A. (2000). Stimulus-centered neglect in reading and object recognition. *Neurocase, 6*, 13–31.
- Vallar, G., Bottini, G., & Paulesu, E. (2003). Neglect syndromes: The role of the parietal cortex. *Advances in Neurology, 93*, 293–319.
- Vallar, G., Lobel, E., Galati, G., Berthoz, A., Pizzamiglio, L., & Le Bihan, D. (1999). A fronto-parietal system for computing the egocentric spatial frame of reference in humans. *Experimental Brain Research, 124*, 281–286.
- Vallar, G., & Perani, D. (1986). The anatomy of unilateral neglect after right-hemisphere stroke lesions—A clinical CT-scan correlation study in man. *Neuropsychologia, 24*, 609–622.
- Warach, S., Dashe, J. F., & Edelman, R. R. (1996). Clinical outcome in ischemic stroke predicted by early diffusion-weighted and perfusion magnetic resonance imaging: A preliminary analysis. *Journal of Cerebral Blood Flow and Metabolism, 16*, 53–59.
- Yeterian, E. H., & Pandya, D. N. (1998). Corticostriatal connections of the superior temporal region in rhesus monkeys. *Journal of Comparative Neurology, 399*, 384–402.