

& Agid, 1995) or the role of M1 was not clarified as the location of the lesions was not precisely established (Mutsaerts, Steenbergen, & Bekkering, 2007; Johnson, 2000).

The apparent inconsistency among the various imaging studies might depend on how participants performed the task (Kosslyn, Thompson, Wraga, & Alpert, 2001) on the kind of stimuli to which participants were exposed before the imagination task (Wraga, Thompson, Alpert, & Kosslyn, 2003) or the choice of stimuli because stimuli other than body parts may lead to sensorimotor activation (Carpenter, Just, Keller, Eddy, & Thulborn, 1999; Cohen et al., 1996; Tagaris et al., 1996; but see Tomasino, Borroni, et al., 2005; Kosslyn et al., 1998).

In the present study, we investigated whether the involvement of the sensorimotor region in MR depends on the stimulus type (body vs. nonbody parts) or on the cognitive strategy (motor vs. visuospatial) used to solve the task. To ascertain whether the activation of the motor cortex is bottom-up or top-down, we assessed the ability of neurosurgical patients to imagine rotational movements. Patients had focal lesions at the border of the primary motor and somatosensory cortex, selectively affecting or sparing hand representation (hereafter HA- and HA+, respectively). With this methodology, it is possible to establish the causal role of the motor cortex hand area in mental simulation and consequently to rule out the alternative explanations mentioned earlier.

In Experiment 1, patients and controls performed the same task that was employed in a previous TMS study (Tomasino, Borroni, et al., 2005). Participants were presented with pictures of two rotated hands or letters and had to decide whether the stimuli were the identical or the mirror images. This task is solved by mental simulation as the response times increase linearly with the angular disparity between the stimuli as it would if the object were being physically rotated (Shepard & Metzler, 1971). If sensorimotor involvement is stimulus driven (i.e., the bottom-up hypothesis), then a lesion involving the hand sensorimotor representation should disrupt simulation of hand (Parsons, 1987b; Sekiyama, 1982) but not of letter rotational movements (Tomasino, Borroni, et al., 2005).

In Experiment 2, we tested the alternative hypothesis, that is, that sensorimotor activation may be induced top-down, depending on the cognitive strategy. Here patients and controls were instructed to imagine rotational movements of hands and nonbody part stimuli by using motor or visual imagery-based mental transformations (Tomasino & Rumiati, 2004). If the *type of strategy* is the critical factor in recruiting the sensorimotor cortex, then patients would exhibit a selective deficit when solving the task with motor simulation (Kosslyn et al., 2001), irrespective of the type of stimulus to be rotated. When performing a handedness task, participants spontaneously compare the displayed body part with their own, that is, they carry out a motor imagery task using the egocentric perspective (Parsons, 1987a, 1987b, 1994). Alternatively, they can be instructed to use an external strategy, which consists of imagining the

stimulus rotating in visual space (Tomasino & Rumiati, 2004; Kosslyn et al., 1998). This latter strategy is a mental transformation on the basis of the object reference frame in the visual space (i.e., allocentric perspective). Investigating whether RTs reflect arm-hand biological constraints (Parsons, 1987b, 1994) will ascertain which strategy has been employed. Performing the task in a somatic or bio-mechanical space (Parsons, Gabrieli, Phelps, & Gazzaniga, 1998) induces faster processing of stimuli oriented toward the body's midsagittal plane (i.e., medial) compared with those oriented away from it (i.e., lateral). This confirms that imagined movements reflect the bio-mechanical limitations that affect real movements, although the mental space is, at least in principle, constraint free (Corradi-Dell'Acqua, Tomasino, & Fink, 2009; Tomasino & Rumiati, 2004). However, when participants mentally rotate their hand (or an object) in visual space (i.e., the visual imagery-based strategy), this lateral-medial gradient is not expected to appear.

METHODS

Participants

Five right-handed (Oldfield, 1971) patients (age = 49.2 ± 12.6 years, education = 11 ± 2.73 years) with a lesion of the left frontal area (i.e., sensorimotor area) and 15 right-handed (Oldfield, 1971) controls matched by age (46.66 ± 8.45 years) and education (8.73 ± 2.9 years) took part in the study. All experiments, for which the participants gave informed consent, were performed in compliance with the relevant laws and institutional guidelines and were approved by the S.I.S.S.A. Ethical Committee.

Neuropsychological Testing

Patients performed well on tests assessing their intelligence (Raven CPM, 1979; range = 33/36–36/36, cutoff = 20.75), language (Aachener Aphasia Test; Luzzatti, Willmes, & De Bleser, 1996), STM (digit span; Spinnler & Tognoni, 1987; range = 4–6, cutoff = 3.75), praxis (ideomotor apraxia; De Renzi, Motti, & Nichelli, 1980; range 60/72–72/72, cutoff = 53), visual and spatial processes (Subtests 1, 2, and 3 from VOSP; Warrington & James, 1991; range = 18/20–20/20, cutoff = 14, 15, 16, respectively, for Subtests 1, 2, and 3), spatial attention (cancellation test, the Balloons Test; Edgeworth, Robertson, & McMillan, 1998; all 22/22, cutoff = 17), and left-right discrimination (all 24/24; Ratcliff, 1979). They all underwent surgery for tumor removal at least 5 months before testing.

Lesion Analysis

The preoperative location of the tumor was determined using contrast enhanced T1- and T2-weighted MRI scans taken 1 to 2 days before surgery. T2 images are generally used by neurosurgeons during surgery with the neuro-navigator because they are the best indicator of macro-

scopic tumor extension. Because the excised brain tissue may be partially replaced by the surrounding healthy brain matter, preoperative MR scans are more indicated for localization purposes. MRICro software was used to extrapolate a 3-D representation of the lesion from digital MR scans (Brett, Leff, Rorden, & Ashburner, 2001; Rorden & Brett, 2000). The tumor boundary was drawn as a ROI on each sagittal slice in collaboration with the neurosurgeon, unaware of the behavioral results. The scans and the ROIs were normalized using the Statistical Parametric Mapping (SPM2, Wellcome Department of Cognitive Neurology, London, UK). Each patient's lesion was superimposed on to an anatomical template image automated anatomical labeling (Tzourio-Mazoyer et al., 2002), a macroscopic anatomical parcellation of Montreal Neurological Institute volume. In addition, the lesion location was determined by the neurosurgeon while performing the direct cortical stimulation mapping of the sensorimotor homunculus. The resections were total, stopping at the point in which the cortical stimulation evoked a body part movement. The neurosurgeon, using cortical stimulation, found that all the lesions were limited to the central area (the difference for lesion size between HA- [9.97 ± 5.49] and HA+ [6.25 ± 2.62] was not significant; one-sample Kolmogorov-Smirnov test, $Z = 0.645$, $p > .05$, *ns*). Of the five patients, three (P1, P2, and P3) had a lesion affecting the hand sensorimotor representation (HA-) at the border with the primary motor and somatosensory cortices and two (P4 and P5) had a glioma sparing the hand sensorimotor representation (HA+) (Figure 1). The preoperative MRI images did not show traces of the tumor outside the sensorimotor area, and by using the (anatomical) cytoarchitectonically defined probability maps of Area 6, Areas 4p and 4a and Area 2 (SPM5, Anatomy toolbox), it was possible to confirm that the patients' lesions did not involve the premotor and/or parietal regions, which are frequently associated with motor imagery.

Neurological Motor Examination

Consistently with lesion localization, neurological examination revealed that some patients presented muscular weakness, and their movements were slow. With reference to specific cases, before surgery P1 had right arm hemiplegia, P2 had loss of right-hand sensibility and right thumb seizures, P3 had difficulty in writing and loss of right-hand sensibility, P4 had right foot hemiplegia, and P5 had right leg hemiplegia. After surgery, P1 and P2 showed a loss of sensibility in his right hand, P3 showed loss of sensibility in his right side, P4 showed right foot hemiplegia, and P5 showed loss of sensibility in his right foot.

Stimuli, Design, and Procedure

Stimuli and instructions of Experiments 1 and 2 were presented on a computer screen, placed at a distance of 50 cm from the participants. Patients responded by pressing two keys on a response box using the index and the middle finger of their ipsilesional hand; 50% of the right-handed (Oldfield, 1971) control participants used their right hand and the other 50% the left. All the participants were asked to keep their hands still during the experiments and their nonresponding hand (which was positioned on the table) palm down (as for the responding hand) and parallel to the responding hand. All participants performed 10 practice trials before the actual experiment; E-Prime Software (E-Prime Software, Psychology Software Tools, Pittsburgh, PA) was used to present stimuli and record RTs and accuracy.

Experiment 1: Mental Rotation of Hand Shapes and Letters

Participants were shown pairs of pictures and asked to judge whether the two items of the pairs were the same or different (i.e., a mirror version, as in Figure 2A). Two experimental blocks (see Tomasino, Borroni, et al., 2005), one of line drawings of hands ($n = 28$) and the other of letters ($n = 28$ varying P, F, and L), were counterbalanced across participants. In hand trials, the stimulus on the left side of the screen was always a left hand to avoid visuomotor interference (Ganis et al., 2000), whereas the stimulus on the right side could be either a left (50%) or a right hand (50%). The hand drawings were the same as the original images used by Parsons et al. (1995; Parsons, 1987b), varying in view (i.e., palms and backs) and orientation. All ($N = 56$) stimuli could have either the same (baseline condition, i.e., MR of hand shapes $N = 28 \times 2$ and MR of letters $N = 28 \times 2$) or different orientations (rotation condition, i.e., MR of hand shapes $N = 28 \times 2$ and MR of letters $N = 28 \times 2$), for a total of 112 trials. The stimulus on the left side was always upright in the rotation condition, whereas the stimulus on the right side appeared in one of four different orientations (60° , 150° , 210° , and 330°).

Experiment 2: Mental Rotation of Hands and 3-D Cubes Using Different Strategies

Twenty-four color photographs (created using Adobe Photoshop Version 7.0) of open hands (all digits extended, 50% left, 50% right), varying in view (palm and back) and orientation (rotated in 60° steps on the picture plane),

Figure 1. Localization of the patients' lesions. Axial views are shown together with a template of the lesion reconstruction made with MRICro superimposing ROIs created on the damaged area. Lesions sparing the hand sensorimotor area (HA+) are localized more medially, whereas those involving the hand sensorimotor area (HA-) have been localized more laterally; the small portion of the area involved in all three lesions involving the hand sensorimotor area (HA-) is represented in yellow. The upper three and the bottom two rows show MRI images of the three HA- and two HA+ patients, respectively. All MRI images were taken before neurosurgery.

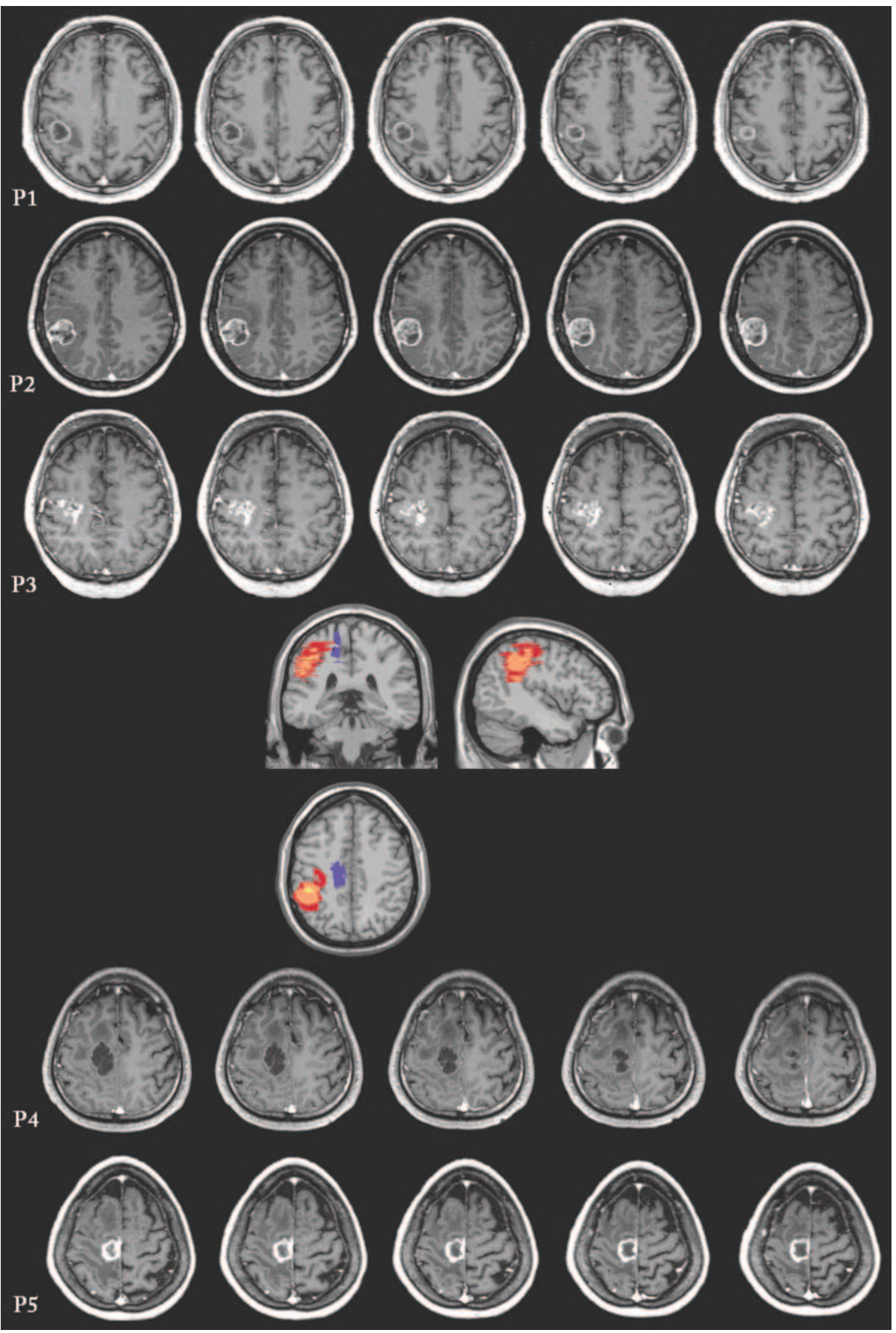
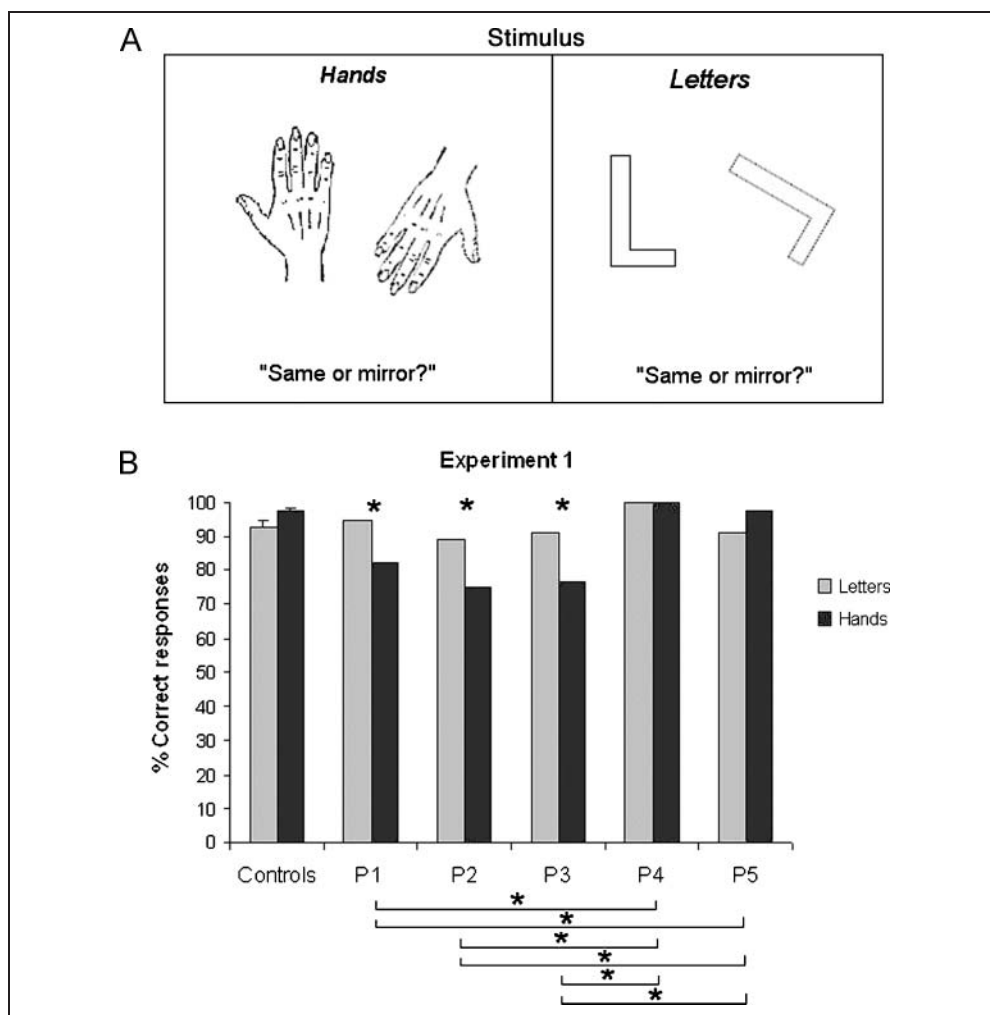


Figure 2. Experiment 1: MR of hands and letters. (A) Examples of the stimuli (hands and letters) and instructions are shown. (B) The percentage of correct responses given by controls and patients is plotted. HA+, lesion sparing the hand sensorimotor area, or HA-, lesion involving the hand sensorimotor area.



and twenty-four pictures of rotated 3-D branching forms (rotated in 60° steps on the picture plane) were used as stimuli (Figure 3A). Color photographs were used as they provide an unambiguous and simpler visual display compared with line-drawings. A red marker was placed in different positions on the left or right side of the pictures of hands and the 3-D branching forms. Patients and control participants were instructed to use motor imagery-based (i.e., to imagine rotating the stimulus with their own hand) or visual imagery-based (i.e., to imagine the same stimuli as rotating freely in visual space) strategies, elicited by means of precise instructions (Tomasino & Rumiati, 2004). In the motor imagery-based task, all participants decided which of their hands corresponded to the hand stimulus (hand task) or, for cubes, which hand they would use to touch the red marker comfortably with their thumb. When performing these tasks, participants mentally rotate the motor image of their own hand (i.e., egocentric perspective) and match it to the target stimulus (Parsons et al., 1995; Parsons, 1987b), with the allocentric reference frame being irrelevant. In the visual imagery-based task, all participants were asked to mentally visualize the same stimuli as rotating freely in visual space and to indicate on

which side of either the hand or the cube the red marker would be after having mentally visualized the reorientation of the stimulus toward the canonical upright position (“Imagine seeing the stimulus rotating on the screen until it reaches the upright position, and then decide whether the red marker is on the L or R side with respect to the picture”). To accomplish the visual task, participants perform a mental rotation which is based on the reference frame of the object (i.e., allocentric perspective).

The order of the strategy and the type of stimulus block were counterbalanced across all possible orders of the blocks. Each participant performed the full set of trials ($n = 24$) three times for each task (hands and 3-D branching forms) to ensure a sufficient number of observations.

Data Analyses

Data analyses were carried out with SPSS 8.0. Data were examined following a multiple single-case approach. The performance of each patient was compared with that of the controls using a z test and to that of the other patients using the Wilcoxon test, for both experiments. Correct RTs were entered in a general factorial ANOVA. In particular, in

Experiment 2, application of the motor or the visual strategy was controlled by checking whether RTs reflect arm–hand biological constraints (Tomasino & Rumiati, 2004; Parsons et al., 1995; Parsons, 1987b). The lateral-medial gradient, with faster RTs for medial orientations than for lateral ones, should be present when participants adopt the motor strategy (Tomasino & Rumiati, 2004; Parsons et al., 1995; Parsons, 1987b) and absent when they adopt the visual strategy. Lastly, we checked for possible alternative strategies, such as solving the task by visual inspection of stimuli details or by checking accuracy for upside-down rotated stimuli. In this condition, the responses given on the basis of the relative positions of hand parts and those on the basis of the required spatial judgment are incongruent. The responses given by each participant in each test for imagined

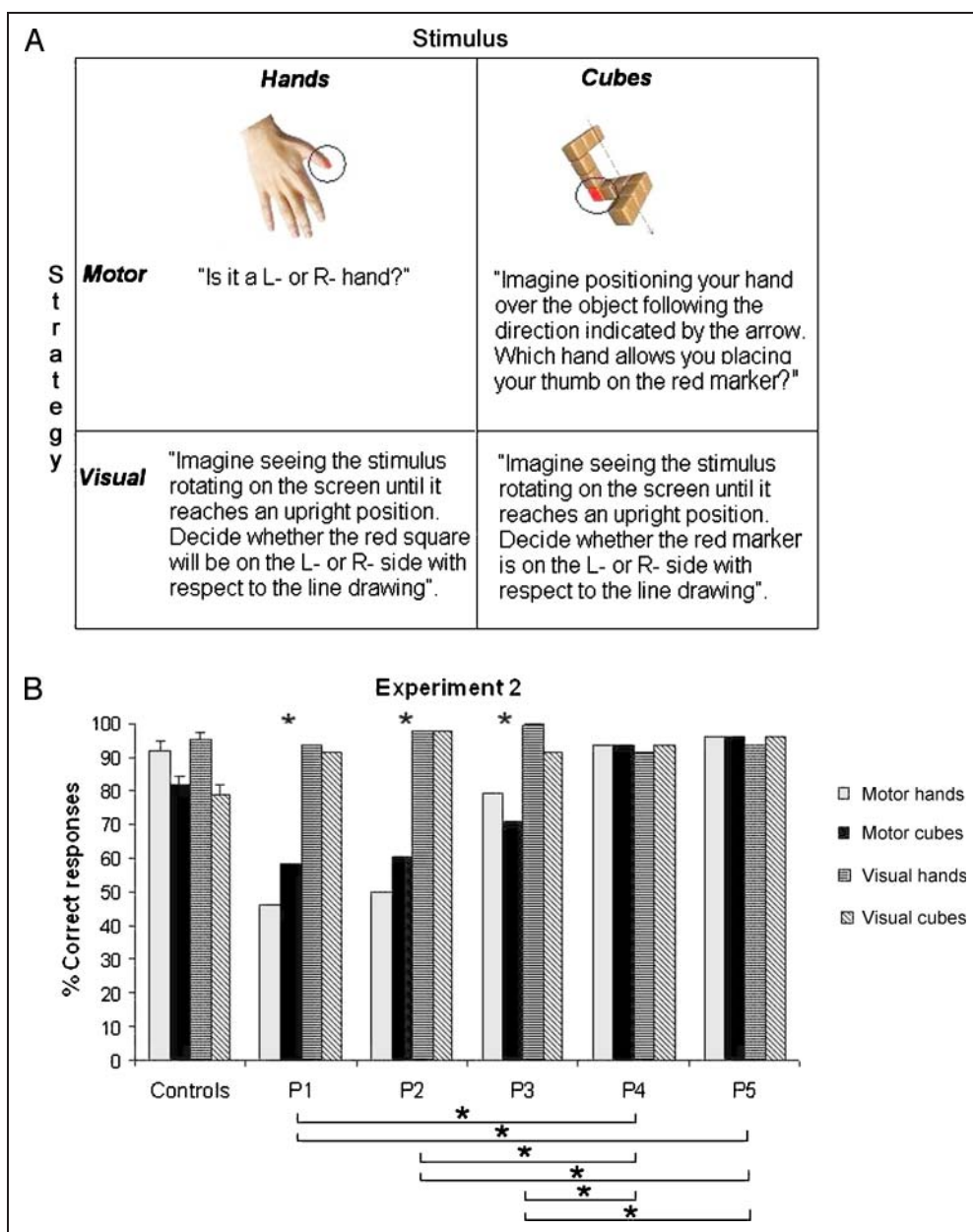
right- or left-hand movements were subjected to a logistic regression analysis, in which the dependent variable was his or her response, coded as either 1 (correct) or 0 (incorrect).

RESULTS

Experiment 1: Simulation of the Movements of Hands and Objects

The HA– patients (P1, P2, and P3) performed pathologically when imagining rotational hand movements (degree of accuracy for P1, P2, and P3: 82%, 75%, and 76%, respectively; *Z* scores: -5.34 , -7.84 , and -7.22 ; all *p*s < .001 when compared with controls; mean = 97.3%, *SD* = 1.2%; see Figure 2B) and normally when imagining rotational letter

Figure 3. Experiment 2: MR of hands and 3-D cubes using motor and visual imagery-based strategies. (A) Examples of the stimuli (hands and 3-D cubes) and instructions for triggering the motor and the visual strategies are shown. (B) The percentage of correct responses given by controls and patients is plotted. HA+, lesion sparing the hand area, or HA–, lesion involving the hand area.



movements (degree of accuracy for P1, P2, and P3: 94%, 89%, and 91%, respectively; Z scores: 0.87, -1.58 , and -0.76 ; all $ps > .05$, ns , when compared with the controls; mean = 92.7%, $SD = 2\%$). The HA+ patients (P4 and P5) were as accurate as the controls in both the hand (degree of accuracy for P4 and P5, 100% and 97%, respectively; Z scores 0.91 and -0.33 ; all $ps > .05$, ns) and the letter task (P5: 91%, Z scores = -0.76 , $p > .05$, ns), with P4 performing more accurately than the control group (P4: 100%, Z scores = 3.32 , $p < .001$).

The deficit of HA- patients (P1, P2, and P3) was selective for hands, whereas on the letter task, all patients reached a comparable level of performance; Wilcoxon test for the hand task: P1 performed significantly worse than P4 ($Z = -3.16$, $p < .005$), P5 ($Z = -2.82$, $p < .005$), and P2 ($Z = -2.000$, $p < .05$) but comparably with P3 ($Z = -1.732$, $p > .05$). P2 performed significantly worse than P4 ($Z = -3.742$, $p < .001$) and P5 ($Z = -3.464$, $p < .001$) but similarly to P3 ($Z = -1.000$, $p > .05$, ns), who in turn performed significantly worse than P4 ($Z = -3.606$, $p < .005$) and P5 ($Z = -3.317$, $p < .005$), whereas P4 was as accurate as P5 ($Z = -1.414$, $p > .05$, ns); for the letter task: P1 versus P4 ($Z = -1.732$), versus P5 ($Z = -1.414$), versus P3 ($Z = -1.414$), and versus P2 ($Z = -1.732$). P2 versus P3 ($Z = -1.000$) and versus P5 ($Z = -1.000$). P3 versus P5 ($Z = .000$), all $ps > .05$, although P4 performed somewhat better than the others, including P5 [P4 vs. P5 ($Z = -2.236$, $p < .05$), vs. P3 ($Z = -2.236$, $p < .05$), and vs. P2 ($Z = -2.449$, $p < .05$)].

The deficit of HA- patients affected the MR of the left- and right-hand stimuli equally (Wald, $p > .05$, ns). In addition, patients were able to match stimuli in the baseline condition, which does not require mental rotation (for hands: controls = $97.26\% \pm 0.6\%$, P1 = 96.43%, P2 = 96.43%, P3 = 96.43%, P4 = 96.43%, and P5 = 100%; for letters: controls = $94.06\% \pm 0.9\%$, P1 = 96.43%, P2 = 100%, P3 = 100%, P4 = 96.43%, and P5 = 96.43%). Overall, although patients took longer than the control participants to perform the task, they all showed a significant main effect of Condition [longer RTs for rotation vs. baseline: P1, $F(1, 89) = 5.89$, $p < .05$; P2, $F(1, 93) = 3.86$, $p < .05$; P3, $F(1, 104) = 5.6$, $p < .05$; P4, $F(1, 107) = 11.9$, $p < .005$; P5, $F(1, 107) = 8.9$, $p < .005$], of Stimulus type (RTs were longer for hand MR vs. letters; all $ps < .05$), and of Angle (all $ps < .05$), indicating that they were all able to imagine rotational movements of the stimuli.

Experiment 2: Motor and Visual Strategy-guided Simulation of the Movements of Hands and Objects

The HA- patients performed both hand and object rotations pathologically when using the motor imagery-based strategy (the degree of accuracy for P1, P2, and P3 for hands was, respectively, 45.8%, 50%, and 79%, Z scores = -7.55 , -6.87 , and -2.08 , all $ps < .001$; for objects, 58.3%, 60.4%, and 70%, Z scores = -3.96 , -3.61 , and -1.84 , all $ps < .01$)

compared with controls (mean accuracy, 92% for hands and 82% for objects; see Figure 3B). They were all as accurate as controls (mean accuracy 96%) when using the visually based strategy with hand rotations (P1, P2, and P3: 93.7%, 97.9%, and 100%, Z scores = -0.28 , 0.58 , and 1.02 , all $ps > .05$, ns), and they performed even better on object rotations (P1, P2, and P3: 91.6%, 97.9%, and 91.6%, Z scores = 2.17 , 3.23 , and 2.17 , $p < .05$) than controls (mean accuracy = 79%). The HA+ patients (P4 and P5) were as accurate as controls on hand rotations both when using the motor (94% and 95.8%, Z scores = 0.317 and 0.66 , $p > .05$, ns) and the visual strategy (93.7% and 95.8%, Z scores = -0.71 and -0.27), and when manipulating objects, they performed better than controls when using either the motor (91.6% and 93.7%, Z scores = 2.04 and 2.39 , $p < .05$) or the visual strategy (93.7% and 95.8%, Z scores = 2.52 and 2.88 ; all $ps > .05$, ns).

A dissociation between motor and visual imagery-based strategies was found for both types of stimuli. HA+ patients (P4 and P5) were more accurate than HA- patients (P1, P2, and P3) when they imagined grasping and turning the stimuli (whether body parts or objects) with their own hands. By contrast, they were perfectly able to mentally visualize the rotation of the stimuli in space (see Figure 3B). The levels of significance achieved on the Wilcoxon test by patients for motor-based rotation of hands and 3-D cubes were as follows: P1 was significantly worse than P4 ($Z = -4.796$, $p < .001$, and $Z = -4.123$, $p < .001$) and P5 ($Z = -4.899$, $p < .001$, and $Z = -4.243$, $p < .001$) but was similar to P2 ($Z = -1.414$, $p = .157$, ns , and $Z = -1.000$, $p = .317$, ns) and significantly worse than P3 ($Z = -4.000$, $p < .001$, and $Z = -2.449$, $p < .05$), and they were both pathological when compared with controls; P2 was significantly worse than P4 ($Z = -4.583$, $p < .001$, and $Z = -4.000$, $p < .001$), P5 ($Z = -4.690$, $p < .001$, and $Z = -4.123$, $p < .001$), and P3 ($Z = -3.742$, $p < .001$, and -2.236 , $p < .05$), and both were pathological when compared with controls. P3 was significantly worse than P4 ($Z = -2.646$, $p < .01$, and $Z = -3.317$, $p < .01$) and P5 ($Z = -2.828$, $p < .05$, and $Z = -3.464$, $p < .01$). The performances of P4 and P5 were comparable ($Z = -1.000$, $p = .317$, ns , and $Z = -1.000$, $p = .317$, ns). However, when the Wilcoxon test was applied to the visual-based rotation of both hands and 3-D cubes, all comparisons led to all $ps > .05$ [P1 vs. P4 ($Z = -1.000$ and $.000$), P5 ($Z = .000$ and -1.000), P3 ($Z = -1.732$ and -1.000), and P2 ($Z = -1.414$ and -1.414); P2 vs. P4 ($Z = -1.732$ and -1.414), P5 ($Z = -1.414$ and -1.000), and P3 ($Z = -1.000$ and -1.732); P3 vs. P4 ($Z = -1.732$ and -1.000) and P5 ($Z = -1.732$ and -1.414); P4 vs. P5 ($Z = -1.000$ and -1.000)].

On the basis of previous findings (Tomasino & Rumiati, 2004; Parsons, 1987a, 1987b), we expected that RTs would reflect the physical arm-hand joint constraints when patients applied the motor imagery-based strategy for simulating hand movements. When participants used motor imagery, their RTs were consistently faster for medial (i.e., trials which required a rotation toward the midsagittal plane: right-hand

rotational movements counterclockwise and left-hand rotational movements clockwise) than for lateral orientations (i.e., trials requiring rotation away from the midsagittal plane: right-hand rotational movements clockwise and left-hand rotational movements counterclockwise), indicating that participants switched between the two simulation modes. Importantly, the “lateral-medial” gradient effect disappeared when they used the visual strategy. This is confirmed by the significant Lateral-Medial Gradient \times Strategy interaction for all but one patient: P3, $F(1, 156) = 10.52, p < .005$; P2, $F(1, 109) = 6.19, p < .05$; P1, $F(1, 112) = 4.82, p < .05$; P4, $F(1, 140) = 5.69, p < .05$; P5, $F(1, 142) = 11.77, p < .005$.

Solving the visual task via an alternative strategy as examining the relative position of the stimulus parts (e.g., thumb with the red marker; Figure 3A) would have given rise to an erroneous response (this type of error can occur for upside-down rotated stimuli). In fact, in this condition, responses on the basis of the relative positions of the hand parts (such as the thumb with the red marker or the index finger) and those on the basis of spatial judgment are incompatible. Both the HA+ and the HA- patients performed the task as accurately as the controls, ruling out the possibility that they might have used an alternative strategy.

DISCUSSION

This study measured the performance of patients with lesions in the sensorimotor cortex while they imagined rotational hand movements. The causal role of this area in the higher cognitive functions, particularly in mental rotation, has been the object of debate both in functional neuroimaging (Barnes et al., 2000; Harris et al., 2000; Kosslyn et al., 1998; Parsons et al., 1995) and in TMS studies (Bode, Koeneke, & Jancke, 2007; Eisenegger, Herwig, & Jäncke, 2007; Sauner et al., 2006; Tomasino, Borroni, et al., 2005; Ganis et al., 2000). No clear neuropsychological evidence has been provided so far to clarify whether the recruitment of the sensorimotor area in the imagination of hand movements is necessary or an epiphenomenon. To explore this issue, we studied neurosurgical patients with small and selective lesions of the left sensorimotor cortex.

In Experiment 1, the performance of HA- patients was significantly inferior to that of HA+ and healthy controls in imagining the movement of their own hands; on the contrary, all patients performed as accurately as the controls when they imagined similar rotational movements of letters. Our findings provide evidence for a causal role of the sensorimotor area in the simulation of the rotational movements of body parts, but not of nonbody part stimuli (Tomasino, Borroni, et al., 2005; Ganis et al., 2000; Kosslyn et al., 1998). We propose that the pathological performance of patients on imagining mental transformations of hand shapes was a result of damage to their motor imagery ability. Their normal performance in Experiment 1 on the baseline trials (a pair of hands with either the same or mirror

orientation, for which no imagined rotational movement was required) indicates that patients can match stimuli that do not require mental rotation. Our behavioral results support the hypothesis that patients were mentally rotating an image of their own hands a trajectory starting from an upright position through to the position of the hand stimulus. All the patients who failed on this task had a lesion affecting the hand representation (HA-), whereas patients with a lesion sparing the hand representation (HA+) performed the task accurately. Patients with focal and selective lesions affecting the hand sensorimotor area are more appropriate for localization purposes.

Our findings suggest that motor imagery recruits somatotopically organized regions of the sensorimotor area, depending on the effector involved in the mental transformation. In previous imaging studies (Ehrsson et al., 2003; Stippich et al., 2002), imagery of voluntary movements of different body parts activated somatotopical sections of the human motor cortices when participants actually executed or imagined performing repetitive flexion/extension movements of their right fingers or right toes or horizontal movements of the tongue. Similarly, it has been shown that TMS applied to the hand motor area interfered with the hand but not feet mental rotation (Ganis et al., 2000) and that corticospinal excitability was enhanced during motor imagery of movements, but only for those muscles that would be recruited during overt movement execution (Fadiga, Craighero, & Olivier, 2005). This study with data from patients with lesions to the sensorimotor cortex further confirms a previous study in which the general motor imagery ability was investigated in a patient with a right motor lesion (Sirigu, Cohen, Duhamel, Pillon, Dubois, Agid, & Pierrot-Deseilligny, 1995) and another addressing the ability of a patient with an electrode grid placed on the M1 cortex (Tomasino, Budai, et al., 2005) to imagine rotational hand movements.

We also found that a lesion of the left sensorimotor cortex impaired the simulation of both left- and right-hand movements. Assuming that patients are using the same strategy observed in studies with healthy individuals (Kosslyn et al., 2001; Parsons et al., 1995; Parsons, 1987b), the participants were expected to use their motor imagery of their left hand for judging left-hand stimuli (thus activating a right-lateralized network of motor areas) and vice versa for judging right-hand stimuli. A study of split-brain patients (Parsons et al., 1998) with intact but disconnected hemispheres demonstrated that both hemispheres can perform accurate motor imagery (with the same lead time as healthy participants) with the contralateral hand. It follows therefore that our patients should also have been impaired on the mental simulation of right-hand movements only. Our findings, however, suggest that the left hemisphere seems to play a critical role in the mental simulation of left- and right-hand movements. How can we reconcile these two contrasting sets of findings? The intact right hemisphere does not seem to be sufficient to support motor imagery for left- or right-hand stimuli in our patients.

One possible explanation is that a lesion of the left-hand representation (or possibly peri-lesion areas) may actively disrupt the normal capacity of the right hemisphere to independently perform accurate motor imagery for the left hand. This is consistent with functional neuroimaging studies reporting healthy participants with predominant left sensorimotor area activity when performing a motor imagery task involving the right hand and left and right motor area activity for motor imagery of the left hand (Kosslyn et al., 2001; Porro et al., 2000; Porro et al., 1996; Parsons et al., 1995). The specialization of the left sensorimotor cortex for both left- and right-hand movements has also been shown in the context of the planning, execution, and simulation of movements (Ganis et al., 2000; Fadiga et al., 1999). A distinctive feature of ideomotor and ideational apraxia is that they affect both sides of the body equally after a unilateral left-brain damage (De Renzi, Faglioni, & Sorgato, 1982; for a review, see Goldenberg, 2008).

The results from Experiment 1 showed that the hand representation plays a key role in imagining hand movements but not the movements of objects, suggesting that the involvement of the hand sensorimotor area is stimulus specific. Results from Experiment 2 clarified that the involvement of the sensorimotor cortex is sensitive to the type of strategy for performing the mental transformation that was explicitly induced in the patients. HA- patients were impaired when trying to apply motor imagery, independent of whether the stimulus was a body part or an object, while they were still capable of performing the MR of both types of stimuli as accurately as the controls when they used the visual imagery to accomplish the same task. This is consistent with the possibility that left-hand representation is recruited whenever MR is carried out to simulate hand actions (i.e., motor simulation). These results provide neuropsychological data that converge with results obtained with imaging techniques (Kosslyn et al., 1998) in which activation of the left sensorimotor area was dependent on the strategy adopted by the participants to perform the task. In a previous study, we found that TMS applied to the left sensorimotor area interfered with the simulation of hand movements, but not of object movement (Tomasino, Borroni, et al., 2005), and suggested that when the subject is left free to select the motor or visual strategy, the nature of the stimulus implicitly triggered a particular type of mental transformation. Hands elicited motor imagery, and letters elicited visual imagery. This interpretation also seems to hold true for the results of the current study.

The interpretation we favor is that the hand sensorimotor area in the left hemisphere participates in MR whenever hand manipulation is required either implicitly, triggered by a given type of stimulus, or explicitly, by applying task instructions, or simply because participants are more familiar with motor simulation. More importantly, a significant biological constraint effect on response times (i.e., the lateral-medial gradient mentioned above) indicated that patients did actually use the motor and the visual strategies, revealing longer response times for stimuli that were later-

ally oriented (i.e., trials where arms were rotated away from the body's midsagittal plane) but not medially oriented (i.e., trials where arms were rotated toward the body's midsagittal plane), but only when using the *motor* strategy. This effect indicates that patients were aware of the trajectories through which their hands can be displaced, limiting them to physically manageable rotations. In Experiment 2, the biological constraint effect was present in the motor imagery-based condition, confirming that the participants performed the task in somatic or bio-mechanical space (see also Parsons et al., 1995, 1998); on the contrary, the fact that a biological constraint effect was not found on the mental rotation of the stimulus in the visual imagery-based condition is consistent with the view that this operation takes place in visual space, with the object as its reference frame. The present study adds to findings reported in a previous single case study (Tomasino, Budai, et al., 2005) in which cortical stimulation through an electrode grid applied to the motor cortex resulted in interference with task performance in mental rotation only when the participant was instructed to use a motor strategy similar to internal strategy (egocentric perspective transformations; Zacks, Vettel, & Michelon, 2003). The mental rotation performance was unaffected when the participant was instructed to adopt a visual strategy comparable with external strategy (object-based spatial transformations; Tomasino, Budai, et al., 2005).

What is the function of the sensorimotor area during motor imagery of rotational hand movements? There are several possible explanations to be derived from the literature, which certainly deserve to be tested further. First, it may reflect anticipatory priming signals received from the premotor cortex in support of motor planning, or alternatively, it could be the consequence of pFC inhibition of motor behavior. Second, sensorimotor activity may reflect the process of attention to motor behavior occurring in hand-centered space, as suggested by a study in which the neural activity of subarea 4p (posterior) within the primary motor area has been found to be modulated by the attention participants paid to action (Binkofski et al., 2002). Third, a study in which the activity of single neurons was recorded in the brain of a monkey, demonstrated the existence of direction-sensitive neurons in the primary motor area supporting hand visuomotor transformations (Georgopoulos, 2000; Georgopoulos, Lurito, Petrides, Schwartz, & Massey, 1989), thus suggesting a direct involvement of the sensorimotor cortex in the mental simulation of rotational hand movements. There are cortical circuits that compute the appropriate motor command by projecting the visual information about the target location onto an arm-centered reference frame (Burnod et al., 1992). The interpretation we favor is that the sensorimotor cortex may contribute to such motor simulation by providing a continuous updating of somatotopic representations while individuals compare the stimulus position with their own hand motor image, an essential function during the imagination of rotational hand movements. Motor regions may

play a role in providing ongoing kinesthetic feedback during mental rotation or in checking the results of the imagined transformation, all with no overt execution of movement. Importantly, causal connectivity analyses studies demonstrated that some connections from nonprimary to primary motor areas are inhibitory during motor imagery (Kasses et al., 2008; Solodkin, Hlustik, Elinor Chen, & Small, 2004). These connections presumably remain active during motor imagery to keep the activity level in the primary motor area below a certain level. Despite the absence of real movements, they might allow a continuous updating between the imagined movement and the final target hand position. The notion that imagined hand rotations may utilize the same motor structures as actual movements is consistent with previous behavioral experiments in which it has been found that manual rotation interferes with the speed of a concurrent MR occurring in the opposite direction (Wohlschläger, 2001; Wexler, Kosslyn, & Berthoz, 1998; Wohlschläger & Wohlschläger, 1998). It should also come as no surprise that MR may, in some instances, involve action-related brain areas. The concept that the manipulation of mental images is associated with a motor process was already intrinsic to the definition of MR (Shepard & Metzler, 1971). It has been argued that stimuli under MR appear to move in imagery as they would if they were physically rotated, and our results are consistent with the notion that the sensorimotor area actively participates in this operation.

Conclusions

Recently, the role of the sensorimotor cortex in higher cognitive functions such as motor imagery, mental rotation, motor memory, and linguistic processing of action-related sentences has been at the focus of a stimulating debate. More specifically, fMRI and TMS studies have addressed the issue of whether this area is involved when participants perform motor imagery tasks. Our findings provide evidence of a causal relationship between the left sensorimotor hand representation, whose primary function is the execution of hand movements, and higher cognitive operations such as motor simulation.

Acknowledgments

The authors are very grateful to the patients and to Dr. Peter Weiss and to Dr. Karsten Specht for his helpful comments on the normalization of patients' MRI scans using SPM2.

Reprint requests should be sent to Dr. Barbara Tomasino, IRCCS "E. Medea," Polo Regionale del Friuli Venezia Giulia, via della Bontà, 7, San Vito al Tagliamento (PN), 33078, Italy, or via e-mail: btomasino@ud.lnf.it.

REFERENCES

Barnes, J., Howard, R. J., Senior, C., Brammer, M., Bullmore, E. T., Simmons, A., et al. (2000). Cortical activity during rotational and linear transformations. *Neuropsychologia*, *38*, 1148–1156.

Binkofski, F., Fink, G. R., Geyer, S., Buccino, G., Gruber, O., Shah, N. J., et al. (2002). Neural activity in human primary motor cortex areas 4a and 4p is modulated differentially by attention to action. *Journal of Neurophysiology*, *88*, 514–519.

Bode, S., Koenke, S., & Jancke, L. (2007). Different strategies do not moderate primary motor cortex involvement in mental rotation: A TMS study. *Behavioral and Brain Functions*, *3*, 38.

Brett, M., Leff, A. P., Rorden, C., & Ashburner, J. (2001). Spatial normalization of brain images with focal lesions using cost function masking. *Neuroimage*, *14*, 486–500.

Burnod, Y., Grandguillaume, P., Otto, I., Ferraina, S., Johnson, P. B., & Caminiti, R. (1992). Visuomotor transformations underlying arm movements toward visual targets: A neural network model of cerebral cortical operations. *Journal of Neuroscience*, *12*, 1435–1453.

Carpenter, P. A., Just, M. A., Keller, T. A., Eddy, W., & Thulborn, K. (1999). Graded functional activation in the visuospatial system with the amount of task demand. *Journal of Cognitive Neuroscience*, *11*, 9–24.

Cohen, M. S., Kosslyn, S. M., Breiter, H. C., DiGirolamo, G. J., Thompson, W. L., Anderson, A. K., et al. (1996). Changes in cortical activity during mental rotation. A mapping study using functional MRI. *Brain*, *119*, 89–100.

Corradi-Dell'Acqua, C., Tomasino, B., & Fink, G. R. (2009). What is the position of an arm relative to the body? Neural correlates of body schema and body structural description. *Journal of Neuroscience*, *29*, 4162–4171.

de Lafuente, V., & Romo, R. (2004). Language abilities of motor cortex. *Neuron*, *41*, 178–180.

de Lange, F. P., Hagoort, P., & Toni, I. (2005). Neural topography and content of movement representations. *Journal of Cognitive Neuroscience*, *17*, 97–112.

De Renzi, E., Faglioni, P., & Sorgato, P. (1982). Modality-specific and supramodal mechanisms of apraxia. *Brain*, *105*, 301–312.

De Renzi, E., Motti, F., & Nichelli, P. (1980). Imitating gestures. A quantitative approach to ideomotor apraxia. *Archives of Neurology*, *37*, 6–10.

Edgeworth, J. A., Robertson, I. H., & McMillan, T. M. (1998). *The balloons test*. England: Harcourt Assessment.

Ehrsson, H. H., Geyer, S., & Naito, E. (2003). Imagery of voluntary movement of fingers, toes, and tongue activates corresponding body-part-specific motor representations. *Journal of Neurophysiology*, *90*, 3304–3316.

Eisenegger, C., Herwig, U., & Jäncke, L. (2007). The involvement of primary motor cortex in mental rotation revealed by transcranial magnetic stimulation. *European Journal of Neuroscience*, *25*, 1240–1244.

Fadiga, L., Buccino, G., Craighero, L., Fogassi, L., Gallese, V., & Pavesi, G. (1999). Corticospinal excitability is specifically modulated by motor imagery: A magnetic stimulation study. *Neuropsychologia*, *37*, 147–158.

Fadiga, L., Craighero, L., & Olivier, E. (2005). Human motor cortex excitability during the perception of others' action. *Current Opinion in Neurobiology*, *15*, 213–218.

Floel, A., Ellger, T., Breitenstein, C., & Knecht, S. (2003). Language perception activates the hand motor cortex: Implications for motor theories of speech perception. *European Journal of Neuroscience*, *18*, 704–708.

Ganis, G., Keenan, J. P., Kosslyn, S. M., & Pascual-Leone, A. (2000). Transcranial magnetic stimulation of primary motor cortex affects mental rotation. *Cerebral Cortex*, *10*, 175–180.

Georgopoulos, A. P. (2000). Neural aspects of cognitive motor control. *Current Opinion in Neurobiology*, *10*, 238–241.

Georgopoulos, A. P., Lurito, J. T., Petrides, M., Schwartz, A. B., & Massey, J. T. (1989). Mental rotation of the neuronal population vector. *Science*, *243*, 234–236.

Goldenberg, G. (2008). Apraxia and the parietal lobes. *Neuropsychologia*, *47*, 1449–1459.

- Harris, I. M., Egan, G. F., Sonkkila, C., Tochon-Danguy, H. J., Paxinos, G., & Watson, J. D. (2000). Selective right parietal lobe activation during mental rotation: A parametric PET study. *Brain*, *123*, 65–73.
- Jeannerod, M., & Frak, V. (1999). Mental imaging of motor activity in humans. *Current Opinion in Neurobiology*, *9*, 735–739.
- Johnson, S. H. (2000). Imagining the impossible: Intact motor representations in hemiplegics. *NeuroReport*, *11*, 729–732.
- Kasses, C. H., Windischberger, C., Cunnington, R., Lanzenberger, R., Pezawas, L., & Moser, E. (2008). The suppressive influence of SMA on M1 in motor imagery revealed by fMRI and dynamic causal modeling. *NeuroImage*, *40*, 828–837.
- Kosslyn, S. M., DiGirolamo, G. J., Thompson, W. L., & Alpert, N. M. (1998). Mental rotation of objects versus hands: Neural mechanisms revealed by positron emission tomography. *Psychophysiology*, *35*, 151–161.
- Kosslyn, S. M., Thompson, W. L., Wraga, M., & Alpert, N. M. (2001). Imagining rotation by endogenous versus exogenous forces: Distinct neural mechanisms. *NeuroReport*, *12*, 2519–2525.
- Luzzatti, C., Willmes, K., & De Bleser, R. (1996). *Aachener Apbasie Test*. Firenze: Organizzazioni Speciali.
- Masumoto, K., Yamaguchi, M., Sutani, K., Tsuneto, S., Fujita, A., & Tonoike, M. (2006). Reactivation of physical motor information in the memory of action events. *Brain Research*, *1101*, 102–109.
- Mutsaerts, M., Steenbergen, B., & Bekkering, H. (2007). Impaired motor imagery in right hemiparetic cerebral palsy. *Neuropsychologia*, *45*, 853–859.
- Oldfield, R. C. (1971). The assessment and analysis of handedness: The Edinburgh inventory. *Neuropsychologia*, *9*, 97–113.
- Parsons, L. M. (1987a). Imagined spatial transformation of one's body. *Journal of Experimental Psychology: General*, *116*, 172–191.
- Parsons, L. M. (1987b). Imagined spatial transformations of one's hands and feet. *Cognitive Psychology*, *19*, 178–241.
- Parsons, L. M. (1994). Temporal and kinematic properties of motor behavior reflected in mentally simulated action. *Journal of Experimental Psychology: Human Perception and Performance*, *20*, 709–730.
- Parsons, L. M., Fox, P. T., Downs, J. H., Glass, T., Hirsch, T. B., Martin, C. C., et al. (1995). Use of implicit motor imagery for visual shape discrimination as revealed by PET. *Nature*, *375*, 54–58.
- Parsons, L. M., Gabrieli, J. D., Phelps, E. A., & Gazzaniga, M. S. (1998). Cerebrally lateralized mental representations of hand shape and movement. *Journal of Neuroscience*, *18*, 6539–6548.
- Porro, C. A., Cettolo, V., Francescato, M. P., & Baraldi, P. (2000). Ipsilateral involvement of primary motor cortex during motor imagery. *European Journal of Neuroscience*, *12*, 3059–3063.
- Porro, C. A., Francescato, M. P., Cettolo, V., Diamond, M. E., Baraldi, P., Zuiani, C., et al. (1996). Primary motor and sensory cortex activation during motor performance and motor imagery: A functional magnetic resonance imaging study. *Journal of Neuroscience*, *16*, 7688–7698.
- Ratcliff, G. (1979). Spatial thought, mental rotation and the right cerebral hemisphere. *Neuropsychologia*, *17*, 49–54.
- Richter, W., Somorjai, R., Summers, R., Jarmasz, M., Menon, R. S., Gati, J. S., et al. (2000). Motor area activity during mental rotation studied by time-resolved single-trial fMRI. *Journal of Cognitive Neuroscience*, *12*, 310–320.
- Rorden, C., & Brett, M. (2000). Stereotaxic display of brain lesions. *Behavioural Neurology*, *12*, 191–200.
- Sauner, D., Bestmann, S., Siebner, H. R., & Rothwell, J. C. (2006). No evidence for a substantial involvement of primary motor hand area in handedness judgements: A transcranial magnetic stimulation study. *European Journal of Neuroscience*, *23*, 2215–2224.
- Sekiyama, K. (1982). Kinesthetic aspects of mental representations in the identification of left and right hands. *Perceptual Psychophysics*, *32*, 89–95.
- Shepard, R. N., & Metzler, J. (1971). Mental rotation of three-dimensional objects. *Science*, *171*, 701–703.
- Sirigu, A., Cohen, L., Duhamel, J. R., Pillon, B., Dubois, B., & Agid, Y. (1995). A selective impairment of hand posture for object utilization in apraxia. *Cortex*, *31*, 41–55.
- Sirigu, A., Cohen, L., Duhamel, J. R., Pillon, B., Dubois, B., Agid, Y., et al. (1995). Congruent unilateral impairments for real and imagined hand movements. *NeuroReport*, *6*, 997–1001.
- Solodkin, A., Hlustik, P., Elinor Chen, E., & Small, S. L. (2004). Fine modulation in network activation during motor execution and motor imagery. *Cerebral Cortex*, *14*, 1246–1255.
- Spinnler, H., & Tognoni, G. (1987). Standardizzazione e taratura italiana di test neuropsicologici. *Italian Journal of Neurological Sciences*, *8(Suppl.)*, 1–120.
- Stippich, C., Ochmann, H., & Sartor, K. (2002). Somatotopic mapping of the human primary sensorimotor cortex during motor imagery and motor execution by functional magnetic resonance imaging. *Neuroscience Letters*, *331*, 50–54.
- Tagaris, G. A., Kim, S. G., Strupp, J. P., Andersen, P., Ugurbil, K., & Georgopoulos, A. P. (1996). Quantitative relations between parietal activation and performance in mental rotation. *NeuroReport*, *7*, 773–776.
- Tomasino, B., Borroni, P., Isaja, A., & Rumiati, R. I. (2005). The role of primary motor cortex in mental rotation: A TMS study. *Cognitive Neuropsychology*, *22*, 348–363.
- Tomasino, B., Budai, R., Mondani, M., Skrap, M., & Rumiati, R. I. (2005). Mental rotation in a patient with an implanted electrode grid in the motor cortex. *NeuroReport*, *16*, 1795–1800.
- Tomasino, B., & Rumiati, R. I. (2004). Effects of strategies on mental rotation and hemispheric lateralization: Neuropsychological evidence. *Journal of Cognitive Neuroscience*, *16*, 878–888.
- Tzourio-Mazoyer, N., Landeau, B., Papathanassiou, D., Crivello, F., Etard, O., Delcroix, N., et al. (2002). Automated anatomical labeling of activations in SPM using a macroscopic anatomical parcellation of the MNI MRI single-subject brain. *NeuroImage*, *15*, 273–289.
- Vingerhoets, G., Santens, P., Van, L. K., Lahorte, P., Dierckx, R. A., & De, R. J. (2001). Regional brain activity during different paradigms of mental rotation in healthy volunteers: A positron emission tomography study. *NeuroImage*, *13*, 381–391.
- Warrington, E. K., & James, M. (1991). *VOSP: The visual object and space perception battery*. Bury St. Edmunds, UK: Thames Valley Test Company.
- Wexler, M., Kosslyn, S. M., & Berthoz, A. (1998). Motor processes in mental rotation. *Cognition*, *68*, 77–94.
- Wohlschläger, A. (2001). Mental object rotation and the planning of hand movements. *Perception & Psychophysics*, *63*, 709–718.
- Wohlschläger, A., & Wohlschläger, A. (1998). Mental and manual rotation. *Journal of Experimental Psychology: Human Perception and Performance*, *24*, 397–412.
- Wraga, M., Thompson, W. L., Alpert, N. M., & Kosslyn, S. M. (2003). Implicit transfer of motor strategies in mental rotation. *Brain and Cognition*, *52*, 135–143.
- Zacks, J. M. (2008). Neuroimaging studies of mental rotation: A meta-analysis and review. *Journal of Cognitive Neuroscience*, *20*, 1–19.
- Zacks, J. M., Vettel, J. M., & Michelon, P. (2003). Imagined viewer and object rotations dissociated with event-related fMRI. *Journal of Cognitive Neuroscience*, *15*, 1002–1018.