

What Role Does the Anterior Temporal Lobe Play in Sentence-level Processing? Neural Correlates of Syntactic Processing in Semantic Variant Primary Progressive Aphasia

Stephen M. Wilson¹, Andrew T. DeMarco¹, Maya L. Henry², Benno Gesierich², Miranda Babiak², Maria Luisa Mandelli², Bruce L. Miller², and Maria Luisa Gorno-Tempini²

Abstract

Neuroimaging and neuropsychological studies have implicated the anterior temporal lobe (ATL) in sentence-level processing, with syntactic structure-building and/or combinatorial semantic processing suggested as possible roles. A potential challenge to the view that the ATL is involved in syntactic aspects of sentence processing comes from the clinical syndrome of semantic variant primary progressive aphasia (semantic PPA; also known as semantic dementia). In semantic PPA, bilateral neurodegeneration of the ATLS is associated with profound lexical semantic deficits, yet syntax is strikingly spared. The goal of this study was to investigate the neural correlates of syntactic processing in semantic PPA to determine which regions normally involved in syntactic processing are damaged in semantic PPA and whether spared syntactic processing depends on preserved functionality of intact regions, preserved functionality of atrophic regions, or compensatory functional reorganization. We scanned 20 individuals with semantic PPA and 24 age-matched controls using structural MRI and fMRI. Participants performed a sentence comprehension task that emphasized syntactic processing and minimized lexical semantic demands. We found that, in controls,

left inferior frontal and left posterior temporal regions were modulated by syntactic processing, whereas anterior temporal regions were not significantly modulated. In the semantic PPA group, atrophy was most severe in the ATLS but extended to the posterior temporal regions involved in syntactic processing. Functional activity for syntactic processing was broadly similar in patients and controls; in particular, whole-brain analyses revealed no significant differences between patients and controls in the regions modulated by syntactic processing. The atrophic left ATL did show abnormal functionality in semantic PPA patients; however, this took the unexpected form of a failure to deactivate. Taken together, our findings indicate that spared syntactic processing in semantic PPA depends on preserved functionality of structurally intact left frontal regions and moderately atrophic left posterior temporal regions, but no functional reorganization was apparent as a consequence of anterior temporal atrophy and dysfunction. These results suggest that the role of the ATL in sentence processing is less likely to relate to syntactic structure-building and more likely to relate to higher-level processes such as combinatorial semantic processing. ■

INTRODUCTION

In the classical literature on aphasia and the neural substrates of language, the anterior temporal lobe (ATL) was not considered to be an important language region. Cortical stimulation of the ATL during presurgical language mapping did not typically induce speech errors or aphasic errors, and the ATL was frequently resected to treat intractable epilepsy without resulting in obvious aphasias (Penfield & Roberts, 1959). Moreover, focal strokes to the ATL are very uncommon because of vascular anatomy, so there were no relevant data from cerebrovascular patients (Holland & Lambon Ralph, 2010). However, the past two decades have seen an increasing body of evidence for critical involvement of the ATL in two aspects

of language: first, in the representation and processing of lexical semantic information (for a review, see Patterson, Nestor, & Rogers, 2007), and second, in sentence-level processing (Humphries, Binder, Medler, & Liebenthal, 2006; Dronkers, Wilkins, Van Valin, Redfern, & Jaeger, 2004; Vandenberghe, Nobre, & Price, 2002; Mazoyer et al., 1993).

The role of the ATL in sentence-level processing has been primarily motivated by numerous PET and fMRI studies that have shown increased ATL activation for sentences compared with matched word lists (Pallier, Devauchelle, & Dehaene, 2011; Rogalsky & Hickok, 2009; Humphries et al., 2006; Humphries, Love, Swinney, & Hickok, 2005; Xu, Kemeny, Park, Frattali, & Braun, 2005; Vandenberghe et al., 2002; Humphries, Willard, Buchsbaum, & Hickok, 2001; Friederici, Meyer, & von Cramon, 2000; Stowe et al., 1999; Mazoyer et al., 1993). As many of these

¹University of Arizona, ²University of California, San Francisco

authors have pointed out, it is difficult to determine what aspect of sentence processing is responsible for the greater activation of the ATL for sentences than word lists, because sentence comprehension entails not only syntactic processes to parse the sentence and build the syntactic structure, but also combinatorial semantic processes that integrate the meanings of the words in the sentence to arrive at a global meaning.

The strongest evidence that the ATL might play a specifically syntactic role in sentence comprehension has come from several studies reporting that even sentences in which content words were replaced with pseudowords (“*Jabberwocky* sentences”) activated the ATL more than matched pseudoword lists (Humphries et al., 2006; Friederici et al., 2000; Mazoyer et al., 1993). These findings suggest that ATL activation for sentences reflects syntactic processes, because the pseudowords in the *Jabberwocky* sentences lack any lexical semantic representations, which should limit the recruitment of combinatorial semantic processes. Additional findings supporting a syntactic role for the ATL include two voxel-based lesion-symptom mapping studies showing associations between anterior temporal damage and sentence comprehension deficits (Magnusdottir et al., 2013; Dronkers et al., 2004), adaptation effects for repeated syntactic structures in the ATL (Noppeney & Price, 2004), and ATL activation associated with time-varying syntactic structure-building in naturalistic contexts (Brennan et al., 2012).

A potential challenge to the view that the ATL is involved in syntactic aspects of sentence processing comes from the clinical syndrome of semantic variant primary progressive aphasia (semantic PPA; also known as semantic dementia; Hodges, Patterson, Oxbury, & Funnell, 1992; Snowden, Goulding, & Neary, 1989; Warrington, 1975). Semantic PPA is characterized by dramatic bilateral atrophy of the ATL and profound lexical semantic deficits, yet syntactic function is almost completely spared (for a review, see Wilson, Galantucci, Tartaglia, & Gorno-Tempini, 2012). Patients with semantic PPA almost invariably score close to ceiling on sentence comprehension measures so long as lexical demands are minimized (Wilson et al., 2011; Gorno-Tempini et al., 2004; Hodges et al., 1992; Warrington, 1975) and they show normal sensitivity to syntactic violations in on-line and off-line tasks (Cotelli et al., 2007; Grossman, Rhee, & Moore, 2005). Other patient groups with ATL damage have also been reported to have spared sentence comprehension, including patients who have had anterior temporal lobectomies (Kho et al., 2008) and patients with herpes simplex encephalitis (Kapur et al., 1994).

Spared syntax in the face of ATL damage constitutes a challenge to the view that the ATL is involved in syntactic processing. However, it is important to determine whether the specific regions thought to be involved in syntactic processing are damaged and whether any compensatory functional reorganization might have taken place that could compensate for the damaged ATL. The goal of this

study was to investigate the neural correlates of syntactic processing in semantic PPA to address these two questions. Specifically, we first determined which regions that are normally involved in syntactic processing are damaged in semantic PPA by comparing activations for syntactic processing in age-matched controls with patterns of atrophy in semantic PPA. Second, we asked whether spared syntactic processing in semantic PPA depends on preserved functionality of intact regions, preserved functionality of atrophic regions, or functional reorganization. If the ATL is critical for syntactic processing, which is largely spared in semantic PPA, then we would expect that syntactic processing in semantic PPA would depend on preserved functionality in the ATL despite atrophy and/or functional reorganization such that relatively intact regions compensate for the damaged ATL.

METHODS

Participants

We successfully acquired structural and functional imaging data in 20 patients with semantic PPA and 24 age-matched control participants over a 4-year period. Patients and age-matched controls were recruited through the Memory and Aging Center at the University of California, San Francisco (UCSF). All participants gave written informed consent, and the study was approved by the institutional review boards at UCSF and the University of Arizona. Patients and controls received a comprehensive multidisciplinary evaluation including neurological history and examination, neuropsychological testing, and neuroimaging.

Patients were diagnosed with semantic variant PPA based on recent guidelines (Gorno-Tempini et al., 2011). A diagnosis of PPA required progressive deterioration of speech and/or language functions and that deficits be largely restricted to speech and/or language for at least 2 years. A diagnosis of semantic variant PPA required two core features to be present: impaired confrontation naming and impaired single word comprehension. At least three of the four following features were also required: impaired object knowledge, surface dyslexia or dysgraphia, spared repetition, and spared speech production. Neuroimaging results were not used for diagnostic purposes, but only to rule out other causes of focal brain damage. However, anterior temporal atrophy was evident in all 20 patients.

Additional inclusion criteria were fluency in English and a Mini-Mental State Examination score of at least 15. A total of 23 patients met these criteria and were scanned, but two patients requested that the scanning session be stopped before the functional run was complete, and one patient had excessive head motion that could not be corrected, so all analyses were based on the remaining 20 patients.

Demographic, clinical, and neuropsychological characteristics for all participants are provided in Table 1.

Table 1. Demographic, Clinical, and Neuropsychological Characteristics of Patients and Controls

	<i>Semantic PPA</i>	<i>Controls</i>
<i>Demographic</i>		
Age	63.4 ± 6.5	66.8 ± 4.2
Sex (M/F)	11/9	7/17
Handedness (R/L)	17/3	22/2
Education (years)	16.5 ± 2.5	17.2 ± 2
<i>Clinical</i>		
Mini Mental Status Examination (30)	26.3 ± 3.0 ^a	29.3 ± 0.8
Clinical Dementia Rating	0.6 ± 0.2	N/A
Age at disease onset	58.8 ± 7.5	N/A
Years from first symptom	4.7 ± 2.7	N/A
<i>Language Production</i>		
Confrontation naming (BNT, 15) ^b	5.4 ± 3.8 ^a	14.5 ± 0.7
Phonemic fluency (D words in 1 min)	7.5 ± 5.0 ^a	17.6 ± 4.1
Semantic fluency (Animals in 1 min) ^b	7.8 ± 4.7 ^a	23.8 ± 4.3
Speech fluency (WAB, 10)	8.7 ± 0.9 ^a	10.0 ± 0.0 ^c
Apraxia of speech rating (MSE, 7)	0.0 ± 0.0	N/A
Dysarthria rating (MSE, 7)	0.0 ± 0.0	N/A
Repetition (WAB, 100)	92.2 ± 8.3 ^a	99.5 ± 0.9 ^c
<i>Language Comprehension</i>		
Auditory word recognition (PPVT, 16) ^b	8.9 ± 4.4 ^a	15.7 ± 0.7
Sequential commands (WAB, 80)	75.7 ± 8.0 ^a	80.0 ± 0.0 ^c
Semantic knowledge (PPT-P, 52) ^b	42.7 ± 6.4 ^a	51.8 ± 0.4 ^c
<i>Visuospatial Function</i>		
Modified Rey-Osterrieth copy (17)	15.7 ± 1.0	15.0 ± 1.1
<i>Visual Memory</i>		
Modified Rey-Osterrieth delayed copy (17)	8.2 ± 4.3 ^a	11.7 ± 2.3
<i>Verbal Memory</i>		
CVLT-MS Trials 1–4 (40)	16.4 ± 7.7 ^a	28.7 ± 3.1
CVLT-MS 30 sec free recall (10)	2.9 ± 2.5 ^a	7.9 ± 1.6
CVLT-MS 10 min free recall (10)	1.9 ± 2.0 ^a	7.3 ± 1.6
<i>Executive Function</i>		
Digit span backwards	5.3 ± 1.3	5.6 ± 1.2
Modified Trail Making Test (lines per min)	24.5 ± 9.8 ^a	37.8 ± 12.6
Calculation (WAB, 5)	4.7 ± 0.6	4.8 ± 0.4

Values are means ± standard deviation. Variables were compared between patients and controls using Welch's *t* tests where appropriate, the Wilcoxon signed-rank test for measures with floor or ceiling effects, and Fisher's exact test for discrete variables. See Kramer et al. (2003) for detailed description of neuropsychological testing procedures and Gorno-Tempini et al. (2004) for detailed description of language testing procedures.

BNT = Boston Naming Test; WAB = Western Aphasia Battery; MSE = Motor Speech Evaluation; PPVT = Peabody Picture Vocabulary Test; PPT-P = Pyramids and Palm Trees-Pictures; CVLT-MS = California Verbal Learning Test-Mental Status.

^aSignificantly impaired relative to controls, *p* < .05.

^bVariables included in composite semantic score.

^cData from Gorno-Tempini et al. (2004) because present control group was not tested on these variables.

There were no significant differences between patients and controls in age, sex, handedness, or education. As expected, semantic PPA patients had significant deficits on all measures related to lexical semantic function, including confrontation naming and auditory word recognition.

In addition to the 24 controls who took part in functional imaging, structural images from an additional 50 age-matched controls were used to create a template for intersubject normalization and voxel-based morphometry.

Experimental Design

The design of the fMRI study has been described in detail previously (Wilson, Dronkers, et al., 2010), so only a brief summary is presented here. We scanned participants with fMRI as they performed an auditory sentence-to-picture matching task. Each trial began with the presentation of two pictures: a target and a foil, one on the left and one on the right of the screen. One second later, a sentence was presented auditorily that matched one of the two pictures. Participants selected the matching picture at any point by pressing one of two buttons with their right hand.

There were seven conditions, which differed in the syntactic processing required as well as in length (Table 2). In two conditions (Short Lexical, Long Lexical), the correct response could be determined based on lexical information alone, because the foil pictures involved different lexical items than the target pictures. In two more conditions (Short Active, Long Easy), the foil pictures contained the same lexical items as the target pictures, so it was necessary to attend to syntactic structures to determine the correct response, but the syntactic structures involved were canonical: Elements were arranged in con-

figurations that are prototypical in English. The final three conditions (Short Passive, Long Medium, Long Hard) also required processing of syntactic structures to determine the correct response, but now the structures involved were noncanonical: Elements were displaced from their prototypical positions. Within each length category (short or long), all conditions were matched for length, for lexical content, and for the point at which the sentence disambiguated between the target and foil pictures. To keep lexical demands to a minimum, all sentences were constructed using just two high-frequency nouns (boy, girl), one of seven high-frequency verbs (push, pull, kiss, kick, chase, wash, hug), and for the long sentences, one of three high-frequency color adjectives (red, green, blue). It was important to minimize lexical demands because semantic PPA patients typically have severe lexical deficits. Note that no “scrambled” condition was included, because pilot studies had revealed that neurodegenerative patients were often confused by such conditions and responded to them in wildly variable ways.

Before scanning, participants were trained on the task. They were then scanned on a Siemens 3-T Trio scanner. T1-weighted anatomical images and T2*-weighted fMRI images (repetition time = 2000 msec; whole-brain coverage) were acquired using standard sequences as described previously (Wilson, Dronkers, et al., 2010). Auditory stimuli were presented via headphones, visual stimuli were presented via a screen that was viewed through a mirror, and button presses were recorded. There were three blocks per condition, for a total of 21 blocks, presented in random order. Each block was 28 sec in length and contained four equally spaced trials, and there were 16-sec rest periods between blocks and at the beginning and end of the experiment. The total duration of the functional sequence was 15 m 40 sec.

Table 2. Sentence Structures and Foils in the Seven Conditions

<i>Condition</i>	<i>Sentence Example</i>	<i>Foil Picture</i>
Short Lexical	The boy is hugging the girl.	Different action (e.g., pulling)
Short Active	The girl is kissing the boy.	Agent and patient reversed
Short Passive ^a	The boy is kicked by the girl.	Agent and patient reversed
Long Lexical	The girl who is green is pushing the boy. The boy is kissing the girl who is red.	Different action (e.g., chasing) Different colored patient (e.g., green girl)
Long Easy	The girl is pulling the boy who is red. The boy who is red is chasing the girl.	Color assigned to wrong participant Agent and patient reversed
Long Medium ^a	The girl who is washed by the boy is green. The girl who the boy is hugging is red.	Color assigned to wrong participant Agent and patient reversed
Long Hard ^a	The boy who the girl is pushed by is blue. The girl who the boy is kissed by is green.	Agent and patient reversed Color assigned to wrong participant

^aNoncanonical structures. See Wilson, Dronkers, et al. (2010) for a more detailed description and linguistic analysis of the stimuli.

Analysis of Behavioral Data

Overall accuracy and RT and differences in accuracy and RT between noncanonical and canonical conditions were compared between semantic PPA patients and controls using two-tailed Welch's *t* tests. Correlations were calculated between overall accuracy and disease duration and between overall accuracy and a composite semantic measure (see Table 1).

Analysis of Structural Imaging Data

The T1-weighted structural images were bias-corrected; segmented into gray matter, white matter, and cerebrospinal fluid; and initially normalized to Montreal Neurological Institute (MNI) space using the unified segmentation algorithm in SPM5 (Ashburner & Friston, 2005). More anatomically precise intersubject registration was then performed with the DARTEL (Diffeomorphic Anatomical Registration Through Exponentiated Lie algebra) toolbox (Ashburner, 2007) by warping each participant's image to a template created from the 50 additional control participants. Gray matter and white matter probability maps were scaled by Jacobians, smoothed with a Gaussian kernel of 12 mm FWHM, then summed together to obtain a map of brain parenchyma (Wilson, Henry, et al., 2010).

To map atrophy at the group level, we compared the semantic PPA patients with 74 age-matched controls (the 24 controls who took part in the functional study plus the 50 additional controls), with age, sex, and total intracranial volume included as covariates. Percent volume loss was plotted for regions with at least 10% volume loss.

To identify regions where volume loss was predictive of syntactic deficits, we calculated voxelwise correlations of tissue volume with overall accuracy on the sentence comprehension task in the group of 20 semantic PPA patients only, with the same covariates. The resulting *t* map was thresholded at voxelwise $p < .005$, then corrected for multiple comparisons based on cluster size with respect to 1000 permutations in which behavioral scores were randomly reassigned (Wilson, Henry, et al., 2010).

Analysis of Functional Imaging Data

The functional data were visually inspected, and volumes where there was excessive head motion (visible interleaving artifact) or other artifacts were replaced with interpolated data before preprocessing and later excluded from analysis. The number of volumes excluded was 19.5 ± 22.7 in semantic PPA patients and 11.5 ± 15.9 in controls (*ns*). The functional imaging data were preprocessed with standard methods in AFNI (Cox, 1996): The data were corrected for slice timing differences, realigned to account for head movement, smoothed with a Gaussian kernel of 8 mm FWHM, high pass filtered (cut-off = 100 sec) and detrended (Legendre polynomials of order up to and including 2). Independent component analysis was then

carried out using the FSL tool *melodic* (Beckmann & Smith, 2004), generating 30 components. Noise components were manually identified with reference to published criteria (Kelly et al., 2010) and removed using *fsl_regfilt*. The mean number of components removed was 9.1 ± 2.4 in semantic PPA patients and 9.0 ± 2.4 in controls (*ns*). Because the ATL is sensitive to susceptibility artifacts, we calculated a map of temporal signal-to-noise ratio. The mean temporal signal-to-noise ratio in the ATL ROI described below was 165, sufficient to detect functional changes.

We analyzed the data using two different whole-brain general linear models (GLMs), each of which was fit using the *fmrilm* procedure from FMRISTAT (Worsley et al., 2002). The first was a conventional parametric block design model, and the second was based on individual participants' RTs on individual trials. We also carried out ROI analyses in nine left hemisphere ROIs to quantify the distribution of structural and functional imaging measures in these key regions and to identify any correlations between different imaging measures and behavior.

In the first whole-brain GLM analysis, the design matrix contained one explanatory variable for each of the seven conditions, each consisting of a boxcar function convolved with a standard hemodynamic response function. Additional covariates of no interest were included to reduce error variance: three translation and three rotation parameters (saved during realignment), signal time courses from a white matter ROI, a cerebrospinal fluid ROI, and the whole-brain global signal and three cubic spline temporal trends. The primary contrast of interest was between the three conditions involving noncanonical structures and the four conditions that involved only canonical structures. The purpose of this contrast was to identify regions modulated by syntactic complexity. Note that the Short Passive condition was multiplied by 2 in the contrast, so that the contrast was balanced across short and long conditions. A second contrast of interest was between all seven conditions and the resting baseline. This contrast identified regions involved in sentence comprehension in general, along with nonlinguistic functions related to the task, such as visual, auditory, motor, and executive processes.

In the second whole-brain GLM analysis, we used RT as a proxy for allocation of syntactic processing resources. RT was measured from the onset of the first word in the sentence that disambiguated the target from the foil, and we assumed that more syntactic processing took place on trials with longer RTs. This approach enabled a direct comparison of the regions that patients and controls recruited to perform the task, despite individual and group differences in performance. The four trials within each block were treated as separate events with a duration of 4 sec each, convolved with a hemodynamic response function. Short and long trials were modeled with separate explanatory variables, each of which was parametrically modulated by another variable coding RT for each trial.

RT was demeaned based on the mean of all short or long trials and clipped at 1.5 standard deviations from the mean. Correct and incorrect trials were included, because we were interested in identifying regions recruited for syntactic processing regardless of whether that processing was successful. (Note that including only correct trials yielded very similar results, because performance was generally accurate for both groups.) Trials on which there was no response were not included; they were modeled with a separate explanatory variable of no interest. The same covariates of no interest were included as in the first analysis. The contrast of interest was signal change per second of RT, which was averaged across the short and long parametric variables.

Random effects analyses were carried out on contrast images from individual participants, which were normalized to MNI space by applying the transformations described above. Patients and controls were compared with Welch's *t* tests. All statistical maps were thresholded at voxelwise $p < .005$ and then corrected for multiple comparisons at $p < .05$ based on cluster extent according to Gaussian random field theory implemented in SPM5. To ameliorate loss of power due to multiple comparisons, clusters in liberally defined potential language areas were corrected for the total combined volume of these language areas, whereas clusters outside these areas were corrected based on whole-brain volume. Potential language areas were defined as almost the entire lateral left hemisphere, specifically the left superior temporal gyrus (STG), middle temporal gyrus (MTG), inferior temporal gyrus (ITG), Heschl's gyrus, temporal pole, supra-marginal gyrus, angular gyrus, inferior frontal gyrus (IFG), middle frontal gyrus, premotor cortex, and insula (Tzourio-Mazoyer et al., 2002).

Analyses identifying regions with increased activation in semantic PPA relative to controls were inclusively masked with regions showing positive activations in semantic PPA (to identify abnormally activated regions) or deactivations in age-matched controls (to identify failure to deactivate normally). Conversely, analyses identifying regions with decreased activation in semantic PPA relative to controls were inclusively masked with regions showing deactivations in semantic PPA (to identify abnormally deactivated regions) or positive activations in age-matched controls (to identify lack of normal activations). All masks were defined at voxelwise $p < .005$, uncorrected.

ROI analyses were carried out using MATLAB in nine left hemisphere ROIs, each defined as a sphere with a radius of 8 mm. Six of the ROIs (anterior STS, posterior STS, TPJ, IFG pars opercularis, premotor cortex, and anterior insula) were centered on activation peaks in the contrast of noncanonical versus canonical conditions, averaged across semantic PPA patients and controls, so as not to bias them with respect to comparisons between patients and controls. A temporal pole ROI was centered on the mean coordinates ($-50, 3, -20$) of ATL activations related to syntactic or combinatorial semantic processing in nine

previous studies (Brennan et al., 2012; Pallier et al., 2011; Rogalsky & Hickok, 2009; Humphries et al., 2006; Xu et al., 2005; Dronkers et al., 2004; Noppeney & Price, 2004; Vandenberghe et al., 2002; Stowe et al., 1999). Finally, anterior MTG and IFG pars triangularis ROIs were centered on the peaks of regions that differed between semantic PPA patients and controls in whole-brain analyses of regions activated for sentence comprehension relative to rest (see below); our intention was to examine measures other than the contrast on the basis of which the regions had been defined.

For each of the nine ROIs, patients and controls were compared with two-tailed Welch's *t* tests on one structural imaging measure (tissue volume) and three functional imaging measures (modulation by syntactic complexity, modulation by RT, and activation for the sentence comprehension task relative to rest). These 36 comparisons were corrected for multiple comparisons using the false discovery rate (FDR) procedure implemented in MATLAB. For each ROI, correlations were computed between (1) tissue volume and accuracy, (2) tissue volume and each of the three functional measures, and (3) each of the three functional measures and accuracy. These 63 correlations were corrected for multiple comparisons using the FDR procedure.

RESULTS

Behavioral Data

Semantic PPA patients performed the sentence comprehension task quite accurately ($86.1\% \pm 5.8\%$ correct); however, they were less accurate than controls ($92.8\% \pm 3.1\%$), $t(27.72) = -4.61$, $p < .0001$ (Figure 1A). Accuracy in the patient group was not related to disease duration ($r = -0.21$, $p = .39$) or the composite semantic measure ($r = -0.07$, $p = .78$). Semantic PPA patients also performed disproportionately poorly relative to controls on more syntactically complex (noncanonical) conditions compared with less complex (canonical) conditions, $t(30.21) = -2.75$, $p = .0099$.

Semantic PPA patients also responded more slowly overall (1612 ± 321 msec) than controls (1218 ± 175 msec), $t(28.18) = 4.90$; $p < .0001$, and they responded disproportionately more slowly on syntactically complex conditions, $t(33.01) = 2.12$; $p = .042$ (Figure 1B).

Although semantic PPA patients did not perform as well as controls, it is noteworthy that they performed much better than the nonfluent/agrammatic PPA patients we investigated using this task in a prior study, whose mean accuracy was just $69.8\% \pm 14.0\%$ (Wilson, Dronkers, et al., 2010).

Atrophy in Semantic PPA Patients

The most markedly atrophic regions in the semantic PPA patients were the temporal lobes, with atrophy much

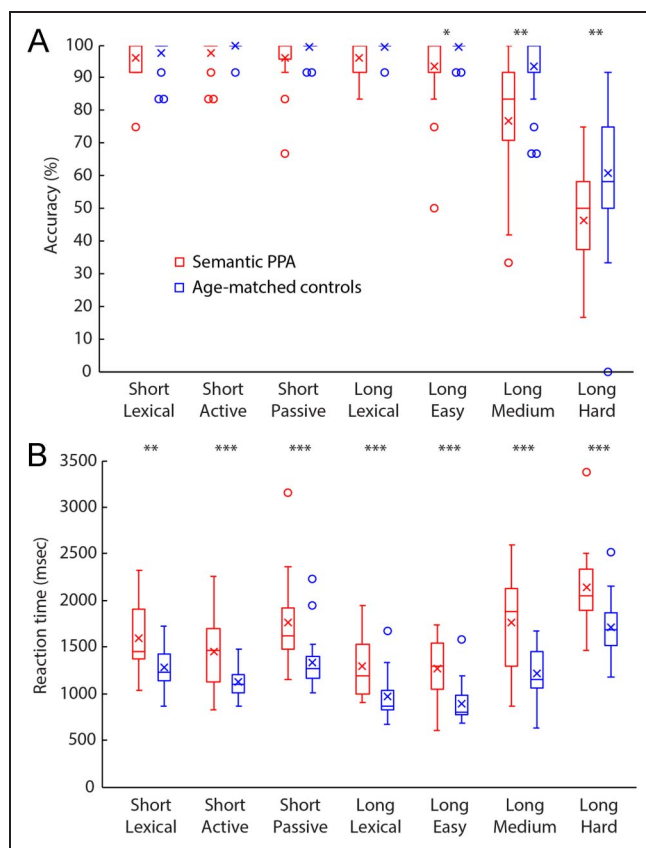


Figure 1. Behavioral data obtained during scanning. Accuracy (A) and RT (B) on the syntactic comprehension task for semantic PPA patients (red) and age-matched controls (blue). Boxes = interquartile range; whiskers = range not including outliers; circles = outliers; horizontal lines = medians; crosses = means. * $p < .05$; ** $p < .01$; *** $p < .001$.

more extensive anteriorly than posteriorly (Figure 2, blue-green). The entire left temporal lobe was atrophic, including lateral and medial aspects; atrophy extended posteriorly as far as the angular gyrus. In the right temporal lobe, atrophy was somewhat less extensive: most of the STG was spared, and the atrophy did not extend as far posteriorly. Ventromedial prefrontal cortex and the insula were also atrophic bilaterally.

Brain Regions Modulated by Syntactic Complexity in Controls

Brain regions modulated by syntactic complexity in controls (i.e., more active for noncanonical than canonical conditions) included the left dorsal posterior IFG, inferior frontal sulcus, precentral gyrus and anterior insula, and the left posterior STS and adjacent MTG and ITG (Figure 2, hot; Table 3). No anterior temporal regions were significantly modulated by syntactic complexity; however, there was a nonsignificant cluster in the anterior STS/STG (extent = 1392 mm³; $p = .24$) that we included in the figure and table because of our specific questions related to this

brain region. Note that these control data have been published previously (Wilson, Dronkers, et al., 2010); however, we used improved image analysis procedures in this study, so the results are not identical.

Overlap between Brain Regions Modulated by Syntactic Complexity in Controls and Atrophy in Semantic PPA Patients

There was extensive overlap between regions modulated by syntactic complexity in controls and atrophic regions in semantic PPA. In particular, the left posterior temporal regions modulated in controls were largely atrophic, as was the nonsignificant cluster in the left anterior STS. There was also overlap in the left and right anterior insula (Figure 2).

Comparison of Brain Regions Modulated by Syntactic Complexity in Semantic PPA Patients and Controls

The regions modulated by syntactic complexity were strikingly similar in semantic PPA patients and controls (Figure 3). Unthresholded effect size maps are presented to depict the broad similarities in the regions activated (Figure 3, hot). Similar to the control group, the regions significantly modulated by syntactic complexity in semantic PPA patients included left inferior frontal and posterior temporal regions (Figure 3, white outlines; Table 3).

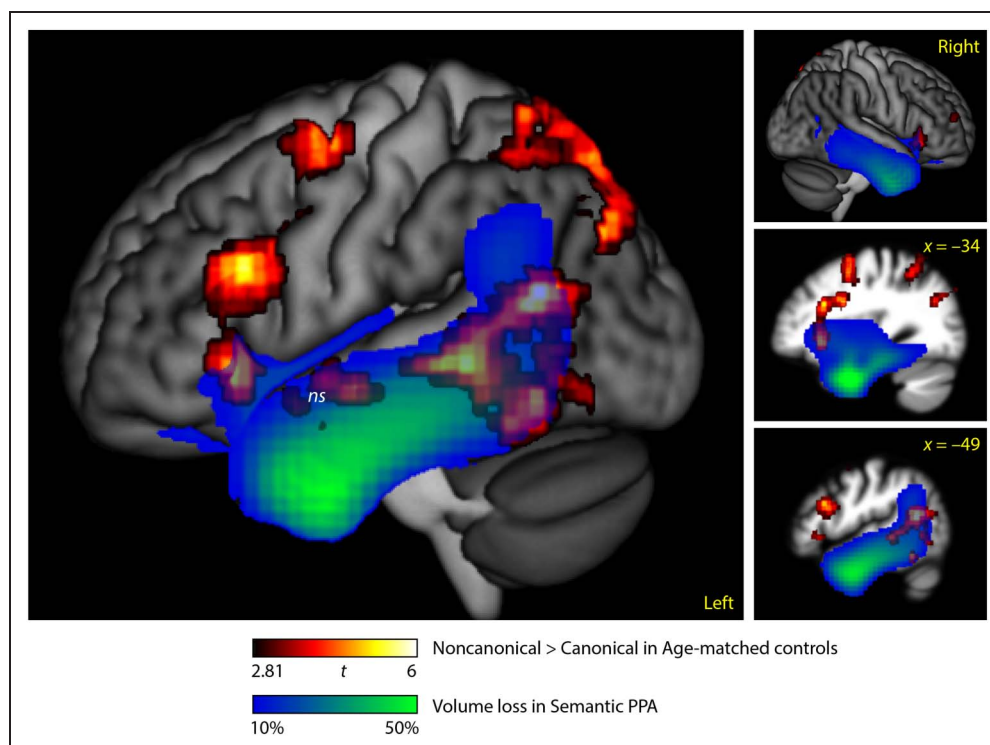
When the two groups were compared directly, there were no significant differences between semantic PPA patients and controls in the regions modulated by syntactic complexity. This suggests that despite atrophy extending to several regions involved in syntactic processing in controls, these regions continued to show normal functional activity in semantic PPA.

RT as a Proxy for Syntactic Processing

We carried out a second analysis in which RT was used as a proxy for allocation of syntactic processing resources (Figure 4). Brain regions modulated by RT in controls were similar to those activated for noncanonical versus canonical conditions and included left inferior frontal and posterior temporal regions (Figure 4A, hot). Similar to the syntactic complexity contrast, there were no anterior temporal regions significantly modulated by RT, but there was a nonsignificant cluster in the anterior STS (MNI coordinates: $-49, -5, -15$; extent = 1640 mm³; max $t = 4.76$; $p = .13$) that we included in the figure. Also similar to the syntactic complexity contrast, posterior temporal and insular regions overlapped with atrophy in semantic PPA (Figure 4A, blue-green).

The regions modulated by RT were similar in semantic PPA patients and controls. Unthresholded effect size maps are presented to depict the broad similarities in

Figure 2. Overlap between regions modulated by syntactic complexity in controls and atrophic regions in semantic PPA. Regions activated for noncanonical versus canonical sentences in controls ($n = 24$, voxelwise $p < .005$, corrected $p < .05$; hot) and regions with tissue loss of 10% or greater in semantic PPA patients ($n = 20$; blue-green).



the regions activated (Figure 4B and C, hot). As in controls, left inferior frontal and posterior temporal regions were significantly modulated by RT in the patients (Figure 4B, white outlines).

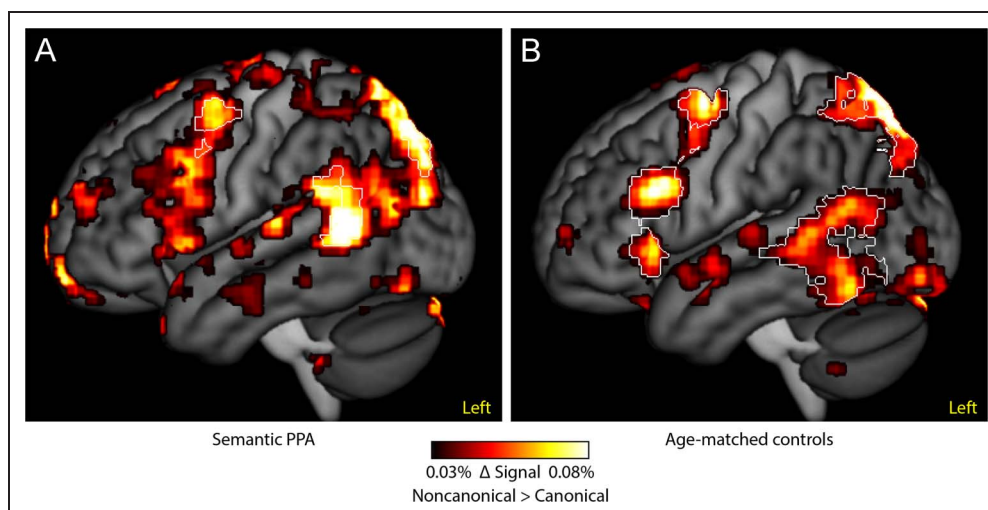
When the two groups were compared directly, there were no significant differences between semantic PPA patients and controls in the regions modulated by RT.

Table 3. Brain Regions Modulated by Syntactic Complexity in Controls and Semantic PPA Patients

Brain Region	MNI Coordinates			Extent (mm ³)	Max t	p
	x	y	z			
<i>Modulated by Syntactic Complexity in Controls</i>						
Left posterior IFG (pars opercularis) and anterior insula	-39	19	16	11984	5.58	< .001
Left precentral gyrus	-36	-1	56	4792	4.95	.001
Left posterior STS, MTG, and ITG	-53	-51	3	13256	6.40	< .001
Left anterior STS and STG	-62	-3	-10	1392	4.81	.24 (<i>ns</i>)
Left superior parietal lobule	-19	-66	49	16664	5.43	< .001
Bilateral pre-SMA	0	14	53	3112	4.37	.033
Right anterior insula	39	27	2	3568	4.03	.017
<i>Modulated by Syntactic Complexity in Semantic PPA Patients</i>						
Left precentral gyrus	-37	1	50	1944	4.52	.048
Left posterior STS	-60	-50	12	2376	4.67	.035
Left superior parietal lobule	-28	-82	44	3784	6.49	.019
Left precuneus	-10	-54	44	3408	4.74	.032

MNI coordinates for clusters are centers of mass.

Figure 3. Effect size maps of regions modulated by syntactic complexity in semantic PPA (A) and controls (B). Uncorrected signal change is plotted to illustrate the similarities between activation patterns in the two groups. The white outlines indicate regions that were statistically significant in each group (voxelwise $p < .005$, corrected $p < .05$). When the groups were compared directly, there were no significant differences between them.



Comparison of Brain Regions Activated or Deactivated for Sentence Comprehension versus Rest in Semantic PPA Patients and Controls

We next examined the regions that were activated for the sentence comprehension task relative to rest in the two groups (Figure 5). Unthresholded effect size maps are presented showing activations (Figure 5A and B, hot) and deactivations (Figure 5A and B, cool), along with statistical significance (Figure 5A and B, white and cyan outlines). There were no activations in the ATL (anterior to auditory regions), and surprisingly, the ventral ATL was robustly deactivated in controls.

Although broad similarities between the two groups can be readily appreciated, there were also three regions that differed significantly when the two groups were directly compared (Table 4). First, semantic PPA patients did not show the ventral ATL deactivation that was observed in controls (Figure 5C); the region where this difference was observed was atrophic in the semantic PPA patients (compare Figure 2A). Second, left inferior

frontal activation extended more anteriorly in semantic PPA patients than in controls (Figure 5D); this region was not atrophic (compare Figure 2A). Third, there was less activation in the right STG in patients than in controls (Figure 5E); this region was also not atrophic.

ROI Analyses

In nine left hemisphere ROIs, we investigated the distribution of tissue volume, modulation of signal by syntactic processing, modulation of signal by RT, and signal change for sentence comprehension relative to rest (Figure 6).

Semantic PPA patients showed significant volume loss in all temporal lobe regions and the insula, but not in any of the lateral frontal regions (Figure 6A). No regions differed between patients and controls in terms of modulation by syntactic complexity (Figure 6B). However, for modulation by RT, the posterior STS differed between groups: This region was modulated more in controls than in semantic PPA patients ($p = .038$; Figure 6C). Signal change for sentence comprehension relative to rest differed

Table 4. Differences between Semantic PPA Patients and Controls in Functional Activations for the Sentence Comprehension Task versus Rest

Brain Region	MNI Coordinates			Extent (mm^3)	Max t	p
	x	y	z			
<i>Semantic PPA > Controls</i>						
Left IFG (pars triangularis and orbitalis)	-48	26	9	3128	4.47	.017
Left anterior MTG	-60	-19	-22	6024	5.18	.002
<i>Semantic PPA < Controls</i>						
Right STG	56	-30	8	10872	5.94	< .001

MNI coordinates for clusters are centers of mass.

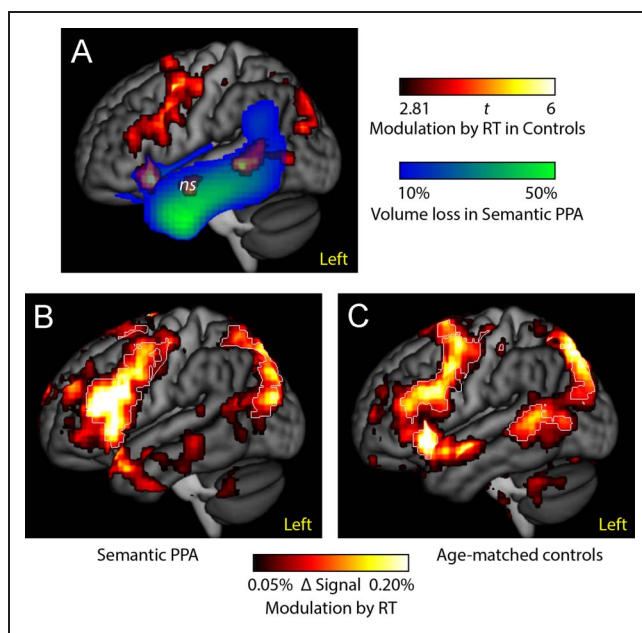
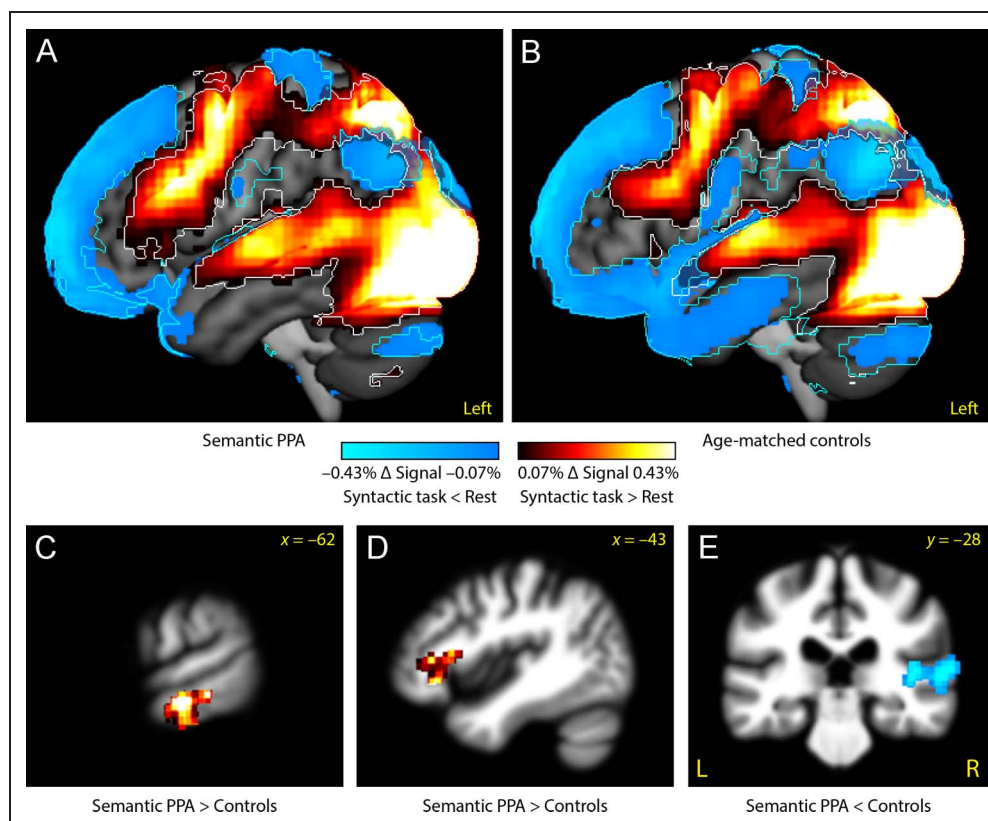


Figure 4. Analysis with RT as a proxy for syntactic processing. (A) Overlap between regions modulated by RT in age-matched controls (hot) and atrophic regions in semantic PPA (blue-green). (B) Effect size map of regions modulated by RT in semantic PPA. (C) Effect size map of regions modulated by RT in controls. The white outlines indicate regions that were statistically significant in each group (voxelwise $p < .005$, corrected $p < .05$). When the groups were compared directly, there were no significant differences between them.

Figure 5. Activations for the syntactic task relative to rest. (A) Effect size map of regions activated for task versus rest in semantic PPA. (B) Effect size map of regions activated for task versus rest in semantic PPA. Uncorrected signal change is plotted to illustrate the similarities between activation patterns in the two groups. The white and cyan outlines indicate regions that were statistically activated (white) or deactivated (cyan) in each group (voxelwise $p < .005$, corrected $p < .05$). (C) When the groups were compared directly, there was greater activation for semantic PPA patients than controls in the left anterior MTG, reflecting deactivation in controls but not patients. (D) There was greater activation for semantic PPA patients than controls in the left IFG. (E) There was less activation for semantic PPA patients than controls in the right STG.



between groups in the two ROIs that had been defined based on that contrast—the anterior MTG and the IFG pars triangularis—and also in the anterior STS, which was activated more in semantic PPA patients than controls ($p = .021$ (Figure 6D)). This region is adjacent to the anterior MTG region that failed to deactivate in patients, so this difference likely reflects extension of deactivation into the anterior STS in some controls, but not in patients.

We next investigated, in semantic PPA patients only, whether atrophy predicted accuracy, whether atrophy predicted any of the three functional measures, and whether any of the three functional measures predicted accuracy (Figure 7).

The only ROI where atrophy predicted accuracy was the left anterior insula, where patients with greater volume loss were less accurate ($r = 0.61$, $p = .043$; Figure 7A). On the basis of that finding, we also carried out a whole-brain voxel-based morphometry analysis to determine where atrophy was associated with decreased accuracy, and we found that tissue loss not only in the left anterior insula, but throughout left frontal cortex, was associated with decreased accuracy ($p = .002$; Figure 7B).

There were two instances in which atrophy was predictive of functional imaging measures. In the left anterior insula, patients with more atrophy showed less modulation by syntactic complexity ($r = 0.70$, $p = .021$; Figure 7C), and in the left posterior STS, patients with more atrophy showed less modulation by RT ($r = 0.69$, $p = .012$; Figure 7D).

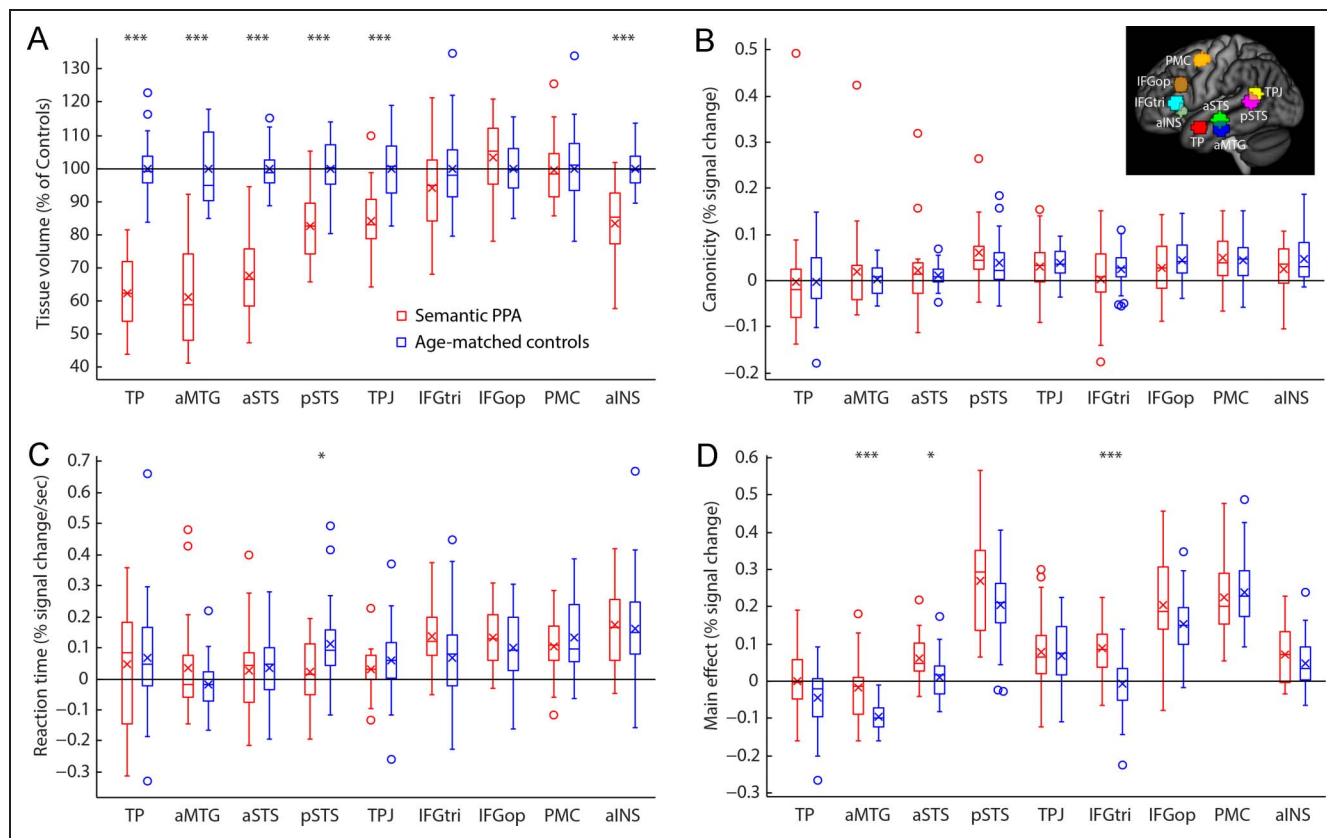


Figure 6. ROI analyses for nine regions shown projected onto the cortical surface in the inset. (A) Tissue volume as a percentage of the control mean for semantic PPA patients (red) and age-matched controls (blue). (B) Signal change for processing noncanonical sentences relative to canonical sentences. (C) Signal change per second of RT. (D) Signal change for sentence comprehension task versus rest. Boxes = interquartile range; whiskers = range not including outliers; circles = outliers; horizontal lines = medians; crosses = means. * $p < .05$; ** $p < .01$; *** $p < .001$ (corrected for multiple comparisons, FDR).

There were no regions in which functional activity was predictive of accuracy, although prior to correction for multiple comparisons, there was some indication that, in the left anterior insula, modulation by syntactic complexity ($p = .056$, uncorrected) and modulation by RT ($p = .032$, uncorrected) were predictive of accuracy.

DISCUSSION

The overall goal of this study was to investigate the role of the ATL in sentence processing by identifying the neural correlates of syntactic processing in semantic PPA, a clinical syndrome in which the ATL is damaged yet syntactic

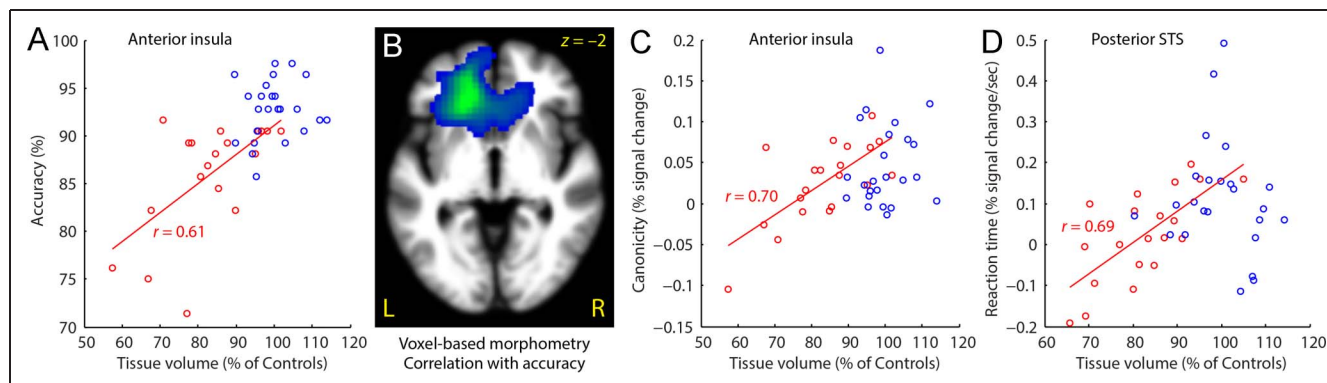


Figure 7. Correlations between atrophy, behavior, and functional activation. (A) Tissue volume in the left anterior insula was predictive of accuracy on the sentence comprehension task in semantic PPA patients. (B) Voxel-based morphometry revealed that left frontal atrophy was predictive of accuracy on the sentence comprehension task. (C) Tissue volume in the left anterior insula was predictive of the difference in functional activity between noncanonical and canonical sentences in semantic PPA patients. (D) Tissue volume in the left posterior STS was predictive of the extent to which this region was modulated by RT in semantic PPA patients. Note that all correlations reflect only the semantic PPA group (red); data for controls (blue) are shown for reference.

processing is largely spared. We aimed to address two specific questions. The first question was, which regions normally involved in syntactic processing are damaged in semantic PPA? We found that, in controls, left inferior frontal and left posterior temporal regions were functionally modulated by syntactic processing (quantified in terms of syntactic complexity or trial-by-trial RT). Anterior temporal regions were not consistently modulated. In the semantic PPA group, atrophy was most severe in the ATLs but extended to the posterior temporal regions involved in syntactic processing. Atrophy also overlapped with regions involved in syntactic processing in controls in the anterior insula bilaterally.

The second question was whether spared syntactic processing in semantic PPA depends on preserved functionality of intact regions, preserved functionality of atrophic regions, or compensatory functional reorganization. We found that the brain regions modulated by syntactic processing in semantic PPA were similar in most respects to those observed in controls; in particular, there were no significant differences in whole-brain analyses comparing patients and controls in the regions modulated by syntactic complexity or RT. This suggests that spared syntactic processing in semantic PPA depends on preserved functionality of intact regions (lateral frontal regions) as well as preserved functionality of moderately atrophic regions (posterior temporal cortex and the anterior insula). Although there were some significant differences in functional activity between semantic PPA patients and controls (discussed below), there were no patterns suggestive of functional reorganization, that is, no novel regions were modulated by syntactic processing in semantic PPA.

The Role of the ATL in Sentence Processing

In controls and in semantic PPA patients, the ATL was only inconsistently modulated by syntactic complexity and RT (Figure 6), so no ATL regions were significantly activated in either controls or semantic PPA patients. This is consistent with prior studies of syntactic processing, which have shown that frontal and posterior temporal regions are activated for syntactically complex conditions relative to simpler ones, but not the ATL (e.g., Bornkessel, Zysset, Friederici, von Cramon, & Schlesewsky, 2005; Stromswold, Caplan, Alpert, & Rauch, 1996).

Because the ATL is not modulated by syntactic complexity, yet is activated for sentences relative to word lists, some authors have raised the possibility that the ATL may be involved in early stages of parsing and syntactic structure-building that may not differ as a function of syntactic complexity (Humphries et al., 2006; Friederici & Kotz, 2003). In our view, it would be surprising if the processes of reactivation and/or reanalysis that take place in complex sentence processing did not make additional demands on basic parsing mechanisms. Besides this theoretical consideration, there are two respects in which our data are inconsistent with a role for the ATL in basic syn-

tactic structure-building. First, the semantic PPA patients showed severe atrophy of the ATL, including almost 40% volume loss in a temporal pole ROI that was defined based on coordinates from the relevant literature. Although this atrophy was sufficient to cause severe lexical semantic deficits, syntactic processing was largely spared, with a mean accuracy of 86.1% correct. The difference in accuracy between patients and controls was just 7%, and although this difference was statistically significant, its small magnitude confirmed that syntactic processing is largely spared in semantic PPA, consistent with previous literature (Wilson et al., 2011; Cotelli et al., 2007; Grossman et al., 2005; Gorno-Tempini et al., 2004; Hodges et al., 1992; Warrington, 1975; see Wilson et al., 2012, for a review). Second, the ATL was not activated for sentence comprehension relative to rest in the controls or semantic PPA patients. If the ATL were involved in basic syntactic structure-building, we would have expected activation in all seven conditions, because even canonical sentences require syntactic structure-building.

Not only was the ATL not activated by our sentence comprehension task relative to rest, but in the control group, the ventral ATL was robustly deactivated. This was a surprising finding, because most of the previous studies comparing sentences and word lists have reported positive ATL activation for sentences compared with rest (Rogalsky & Hickok, 2009; Humphries et al., 2001, 2005, 2006; Xu et al., 2005; Friederici et al., 2000; Stowe et al., 1999; Mazoyer et al., 1993). The deactivation of the ATL in our study is almost certainly a consequence of our sentence-to-picture matching task. The ventral ATL is one of the set of regions consistently deactivated for attention-demanding cognitive tasks relative to rest (Shulman et al., 1997). Why then has the ATL not shown deactivation in previous sentence processing studies? A likely explanation is that the ATL is an important node of the semantic system (Binder, Desai, Graves, & Conant, 2009), and its deactivation in attention-demanding cognitive tasks reflects reduced conceptual processing (Binder et al., 1999). Many previous sentence processing studies used passive listening (e.g., Humphries et al., 2005), very simple tasks (e.g., Vandenberghe et al., 2002), or explicitly semantic tasks (Humphries et al., 2006), all of which likely promote semantic processing of the stimuli.

Intriguingly, the ventral ATL was not deactivated for sentence comprehension relative to rest in the semantic PPA patients. This indicates that the ATL is not just atrophic in semantic PPA, but it is also functionally abnormal. If our speculation is correct that the ATL deactivation in controls reflects a reduction of resting state conceptual processing, this lack of deactivation could be taken to imply reduced resting state conceptual processing in semantic PPA, which would be consistent with the fundamentally semantic nature of this syndrome.

On the basis of the arguments above, the role of the ATL in sentence processing is unlikely to relate to syntactic structure-building. Why then is the ATL so reliably

activated for sentences relative to word lists? As many authors have suggested, we believe the role of the activation of the ATL in these contrasts reflects combinatorial semantic processing (Vandenberghe et al., 2002). However, it is important to define what is meant by “combinatorial semantic processing,” because syntactic processing is also combinatorial: building a syntactic structure for a sentence tells us “who did what to whom.” That is, building a syntactic structure relates the words in the sentence to one another, connecting determiners to nouns, noun phrases to slots in verb argument structure, and so on. An insightful illustration of combinatorial semantic processing that clearly distinguishes it from combinatorial syntactic processing is provided by Humphries, Binder, Medler, and Liebenthal (2007), drawing on earlier work from Barsalou (1982). They note that, in the sentence *The shipwreck victim survived by clinging to a basketball*, the meaning of *basketball* takes on a crucial aspect of meaning that is absent in isolation: The property of basketballs that they *float* is made salient. In another example, *The man on vacation lost a bag and a wallet*, the word *bag* in isolation has many possible meanings (e.g., garbage bag, tea bag, etc.), but the sentential context refines the meaning to suitcases, duffel bags, and the like.

In support of the view that combinatorial semantic processing explains ATL activation for sentences, Vandenberghe et al. (2002) reported that a subregion of the ATL showed more activity for sentences than word lists only when the sentences were semantically coherent. Pallier et al. (2011) reported that the ATL was modulated by syntactic constituent size only when stimuli contained real words and not when they contained pseudowords. This appears to contradict previous studies showing activation for syntactic structure even with pseudowords (Humphries et al., 2006; Friederici et al., 2000; Mazoyer et al., 1993). The discrepancy between these studies almost certainly reflects task differences. For instance, Humphries et al. (2006) asked participants to rate the meaningfulness of stimuli on a 4-point scale. We speculate that being asked to rate the meaningfulness of pseudoword sentences leads participants to attempt to infer meanings for pseudowords, possibly based on formal similarities to real words, and to attempt to relate the pseudowords to one another. Consider, for instance, *Twas brillig, and the slithy toves*, the first line of *The Jabberwocky*. The syntactic structure implies that *slithy* is an adjective, and lexical neighbors such as *sly*, *slimy*, *slippery*, and *sleazy* come to mind. These tend to give rise to the impression that whatever *toves* are; they are probably not very nice. Indeed later in *Through the Looking Glass*, Humpty Dumpty tells Alice that *slithy* is a portmanteau of *slimy* and *lithe* and that *toves* are something like lizards, something like badgers, and something like corkscrews. We can speculate that when participants make inferences about the meaning of *slithy* that restrict the meaning of *toves*, they are engaging in combinatorial semantic processing that relies on the ATL.

Further support for a semantic function of the ATL comes from studies of discourse-level comprehension that have shown greater activation of the ATL for sentences that were linked together to form a coherent narrative than sentences that bore no relation to one another (Xu et al., 2005; Fletcher et al., 1995) and strong correlations in the time course of ATL activity across participants listening to the same narratives (Wilson, Molnar-Szakacs, & Iacoboni, 2008).

We noted above that the ATL has been implicated in two aspects of language: lexical semantics (Patterson et al., 2007) and sentence-level processing. The literatures related to these two seemingly distinct functions have rarely intersected. However, if the sentence-level role of the ATL involves combinatorial semantic processing as defined above, then we can suggest that the role of the ATL in sentence processing is not distinct from its role in lexical semantics, but rather follows directly from it. When lexical items are brought together in relation to one another in sentences and in discourses, their meanings are narrowed, expanded, shifted, and refined by the contexts in which they occur. If the core function of the ATL is the representation and processing of lexical semantic information, then it follows that it will be more activated for sentences than word lists, and discourses than sentences, because the more context there is, the greater the extent to which lexical semantic representations can be refined.

Our sentence comprehension task was deliberately limited in lexical semantic content: There were only two nouns, seven verbs, and three adjectives employed in the entire set of stimuli. Furthermore, because it was a sentence-to-picture matching task, the entities and actions referred to by the lexical items were apparent in advance of hearing each sentence. Under these conditions, little to no combinatorial semantic processing is necessary or perhaps even possible, which may explain why the ATL was not modulated by syntactic complexity, or even activated for the sentence comprehension task relative to rest, and why severe damage to the ATL in semantic PPA has little effect on performance on this task.

Lateral Frontal Cortex: Preserved Functionality of Structurally Intact Regions

Left inferior frontal regions were modulated by syntactic complexity, modulated by RT, and activated for the sentence comprehension task relative to rest in controls and in patients with semantic PPA. Numerous functional imaging studies have shown inferior frontal regions to be differentially recruited for the processing of syntactically complex sentences relative to simpler ones (Bornkessel et al., 2005; Stromswold et al., 1996).

Although there were no differences between patients and controls in frontal regions modulated by syntactic complexity or RT, activation for the sentence comprehension task relative to rest extended more anteriorly into

the pars triangularis in patients with semantic PPA (Figure 5D). An almost identical region showed increased activation for this contrast in nonfluent/agrammatic PPA patients relative to controls (Wilson, Dronkers, et al., 2010). Increased prefrontal activation has been observed in many studies of normal aging as well as dementia and other neurological conditions and may reflect domain-general compensatory processes (Park & Reuter-Lorenz, 2009).

The preserved functionality of lateral frontal regions in semantic PPA, in particular the posterior IFG, contrasts with our previous findings in patients with the nonfluent/agrammatic variant of PPA, in whom these regions showed abnormal functional activity (Wilson, Dronkers, et al., 2010). Taken together with those findings, our present results suggest that spared syntax in semantic PPA depends in part on preserved functionality in these structurally intact lateral frontal regions.

Posterior Temporal Cortex and Anterior Insula: Preserved Functionality of Atrophic Regions

The left posterior STS, MTG, and adjacent regions were modulated by syntactic complexity, modulated by RT, and activated for the sentence comprehension task relative to rest in controls and in patients with semantic PPA. Posterior temporal regions have been implicated in syntactic processing in functional neuroimaging (e.g., Friederici, Makuuchi, & Bahlmann, 2009; Bornkessel et al., 2005) and neuropsychological (Dronkers et al., 2004) studies and may play a central role in syntactic structure-building (Bornkessel-Schlesewsky & Schlewsky, 2013) or may constitute an interface between syntax and the lexicon (Friederici et al., 2009; Snijders et al., 2009).

The preserved functionality of posterior temporal cortex in patients is noteworthy because these regions showed significant atrophy. Although volume loss was most severe in the ATLS (~40% volume loss), posterior temporal regions were not spared; almost every patient had less tissue in this region than the control mean, and mean volume loss was approximately 20% (Figure 6A). This suggests that spared syntactic processing in semantic PPA depends in part on preserved functionality of moderately atrophic left posterior temporal regions.

Although whole-brain analyses did not show any differences between semantic PPA patients and controls in posterior temporal cortex, the more sensitive ROI analysis showed that there was less modulation by RT in the posterior STS (Figure 6C) and that patients with more extensive atrophy in this region showed less modulation by RT (Figure 7D). These findings should be treated with caution, however, because there was no such effect for modulation by syntactic complexity (Figure 6B). It is noteworthy that neither atrophy nor functional changes in the posterior STS were correlated with accuracy (but cf. Bright, Moss, Stamatakis, & Tyler, 2008; Peelle et al., 2008). This is consistent with our interpretation that the

extension of atrophy into posterior temporal cortex in semantic PPA has minimal consequences for the functional status of this region, but an alternative explanation could be that posterior temporal regions are less critical for syntactic processing than left frontal cortex.

Volume loss in the left anterior insula, as well as other frontal regions, was associated with less accurate performance on the sentence comprehension task (Figure 7A and B). Volume loss in the anterior insula was also associated with less functional modulation by syntactic complexity, and there was some indication that these functional changes mediated the performance deficits. The role of the anterior insula in this context likely relates to domain-general cognitive control and attention (Dosenbach et al., 2006). Some of the minimal syntactic deficits observed in semantic PPA may reflect the extension of atrophy into the anterior insula and other frontal regions important for cognitive and executive processes that support syntactic processing.

Conclusion

In summary, our results show that spared syntactic processing in semantic PPA depends on preserved functionality of structurally intact left frontal regions and moderately atrophic left posterior temporal regions, but there is no functional reorganization apparent as a consequence of anterior temporal atrophy and dysfunction. We have argued that the role of the ATL in sentence processing is less likely to relate to syntactic structure-building and more likely to relate to higher level processes such as combinatorial semantic processing.

Acknowledgments

This research was supported in part by the National Institutes of Health (NIDCD R03 DC010878, NINDS R01 NS050915, NIA P50 AG03006, NIA P01 AG019724). We thank Nina Dronkers for helpful discussions; Jenny Ogar for patient testing; Laura Calverley for drawing the stimulus pictures; Max Besbris, Paul Keselman, and Lara Stables for assistance with functional imaging; Matthew Growdon, Jung Jang, Michael Neylan, and Henry Rodriguez for administrative assistance; all of the members of the UCSF Memory and Aging Center who contributed to patient evaluation and care; and the patients, caregivers, and volunteers for their participation in our research.

Reprint requests should be sent to Stephen M. Wilson, Department of Speech, Language and Hearing Sciences, University of Arizona, P.O. Box 210071, Tucson, AZ 85721, or via e-mail: smwilson@u.arizona.edu.

REFERENCES

- Ashburner, J. (2007). A fast diffeomorphic image registration algorithm. *Neuroimage*, *38*, 95–113.
- Ashburner, J., & Friston, K. J. (2005). Unified segmentation. *Neuroimage*, *26*, 839–851.
- Barsalou, L. W. (1982). Context-independent and context-dependent information in concepts. *Memory & Cognition*, *10*, 82–93.

- Beckmann, C. F., & Smith, S. M. (2004). Probabilistic independent component analysis for functional magnetic resonance imaging. *IEEE Transactions on Medical Imaging*, *23*, 137–152.
- Binder, J. R., Desai, R. H., Graves, W. W., & Conant, L. L. (2009). Where is the semantic system? A critical review and meta-analysis of 120 functional neuroimaging studies. *Cerebral Cortex*, *19*, 2767–2796.
- Binder, J. R., Frost, J. A., Hammeke, T. A., Bellgowan, P. S. F., Rao, S. M., & Cox, R. W. (1999). Conceptual processing during the conscious resting state: A functional MRI study. *Journal of Cognitive Neuroscience*, *11*, 80–93.
- Bornkessel, I., Zysset, S., Friederici, A. D., von Cramon, D. Y., & Schlesewsky, M. (2005). Who did what to whom? The neural basis of argument hierarchies during language comprehension. *NeuroImage*, *26*, 221–233.
- Bornkessel-Schlesewsky, I., & Schlesewsky, M. (2013). Reconciling time, space and function: A new dorsal-ventral stream model of sentence comprehension. *Brain and Language*, *125*, 60–76.
- Brennan, J., Nir, Y., Hasson, U., Malach, R., Heeger, D. J., & Pykkänen, L. (2012). Syntactic structure building in the anterior temporal lobe during natural story listening. *Brain and Language*, *120*, 163–173.
- Bright, P., Moss, H. E., Stamatakis, E. A., & Tyler, L. K. (2008). Longitudinal studies of semantic dementia: The relationship between structural and functional changes over time. *Neuropsychologia*, *46*, 2177–2188.
- Cotelli, M., Borroni, B., Manenti, R., Ginex, V., Calabria, M., Moro, A., et al. (2007). Universal grammar in the frontotemporal dementia spectrum: Evidence of a selective disorder in the corticobasal degeneration syndrome. *Neuropsychologia*, *45*, 3015–3023.
- Cox, R. W. (1996). AFNI: Software for analysis and visualization of functional magnetic resonance neuroimages. *Computers and Biomedical Research*, *29*, 162–173.
- Dosenbach, N. U., Visscher, K. M., Palmer, E. D., Miezin, F. M., Wenger, K. K., Kang, H. C., et al. (2006). A core system for the implementation of task sets. *Neuron*, *50*, 799–812.
- Dronkers, N. F., Wilkins, D. P., Van Valin, R. D., Jr., Redfern, B. B., & Jaeger, J. J. (2004). Lesion analysis of the brain areas involved in language comprehension. *Cognition*, *92*, 145–177.
- Fletcher, P. C., Happe, F., Frith, U., Baker, S. C., Dolan, R. J., Frackowiak, R. S. J., et al. (1995). Other minds in the brain: A functional imaging study of “theory of mind” in story comprehension. *Cognition*, *57*, 109–128.
- Friederici, A. D., & Kotz, S. A. (2003). The brain basis of syntactic processes: Functional imaging and lesion studies. *NeuroImage*, *20*(Suppl. 1), S8–S17.
- Friederici, A. D., Makuuchi, M., & Bahlmann, J. (2009). The role of the posterior superior temporal cortex in sentence comprehension. *NeuroReport*, *20*, 563–568.
- Friederici, A. D., Meyer, M., & von Cramon, D. Y. (2000). Auditory language comprehension: An event-related fMRI study on the processing of syntactic and lexical information. *Brain and Language*, *75*, 289–300.
- Gorno-Tempini, M. L., Dronkers, N. F., Rankin, K. P., Ogar, J. M., Phengrasamy, L., Rosen, H. J., et al. (2004). Cognition and anatomy in three variants of primary progressive aphasia. *Annals of Neurology*, *55*, 335–346.
- Gorno-Tempini, M. L., Hillis, A. E., Weintraub, S., Kertesz, A., Mendez, M., Cappa, S. F., et al. (2011). Classification of primary progressive aphasia and its variants. *Neurology*, *76*, 1006–1014.
- Grossman, M., Rhee, J., & Moore, P. (2005). Sentence processing in frontotemporal dementia. *Cortex*, *41*, 764–777.
- Hodges, J. R., Patterson, K., Oxbury, S., & Funnell, E. (1992). Semantic dementia. Progressive fluent aphasia with temporal lobe atrophy. *Brain*, *115*, 1783–1806.
- Holland, R., & Lambon Ralph, M. A. (2010). The anterior temporal lobe semantic hub is a part of the language neural network: Selective disruption of irregular past tense verbs by rTMS. *Cerebral Cortex*, *20*, 2771–2775.
- Humphries, C., Binder, J. R., Medler, D. A., & Liebenthal, E. (2006). Syntactic and semantic modulation of neural activity during auditory sentence comprehension. *Journal of Cognitive Neuroscience*, *18*, 665–679.
- Humphries, C., Binder, J. R., Medler, D. A., & Liebenthal, E. (2007). Time course of semantic processes during sentence comprehension: An fMRI study. *NeuroImage*, *36*, 924–932.
- Humphries, C., Love, T., Swinney, D., & Hickok, G. (2005). Response of anterior temporal cortex to syntactic and prosodic manipulations during sentence processing. *Human Brain Mapping*, *26*, 128–138.
- Humphries, C., Willard, K., Buchsbaum, B., & Hickok, G. (2001). Role of anterior temporal cortex in auditory sentence comprehension: An fMRI study. *NeuroReport*, *12*, 1749–1752.
- Kapur, N., Barker, S., Burrows, E. H., Ellison, D., Brice, J., Illis, L. S., et al. (1994). Herpes simplex encephalitis: Long term magnetic resonance imaging and neuropsychological profile. *Journal of Neurology, Neurosurgery, and Psychiatry*, *57*, 1334–1342.
- Kelly, R. E., Jr., Alexopoulos, G. S., Wang, Z., Gunning, F. M., Murphy, C. F., Morimoto, S. S., et al. (2010). Visual inspection of independent components: Defining a procedure for artifact removal from fMRI data. *Journal of Neuroscience Methods*, *189*, 233–245.
- Kho, K. H., Indefrey, P., Hagoort, P., van Veelen, C. W. M., van Rijen, P. C., & Ramsey, N. F. (2008). Unimpaired sentence comprehension after anterior temporal cortex resection. *Neuropsychologia*, *46*, 1170–1178.
- Kramer, J. H., Jurik, J., Sha, S. J., Rankin, K. P., Rosen, H. J., Johnson, J. K., et al. (2003). Distinctive neuropsychological patterns in frontotemporal dementia, semantic dementia, and Alzheimer disease. *Cognitive and Behavioral Neurology*, *16*, 211–218.
- Magnusdottir, S., Fillmore, P., den Ouden, D. B., Hjaltason, H., Rorden, C., Kjartansson, O., et al. (2013). Damage to left anterior temporal cortex predicts impairment of complex syntactic processing: A lesion-symptom mapping study. *Human Brain Mapping*, *34*, 2715–2723.
- Mazoyer, B. M., Tzourio, N., Frak, V., Syrota, A., Murayama, N., Levrier, O., et al. (1993). The cortical representation of speech. *Journal of Cognitive Neuroscience*, *5*, 467–479.
- Noppeney, U., & Price, C. J. (2004). An fMRI study of syntactic adaptation. *Journal of Cognitive Neuroscience*, *16*, 702–713.
- Pallier, C., Devauchelle, A. D., & Dehaene, S. (2011). Cortical representation of the constituent structure of sentences. *Proceedings of the National Academy of Sciences, U.S.A.*, *108*, 2522–2527.
- Park, D. C., & Reuter-Lorenz, P. (2009). The adaptive brain: Aging and neurocognitive scaffolding. *Annual Review of Psychology*, *60*, 173–196.
- Patterson, K., Nestor, P. J., & Rogers, T. T. (2007). Where do you know what you know? The representation of semantic knowledge in the human brain. *Nature Reviews Neuroscience*, *8*, 976–987.
- Peelle, J. E., Troiani, V., Gee, J., Moore, P., McMillan, C., Vesely, L., et al. (2008). Sentence comprehension and voxel-based morphometry in progressive nonfluent aphasia,

- semantic dementia, and nonaphasic frontotemporal dementia. *Journal of Neurolinguistics*, *21*, 418–432.
- Penfield, W., & Roberts, L. (1959). *Speech and brain-mechanisms*. Princeton, NJ: Princeton University Press.
- Rogalsky, C., & Hickok, G. (2009). Selective attention to semantic and syntactic features modulates sentence processing networks in anterior temporal cortex. *Cerebral Cortex*, *19*, 786–796.
- Shulman, G. L., Fiez, J. A., Corbetta, M., Buckner, R. L., Miezin, F. M., Raichle, M. E., et al. (1997). Common blood flow changes across visual tasks: II. Decreases in cerebral cortex. *Journal of Cognitive Neuroscience*, *9*, 648–663.
- Snijders, T. M., Vosse, T., Kempen, G., Van Berkum, J. J., Petersson, K. M., & Hagoort, P. (2009). Retrieval and unification of syntactic structure in sentence comprehension: An fMRI study using word-category ambiguity. *Cerebral Cortex*, *19*, 1493–1503.
- Snowden, J. S., Goulding, P. J., & Neary, D. (1989). Semantic dementia: A form of circumscribed cerebral atrophy. *Behavioural Neurology*, *2*, 167–182.
- Stowe, L. A., Paans, A. M., Wijers, A. A., Zwarts, F., Mulder, G., & Vaalburg, W. (1999). Sentence comprehension and word repetition: A positron emission tomography investigation. *Psychophysiology*, *36*, 786–801.
- Stromswold, K., Caplan, D., Alpert, N., & Rauch, S. (1996). Localization of syntactic comprehension by positron emission tomography. *Brain and Language*, *52*, 452–473.
- Tzourio-Mazoyer, N., Landeau, B., Papathanassiou, D., Crivello, F., Etard, O., Delcroix, N., et al. (2002). Automated anatomical labeling of activations in SPM using a macroscopic anatomical parcellation of the MNI MRI single-subject brain. *Neuroimage*, *15*, 273–289.
- Vandenberghe, R., Nobre, A. C., & Price, C. J. (2002). The response of left temporal cortex to sentences. *Journal of Cognitive Neuroscience*, *14*, 550–560.
- Warrington, E. K. (1975). The selective impairment of semantic memory. *Quarterly Journal of Experimental Psychology*, *27*, 635–657.
- Wilson, S. M., Dronkers, N. F., Ogar, J. M., Jang, J., Growdon, M. E., Agosta, F., et al. (2010). Neural correlates of syntactic processing in the nonfluent variant of primary progressive aphasia. *Journal of Neuroscience*, *30*, 16845–16854.
- Wilson, S. M., Galantucci, S., Tartaglia, M. C., & Gorno-Tempini, M. L. (2012). The neural basis of syntactic deficits in primary progressive aphasia. *Brain and Language*, *122*, 190–198.
- Wilson, S. M., Galantucci, S., Tartaglia, M. C., Rising, K., Patterson, D. K., Henry, M. L., et al. (2011). Syntactic processing depends on dorsal language tracts. *Neuron*, *72*, 397–403.
- Wilson, S. M., Henry, M. L., Besbris, M., Ogar, J. M., Dronkers, N. F., Jarrold, W., et al. (2010). Connected speech production in three variants of primary progressive aphasia. *Brain*, *133*, 2069–2088.
- Wilson, S. M., Molnar-Szakacs, I., & Iacoboni, M. (2008). Beyond superior temporal cortex: Intersubject correlations in narrative speech comprehension. *Cerebral Cortex*, *18*, 230–242.
- Worsley, K. J., Liao, C. H., Aston, J., Petre, V., Duncan, G. H., Morales, F., et al. (2002). A general statistical analysis for fMRI data. *Neuroimage*, *15*, 1–15.
- Xu, J., Kemeny, S., Park, G., Frattali, C., & Braun, A. (2005). Language in context: Emergent features of word, sentence, and narrative comprehension. *Neuroimage*, *25*, 1002–1015.