

Parahippocampal and Entorhinal Resection Extent Predicts Verbal Memory Decline in an Epilepsy Surgery Cohort

Anli Liu, Thomas Thesen, William Barr, Chris Morrison, Patricia Dugan, Xiuyuan Wang, Michael Meager, Werner Doyle, Ruben Kuzniecky, Orrin Devinsky, and Karen Blackmon

Abstract

■ The differential contribution of medial-temporal lobe regions to verbal declarative memory is debated within the neuroscience, neuropsychology, and cognitive psychology communities. We evaluate whether the extent of surgical resection within medial-temporal regions predicts longitudinal verbal learning and memory outcomes. This single-center retrospective observational study involved patients with refractory temporal lobe epilepsy undergoing unilateral anterior temporal lobe resection from 2007 to 2015. Thirty-two participants with Engel Class 1 and 2 outcomes were included (14 left, 18 right) and followed for a mean of 2.3 years after surgery (± 1.5 years). Participants had baseline and postsurgical neuropsychological testing and high-resolution T1-weighted MRI scans. Postsurgical lesions were manually traced and coregistered to presurgical scans to pre-

cisely quantify resection extent of medial-temporal regions. Verbal learning and memory change scores were regressed on hippocampal, entorhinal, and parahippocampal resection volume after accounting for baseline performance. Overall, there were no significant differences in learning and memory change between patients who received left and right anterior temporal lobe resection. After controlling for baseline performance, the extent of left parahippocampal resection accounted for 27% ($p = .021$) of the variance in verbal short delay free recall. The extent of left entorhinal resection accounted for 37% ($p = .004$) of the variance in verbal short delay free recall. Our findings highlight the critical role that the left parahippocampal and entorhinal regions play in recall for verbal material. ■

INTRODUCTION

The differential role of medial-temporal lobe regions in verbal declarative learning and memory is the subject of ongoing debate. Declarative memory refers to the conscious learning of facts and events (Squire & Zola, 1996; Squire, 1992). It has been clear since the early days of anteromesial temporal lobe epilepsy surgery in humans that the hippocampus is critical for initial formation of declarative memories (Scoville & Milner, 1957). Primate studies reveal that lesions involving the hippocampal, parahippocampal, and perirhinal cortex produce worse memory impairment than lesions involving the hippocampal formation alone (Zola-Morgan, Squire, Clower, & Rempel, 1993; Zola-Morgan, Squire, Amaral, & Suzuki, 1989). Likewise, larger medial-temporal lesions, including entorhinal and parahippocampal cortex, more consistently lead to impairment in delayed nonmatching to sample tasks compared with hippocampal-only lesions (Malkova & Mishkin, 2003; Gaffan, 1994; Murray, Gaffan, & Mishkin, 1993; Zola-Morgan et al., 1993).

Patients undergoing epilepsy surgery provide a means to investigate the mnemonic contributions of different medial-temporal subregions, as these regions may be surgically removed to a varying degree if implicated in the seizure network. For patients with medication-refractory epilepsy, the best option for achieving seizure freedom is surgical resection, with 30–80% of patients attaining this outcome (Tellez-Zenteno, Dhar, & Wiebe, 2005). For patients with temporal lobe epilepsy, rates of seizure freedom following unilateral anteromesial temporal lobe resection (ATLR) are higher, between 66% and 70% (Spencer & Huh, 2008). In a recent meta-analysis, seizure outcomes following standard ATLR are superior to selective amygdalohippocampectomy (Josephson et al., 2013).

However, negative consequences such as memory impairment are also common (Sherman et al., 2011). Memory subtypes appear highly lateralized, as impairment across a variety of episodic memory tasks has been demonstrated with left ATLR, but not right ATLR (Barr, Goldberg, Wasserstein, & Novelly, 1990). Between 22% and 63% of individuals who undergo unilateral left ATLR experience decline in verbal memory (Sherman et al., 2011), though

there is a considerable amount of variability in degree of verbal memory change (Hermann, Seidenberg, Haltiner, & Wyler, 1995).

Patients who undergo larger unilateral temporal lobe resections perform worse on an verbal associative learning and recall tasks than patients who had smaller surgeries (Helmstaedter, Petzold, & Bien, 2011; Helmstaedter, Roeske, Kaaden, Elger, & Schramm, 2011), suggesting that medial-temporal regions other than the hippocampus support verbal declarative memory formation. There is a strong correlation between 18F-fluorodeoxyglucose uptake in the left perirhinal cortex and learning of arbitrary word pairs in patients with left temporal lobe epilepsy (Weintrob, Saling, Berkovic, Berlangieri, & Reutens, 2002). Similarly, the structural integrity of the left perirhinal region, as measured by MRI T2 relaxation time, is associated with learning of arbitrary relational verbal material, whereas consolidation of the material is related to hippocampal integrity (Lillywhite et al., 2007). Furthermore, regional blood flow measured by PET [¹⁵O]H₂O during a task involving unrelated verbal word pairs implicates a predominantly left-sided network including dorsolateral pFC, fusiform, parahippocampal, perirhinal cortices, and posterior cingulate structures (Weintrob, 2004). Saling has proposed a two-part model for verbal memory involving the left temporal lobe: (1) a mesial protosemantic component responsible for arbitrary paired associated learning and (2) a lateral semantic component when semantic meaning is required (e.g., during related paired associates or passage learning; Saling, 2009). Furthermore, Fernández and Tendolkar (2006) propose that rhinal cortex acts as a “gatekeeper” to the hippocampal formation, with the semantic status of the incoming information determining probability of transfer to the hippocampus (Fernández & Tendolkar, 2006).

Variance in neurosurgical practice and cognitive outcomes in the epilepsy surgical population provides a unique opportunity to understand the respective contributions of the entorhinal and parahippocampal regions to the formation and retention of new verbal memory traces in humans. Here, we introduce a novel approach for measuring the extent of entorhinal and parahippocampal resection in a case series of patients who underwent ATR. We segment the medial-temporal neocortical architecture of each individual participant on his or her high-resolution presurgical MRI scan and then coregister his or her postsurgical lesion mask to this native neuroanatomical map. This method allows for precise quantification of resection extent in medial-temporal lobe subregions and investigation of their particular contributions to longitudinal verbal declarative memory outcomes.

METHODS

This was a retrospective observational study conducted at New York University (NYU) Comprehensive Epilepsy Center at the NYU School of Medicine using data collected

from 2007 to 2015. This study was approved by the NYU School of Medicine institutional review board. All patients consented to participate in research MRI scanning and neuropsychological testing and to have their clinical records reviewed. All patients were adults diagnosed with medication-refractory focal epilepsy (defined as failure of at least two appropriately chosen and dosed antiepileptic medications) and were considered appropriate candidates for temporal lobe resection.

Clinical Variables

Participants' clinical data such as seizure type and frequency, age of seizure onset, duration of epilepsy, estimated lifetime number complex partial and secondarily generalized tonic-clonic seizures, and number of current antiepileptic medications were extracted from clinical records. The presence or absence of mesial temporal sclerosis was diagnosed using MRI criteria (i.e., hippocampal volume loss and increased T2 signal on T2-weighted imaging) and histopathological evaluation of resected surgical tissue. The intracarotid sodium amobarbital procedure (also known as the “Wada test”) variables included language lateralization (left/right/bilateral) and memory scores for the right and left hemisphere (discrimination of 12 target objects and pictures from 24 foils). Patients were followed clinically for at least 1 year to assess postsurgical clinical outcomes. Seizure type and frequency were used to determine their Engel class outcome (Engel 1 = seizure free, Engel 2 = rare disabling seizures, Engel 3 = worthwhile reduction in seizure frequency, Engel 4 = worthwhile improvement; 1992 Palm Desert Conference on Epilepsy Surgery).

Participant Population

There were 34 participants initially enrolled in this study, including 15 who underwent a left ATR and 19 who underwent a right ATR. Two participants were excluded from analyses because of poor postsurgical seizure outcomes (Engel class 3–4). The remaining group of 32 participants had a mean age of 35.5 years (range = 16–63 years) at time of surgery and mean postoperative follow-up of 2.41 years ($SD = 1.45$ years; Table 1). Mean age of seizure onset was 15.1 years (range = 1–47 years), with a mean duration of seizures of 18.9 years ($SD = 14.2$). About 41% of the cohort had mesial temporal sclerosis identified by pathology. Mean educational level was 15.0 years ($SD = 2.8$). At presurgical baseline testing, participants had an average IQ of 99.0 ($SD = 13.8$). As a group, patients had low depression (mean BDI = 9.3, $SD = 5.7$) and anxiety (mean = 11.3, $SD = 11.4$) scores. There were no differences in baseline or postsurgical demographic, clinical, or neuropsychological characteristics of patients who underwent a left- or right-sided ATR (Table 1), except that patients who received a left ATR showed a trend toward a lower left-sided Wada memory score at baseline

Table 1. Demographic and Baseline Clinical Characteristics of Participants (Engel Classes 1 and 2 Only, $N = 32$, Mean \pm SD)

	<i>All Participants</i>	<i>Left ATLR</i>	<i>Right ATLR</i>	<i>p</i>
<i>Demographic and Clinical Characteristics</i>				
Number of participants	$N = 32$	$N = 14$	$N = 18$	
Age at surgery (years, range)	35.53 (16–63)	36.57 \pm 9.35	34.72 \pm 13.54	.666
Sex (male/female)	17/15	8/6	9/9	.688
Education (years)	15.0 \pm 2.77	15.00 \pm 2.08	15.00 \pm 3.12	1.00
Ethnicity				
White	23 (71.9%)	10	13	.735 (Fisher's exact)
Black	4 (12.5%)	2	2	
Hispanic	4 (12.5%)	2	2	
Asian	1 (3.1%)	0	1	
Handedness (right/left/ambidextrous)	23/8/1	10/4/0	13/4/1	.636
Age at seizure onset (years)	15.06 (1–47)	15.71 \pm 10.36	14.56 \pm 11.24	.767
Duration of seizures (years)	18.88 \pm 14.18	18.93 \pm 13.34	18.83 \pm 15.18	.985
Years of follow-up after surgery (years)	2.41 \pm 1.45	2.51 \pm 1.46	2.34 \pm 1.50	.763
Mesial temporal sclerosis	13/17 (40.6%/53.1%)	4/9	9/8	.283
Engel class outcome				
Class 1	27 (84.4%)	11	16	.631
Class 2	5 (15.6%)	3	2	
<i>Baseline Neuropsychological Testing</i>				
FSIQ	99.04 \pm 13.76	98.83 \pm 13.99	99.19 \pm 14.05	.948
Verbal Comprehension Index	100.5 \pm 19.82	94.36 \pm 18.98	105.28 \pm 19.64	.124
Perceptual Reasoning Index	98.84 \pm 15.39	101.14 \pm 17.77	97.06 \pm 13.51	.465
Working Memory Index	93.78 \pm 18.64	99.50 \pm 10.06	89.50 \pm 22.49	.164
Processing Speed Index	93.72 \pm 19.71	97.75 \pm 10.91	90.88 \pm 24.02	.365
Verbal Learning	46.81 \pm 12.89	45.14 \pm 14.69	46.33 \pm 9.94	.404
Verbal SDFR	8.85 \pm 3.53	8.21 \pm 3.42	8.58 \pm 3.58	.190
Verbal LDFR	9.42 \pm 3.67	8.71 \pm 3.47	9.58 \pm 3.42	.346
Visual Confrontation Naming (BNT)	50.20 \pm 7.30	48.93 \pm 6.96	51.31 \pm 7.64	.382
Visual Memory (RCFT delay trial)	12.90 \pm 6.48	14.00 \pm 7.47	12.17 \pm 5.84	.458
BDI	9.26 \pm 5.73	9.15 \pm 5.90	9.36 \pm 5.79	.929
BAI	11.32 \pm 11.35	12.07 \pm 12.69	10.57 \pm 10.26	.734
Left Wada memory score	9.03 \pm 3.52	7.64 \pm 3.97	10.18 \pm 2.72	.055
Right Wada memory score	7.32 \pm 3.32	8.29 \pm 2.64	6.47 \pm 3.70	.138
Wada language (left/right/bilateral)	30/0/1	13/0/1	17/0/0	.452 (Fisher's exact)

Table 1. (continued)

	All Participants	Left ATLR	Right ATLR	<i>p</i>
<i>Postsurgical Neuropsychological Testing</i>				
FSIQ	99.61 ± 14.61	99.25 ± 11.35	99.88 ± 17.02	.913
Verbal Comprehension Index	103.93 ± 15.02	101.00 ± 9.83	106.00 ± 17.82	.387
Perceptual Reasoning Index	99.45 ± 13.58	101.33 ± 11.74	98.12 ± 14.95	.540
Working Memory Index	100.56 ± 14.76	103.45 ± 13.78	98.56 ± 15.50	.408
Processing Speed Index	97.18 ± 14.01	96.42 ± 14.79	97.75 ± 13.87	.809
Verbal Learning	42.56 ± 10.81	39.08 ± 10.77	46.33 ± 9.94	.094
Verbal SDFR	6.92 ± 3.67	5.38 ± 3.15	8.58 ± 3.58	.026
Verbal LDFR	7.60 ± 4.26	5.77 ± 4.30	9.58 ± 3.34	.022
Visual Confrontation Naming (BNT)	48.30 ± 8.81	44.36 ± 9.52	52.54 ± 5.70	.012
Visual Memory (RCFT delay trial)	10.97 ± 5.17	12.69 ± 5.66	9.56 ± 4.43	.106
BDI	8.13 ± 7.32	9.36 ± 8.23	7.12 ± 6.56	.406
BAI	6.84 ± 6.40	8.29 ± 7.97	5.64 ± 4.67	.260

Independent samples *t* test comparison performed with *p* values listed.

*Significant after correction for multiple comparisons.

(7.6 vs. 10.2, *p* = .055), as well as lower postsurgical verbal memory and naming scores, compared with patients who received a right-sided resection.

Neuropsychological Testing

Presurgical comprehensive neuropsychological testing was conducted as part of routine clinical practice. Postsurgical neuropsychological testing was acquired for research (at least 6 months following surgery) and included the same test battery administered presurgically. The neuropsychological test battery adhered to the National Institute of Neurological Disorders and Stroke common data elements protocol for epilepsy (Loring et al., 2011), with the exception of the California Verbal Learning Test-2nd Edition (CVLT-II), which was administered to patients before 2011. The Wechsler Adult Intelligence Scale-Third or Fourth Edition (WAIS-III or WAIS-IV) was administered to obtain the Full-Scale Intellectual Quotient (FSIQ). Participants completed standard questionnaires of mood functioning, including the Beck Anxiety Inventory (BAI; Beck & Steer, 1993) and Beck Depression Inventory-II (BDI-II; Beck, Steer, & Brown, 1996). Measurements of global cognitive functioning (FSIQ) and mood (BAI, BDI-II) were used to determine whether changes in these variables contributed to memory decline between pre- and postsurgical time points.

Verbal declarative memory was assessed with serial word list-learning tasks (Rey Auditory Verbal Learning Test or the CVLT-II; Taylor, 1959). On both of these list-learning

tasks, examinees are asked to learn a list of words (List A) across a series of five learning trials, given a second distraction word list (List B), and then they are asked to freely recall words from List A. Free recall of the List A words are tested after a brief (2 min) and long (20 min) delay. The total score across all five learning trials was used as a measure of verbal learning; the short delay free recall (SDFR) score represents verbal free recall after 2 min and the long delay free recall (LDFR) score represents verbal free recall after 20 min (Taylor, 1959). Raw scores across these two list-learning tasks are highly correlated in patients with closed head injuries whereas normalized scores differ (Stallings, Boake, & Sherer, 1995); therefore, raw scores were utilized for this study. Within an individual, the same list-learning task was administered pre- and postsurgically. Longitudinal change in verbal declarative learning and memory performance was assessed by subtracting the postsurgical test score from the presurgical test score. Negative scores indicate decline in performance, and positive scores indicate improvement. The following dependent variables were used in subsequent analyses of longitudinal change in neuropsychological performance: Change in Verbal Learning, Verbal SDFR (SDFR-change), and Verbal LDFR (LDFR-change).

To test the specificity of findings to verbal declarative memory, we calculated change scores for the Boston Naming Test (BNT), a measure of visual confrontation naming, and the Rey Complex Figure Test (RCFT)-Delayed Recall Trial, a measure of memory for visual material. Finally, we calculated change scores for the BAI and BDI

to ensure that changes in verbal declarative memory were not associated with changes in mood or anxiety.

MRI Scanning Protocol

Before resective epilepsy surgery, all patients completed a high-resolution T1-weighted MPRAGE (echo time = 3.25 msec, repetition time = 2530 msec, inversion time = 1100 msec, flip angle = 7°, field of view = 256 mm, matrix = 256x256, voxel size = 1 × 1 × 1.3 mm) on a Siemens (Erlangen, Germany) Allegra 3T research-dedicated MR scanner. Immediately following resective surgery (i.e., within 24 hr), a clinical MRI scanning protocol was acquired at the NYU Department of Radiology on 1.5-T and 3-T Siemens scanners. In many patients, an additional postsurgical MRI scan was acquired at a second time point more remote to surgery (i.e., more than 6 months to 1 year after surgery); however, in these remote MRI scans there was evidence of brain shift, which tended to increase error in the coregistration of postsurgical to presurgical MRI scans. Error associated with brain shift over time was greater than error associated with immediate postsurgical brain swelling; therefore, in all cases the MRI scan that was acquired proximal to surgery was utilized. Postsurgical image acquisitions were used for manual tracing of the surgical lesion and included a high-resolution T1-weighted volume (MPRAGE) and a T2-weighted FLAIR volume, which was used to improve visualization of postsurgical lesion extent.

Quantifying Surgical Lesion Extent

Surgical lesion extent for specific temporal lobe subregions was quantified by (1) anatomical labeling of the high-resolution presurgical MRI scan (see below), (2) slice-by-slice manual tracing of lesion extent on the postsurgical

MRI, (3) rigid body coregistration of the postsurgical MRI lesion mask to the native presurgical MRI scan, and (4) quantification of the percentage of each labeled subregion that was surgically resected. By coregistering the postsurgical lesion mask to an individual's presurgical MRI rather than a standard neuroanatomical atlas, this procedure preserves native architectural features and allows for precise delineation of subregion lesion extent. These steps are outlined in more detail below.

Neuroanatomical Labeling of Subcortical Structures and Cortical Regions on Presurgical Scans

Subcortical Segmentation and Labeling

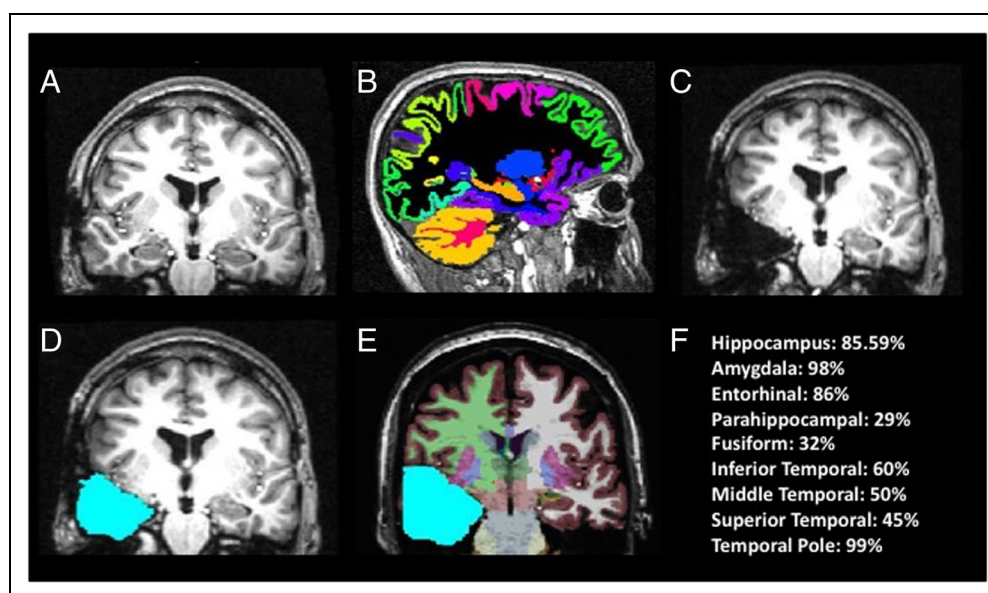
Presurgical images were processed with FreeSurfer 5.1 software package (surfer.nmr.mgh.harvard.edu). Segmentation and labeling of subcortical structures (see Figure 1) was performed by rigid body alignment of the participant's brain to a probabilistic atlas, followed by nonlinear morphing to the atlas. Labels were generated based on the prior probability of a given tissue class occurring at a specific atlas location, the likelihood of the image intensity given that tissue class, and the probability of the local spatial configuration of labels given the tissue class (Fischl et al., 2002). Labels were manually inspected and, in rare cases, corrected if necessary. ROIs for the current study include the hippocampus, entorhinal, and parahippocampal regions.

Cortical Surface Reconstruction, Segmentation, and Labeling

Freesurfer 5.1 was used to reconstruct, segment, and label the cortical sheet. These procedures are described in detail in prior publications (Fischl, Sereno, & Dale, 1999; Fischl

Figure 1. Methods for precise delineation and quantification of surgical resection extent.

(A) Presurgical T1-weighted scan is (B) segmented with FreeSurfer software for labeling of individual subcortical and cortical anatomy. (C) Post-surgical T1 is coregistered to presurgical T1 MPRAGE. (D) Resection mask is drawn with respect to presurgical boundaries. (E) Resection mask is overlaid on presurgical scan with subcortical and cortical labeling. (F) Percentage of tissue resected for each labeled structure/region.



et al., 2002; Dale, Fischl, & Sereno, 1999). In brief, processing steps included segmentation of gray matter and white matter, inflation and flattening of the cortical surface, and automatic correction of topological defects. First, intensity variations due to magnetic field inhomogeneities are corrected; a normalized intensity image is created; and the skull is removed from the high-resolution, T1-weighted, anatomical MR image. The cortical gray matter ribbon is segmented, and the resulting surface is covered with a polygonal tessellation and smoothed to reduce metric distortions. After constructing the initial surface model, a refinement procedure delineates the gray/white interface. This surface is subsequently deformed outwards to obtain an explicit representation of the pial surface. Then, an automated method for subdividing the human cerebral cortex into standard gyral-based neuroanatomical regions is applied (Desikan et al., 2006). This method results in the neuroanatomic labeling of 34 cortical regions (see Figure 1B) and corresponding white matter regions. The following ROIs were analyzed given that they are typically included (to varying degrees) in a standard ATLR: entorhinal, fusiform gray matter, parahippocampal, inferior temporal lobe, middle temporal lobe, superior temporal lobe, temporal pole.

Manual Lesion Tracing and Estimation of Resection Percentages

Before lesion tracing, the postoperative T1-weighted and FLAIR images were coregistered to the preoperative T1-weighted image using rigid body linear transformation algorithms. Surgical lesion masks were manually traced on the postsurgical T1-weighted scan, with the T2-weighted FLAIR image used to verify lesion boundaries (see Figure 1C–D). Lesion masks were crosschecked across the coronal, axial, and sagittal planes of the T1-weighted image. Each postoperative slice was visually reviewed against the presurgical segmentations, and if there was evidence of brain shift, then the masks were manually adjusted accordingly. These resection masks were then overlaid onto the neuroanatomical division maps of the individual patient to calculate the percentage of the subcortical and cortical regions that were removed (see Figure 1E–F). Total resection extent was calculated as a percentage of the total supratentorial brain volume. The hippocampus and amygdala resection extent was quantified as a percentage of total preoperative hippocampus and amygdala volume removed for each patient. Resection extent for entorhinal, parahippocampal, fusiform, temporal pole, superior temporal, middle temporal, and inferior temporal gray and white matter regions was quantified as a percentage of total preoperative area removed for each patient.

Statistical Analysis

Statistical analysis was performed with SPSS Version 22.0 (SPSS, Inc., Chicago, IL). Descriptive statistics, including

frequencies, means, and standard deviations, were calculated. An independent samples *t* test with a *p* value of .05 was used to determine differences for all continuous variables such as clinical, demographic, and baseline neuropsychological testing by side of surgery. For comparison between categorical variables such as Engel class outcome and side of surgery, a Fisher's exact test was used. For analysis of longitudinal neuropsychological outcomes, only Engel Classes 1 and 2 outcomes were included to avoid confounding poor seizure control or impact of medication changes with cognitive performance. A repeated-measures ANOVA with Lesion group (right/left) as the between-subject factor and Time point (pre/post) as the within-subject factor was conducted, with performance on verbal memory tests as the dependent variables. Regression analyses were performed to examine the relationship between resection extent of the medial-temporal subregions (hippocampus, entorhinal cortex, and parahippocampal regions) and change in verbal learning and memory scores, after accounting for baseline performance. Given the strong established relationship between verbal memory decline and left-sided resection described in the literature, we performed separate regression analyses in the left and right ATLR groups. To account for multiple comparisons, Benjamini–Hochberg correction for false discovery rate was applied.

RESULTS

Surgical Resection

The extent of surgical resection was quantified for total resection volume, percentage of total brain volume resected, as well as for each temporal lobe substructure, and described in more detail in Table 2. There was a significant difference in the total resection volume and the percentage of total brain volume resected between patients who received left ATLR versus right ATLR ($p < .001$). There was a wide degree of variance of medial-temporal structures resected (see Table 2). Patients who underwent a left ATLR had significantly decreased extent of inferior, mid, and superior temporal neocortical and subcortical tissue resected compared with right ATLR ($p < .001$). Patients who underwent a right ATLR had slightly less hippocampus resected (left 0.84, $SD = 0.07$ vs. right 0.91, $SD = 0.09$; $p = .014$). Other resection extent percentages were statistically similar.

Cognitive Outcomes

Among participants who had an Engel Class 1 or Engel Class 2 outcome ($n = 32$), there was an average decrease in all measures of verbal memory (Figure 2; Table 3). After correction for multiple comparisons, there were no significant differences in memory performance change by side of resection, although there was a trend toward

Table 2. Surgical Resection Extent by Side of Resection (Engel Classes 1 and 2 Only, $n = 32$)

Region	Range	Left ATLR ($n = 14$) ^a	Right ATLR ($n = 18$) ^a	p ^b
Total resection volume (mm ³)	17319–66955	29139 ± 9103	46165 ± 11938	<.001*
Percentage of total brain volume resected	0.02–0.07	0.03 ± 0.01	0.04 ± 0.01	<.001*
Hippocampal (gray matter)	0.64–1.00	0.84 ± 0.07	0.91 ± 0.09	.014*
Entorhinal (gray and white matter)	0.32–0.97	0.84 ± 0.20	0.89 ± 0.10	.394
Parahippocampal (gray and white matter)	0–0.97	0.62 ± 0.28	0.64 ± 0.24	.507
Fusiform (gray and white matter)	0.08–0.46	0.19 ± 0.06	0.27 ± 0.09	.009*
Temporal pole (gray and white matter)	0.49–1.00	0.89 ± 0.13	0.94 ± 0.06	.166
Inferior temporal (gray and white matter)	0.08–0.67	0.20 ± 0.11	0.40 ± 0.13	<.001*
Mid temporal (gray and white matter)	0.04–0.61	0.14 ± 0.10	0.35 ± 0.15	<.001*
Superior temporal (gray and white matter)	0.02–0.79	0.08 ± 0.07	0.37 ± 0.15	<.001*

^aMeans and *SD* percentage resection of each temporal lobe substructure given for left and right ATLR.

^bIndependent samples *t* test comparison performed with *p* values listed.

*Significant after correction for multiple comparisons.

differing BNT and BDI changes, with patients receiving a left ATLR exhibiting a greater decline in naming and patients receiving a right ATLR reporting less depression after surgery.

Predictors of Verbal Declarative Memory Outcomes

Clinical characteristics including age of seizure onset, duration of seizures before surgery, educational level,

verbal IQ, and ipsilateral Wada memory score were not correlated with change in verbal learning or memory (Table 4); however, there was a positive correlation between baseline verbal learning and verbal learning change ($r = .54, p = .006$) and baseline SDFR and SDFR-change ($r = .44, p = .026$). There was no correlation between baseline LDFR and LDFR change ($r = .286, p = .17$). Neither total resection volume or percentage of total brain volume resected was significantly correlated with change in verbal learning or memory.

Figure 2. Percent change in neuropsychological outcomes by side of resection, for Engels 1 and 2 only ($N = 32$). Patients with a left ATLR (red) are compared with patients who received a right ATLR (blue) percent change across each neuropsychological measure after surgery. Bars represent *SEMs*. There is a statistically significant difference between patients who received a left-sided versus a right-sided ATLR in performance in the BNT and the BDI; otherwise, there were no differences between left and right ATLR groups. Patients who received a left ATLR had a trend toward more decline in verbal learning and recall scores.

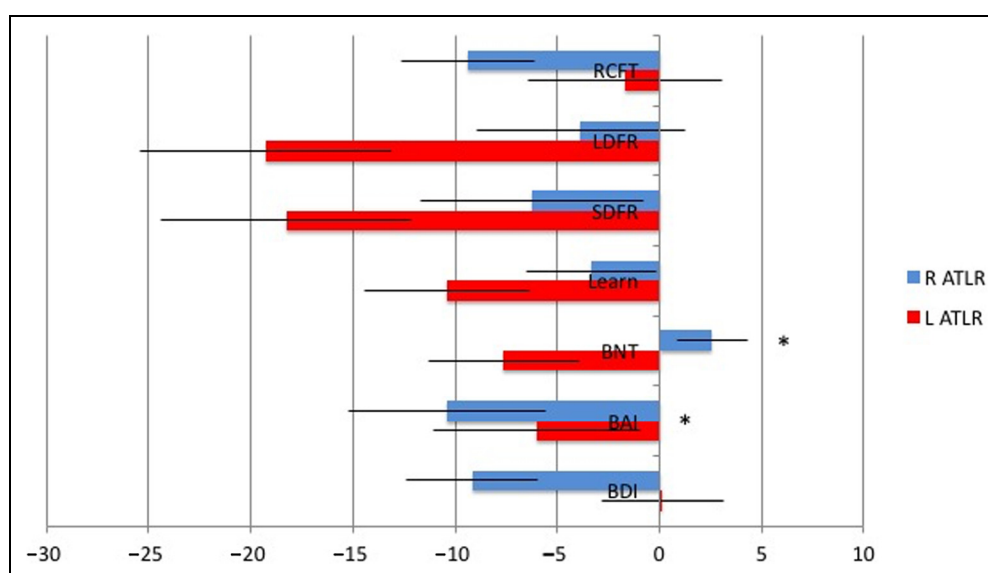


Table 3. Change in Neuropsychological Outcomes (Raw Scores, for Engel Classes 1 and 2 Only, $n = 32$)

Neuropsychological Test	All Participants	p^a	Left ATLR	Right ATLR	p^b
Verbal Learning (L = 14, R = 13) ^c	-5.60 ± 10.56	.014*	-8.31 ± 11.50	-2.67 ± 8.39	.188
Verbal SDFR (L = 14, R = 13) ^c	-2.00 ± 3.38	.007*	-2.92 ± 3.55	-1.00 ± 3.01	.159
Verbal LDFR (L = 14, R = 13) ^c	-1.92 ± 3.57	.011*	-3.07 ± 3.55	-0.67 ± 3.08	.084
RCFT (L = 11, R = 16)	-2.30 ± 5.67	.045*	-0.73 ± 6.76	-3.38 ± 4.72	.241
Visual Confrontation Naming (BNT) (L = 14, R = 13)	-1.62 ± 7.10	.244	-4.43 ± 8.40	1.53 ± 3.71	.022
BDI (L = 13, R 13)	-2.85 ± 7.54	.066	0.08 ± 6.78	-5.77 ± 7.34	.045
BAI (L = 14, R = 13)	-5.11 ± 11.32	.027*	-3.79 ± 11.84	-6.54 ± 10.95	.524

^aGroup level differences were calculated with a paired t test (post-pre), with mean raw scores and SD given for all participants.

^bIndependent samples t test comparing change in neuropsychological test scores. After correction for multiple comparisons, there were no differences in the change in neuropsychological test outcomes for left- versus right-sided resections.

^cCalculated for all participants with same memory test given pre- and postsurgery (CVLT and Rey Auditory Verbal Learning Test) for Engel Classes 1 and 2 only ($n = 25$).

*Significant change from presurgical to postsurgical testing.

Among participants who received a left ATLR, we found that baseline verbal learning performance accounted for 37% of the variance in verbal learning decline (Table 5). After accounting for baseline performance, the extent of parahippocampal resection (gray and white matter) contributed an additional 27% of the variance in verbal learning decline, although this did not reach statistical significance after correction for multiple comparisons ($p = .02$; Table 5A). Baseline verbal SDFR performance accounted for 37% of the variance in verbal SDFR-change. The extent of entorhinal region (gray and white matter) resection accounted for an additional 37% of the variance ($p = .004$), after controlling for the contribution of baseline SDFR performance. In a separate model, the extent of parahippocampal resection accounted for 27% of the variance in verbal SDFR-change, after controlling for baseline performance ($p = .021$; Table 5B). For LDFR-change, none of the regional resection extent values predicted performance decline (Table 5C). In summary, after correction

for multiple comparisons, resection extent in parahippocampal and entorhinal regions remained significant predictors of decline in verbal SDFR.

Discriminant Validity of Left Parahippocampal and Entorhinal Findings

To determine whether decline in verbal SDFR-change was being driven by resection extent in left entorhinal and parahippocampal regions and not other left temporal lobe subregions, we entered the remaining left temporal lobe subregions (i.e., fusiform, temporal pole, inferior temporal, middle temporal, and superior temporal gray and white matter) as predictors of verbal SDFR-change in separate regression models. There was no relationship between resection extent in any of these left temporal subregions and verbal SDFR-change. Furthermore, we examined the relationship between verbal SDFR-change

Table 4. Participant Characteristics Predicting Verbal Memory Decline After Surgery (for Engel Classes 1 and 2 Only, $n = 32$)

Participant Characteristics	Verbal Learning ^b		Verbal SDFR ^b		Verbal LDFR ^b	
	R	p	R	p	R	p
Age of seizure onset	.067 ^a	.750	.085	.687	.063	.763
Duration of seizures before surgery	-.045	.830	<.001	1.000	.029	.892
Education	.246	.236	.073	.729	.292	.157
Verbal IQ	.079	.720	-.011	.961	.189	.387
Ipsilateral WADA Memory Score	-.167	.436	-.198	.354	-.295	.162

^aValues provided are Pearson correlations (bivariate), with two-tailed p values.

^bFor verbal change scores, only participants who took the same memory test pre and post were included ($n = 25$).

Table 5. Verbal Learning, SDFR, and LDFR Change

<i>A. Linear Regression with Verbal Learning Change as the Dependent Variable, for Left ATLR, Engel Classes 1–2 Only (n = 13)</i>						
	<i>Baseline VL R²</i>	<i>R²-Change</i>	<i>Total R²</i>	<i>Standardized β</i>	<i>t</i>	<i>p</i>
Total volume resected	.37	.05	.41	−0.21	−0.862	.409
Hippocampus	.41	.09	.50	−0.32	−1.30	.23
Entorhinal region (GM + WM)	.37	.06	.43	−0.25	−1.03	.33
Parahippocampal region (GM + WM)	0.37	0.27	0.64	−0.52	−2.76	.02
<i>B. Linear Regression with SDFR Change as the Dependent Variable, for Left ATLR and Engel Classes 1–2 Only (n = 13)</i>						
	<i>Baseline SDFR R²</i>	<i>R²-Change</i>	<i>Total R²</i>	<i>Standardized β</i>	<i>t</i>	<i>p</i>
Total volume resected	.37	.02	.39	−0.14	−0.56	.590
Hippocampus	.63	.05	.68	−0.22	−1.14	.29
Entorhinal region (GM + WM)	.37	.37	.74	−0.614	−3.72	.004*
Parahippocampal region (GM + WM)	.37	.27	.637	−0.520	−2.73	.021*
<i>C. Linear Regression with LDFR Change as the Dependent Variable, for Left ATLR, Engel Classes 1–2 Only (n = 13)</i>						
	<i>Total R²</i>	<i>Standardized β</i>	<i>t</i>	<i>p</i>		
Total volume resected	.037	−0.192	−0.649	.530		
Hippocampus	.188	−0.433	−1.521	.159		
Entorhinal Region (GM + WM) (n = 13)	.275	−0.524	−2.042	.066		
Parahippocampal region (GM + WM)	.144	−0.338	−1.192	.258		

*Significant after correction for multiple comparisons ($p < .05$).

and resection extent in all of the right temporal lobe subregions of patients who underwent right ATLR, and there were no significant findings. To establish the specificity of findings to verbal declarative memory, we examined the relationship between resection extent in left entorhinal regions and BNT-change ($p = .252$), RCFT-change ($p = .262$), BDI-change ($p = .296$), and BAI change ($p = .857$), and there were no significant findings. Likewise, there was no significant correlation between left parahippocampal resection extent and BNT-change ($p = .368$), RCFT change ($p = .692$), BDI-change ($p = .688$), or BAI change ($p = .851$). In addition, there was no relationship between change in verbal SDFR and improvement in depression ($p = .514$) or anxiety ($p = .821$) symptoms. Taken together, these results demonstrate that greater resection extent of left entorhinal and parahippocampal regions predicts decline in verbal declarative

memory specifically and not neuropsychological functions in general.

DISCUSSION

In this retrospective longitudinal study, we demonstrate that the degree of left parahippocampal and entorhinal resection predicted decline in verbal declarative memory performance, after correction for multiple comparisons. This finding was present after accounting for the contribution of baseline verbal memory performance, which has been reported as a critical variable in prior literature (Dulay & Busch, 2012; Baxendale, Thompson, Harkness, & Duncan, 2006). It is important to note that the total resection volume and resection extent of other left and right temporal subregions were not related to verbal memory outcomes, suggesting that the extent of

resection of left parahippocampal and entorhinal regions made a specific contribution to verbal memory decline. However, we cannot draw conclusions about the contribution of hippocampal resection, as this structure was nearly completely resected in most cases (0.84 ± 0.07).

Declines in verbal memory after left temporal lobectomy have been described in other retrospective neurosurgical series (Helmstaedter, Petzold, et al., 2011; Helmstaedter, Roeske, et al., 2011; Helmstaedter, Grunwald, Lehnertz, Gleissner, & Elger, 1997) and selective amygdalo-hippocampectomy (Wendling et al., 2013; Morino et al., 2006). However, there are mixed findings in verbal memory outcomes between the more selective mesial temporal and complete temporal lobe resection (Kuang, Yang, Gu, Kong, & Cheng, 2014; Wendling et al., 2013; Helmstaedter et al., 2008; Morino et al., 2006). Our findings extend previous reports by identifying key temporal lobe subregions that appear to drive verbal memory decline. These findings are consistent with a small case series of patients who had hippocampal-sparing temporal lobe resections; only patients who had perirhinal and entorhinal cortex resections had an immediate and lasting effect on associative learning of unrelated word pairs (Weintrob, Saling, Berkovic, & Reutens, 2007).

Our findings highlight the critical role that the perforant pathway plays in encoding and STM for verbal material. The entorhinal cortex plays a privileged role because it receives input from the perirhinal cortex and parahippocampal cortex and communicates directly to the dentate gyrus and CA1–C3 hippocampal subfields (Eichenbaum, Sauvage, Fortin, Komorowski, & Lipton, 2012). Entorhinal cortex serves as a critical gateway facilitating transfer and convergence of unimodal and polymodal sensory input from the dorsal and ventral streams to the hippocampus (Eichenbaum et al., 2012). In particular, entorhinal cortex may be particularly activated by novel information, increasing the probability of transfer to the hippocampus for encoding (Fernández & Tendolkar, 2006). Communication between entorhinal cortex and hippocampus is facilitated by phase-coupled theta and gamma frequency activity (Fell, Klaver, Elger, & Fernandez, 2002). MRI volumetric studies of patients with intractable temporal lobe epilepsy show hippocampal and entorhinal atrophy ipsilateral to the seizure focus compared with healthy controls, suggesting ongoing cell loss from disruption of a critical hippocampal–entorhinal connection (Bernasconi et al., 2003).

Direct electrical stimulation studies also support the critical role of entorhinal cortex in encoding. In rodents, stimulation of the perforant pathway results in long-term potentiation, including the resetting of the theta phase, which has been associated with improved memory outcomes (Vertes, 2005; Williams & Givens, 2003; Ehret et al., 2001; Bliss & Gardner-Medwin, 1973; Bliss & Lomo, 1973). In epilepsy patients undergoing surgical evaluation, stimulation applied to the EC, but not the hippocampus, enhanced learning on a spatial navigation task

(Suthana et al., 2012). Likewise, previous fMRI studies also support the importance of the parahippocampal structures to verbal associative learning (word–word or word–face), demonstrating increased activation during these tasks (Vilberg & Davachi, 2013; Kirwan & Stark, 2004; Weintrob et al., 2002; Bernard, Desgranges, Platel, Baron, & Eustache, 2001).

To our knowledge, this is the first study to separately measure resection extent in the parahippocampal and entorhinal regions in human participants after epilepsy surgery and examine their respective contributions to verbal declarative memory decline. The strengths of this study include the use of an MRI volumetric tracing method that precisely quantifies the extent of resection in each of these medial-temporal subregions. Since memory stabilizes approximately 2 years after surgery (Andersson-Roswall, Engman, Samuelsson, & Malmgren, 2010; Alpherts et al., 2006), our length of follow-up has likely captured patients' new cognitive baseline.

A limitation of our method for determining resection extent was that brain shift from pre- to postoperative images was evident in some participants. This necessitated visual review and manual correction of lesion masks, which increased the processing time demands. We utilized MRI scans acquired proximal to surgery to minimize such error. Thus, it is important to point out that the lesion masks reflect the extent of tissue resected but not additional damage that might occur from Wallerian degeneration (Winston, Stretton, Sidhu, Symms, & Duncan, 2014; Liu, Gross, Wheatley, Concha, & Beaulieu, 2013; McDonald et al., 2010). Postsurgical white matter changes, including both degeneration and reorganization, might impact postsurgical neuropsychological performance (Yogarajah et al., 2010). However, more sensitive measures of tissue microstructure, such as diffusion tensor imaging, are needed to assess this. In summary, although ongoing postsurgical changes in brain microstructure might also play an important role in postsurgical memory performance, our study is limited to assessing the role of surgical resection extent. In addition, we chose a cortical parcellation method (Desikan et al., 2006) that achieves regional specificity while minimizing the multiple comparison problem and the impact of coregistration error. Finer-grained parcellations improve spatial specificity; however, costs include a higher number of statistical tests and potentially increased risk of coregistration error in smaller regions. Future prospective studies would benefit from higher-resolution pre- and postsurgical imaging of the mesial temporal region and finer grained parcellation of the entorhinal region into perirhinal, medial, and lateral subregions. Although we did not find a relationship between hippocampal resection extent and learning and memory outcomes, this may have been due to the near complete resection of the hippocampus in most patients and the limited range of hippocampal resection extent values. A final limitation of our study is the limited number of patients included, although

our numbers fall within the range of published studies on surgical cohorts.

These findings may ultimately inform neurosurgical approaches to reduce cognitive morbidity after epilepsy surgery. At the very least, these numbers may be helpful in presurgical counseling to advise patients as to the degree of memory impairment to be expected after surgery. Our investigation suggests that there is a measurable decline, on the order of 10–20% decline on a verbal list learning task, in the majority of patients who undergo a left temporal lobe resection. Ideally, a larger, multicenter sample with different surgical approaches could confirm or refute our findings. In particular, larger participant numbers are needed to determine if the presence of mesial temporal sclerosis influences the relationship between resection extent and memory outcomes. Finally, our findings support further investigation of stimulation of perforant pathways to potentially remediate memory dysfunction.

In summary, we use a precise method of quantifying surgical resection volumes to discover that degree of left parahippocampal and entorhinal resection was strongly correlated with decline in recall or verbal material. These findings support the growing body of lesion literature in animals and humans that highlights the critical role of the perforant structures in declarative memory function.

Acknowledgments

This work was supported by NYU Finding a Cure for Epilepsy and Seizures (FACES) and the Morris and Alma Schapiro Fund.

Reprint requests should be sent to Anli Liu, NYU Comprehensive Epilepsy Center, New York University School of Medicine, 223 East 34th Street, New York, NY 10016-6402, or via e-mail: anli.liu@nyumc.org.

REFERENCES

- Alpherts, W. C., Vermeulen, J., van Rijen, P. C., da Silva, F. H., van Veelen, C. W., & Dutch Collaborative Epilepsy Surgery Program (2006). Verbal memory decline after temporal epilepsy surgery? A 6-year multiple assessments follow-up study. *Neurology*, *67*, 626–631.
- Andersson-Roswall, L., Engman, E., Samuelsson, H., & Malmgren, K. (2010). Cognitive outcome 10 years after temporal lobe epilepsy surgery: A prospective controlled study. *Neurology*, *74*, 1977–1985.
- Barr, W. B., Goldberg, E., Wasserstein, J., & Novelty, R. A. (1990). Retrograde amnesia following unilateral temporal lobectomy. *Neuropsychologia*, *28*, 243–255.
- Baxendale, S., Thompson, P., Harkness, W., & Duncan, J. (2006). Predicting memory decline following epilepsy surgery: A multivariate approach. *Epilepsia*, *47*, 1887–1894.
- Beck, A. T., & Steer, R. A. (1993). *Beck Anxiety Inventory Manual*. San Antonio, TX: Psychological Corporation.
- Beck, A. T., Steer, R. A., & Brown, G. K. (1996). *Beck Depression Inventory-II*. San Antonio, TX: Psychological Corporation.
- Bernard, F., Desgranges, B., Platel, H., Baron, J. C., & Eustache, F. (2001). Contributions of frontal and medial temporal regions to verbal episodic memory: A PET study. *NeuroReport*, *12*, 1737–1741.
- Bernasconi, N., Bernasconi, A., Caramanos, Z., Antel, S. B., Andermann, F., & Arnold, D. L. (2003). Mesial temporal damage in temporal lobe epilepsy: A volumetric MRI study of the hippocampus, amygdala and parahippocampal region. *Brain*, *126*, 462–469.
- Bliss, T. V., & Gardner-Medwin, A. R. (1973). Long-lasting potentiation of synaptic transmission in the dentate area of the unanaesthetized rabbit following stimulation of the perforant path. *Journal of Physiology*, *232*, 357–374.
- Bliss, T. V., & Lomo, T. (1973). Long-lasting potentiation of synaptic transmission in the dentate area of the anaesthetized rabbit following stimulation of the perforant path. *Journal of Physiology*, *232*, 331–356.
- Dale, A. M., Fischl, B., & Sereno, M. I. (1999). Cortical surface-based analysis. I. Segmentation and surface reconstruction. *Neuroimage*, *9*, 179–194.
- Desikan, R. S., Ségonne, F., Fischl, B., Quinn, B. T., Dickerson, B. C., Blacker, D., et al. (2006). An automated labeling system for subdividing the human cerebral cortex on MRI scans into gyral based regions of interest. *Neuroimage*, *31*, 968–980.
- Dulay, M. F., & Busch, R. M. (2012). Prediction of neuropsychological outcome after resection of temporal and extratemporal seizure foci. *Neurosurgical Focus*, *32*, E4.
- Ehret, A., Haaf, A., Jeltsch, H., Heimrich, B., Feuerstein, T. J., & Jackisch, R. (2001). Modulation of electrically evoked acetylcholine release in cultured rat septal neurones. *Journal of Neurochemistry*, *76*, 555–564.
- Eichenbaum, H., Sauvage, M., Fortin, N., Komorowski, R., & Lipton, P. (2012). Towards a functional organization of episodic memory in the medial temporal lobe. *Neuroscience and Biobehavioral Reviews*, *36*, 1597–1608.
- Fell, J., Klaver, P., Elger, C. E., & Fernandez, G. (2002). The interaction of rhinal cortex and hippocampus in human declarative memory formation. *Reviews in the Neurosciences*, *13*, 299–312.
- Fernández, G., & Tendolkar, I. (2006). The rhinal cortex: ‘Gatekeeper’ of the declarative memory system. *Trends in Cognitive Sciences*, *10*, 358–362.
- Fischl, B., Salat, D. H., Busa, E., Albert, M., Dieterich, M., Haselgrove, C., et al. (2002). Whole brain segmentation: Automated labeling of neuroanatomical structures in the human brain. *Neuron*, *33*, 341–355.
- Fischl, B., Sereno, M. I., & Dale, A. M. (1999). Cortical surface-based analysis. II: Inflation, flattening, and a surface-based coordinate system. *Neuroimage*, *9*, 195–207.
- Gaffan, D. (1994). Dissociated effects of perirhinal cortex ablation, fornix transection and amygdectomy: Evidence for multiple memory systems in the primate temporal lobe. *Experimental Brain Research*, *99*, 411–422.
- Helmstaedter, C., Grunwald, T., Lehnertz, K., Gleissner, U., & Elger, C. E. (1997). Differential involvement of left temporolateral and temporomesial structures in verbal declarative learning and memory: Evidence from temporal lobe epilepsy. *Brain and Cognition*, *35*, 110–131.
- Helmstaedter, C., Petzold, I., & Bien, C. G. (2011). The cognitive consequence of resecting nonlesional tissues in epilepsy surgery—Results from MRI- and histopathology-negative patients with temporal lobe epilepsy. *Epilepsia*, *52*, 1402–1408.
- Helmstaedter, C., Richter, S., Roske, S., Oltmanns, F., Schramm, J., & Lehmann, T. N. (2008). Differential effects of temporal pole resection with amygdalohippocampectomy versus selective amygdalohippocampectomy on material-specific memory in patients with mesial temporal lobe epilepsy. *Epilepsia*, *49*, 88–97.

- Helmstaedter, C., Roeske, S., Kaaden, S., Elger, C. E., & Schramm, J. (2011). Hippocampal resection length and memory outcome in selective epilepsy surgery. *Journal of Neurology, Neurosurgery and Psychiatry*, *82*, 1375–1381.
- Hermann, B. P., Seidenberg, M., Haltiner, A., & Wyler, A. R. (1995). Relationship of age at onset, chronologic age, and adequacy of preoperative performance to verbal memory change after anterior temporal lobectomy. *Epilepsia*, *36*, 137–145.
- Josephson, C. B., Dykeman, J., Fiest, K. M., Liu, X., Sadler, R. M., Jette, N., et al. (2013). Systematic review and meta-analysis of standard vs selective temporal lobe epilepsy surgery. *Neurology*, *80*, 1669–1676.
- Kirwan, C. B., & Stark, C. E. (2004). Medial temporal lobe activation during encoding and retrieval of novel face-name pairs. *Hippocampus*, *14*, 919–930.
- Kuang, Y., Yang, T., Gu, J., Kong, B., & Cheng, L. (2014). Comparison of therapeutic effects between selective amygdalohippocampectomy and anterior temporal lobectomy for the treatment of temporal lobe epilepsy: A meta-analysis. *British Journal of Neurosurgery*, *28*, 374–377.
- Lillywhite, L. M., Saling, M. M., Briellmann, R. S., Weintrob, D. L., Pell, G. S., & Jackson, G. D. (2007). Differential contributions of the hippocampus and rhinal cortices to verbal memory in epilepsy. *Epilepsy & Behavior*, *10*, 553–559.
- Liu, M., Gross, D. W., Wheatley, B. M., Concha, L., & Beaulieu, C. (2013). The acute phase of Wallerian degeneration: Longitudinal diffusion tensor imaging of the fornix following temporal lobe surgery. *NeuroImage*, *74*, 128–139.
- Loring, D. W., Lowenstein, D. H., Barbaro, N. M., Fureman, B. E., Odenkirchen, J., Jacobs, M. P., et al. (2011). Common data elements in epilepsy research: Development and implementation of the NINDS epilepsy CDE project. *Epilepsia*, *52*, 1186–1191.
- Malkova, L., & Mishkin, M. (2003). One-trial memory for object-place associations after separate lesions of hippocampus and posterior parahippocampal region in the monkey. *Journal of Neuroscience*, *23*, 1956–1965.
- McDonald, C. R., Hagler, D. J., Jr., Girard, H. M., Pung, C., Ahmadi, M. E., Holland, D., et al. (2010). Changes in fiber tract integrity and visual fields after anterior temporal lobectomy. *Neurology*, *75*, 1631–1638.
- Morino, M., Uda, T., Naito, K., Yoshimura, M., Ishibashi, K., Goto, T., et al. (2006). Comparison of neuropsychological outcomes after selective amygdalohippocampectomy versus anterior temporal lobectomy. *Epilepsy & Behavior*, *9*, 95–100.
- Murray, E. A., Gaffan, D., & Mishkin, M. (1993). Neural substrates of visual stimulus-stimulus association in rhesus monkeys. *Journal of Neuroscience*, *13*, 4549–4561.
- Saling, M. M. (2009). Verbal memory in mesial temporal lobe epilepsy: Beyond material specificity. *Brain*, *132*, 570–582.
- Scoville, W. B., & Milner, B. (1957). Loss of recent memory after bilateral hippocampal lesions. *Journal of Neurology, Neurosurgery and Psychiatry*, *20*, 11–21.
- Sherman, E. M., Wiebe, S., Fay-McClymont, T. B., Tellez-Zenteno, J., Metcalfe, A., Hernandez-Ronquillo, L., et al. (2011). Neuropsychological outcomes after epilepsy surgery: Systematic review and pooled estimates. *Epilepsia*, *52*, 857–869.
- Spencer, S., & Huh, L. (2008). Outcomes of epilepsy surgery in adults and children. *Lancet Neurology*, *7*, 525–537.
- Squire, L. R. (1992). Memory and the hippocampus: A synthesis from findings with rats, monkeys, and humans. *Psychological Review*, *99*, 195–231.
- Squire, L. R., & Zola, S. M. (1996). Structure and function of declarative and nondeclarative memory systems. *Proceedings of the National Academy of Sciences, U.S.A.*, *93*, 13515–13522.
- Stallings, G., Boake, C., & Sherer, M. (1995). Comparison of the California Verbal Learning Test and the Rey Auditory Verbal Learning Test in head-injured patients. *Journal of Clinical and Experimental Neuropsychology*, *17*, 706–712.
- Suthana, N., Haneef, Z., Stern, J., Mukamel, R., Behnke, E., Knowlton, B., et al. (2012). Memory enhancement and deep-brain stimulation of the entorhinal area. *The New England Journal of Medicine*, *366*, 502–510.
- Taylor, E. M. (1959). *Psychological appraisal of children with cerebral defects*. Cambridge, MA: Harvard University Press.
- Tellez-Zenteno, J. F., Dhar, R., & Wiebe, S. (2005). Long-term seizure outcomes following epilepsy surgery: A systematic review and meta-analysis. *Brain*, *128*, 1188–1198.
- Vertes, R. P. (2005). Hippocampal theta rhythm: A tag for short-term memory. *Hippocampus*, *15*, 923–935.
- Vilberg, K. L., & Davachi, L. (2013). Perirhinal-hippocampal connectivity during reactivation is a marker for object-based memory consolidation. *Neuron*, *79*, 1232–1242.
- Weintrob, D. L. (2004). *The neural correlates of memory impairment in left temporal lobe epilepsy*. Unpublished PhD Thesis. The University of Melbourne.
- Weintrob, D. L., Saling, M. M., Berkovic, S. F., Berlangieri, S. U., & Reutens, D. C. (2002). Verbal memory in left temporal lobe epilepsy: Evidence for task-related localization. *Annals of Neurology*, *51*, 442–447.
- Weintrob, D. L., Saling, M. M., Berkovic, S. F., & Reutens, D. C. (2007). Impaired verbal associative learning after resection of left perirhinal cortex. *Brain*, *130*, 1423–1431.
- Wendling, A. S., Hirsch, E., Wisniewski, I., Davanture, C., Ofer, I., Zentner, J., et al. (2013). Selective amygdalohippocampectomy versus standard temporal lobectomy in patients with mesial temporal lobe epilepsy and unilateral hippocampal sclerosis. *Epilepsy Research*, *104*, 94–104.
- Williams, J. M., & Givens, B. (2003). Stimulation-induced reset of hippocampal theta in the freely performing rat. *Hippocampus*, *13*, 109–116.
- Winston, G. P., Stretton, J., Sidhu, M. K., Symms, M. R., & Duncan, J. S. (2014). Progressive white matter changes following anterior temporal lobe resection for epilepsy. *NeuroImage: Clinical*, *4*, 190–200.
- Yogarajah, M., Focke, N. K., Bonelli, S. B., Thompson, P., Vollmar, C., McEvoy, A. W., et al. (2010). The structural plasticity of white matter networks following anterior temporal lobe resection. *Brain*, *133*, 2348–2364.
- Zola-Morgan, S., Squire, L. R., Amaral, D. G., & Suzuki, W. A. (1989). Lesions of perirhinal and parahippocampal cortex that spare the amygdala and hippocampal formation produce severe memory impairment. *Journal of Neuroscience*, *9*, 4355–4370.
- Zola-Morgan, S., Squire, L. R., Clower, R. P., & Rempel, N. L. (1993). Damage to the perirhinal cortex exacerbates memory impairment following lesions to the hippocampal formation. *Journal of Neuroscience*, *13*, 251–265.