

***Cryptosporidium* spp. infections in livestock and wild animals in Azerbaijan territory**

S. Mamedova^a and P. Karanis^{b,c,*}

^aNational Academy of Sciences of Azerbaijan, Institute of Zoology, Passage 1128, Block 504, Baku, AZ 1073, Azerbaijan

^bFaculty of Medicine and University Hospital, University of Cologne, Cologne, Germany

^cDepartment of Basic and Clinical Sciences, University of Nicosia Medical School, Nicosia, Cyprus

*Corresponding author. E-mail: karanis.p@unic.ac.cy

ABSTRACT


Cryptosporidium is an intracellular protozoan parasite, globally distributed and capable of infecting various vertebrate species, including humans as well as domestic and wild animals. *Cryptosporidium* is increasingly gaining attention as a human and an animal pathogen mainly due to its dominant involvement in worldwide waterborne outbreaks. The present paper reviews the current knowledge and understanding of *Cryptosporidium* spp. in terrestrial and water animals in Azerbaijan.

Key words: animals, Azerbaijan, *Cryptosporidium*, microscopy, species, Ziehl–Neelsen

HIGHLIGHTS

- First review on knowledge and understanding of *Cryptosporidium* spp. in terrestrial and water animals in Azerbaijan.
- First review zoonotic *Cryptosporidium* species in Azerbaijan.
- Crypto livestock, wildlife, amphibians, birds, and mammals.
- An extensive report based on a comparative analysis of morphometric parameters of Crypto oocysts.
- High prevalence rates in domestic and wild animals.

GRAPHICAL ABSTRACT



INTRODUCTION

Cryptosporidium is an intracellular protozoan parasite and is a major cause of gastroenteritis (cryptosporidiosis) worldwide. *Cryptosporidium* is a globally distributed genus of diarrheal pathogens capable of infecting various vertebrate species, including humans as well as domestic and wild animals (Xiao *et al.* 2004; Plutzer & Karanis 2009). To date, a total of 44 *Cryptosporidium* and *Cryptosporidium*-like species have been described from animals and humans (Table 1).

This is an Open Access article distributed under the terms of the Creative Commons Attribution Licence (CC BY-NC-ND 4.0), which permits copying and redistribution for non-commercial purposes with no derivatives, provided the original work is properly cited (<http://creativecommons.org/licenses/by-nc-nd/4.0/>).

Table 1 | *Cryptosporidium* and *Cryptosporidium*-like species with information on organ location and morphometric characters of oocysts reported from animals

N 1	Species name 2	Authors reported for first time 3	Type host 4	Major host 5	Site of infection 6	Dimension (μm) L (average) \times W (average) 7	L/W (Length/width) 8	References 9
<i>Cryptosporidium</i> and <i>Cryptosporidium</i> -like parasites reported from fish								
1	<i>C. nasorum</i>	Hoover <i>et al.</i> (1981)	Lipstick tang (<i>Naso liburatus</i>)	Fish	Intestine	NR	NR	Levine (1980), Ryan (2010), Šlapeta (2013)
2	<i>C. cichlidis</i> = <i>Piscicryptosporidium cichlidis</i>	Paperna & Vilenkin (1996)	Hybrid fry and fingerling tilapia (<i>Oreochromis aureus</i> \times <i>Oreochromis niloticus</i>)	Fish	Stomach	4.0–4.7, 2.5–3.5	NR	Ryan (2010), Šlapeta (2013)
3	<i>C. reichenbachklinkei</i> = <i>Piscicryptosporidium reichenbachklinkei</i>	Paperna & Vilenkin (1996)	Reared gouramis (<i>Trichogaster leeri</i>)	Fish	Stomach	2.4–3.18, 2.4–3.0	NR	Šlapeta (2013)
4	<i>C. molnari</i>	Alvarez-Pellitero & Sitjà-Bobadilla (2002)	Gilthead sea bream (<i>Sparus aurata</i>) and the European sea bass (<i>Dicentrarchus labrax</i>)	Fish	Stomach and small intestine	3.23–5.45 (4.72) \times 3.02–5.04 (4.47)	1–1.17 (1.05)	Alvarez-Pellitero & Sitjà-Bobadilla (2002)
5	<i>C. scopthalmi</i>	Alvarez-Pellitero <i>et al.</i> (2004)	Turbot (<i>Scophthalmus maximus</i>)	Fish	Intestine and stomach	3.7–5.03 (4.44) \times 3.03–4.69 (3.91)	1.05–1.34 (1.14)	Alvarez-Pellitero <i>et al.</i> (2004)
6	<i>C. huwii</i>	Ryan <i>et al.</i> (2015)	Guppy (<i>Poecilia reticulata</i>)	Fish	Stomach	4.4–4.9 (4.6) \times 4.0–4.8 (4.4)	0.92–1.35 (1.04)	Ryan <i>et al.</i> (2015)
<i>Cryptosporidium</i> species reported from amphibians								
7	<i>C. fragile</i>	Jirku <i>et al.</i> (2008)	Black-spined toads, (<i>Duttaphrynus melanostictus</i>)	NR	Stomach	5.5–7.0 (6.2) \times 5.0–6.5 (5.5)	NR	Jirku <i>et al.</i> (2008)
<i>Cryptosporidium</i> species reported from reptiles								
8	<i>C. serpentis</i>	Levine (1980)	<i>Elaphe gualta</i> , <i>E. suboclaris</i> , <i>Sanzinia madagascarensis</i> (Snakes)	Snakes and lizards	Stomach	5.6–6.6 (6.2) \times 4.8–5.6 (4.2)	1.04–1.33 (1.16)	Plutzer & Karanis (2009), Ryan <i>et al.</i> (2014)
9	<i>C. varanii</i> = <i>C. saurophilum</i>	Pavlásek <i>et al.</i> (1995), Koudela & Modry (1998)	Varanus prasinus (<i>Emerald monitor</i>), Shneider's skinks (<i>Eumeces schneideri</i>)	Lizards	Stomach and small intestine	4.4–5.6 (5.0) \times 4.2–5.2 (4.7), 4.4–5.6 (5.0) \times 4.2–5.2 (5.3)	1.05–1.12 (1.09)	Koudela & Modry (1998), Ryan <i>et al.</i> (2014)
10	<i>C. ducismarci</i>	Traversa (2010)	Tortoises	Tortoises, turtles, other reptiles	NR	4.4–5.4 (5.0) \times 4.3–5.3 (4.8)	1.1 \pm 0.03	Ježková <i>et al.</i> (2016)
11	<i>C. testudines</i>	Ježková <i>et al.</i> (2016)	Russian tortoises (<i>Testudo horsfieldii</i> , Gray)	Tortoises	NR	5.8–6.9 (6.4) \times 5.3–6.3 (5.9)	1.1 \pm 0.05	Ježková <i>et al.</i> (2016)

(Continued)

Table 1 | Continued

N	Species name	Authors reported for first time	Type host	Major host	Site of infection	Dimension (μm) L (average) \times W (average)	L/W (Length/width)	References
1	2	3	4	5	6	7	8	9
<i>Cryptosporidium</i> species reported from birds								
12	<i>C. meleagridis</i>	Slavin (1955)	<i>Melleagris gallopova</i> (Turkey)	Birds and humans	Small intestine	4.5–6.0 (5.0) \times 4.2–5.3 (4.4)	1.0–1.3 (1.3)	Plutzer & Karanis (2009), Ryan <i>et al.</i> (2014)
13	<i>C. baileyi</i>	Current <i>et al.</i> (1986)	<i>Gallus gallus</i> (Chicken)	Birds	Bursa, cloacae, trachea	5.6–7.5 (6.4) \times 4.8–5.75 (4.8)	1.1–1.4 (1.3)	Current <i>et al.</i> (1986), Plutzer & Karanis (2009)
14	<i>C. galli</i>	Pavlásek (1999), Ryan <i>et al.</i> (2003)	Chickens	Passeriformes, Phasianidae, Fringillidae, and Icteridae	Proventriculus	8.0–8.5 (8.25) \times 6.2–6.4 (6.3)	1.30	Ryan <i>et al.</i> (2003)
15	<i>C. avium</i>	Holubová <i>et al.</i> (2016)	Red-crowned parakeets (<i>Cyanoramphus novaezealandiae</i>)	Budgerigar, hens	Ileum and cecum	5.30–6.90 (6.26) \times 4.30– 5.5 (4.86)	1.14–1.47 (1.29)	Holubová <i>et al.</i> (2016)
16	<i>C. proventriculi</i>	Holubová <i>et al.</i> (2019)	Psittaciformes (Birds)	Birds	Proventriculus and ventriculus	7.4 \times 5.8	NR	Holubová <i>et al.</i> (2019)
<i>Cryptosporidium</i> species reported from mammals								
17	<i>C. muris</i>	Tyzzler (1907)	House mouse (<i>Mus musculus</i>)	Rodents	Stomach	8.0–9.0 (8.4) \times 5.6–6.4 (6.1), 7.0–9.0 (8.1) \times 5.0–6.5 (5.9)	1.25–1.61 (1.38) 1.17–1.7 (1.36)	Plutzer & Karanis (2009), Ryan <i>et al.</i> (2014)
18	<i>C. tyzzery</i>	Tyzzler (1912), Ren <i>et al.</i> (2012)	Domestic mice (<i>Mus musculus</i>)	Rodents	Jejunum and ileum	4.64 \pm 0.05 \times 4.19 \pm 0.06	1.11 \pm 0.02	Ren <i>et al.</i> (2012)
19	<i>C. proliferans</i>	Kváč <i>et al.</i> (2016)	Northeast African mole-rat (<i>Tachyoryctes splendens</i>)	Donkey, Sciurus eastern grey squirrel, African buffalo, horse	Stomach, specifically the glandular part	6.8–8.8 (7.7) \times 4.8–6.2 (5.3)	1.48	Kváč <i>et al.</i> (2016)
20	<i>C. apodemi</i>	Čondlová <i>et al.</i> (2018)	Striped field mouse (<i>Apodemus agrarius</i>)	Yellow-necked mice (<i>Apodemus flavicollis</i>)	Intestine	3.9–4.7 (4.2) \times 3.8–4.4 (4.0)	1.0–1.06 (1.03)	Čondlová <i>et al.</i> (2018)

(Continued)

Table 1 | Continued

N 1	Species name 2	Authors reported for first time 3	Type host 4	Major host 5	Site of infection 6	Dimension (μm) <i>L</i> (average) \times <i>W</i> (average) 7	L/W (Length/width) 8	References 9
21	<i>C. ditrichi</i>	Čondlová <i>et al.</i> (2018)	Yellow-necked mice (<i>Apodemus flavicollis</i>)	Mouse (<i>Mus musculus</i>), human (<i>Homo sapiens</i>)	Small intestine – jejunum and ileum	4.5–5.2 (4.7) \times 4.0–4.6 (4.2)	1.0–1.2 (1.12)	Čondlová <i>et al.</i> (2018)
22	<i>C. occultus</i>	Kváč <i>et al.</i> (2018)	Wild brown rats, mice (<i>Rattus norvegicus</i>), Mongolian gerbils (<i>Meriones unguiculatus</i>)	Rodents	Colon	5.20 \times 4.94	NR	Kváč <i>et al.</i> (2018)
23	<i>C. alticolis</i>	Horčíčková <i>et al.</i> (2019)	Common voles (<i>Microtus arvalis</i>)	Voles	Small intestine	5.4 \times 4.9	NR	Horčíčková <i>et al.</i> (2019)
24	<i>C. macroti</i>	Horčíčková <i>et al.</i> (2019)	Common voles (<i>Microtus arvalis</i>)	Voles	Large intestine	4.3 \times 4.1	NR	Horčíčková <i>et al.</i> (2019)
25	<i>C. cuniculus</i>	Inman & Takeuchi (1979), Robinson <i>et al.</i> (2010)	European rabbits (<i>Oryctolagus cuniculus</i>) and humans (<i>Homo sapiens</i>)	Rabbits	Small intestinal	5.55–6.40 (5.98) \times 5.02–5.92 (5.38)	1.1	Robinson <i>et al.</i> (2010)
26	<i>C. rubeyi</i>	Li <i>et al.</i> (2015)	Squirrel (<i>Spermophilus beecheyi</i> , <i>Spermophilus beldingi</i> , <i>Spermophilus lateralis</i>)	Squirrels	NR	4.4–5.0 (4.67) \times 4.0–5.0 (4.34)	1.08	Li <i>et al.</i> (2015)
27	<i>C. felis</i>	Iseki (1979)	<i>Felis catis</i> (Cat)	Cat	Small intestine	6.0–5.0 (5.0) \times 5.0–4.5 (4.5)	NR	Iseki (1979), Plutzer & Karanis (2009), Ryan <i>et al.</i> (2014)
28	<i>C. canis</i>	Fayer <i>et al.</i> (2001)	<i>Canis familiaris</i> (Dog)	Dogs	Small intestine	4.95 \times 4.75	1.05	Fayer <i>et al.</i> (2001), Plutzer & Karanis (2009)
29	<i>C. wrairi</i>	Vetterling <i>et al.</i> (1971)	<i>Cavia porcellus</i> (Guinea pigs)	Guinea pigs	Small intestine	4.8–5.6 (5.4) \times 4.0–5.0 (4.6)	1.17	Plutzer & Karanis (2009), Ryan <i>et al.</i> (2014)
30	<i>C. homai</i>	Zahedi <i>et al.</i> (2017)	<i>Cavia porcellus</i> (Guinea pigs)	NR	NR	NR	NR	Zahedi <i>et al.</i> (2017)
31	<i>C. suis</i>	Ryan <i>et al.</i> (2004)	<i>Sus scrofa</i> (Pig)	Pigs	The small and large intestine	4.9–4.4 (4.6) \times 4.0–4.3 (4.2)	1.1	Ryan <i>et al.</i> (2004)
32	<i>C. scrofarum</i>	Kváč <i>et al.</i> (2013)	<i>Sus scrofa</i> (Pig)	Human, calf, wild boar	Duodenum, jejunum, ileum, cecum, colon	4.81–5.96 (5.16) \times 4.23–5.29 (4.83)	1.07 \pm 0.06	Kváč <i>et al.</i> (2013)

(Continued)

Table 1 | Continued

N	Species name	Authors reported for first time	Type host	Major host	Site of infection	Dimension (μm) L (average) \times W (average)	L/W (Length/width)	References
1	2	3	4	5	6	7	8	9
33	<i>C. parvum</i>	Tyzzler (1912)	<i>Bos taurus</i> (Cattle)	Ruminants, cattle other livestock, humans	Small intestine	4.5–5.4 (4.9) \times 4.2–5.2 (4.4)	1.0–1.13 (1.1)	Plutzer & Karanis (2009), Ryan <i>et al.</i> (2014)
34	<i>C. andersoni</i>	Lindsay <i>et al.</i> (2000)	<i>Bos taurus</i> (Cattle)	Cattle, camel	Abomasum	6.0–8.1 (7.4) \times 5.0–6.5 (5.5)	1.07–1.50 (1.35)	Lindsay <i>et al.</i> (2000)
35	<i>C. bovis</i>	Fayer <i>et al.</i> (2005)	<i>Bos taurus</i> (Cattle)	Cattle	Small intestine	4.76–5.35 (4.89) \times 4.17– 4.76 (4.63)	1.06	Fayer <i>et al.</i> (2005)
36	<i>C. ryanae</i>	Fayer <i>et al.</i> (2008)	<i>Bos taurus</i> (Cattle)	Cattle	NR	2.94–3.68 (3.73) \times 2.94– 4.41 (3.16)	1.18	Fayer <i>et al.</i> (2008)
37	<i>C. ubiguitum</i>	Fayer <i>et al.</i> (2010)	<i>Bos taurus</i> (Cattle)	Ruminants, rodents, carnivores, primates, humans	NR	4.71–5.32 (5.04) \times 4.33– 4.98 (4.66)	1.08	Fayer <i>et al.</i> (2010)
38	<i>C. pestis</i>	Šlapeta (2006)	<i>Bos taurus</i> (Cattle)	NR	NR	NR	NR	Šlapeta (2013)
39	<i>C. xiaoi</i>	Fayer & Santín (2009)	<i>Ovis aries</i> (Sheep)	Sheep and goats	NR	2.94–4.41 (3.94) \times 2.94– 4.41 (3.44)	1.15	Fayer & Santín (2009)
40	<i>C. erinacei</i>	Kváč <i>et al.</i> (2014)	European hedgehog (<i>Erinaceus europaeus</i>)	Hedgehogs	NR	4.5–5.8 (4.9) \times 4.0–4.8 (4.4)	1.02–1.35 (1.13)	Kváč <i>et al.</i> (2014)
41	<i>C. fayeri</i>	Ryan <i>et al.</i> (2008)	Red kangaroo (<i>Macropus rufus</i>)	Marsupials	Small intestine	4.5–5.1 (4.9) \times 3.8–5.0 (4.3)	1.02–1.18 (1.14)	Ryan <i>et al.</i> (2008)
42	<i>C. macropodum</i>	Power & Ryan (2008)	Eastern grey kangaroos (<i>Macropus giganteus</i>).	Marsupials	Small intestine	5.0–6.0 (5.4) \times 4.5–6.0 (4.9)	1.1	Power & Ryan (2008)
43	<i>C. hominis</i>	Morgan-Ryan <i>et al.</i> (2002)	<i>Homo sapiens</i> (Humans)	Humans	Small intestine	4.4–5.9 (5.2) \times 4.4–5.4 (4.86)	1.0–1.09 (1.07)	Ryan <i>et al.</i> (2002)
44	<i>C. viatorum</i>	Elwin <i>et al.</i> (2012)	<i>Homo sapiens</i> (Humans)	Humans	NR	NR	NR	Elwin <i>et al.</i> (2012)

More than 70 genotypes of *Cryptosporidium* have been described; 21 species and 4 genotypes out of these have been reported in humans (Feng & Xiao 2017; Holubová *et al.* 2019). Several *Cryptosporidium* species are known to be zoonotic with animals as major reservoirs (Feng *et al.* 2018). Wild and livestock animals have the potential to act as a biological reservoir for harmful protozoan parasites – *Cryptosporidium* spp. (Xiao & Feng 2008).

Cryptosporidium spp. were first described in mice in 1907 (Tyzzer 1907). *Cryptosporidium* is part of the Apicomplexa phylum (Phylum: *Apicomplexa*, Class: *Coccidea*, Order: *Eucoccidiorida*, Family: *Cryptosporidiidae*, Genus: *Cryptosporidium*) (Fayer & Xiao 2007). Recent taxonomic studies have placed *Cryptosporidium* as a clad separate from *Coccidia*. A study on the 18rRNA gene has indicated a closer relation to the gregarines (*Apicomplexa*, *Gregarinia*) (Carreno *et al.* 1999). This would also explain why *Cryptosporidium* has several features that separate it from other *Coccidia*: host infection is confined to the apical region of the epithelial cells, the small size of the oocysts, the formation of both thick- and thin-walled oocysts, and the insensitivity to anti-coccidian agents. Further understanding of the relation to the Gregarines is very important for elucidating its ecology and waterborne transmission (Ryan & Xiao 2003; Aldeyarbi & Karanis 2016; Ryan *et al.* 2016).

Cryptosporidium completes its lifecycle in a single host, and it is ubiquitous in nature. Oocysts can tolerate various environmental conditions and can survive in water and soil for many months because of suitable moisture content and cool temperatures (Smith *et al.* 2006; King & Monis 2007). They can be transported long distances through air and enter quickly into the water sources because of the oocysts' small size (Vanathy *et al.* 2017). *Cryptosporidium* sparked great public health interest after the large human waterborne outbreaks in Milwaukee in 1993 and rapidly was recognized as one of the most serious waterborne pathogens to date (MacKenzie *et al.* 1994). The outbreaks of cryptosporidiosis have been and continuously reported in several countries (Karanis *et al.* 2007; Baldursson & Karanis 2011; Efstratiou *et al.* 2017). Domestic animals, livestock, wildlife, and humans are potential reservoirs that contribute to the contamination of food, surface waters, and the environment by *Cryptosporidium* spp. Oocysts, thereby transmitting the infection to other hosts via the fecal-oral route (Ahmed & Karanis 2018a, 2018b).

This paper aims to report on the main results of studies on cryptosporidiosis and *Cryptosporidium* among livestock, wild animals, and birds in Azerbaijan territory and to provide first-hand information about the veterinary and public health aspects of this important pathogen in the Azerbaijan territory for the last 32 years. In total, 13 species of *Cryptosporidium* from amphibians, reptiles, birds, and mammals have been identified and reported from studies conducted from 1987 to 2019 on structural features of *Cryptosporidium* oocysts in different regions of the Azerbaijan republic.

We highlighted the occurrence of *Cryptosporidium* infection in animals particularly in cattle, sheep, goats, pigs, buffaloes, birds, and wild animals in Azerbaijan. A total of 70 studies were used to calculate epidemiological figures.

MATERIAL AND METHODS

Geography

Azerbaijan is situated on the western shore of the Caspian Sea and occupies the north-western and south-eastern parts of the Caucasian Ridge. It borders with the Republic of Dagestan in the north (part of the Russian Federation), in the west with Armenian and the Georgian Republic and in the east the Caspian Sea, and in the south, it borders Iran and Turkey. The territory is divided into five physical-geographical regions: Greater Caucasus, Lesser Caucasus, the Kura-Aras, Lankaran, and the Middle Aras (Figure 1).

This review has been prepared based on the current literature data. More than 70 publications describing the presence of *Cryptosporidium* in animals have been published in the last 32 years in Azerbaijan. The language of data collection was English, Russian, and Azeri. The first report of *Cryptosporidium* was in 1987 (Ismailova & Gaibova 1987). From 1987 to 2019 (32-year period), a total of 9,408 samples from 57 studies on wild animals, birds, and common livestock (defined as cattle, sheep, goats, pigs, horses, and buffaloes) were examined for *Cryptosporidium* infection, where *Cryptosporidium* spp. is a widespread pathogen found in many species of domestic animals. Most of the publications (70%) are about *Cryptosporidium* prevalence in domestic animals. Cryptosporidiosis in livestock has become a significant problem for animal health (both subclinical and clinical) and has resulted in economic losses due to the increase of veterinary services and laboratory costs, increased animal healthcare costs, and a decrease in growth rate with a higher associated mortality in severely infected animals. Stool specimens were randomly collected from 8,668 livestock (pigs, horses, donkeys, goats, sheep, calves, buffalo, zebu, camels, and birds) and 740 wild animals (amphibians, reptiles, rodents, cats, and dogs) (Table 2). The most studied livestock animals were pigs ($n = 2,857$), cows ($n = 2,595$), and sheep ($n = 1,823$) (Table 2).

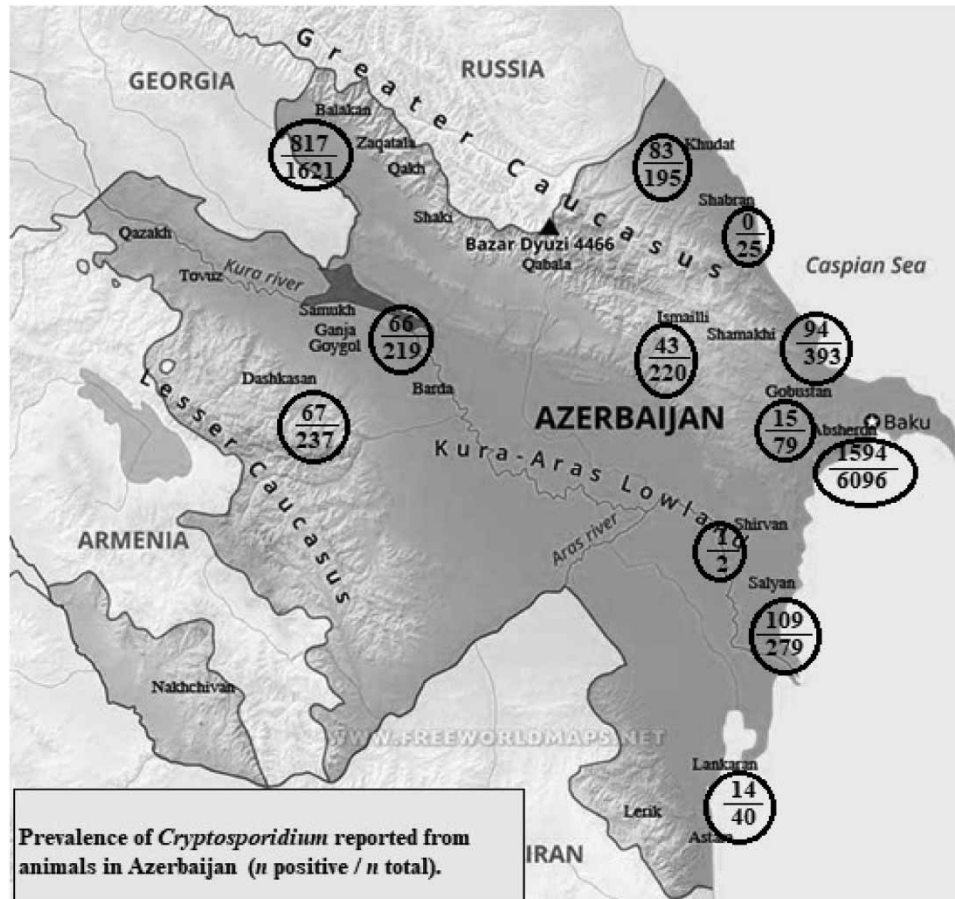

Figure 1 | Map of Azerbaijan borders.

Fecal samples were collected from wild terrestrial and marine animals, birds, and domestic animals from different natural areas and the urban or rural regions of Azerbaijan in the different seasons of the year.

The diagnosis of cryptosporidiosis relies on the identification of oocysts in fecal samples. The diagnosis is established microscopically. Fine feces smears were fixed with methanol and were stained with carbol-fuchsin and methylene green by the Ziehl-Neelsen staining method or detection of *Cryptosporidium* oocysts according to the procedure described by Henriksen & Pohlenz (1981). Microscopy is a cheap method but requires a skilled parasitologist and/or related expert and the diagnostic yield is dependent on proper fecal material collection.

Microscopy was the most used technique to diagnose *Cryptosporidium* infections in animals and human isolates from the reports of the Azerbaijan regions. *Cryptosporidium* spp. identification was based on conventional criteria, such as oocyst morphology and measurements. These criteria agree with those applied by Fayer *et al.* (2000) and Morgan-Ryan *et al.* (2002), who stated that morphometric measurement of oocysts represents the cornerstone of *Cryptosporidium* taxonomy and is one of the requirements for establishing a new species. *Cryptosporidium* infections from birds and mammals and attempted cross-transmission studies have been included in this review (Musaev *et al.* 1997).

RESULTS

Prevalence of *Cryptosporidium* spp.

A total of 9,408 samples from 57 studies on wild animals, birds, and common livestock (defined as cattle, sheep, goats, pigs, horses, and buffaloes) have been examined for *Cryptosporidium* infection in the Azerbaijan regions, where 2,903 (30.9%) were positive for *Cryptosporidium* spp. using microscopy methods. Tables 3–6 summarize the prevalence and frequency of parasite-positive fecal samples from different groups of animals. All animal groups, with some exceptions, tested positive for *Cryptosporidium* spp. regarding wild and domestic animals, *Cryptosporidium* prevalence was higher in wild animals

Table 2 | Summarized prevalences of *Cryptosporidium* reported from animals in Azerbaijan

Hostname	n positive	n total	%	References
<i>Wild animals</i>				
Amphibians	30	87	34.5	Mamedova (2010)
Reptilia: Ordo: Testudines	58	104	55.8	Gaibova <i>et al.</i> (2017a, 2019), Gaibova & Mamedova (in press)
Reptilia: Ordo: Squamata	26	114	22.8	
Rodents	112	325	34.5	Gurbanova & Mamedova (2013), Gurbanova (2015), Gaibova <i>et al.</i> (2017a)
Cats	17	54	31.5	Gaibova <i>et al.</i> (2017a)
Dogs	14	56	25	
Total	257	740	34.7	
<i>Domestic (farm) animals</i>				
Birds	198	729	27.2	Gaibova <i>et al.</i> (2017a), Musaev <i>et al.</i> (1998)
Domestic pigs	804	2,857	28.1	Musaev <i>et al.</i> (1996), Hacıyeva & Ahmedov (2016)
Horse	2	4	50	Gaibova <i>et al.</i> (2017a)
Donkey	1	3	33	
Domestic goat	25	127	19.7	Gaibova & Iskenderova (2012)
Domestic sheep	623	1,823	34.2	Musaev <i>et al.</i> (1996), Gaibova & Iskenderova (2012, 2014)
Cow	779	2,595	30	Musaev <i>et al.</i> (1996), Gaibova & Iskenderova (2012, 2014)
Buffalo	135	318	42.5	Gaibova & Iskenderova (2012, 2014)
Zebu (Indicine cattle)	14	30	46.7	Gaibova & Iskenderova (2012)
Bactrian camel	65	182	35.7	Gaibova <i>et al.</i> (2011)
Total	2,646	8,668	30.5	
Total	2,903	9,408	30.9	

Table 3 | Prevalence of *Cryptosporidium* reported from amphibians in Azerbaijan territory

Host name	Geographic location	n positive	n total	%	References
<i>Amphibians</i>					
<i>Bufo variabilis</i> (European green toad)	Absheron	17	36	47.2	Mamedova (2010)
	Lankaran	3	3	100	
<i>Bufo verrucosissimus</i> (Caucasian toad)	Lankaran	1	6	16.7	
<i>Hyla savignyi</i> (Lemon-yellow tree frog)	Lankaran	0	2		
<i>Pelophylax ridibundus</i> (Euroasian marsh frog)	Lankaran	9	28	32.1	
	Shabran	0	9		
	Gobustan	0	1		
	Gabala	0	2		
Total		30	87	34.5	

(34.7%) than in farmed animals (30.5%). Fecal samples were collected and tested from 8,668 livestock animals from farms in different regions of Azerbaijan, where 30.5% of them tested positive for *Cryptosporidium* oocysts. Fecal samples were collected and tested from 740 wild animals captured from different regions of Azerbaijan, from which 34.7% tested positive for *Cryptosporidium* oocysts (Table 2). The highest prevalence of *Cryptosporidium* oocysts shedding was observed in feces from testudines (55.8% positive), chickens (50.6% positive), and buffaloes (42.4% positive). Overall, feces from younger (immature) animals were more likely to test positive for *Cryptosporidium* spp. than feces from adult animals. Furthermore, male animals had a higher *Cryptosporidium* spp. prevalence than female animals. In the rural and urban areas of Azerbaijan, *Cryptosporidium* infection was more widespread than in the mountainous areas.

Table 4 | Prevalence of *Cryptosporidium* reported in reptilians from Azerbaijan territory

Host name	Geographic location	n positive	n total	%	References
Reptilians					
Ordo: Testudines					
<i>Emys orbicularis</i> (European pond turtle)	Absheron	23	24	95.8	Gaibova <i>et al.</i> (2019)
	Shabran	0	16	0	
<i>Mauremys caspica</i> (East Caspian turtle)	Lankaran	1	1	100	Gaibova & Mamedova (in press)
	Absheron	16	16	100	Gaibova <i>et al.</i> (2019)
<i>Testudo graeca</i> (Greek tortoise)	Absheron	2	23	8.7	Gaibova & Mamedova (in press)
	Gakh district	2	3	75	
	Absheron	7	7	100	Gaibova <i>et al.</i> (2019)
	Balakan, Zagatala districts	7	14	50.0	Gaibova <i>et al.</i> (2017a)
Total (Testudines)		58	104	55.8	
Ordo: Squamata					
<i>Tenuidactylus caspius</i> (Caspian Bent-toed gecko)	Absheron	4	19	21.1	Gaibova & Mamedova (in press)
	Gobustan	1	2		
<i>Paralaudakia caucasia</i> (Caucasian agama)	Gobustan	11	68	16.2	
<i>Eremias arguta</i> (Steppe-runner)	Shirvan	1	2	50	
<i>Eirenis collaris</i> (Collared dwarf racer)	Gobustan	2	6	33.3	
<i>Hemorrhoids ravergieri</i> (Spotted whip snake)	Gobustan district	1	2	50	
<i>Natrix tessellata</i> (Dice snake)	Absheron	5	11	11.5	
<i>Macrovipera lebetina</i> (Levantine viper)	Balakan, Zagatala districts	1	4	25.0	Gaibova <i>et al.</i> (2017a)
Total (Squamata)		26	114	22.8	
Total		84	218	38.5	

Table 5 | Prevalence of *Cryptosporidium* reported in birds from Azerbaijan territory

Hostname	Geographic location	n positive	n total	%	References
<i>Gallus domesticus</i> (Chickens)	Poultry farms in Absheron	135	269	50.6	Musaev <i>et al.</i> (1998)
<i>Phasianus colchicus</i> (Pheasants)	Poultry farms in Absheron	16	203	7.9	
<i>Pavo cristatus</i> (Peacocks)	Poultry farms in Absheron	8	62	12.9	
<i>Coturnix coturnix</i> (Quails)	Poultry farms in Absheron	26	120	21.7	
<i>Columba livia</i> Gm. (Rock dove)	Balakan, Gakh, Zagatala districts	8	60	13.3	Gaibova <i>et al.</i> (2017a)
<i>Anser anser</i> (Grey goose)	Balakan, Gakh, Zagatala districts	3	7	43.0	
<i>Anser Penelope</i> (Grey duck)	Balakan, Gakh, Zagatala districts	2	8	25.0	
Total		198	729	27.2	

Cryptosporidium infection in amphibians and reptilians

Relatively little is known about *Cryptosporidium* in amphibians, and currently, the only accepted species is *Cryptosporidium fragile*, which was described from the stomach of naturally infected black-spined toads (*Duttaphrynus melanostictus*) from the Malay peninsula in Southeast Asia (Jirku *et al.* 2008; Table 1).

The first report of *Cryptosporidium* oocysts in amphibians from Azerbaijan was in 2010. *Cryptosporidium* oocysts were found in the feces of all examined amphibian species except for European tree frogs (Table 3). We found that the morphometric characteristics of *Cryptosporidium* oocysts from *Bufo verrucosissimus* are similar to those of the only valid amphibian *Cryptosporidium* species, *C. fragile*. These oocysts had an average size of $6.31 \pm 0.01 \times 5.01 \pm 0.01 \mu\text{m}$. In general,

Table 6 | Prevalence of *Cryptosporidium* reported in mammals from Azerbaijan territories

Host name	Geographic location	n positive	n total	%	References
<i>Rattus norvegicus</i> (Brown rat)	Gakh	8	11	72.7	Gurbanova Mamedova (2013)
	Absheron, Gobustan	23	54	42.6	Gurbanova (2015)
	Balakan, Zagatala districts	4	9	44.4	Gaibova <i>et al.</i> (2017a)
<i>Mus musculus</i> (House mouse)	Absheron, Gobustan	26	107	24.5	Gurbanova (2015)
	Balakan, Gakh, Zagatala districts	13	21	62.0	Gaibova <i>et al.</i> (2017a)
<i>Meriones libycus</i> (Libyan jird)	Absheron, Gobustan	38	123	30.9	Gurbanova (2015)
Total		112	325	34.5	
<i>Canis lupus familiaris</i> (Dog)	Balakan, Gakh, Zagatala districts	14	56	25	Gaibova <i>et al.</i> (2017a)
<i>Felis silvestris catus</i> (Cat)	Balakan, Gakh, Zagatala districts	17	54	31.5	
Total		31	110	28.2	
<i>Sus scrofa domesticus</i> (Domestic pig)	Pig farms in Absheron	201	1,078	18.6	Musaev <i>et al.</i> (1996)
	Pig farms in Absheron	339	874	39.0	Haciyeva Ahmadov (2016)
	Pig farms in Shamakhi	94	393	24.0	
	Pig farms in Khudat	83	195	42.5	
	Pig farms in Ismayilli	43	220	19.5	
	Pig farms in Salyan	44	97	45.3	
Total		804	2,857	28.1	
<i>Equus ferus caballus</i> (Horse)	Balakan, Qakh, Zagatala districts	2	4		Gaibova <i>et al.</i> (2017a)
<i>Equus africanus asinus</i> (Donkey)	Balakan, Qakh, Zagatala districts	1	3		
Total		3	7	42.9	
<i>Capra aegagrus hircus</i> (Domestic goat)	Absheron, Shabran, Samukh districts	14	57	24.5	Gaibova Iskenderova (2012)
	Ganja, Goygol district	6	35	17.1	
	Dashkasan district	5	35	14.3	
Total		25	127	19.7	
<i>Ovis aries</i> (Domestic sheep)	Farms in Absheron	139	612	22.7	Musaev <i>et al.</i> (1996)
	Absheron, Shabran, Samux	16	220	7.3	Gaibova Iskenderova (2012)
	Ganja, Goygol district	35	58	60.3	
	Dashkasan district	30	57	52.6	
	Gobustan district	48	143	33.6	
	Balakan, Gakh, Zagatala districts	355	733	48.4	Gaibova Iskenderova (2014)
Total		623	1,823	34.2	
<i>Bos taurus</i> (Cow)	Farms in Absheron	366	1,736	21.1	Musaev <i>et al.</i> (1996)
	Absheron, Shabran, Samukh	25	105	24.0	Gaibova Iskenderova (2012)
	Ganja, Goygol district	10	56	17.9	
	Dashkasan district	10	55	18.2	
	Gobustan district	93	179	51.9	Gaibova Iskenderova (2014)
	Balakan, Gakh, Zagatala districts	275	464	59.3	
Total		779	2,595	30.02	
<i>Bubalus bubalis</i> (Buffalo)	Absheron, Shabran Samukh	0	3		Gaibova Iskenderova (2012)
	Ganja, Goygol district	15	70	21.4	
	Dashkasan district	15	75	20.0	
	Balakan, Gakh, Zagatala districts	105	170	61.8	Gaibova Iskenderova (2014)
Total		135	318	42.5	
<i>Bos taurus indicus</i> Zebu (Indicine cattle)	Absheron, Shabran, Samukh	7	15	46.7	Gaibova Iskenderova (2012)
	Dashkasan district	7	15	46.7	
Total		14	30	46.7	
<i>Camelus bactrianus</i> (Bactrian camel)	Farms in Salyan district	65	182	35.7	Gaibova <i>et al.</i> (2011)
Total		2,591	8,374	30.9	

all the oocysts had an elongated oval shape, with a length/width ratio of 1.24. The prevalence of *Cryptosporidium* in the Absheron peninsula and Lankaran lowland was higher than the mountainous regions (Mamedova 2010).

The first report of *Cryptosporidium* in tortoise described oocyst detection using microscopy in the feces of an Indian star tortoise, *Geochelone elegans* (Schoepff 1795), which is kept in a zoo in the USA (Heuschele *et al.* 1986). *Cryptosporidium ducismarci* has been reported in several species of tortoises, snakes, and lizards (Traversa 2010). *C. testudinis* is a parasite of the tortoise, and its oocysts are significantly larger than those of *C. ducismarci*, allowing these two species to be distinguished microscopically (Ježková *et al.* 2016).

In the years from 2008 to 2019, a total of 104 tortoise and turtles (3 species: *Emys orbicularis* (European pond turtle), *Mauremys caspica* (East Caspian turtle), and *Testudo graeca* (Greek tortoise)) were examined for the presence of *Cryptosporidium* and other gastrointestinal parasites from Azerbaijan (Table 4).

Fifty-eight of them (55.8%) were infected with *Cryptosporidium* oocysts. The *Cryptosporidium* oocysts from *Testudo graeca* specimens caught in the territory of Absheron peninsula and in the territory Gakh district were morphologically compared. Oocysts from the territory of Absheron peninsula measured $5.5 \pm 0.1 \times 4.9 \pm 0.01 \mu\text{m}$ and had a length/width index of 1.12 ± 0.03 , and the oocysts obtained from the territory Gakh district were similar in size and measured $5.2 \pm 0.4 \times 4.02 \pm 0.34 \mu\text{m}$, with an index of 1.1 ± 0.03 . The oocysts isolated from the *Testudo graeca* specimens were morphologically similar to *C. ducismarci* that is described in the literature. It was the first time that *C. ducismarci* was found in a Greek tortoise (*T. graeca*). Reptiles caught in the territory of the Absheron peninsula showed a higher prevalence (100%) than reptiles caught in the mountainous territory (50%) (Gaibova & Mamedova *in press*).

Cryptosporidium serpentis (Levine 1980) and *C. varanii* (syn. *Cryptosporidium saurophilum*) are the only valid species associated with reptile reservoirs (Ordo: Squamata) (Pavlásek *et al.* 1995; Pavlasek & Ryan 2008; Plutzer & Karanis 2009; Table 1).

A total of 160 specimens belonging to 18 species of ordo Squamata were examined for *Cryptosporidium* (Gaibova & Mamedova *in press*). *Cryptosporidium* oocysts were found in the feces of 114 reptiles from 7 species (Table 4).

Cryptosporidium oocysts that infected the Caucasian agama (*Paralaudakia caucasia*) (oocysts were 6.4 ± 0.2 by $5.6 \pm 0.1 \mu\text{m}$, a length/width index of 1.2 ± 0.02) and the Steppe-runner (*Eremias arguta*) (oocysts were 6.4 ± 0.2 by $4.7 \pm 0.1 \mu\text{m}$, a length/width index of 1.4 ± 0.1) had morphological characteristics related to *C. serpentis*. Oocysts from the feces of a naturally infected Spotted whip snake (*Hemorrhoids ravergieri*) and Dice snake (*Natrix tessellate*) measured $4.7 \pm 0.1 \times 4.4 \pm 0.1 \mu\text{m}$, with a length/width ratio of 1.07 ± 0.02 and $4.9 \pm 0.1 \times 4.8 \pm 0.2 \mu\text{m}$, and a length/width ratio of 1.07 ± 0.02 , respectively. The authors reported that these oocysts were morphologically indistinguishable from those of *C. varanii*. For the first time, the Caucasian agama (*Paralaudakia caucasia*) and Steppe-runner (*Eremias arguta*) have been identified as the host of *C. serpentis*; and the Spotted whip snake (*Hemorrhoids ravergieri*) and Dice snake (*Natrix tessellate*) for *C. varanii*. Reptiles caught from the territory of Absheron and Gobustan showed a higher prevalence of *Cryptosporidium* than other Azerbaijan regions (Gaibova & Mamedova *in press*).

Cryptosporidium infection in birds

Cryptosporidiosis is one of the main protozoan infections among birds. *Cryptosporidium* species have been reported in more than 30 avian species worldwide (Sreter & Varga 2000). The first description of *Cryptosporidium* infection among birds (chicken) was reported by Tyzzer (1929). In 1955, a new species namely *C. meleagridis* was reported to cause illness and death in young turkeys (Slavin 1955). Later, cryptosporidiosis was diagnosed among domestic geese (*Anser anser*) (Proctor & Kemp 1974) and broiler chickens (Fletcher *et al.* 1975). Current *et al.* (1986) described the biological cycle of *Cryptosporidium* in domestic chickens and named its species, *C. baileyi*. The third valid species of this parasite in birds, *C. galli*, was described by Pavlásek (1999) from the proventriculi of chickens and later was revised by Ryan *et al.* (2003). To date, five species of *Cryptosporidium* (*C. meleagridis*, *C. baileyi*, *C. galli*, *C. avium*, and *C. proventriculi*) have been described in birds (Table 1).

Between 1987 and 2019, a total of 729 fecal samples from birds were collected from different regions in Azerbaijan. According to the microscopy results using Ziehl–Neelsen staining, *Cryptosporidium* oocysts were present in 27.2% of the samples. The first report of *Cryptosporidium* in birds from Azerbaijan was in 1998. A total of 654 bird fecal samples from four species were examined for the *Cryptosporidium* spp. infection during the 9-year study (1989–1998) from farms in the Absheron peninsula, where 185 of them (28.3%) were infected by *Cryptosporidium* oocysts. The extent of *Cryptosporidium* oocysts infection in chickens, pheasants, peacocks, and quails were 50.6% (135/269), 7.9% (16/203), 12.9% (8/62), and

21.7% (26/120), respectively (Musaev *et al.* 1998). The highest prevalence of *Cryptosporidium* was in chickens (50.6%) (Table 5).

Oocysts from the feces of chickens measured $5.3 \times 4.6 \mu\text{m}$ and had a length/width ratio of 1.15, pheasants measured $4.4 \times 3.9 \mu\text{m}$ and had a length/width ratio of 1.13, peacocks measured $4.7 \times 4.15 \mu\text{m}$ and had a length/width ratio of 1.3, and quails measured $5.14 \times 4.8 \mu\text{m}$ and had a length/width ratio of 1.07. The two *Cryptosporidium* species (*C. meleagridis* and *C. baileyi*) that were detected in bird fecal smears from the study areas in Azerbaijan were morphologically similar to the oocysts from the same bird species that were detected in previous studies (Zha & Jiang 1994; Fujino 1996; Ryan *et al.* 2003).

***Cryptosporidium* infection in mammals**

Mammals represent the largest group of animals known to be infected with *Cryptosporidium* spp. *Cryptosporidium* infections have been reported in at least 155 mammalian species (O'Donogue 1995; Fayer *et al.* 1997; Fayer & Xiao 2007). Wild animals seem to be involved in the epidemiology of most zoonoses and serve as major reservoirs for the transmission to domestic animals and humans (Kruse *et al.* 2004). *C. muris*, *C. tyzzeri*, *C. proliferans*, *C. apodemi*, *C. ditrichi*, *C. occultus*, *C. alticolis*, *C. macroti*, *C. ubiquitum*, and *C. tyzzeri* are known parasites of rodents (Table 1).

Three-hundred and twenty-five rodents from three species from the Azerbaijan territories were examined for *Cryptosporidium* oocysts and 112 (34.5%) of them were infected (Table 6). Oocysts appeared as round or ellipsoid formations. Oval oocysts measuring $5.06 \times 4.0 \mu\text{m}$, whereas ellipsoidal oocysts measured $7.50 \times 5.50 \mu\text{m}$. In Azerbaijan, three species of *Cryptosporidium*, such as *C. muris*, *C. parvum*, and *C. ubiquitum*, from rodents have been reported (Gurbanova & Mamedova 2013; Gurbanova 2015; Gaibova *et al.* 2017b).

Cryptosporidium spp. were first reported in cats in Japan (Iseki 1979), later it was called *C. felis*. The first evidence of cryptosporidiosis in dogs was reported by Tzipory & Campbell (1981), which was labeled as *C. canis*. After the examination of 110 dogs and cats caught from the mountainous regions in the Azerbaijan, *Cryptosporidium* oocysts were detected in 25% of dog and 31.5% of cat specimens (Table 6).

Cryptosporidium is a parasite responsible for widespread disease in livestock. The great majority of infections have been reported in domestic animals of economic importance, such as cattle, pigs, and sheep. Studies worldwide suggest that cattle are infected with four major *Cryptosporidium* species: *C. parvum*, *C. bovis*, *C. andersoni*, and *C. ryanae* (Xiao & Feng 2008; Xiao 2010; Ryan *et al.* 2014).

At least 8 *Cryptosporidium* species have been identified in sheep feces, including *C. parvum*, *C. hominis*, *C. andersoni*, *C. suis*, *C. xiaoi*, *C. fayeri*, *C. ubiquitum*, and *C. scrofarum*. *C. xiaoi*, *C. ubiquitum*, and *C. parvum* that had the highest prevalence. *C. parvum*, *C. hominis*, *C. ubiquitum*, and *C. xiaoi* have also been identified in goats. The main *Cryptosporidium* species identified in pigs worldwide are *C. suis* and *C. scrofarum*, although *C. muris*, *C. tyzzeri*, and *C. parvum* have also been reported in pigs (Ryan *et al.* 2014; Table 1).

The prevalence of *Cryptosporidium* in cattle, sheep, goats, buffaloes, and pigs has been studied in Azerbaijan. The first report was published in 1996 (Musaev *et al.* 1996). During a 32-year period from 1987 to 2019, a total of 7,750 (2,595 calves, 318 buffalo, 30 zebus, 1,823 sheep, 127 goats, and 2,857 pigs) stool samples were examined for *Cryptosporidium* (Table 4). Oocysts from the feces of a naturally infected large and young cattle and buffalo measured 5.0×4.7 ($4.4\text{--}5.6 \times 4.2\text{--}5.2$) μm , with a length/width ratio of 1.05. We presented the data on relevant *Cryptosporidium* oocysts in feces from cattle, pigs, and sheep of different ages and the results of experimentally infected laboratory animals (rats, mice, rabbits, and coypus) with oocysts as well. Younger domestic animals showed a higher prevalence of oocyst shedding than older domestic animals. The Coccidia, from the genera *Cryptosporidium*, parasitize the older and younger cattle and buffalo in the Azerbaijan farm economies that were studied from 2005 to 2008, which were situated at different heights above the sea level (Gaibova & Iskenderova 2012). In the farm communities from the vertical belts, lowlands, foothills, and mountains, all reported that the younger cattle suffered higher consequences of *Cryptosporidium* infection than larger cattle and buffalo. The prevalence of *Cryptosporidium* in sheep was higher in the mountainous regions than in cows, goats, or buffalo that were raised in the lowland areas. Three species of *Cryptosporidium* were found in older and younger cattle and buffalo in Azerbaijan: *C. andersoni*, *C. bovis*, and *C. hominis* (Gaibova *et al.* 2017b).

In total, 182 Bactrian camels from Azerbaijan were investigated for *Cryptosporidium*, whereas 65/182 (35.7%) of them were infected with *Cryptosporidium* oocysts (Table 6), and younger camels showed a higher prevalence than the older camels. The highest prevalence of infection was recorded during the autumn season. Oocysts appeared either as round or oval formations, with a diameter $3.34\text{--}5.01 \mu\text{m}$, nearly spherical (a length/width ratio of 1.02 ± 0.003) with a measurement

of $5.0 \pm 0.03 \times 4.92 \pm 0.03 \mu\text{m}$, or even larger with a measurement of $7.4 \pm 0.23 \times 6.9 \pm 0.17 \mu\text{m}$, with a length/width ratio of 1.05 ± 0.003 . Two species of *Cryptosporidium*, namely *C. muris* and *C. andersoni*, were noted in the camel study (Gaibova *et al.* 2011).

In the years 2009–2015, a total of 2,857 pigs were examined for the presence of *Cryptosporidium*, whereas 804 (28.1%) of them were infected with *Cryptosporidium* oocysts (Table 6). The extent of invasion with *Cryptosporidium* was higher in the lowland areas of the Absheron peninsula (39%) and in the Salyan region (45.3%). In the foothill area, Khudat had a 42.5% prevalence, and the mountains of Shamakhi 24% and Ismayilli 19.5%. Most of the detected *Cryptosporidium* oocysts were in the medium size range of 4.7–4.0 μm . These authors also obtained larger oocysts that measured $7.5 \times 7.0 \mu\text{m}$ in the study. Two species of *Cryptosporidium* were found in pigs from Azerbaijan, *C. muris* and *C. suis* (Hacıyeva & Ahmadov 2016).

Cryptosporidium infections in small ruminants may be a source for cryptosporidiosis in humans. In particular, sheep and goats are the known reservoirs of *Cryptosporidium* in cases of human infections (Koinari *et al.* 2014). *Cryptosporidium* outbreaks in school children have been associated with contact with lamb/goat kids as reported in the literature (Lange *et al.* 2014).

The diagnosis of cryptosporidiosis relies on the identification of oocysts in fecal samples released by the infected host. Stool specimens were processed using the modified acid-fast staining method (Ziehl–Neelsen (mZN)) and microscopically

Table 7 | *Cryptosporidium* species reported from animals (wild, domestic, birds, reptiles, and amphibians) in Azerbaijan territory

<i>Cryptosporidium</i> species	Hosts	Dimension (μm)	L/W (Length/Width)
<i>Cryptosporidium fragile</i>	<i>Bufo verrucosissimus</i> – Caucasian toad	$6.31 \pm 0.01 \times 5.01 \pm 0.01$	1.24
<i>Cryptosporidium ducismarci</i>	<i>Testudo graeca</i> – Greek tortoise	$5.5 \pm 0.1 \times 4.9 \pm 0.01$, $5.2 \pm 0.4 \times 4.02 \pm 0.34$	1.12 ± 0.03 , 1.1 ± 0.03
<i>Cryptosporidium serpentis</i>	<i>Paralaudakia caucasia</i> – Caucasian agama	$6.4 \pm 0.2 \times 5.6 \pm 0.1$	1.2 ± 0.02
	<i>Eremias arguta</i> – Steppe-runner	$6.4 \pm 0.2 \times 4.7 \pm 0.1$	1.4 ± 0.1
<i>Cryptosporidium varanii</i>	<i>Hemorrhoids ravergieri</i> – Spotted whip snake	$4.7 \pm 0.1 \times 4.4 \pm 0.1$	1.07 ± 0.02
	<i>Natrix tessellate</i> – Dice snake	$4.9 \pm 0.1 \times 4.8 \pm 0.2$	1.07 ± 0.02
<i>Cryptosporidium baileyi</i>	<i>Gallus domesticus</i> (Chickens)	5.3×4.6	1.15
<i>Cryptosporidium meleagridis</i>	<i>Phasianus colchicus</i> (Pheasants)	4.4×3.9	1.13
	<i>Pavo cristatus</i> (Peacocks)	4.7×4.15	1.3
	<i>Coturnix coturnix</i> (Quails)	5.14×4.8	1.07
<i>Cryptosporidium muris</i>	<i>Mus musculus</i> – House mouse	$7.73\text{--}7.91 \times 5.50\text{--}7.73$	1.29
	<i>Rattus norvegicus</i> – Brown rat,	$7.53\text{--}7.85 \times 6.40\text{--}7.85$	1.04–1.17
	<i>Meriones libycus</i> – Libyan jird	$7.66\text{--}7.94 \times 5.50\text{--}7.73$	1.38–1.41
	Calves	8.35×6.68	1.0
	Pigs	7.5×7.05	1.02
<i>Cryptosporidium parvum</i>	<i>Mus musculus</i> – House mouse	5.06×4.05	1.0
	<i>Rattus norvegicus</i> – Brown rat	5.01×3.89	1.0
	Camel	$5.0 \pm 0.03 \times 4.92 \pm 0.03$	1.02 ± 0.003
	Calves	5.01×4.2	1.0
	Sheep	5.85×5.01	1.0
Human	5.01×4.2	1.0	
<i>Cryptosporidium ubiquitum</i>	<i>Mus musculus</i> – House mouse, <i>Rattus norvegicus</i> – Brown rat, <i>Meriones libycus</i> – Libyan jird	5.01×4.35	1.08
<i>Cryptosporidium andersoni</i>	Camel	$7.4 \pm 0.23 \times 6.9 \pm 0.17$	1.05 ± 0.003
	Sheep, goat	$6.3 \pm 0.07 \times 6.08 \pm 0.08$	1.03
	Calves, buffalo	$6.7\text{--}5.85 \times 6.7\text{--}5.01$	1.0–1.2
<i>Cryptosporidium bovis</i>	Large and small cattle	5.0×4.7 ($4.4\text{--}5.6 \times 4.2\text{--}5.2$)	1.05
<i>Cryptosporidium hominis</i>	Calves, buffalo, sheep, human	$4.35 \pm 0.16 \times 3.9 \pm 0.14$ ($5.8\text{--}5.01 \times 4.2\text{--}3.34$)	1.1
	Pigs	4.7×4.0	1.03

examined for *Cryptosporidium* oocysts. Thirteen species of *Cryptosporidium* (*C. fragile*, *C. ducismarci*, *C. serpentis*, *C. varanii*, *C. baileyi*, *C. meleagridis*, *C. muris*, *C. parvum*, *C. ubiquitum*, *C. andersoni*, *C. bovis*, *C. hominis*, and *C. suis*) have been reported from amphibians, reptiles, birds, and mammals that were identified from the studies conducted from 1987 to 2019 on the structural features of *Cryptosporidium* oocysts in Azerbaijan territory (Table 7). These species of *Cryptosporidium* were identified by microscopy and mZN staining from fecal samples of animal specimens collected in the studies. The prevalence of *Cryptosporidium* in Absheron peninsula and Lankaran lowland was higher than in the mountainous regions from these animals.

These investigations confirmed that *Cryptosporidium* spp. are common parasites of wild and domestic animals, birds, reptiles, and amphibians in Azerbaijan. The prevalence of *Cryptosporidium* infection was higher in the rural than the urban areas of Azerbaijan. Additional investigations are in progress to further evaluate and estimate the widespread prevalence and distribution of this pathogen throughout Azerbaijan. There is a significant cryptosporidiosis risk for animals and humans from contaminated fecal material in the water and food supply. A unified public health policy needs to be implemented to protect the susceptible human and animal populations.

CONCLUSION

The present review has shown that there is a high prevalence of *Cryptosporidium* spp. (more than 30%) in the areas studied in Azerbaijan. The studies of *Cryptosporidium* infection in animals and livestock from different regions of Azerbaijan have revealed the following distribution pattern: the highest prevalence of infection was recorded in the lowland areas and the lowest prevalence was recorded in the mountainous regions. The highest rate of infection with *Cryptosporidium* was found in reptiles and amphibians and other terrestrial animals from the Absheron peninsula and Gobustan reserve. The Absheron peninsula is the most urbanized territory of the Republic of Azerbaijan, where *Cryptosporidium* transmission from reptile and amphibian reservoirs could have a negative impact on human and animal health.

The review has shown that *Cryptosporidium* spp. is a common parasite of animals in Azerbaijan. Herein, 13 species of *Cryptosporidium* from amphibians, reptiles, birds, and mammals have been identified based on the structural features of *Cryptosporidium* oocysts from this country.

Cryptosporidium species have been determined based on a comparative analysis of morphometric parameters of oocysts found in stool specimens that are consistent with previously described species of Coccidia. The morphological features of *Cryptosporidium* oocysts have been essential for *Cryptosporidium* species identification. However, further lifecycle studies and DNA analyses are recommended to complement the morphometric characteristics of *Cryptosporidium* found in Azerbaijan. These studies will be key to the understanding of *Cryptosporidium* epidemiology and transmission in domestic and wild animals, natural environment, and humans living in Azerbaijan.

ACKNOWLEDGEMENTS

We acknowledge Chad Schou, University of Nicosia Medical School, Cyprus, for the time and effort devoted to improving the linguistic quality of this review.

DATA AVAILABILITY STATEMENT

All relevant data are included in the paper or its Supplementary Information.

REFERENCES

- Ahmed, S. & Karanis, P. 2018a Comparison of current methods used to detect *Cryptosporidium* oocysts in stools. *Int. J. Hyg. Environ. Health* **221** (5), 743–763. doi:10.1016/j.ijheh.2018.04.006. Epub 2018 Apr 21. PMID: 29776848.
- Ahmed, S. & Karanis, P. 2018b An overview of methods/techniques for the detection of *Cryptosporidium* in food samples. *Parasitol. Res.* **117** (3), 629–653. doi:10.1007/s00436-017-5735-0. Epub 2018 Jan 19. PMID: 29350281.
- Aldeyarbi, H. & Karanis, P. 2016 The ultra-structural similarities between *Cryptosporidium parvum* and the gregarines. *J. Eukar. Microbiol.* **63** (1), 79–85. doi:10.1111/jeu.12250.
- Alvarez-Pellitero, P. & Sitjà-Bobadilla, A. 2002 *Cryptosporidium molnari* n. sp. (Apicomplexa: Cryptosporidiidae) infecting two marine fish species, *Sparus aurata* L. and *Dicentrarchus labrax* L. *Int. J. Parasitol.* **32** (8), 1007–1021. doi:10.1016/s0020-7519(02)00058-9. PMID: 12076630.

- Alvarez-Pellitero, P., Quiroga, M., Sitjà-Bobadilla, A., Redondo, M., Palenzuela, O., Padrós, F., Vázquez, S. & Nieto, J. 2004 *Cryptosporidium scophthalmi* n. sp. (Apicomplexa: Cryptosporidiidae) from cultured turbot *Scophthalmus maximus*. Light and electron microscope description and histopathological study. *Dis. Aquat. Organ.* **62** (1–2), 133–145. doi:10.3354/dao062133. PMID: 15648840.
- Baldursson, S. & Karanis, P. 2011 Waterborne transmission of protozoan parasites: review of worldwide outbreaks – an update 2004–2010. *Water Res.* **45** (20), 6603–6614. doi:10.1016/j.watres.2011.10.013. Epub 2011 Oct 20. PMID: 22048017.
- Carreno, R., Martín, D. & Barta, J. 1999 *Cryptosporidium* is more closely related to the gregarines than to Coccidia as shown by phylogenetic analysis of apicomplexan parasites inferred using small-subunit ribosomal RNA gene sequences. *Parasitol. Res.* **85** (11), 899–904. doi:10.1007/s004360050655. PMID: 10540950.
- Čondlová, Š., Horčíčková, M., Sak, B., Květoňová, D., Hlásková, L., Konečný, R., Stanko, M., McEvoy, J. & Kváč, M. 2018, *Cryptosporidium apodemi* sp. n. and *Cryptosporidium ditrichi* sp. n. (Apicomplexa: Cryptosporidiidae) in *Apodemus* spp. *Eur. J. Protistol.* **63**, 1–12. doi:10.1016/j.ejop.2017.12.006. Epub 2018 Jan 4. PMID: 29360041.
- Current, W., Upton, S. & Haynes, T. 1986 The life cycle of *Cryptosporidium baileyi* n. sp. (Apicomplexa, Cryptosporidiidae) infecting chickens. *J. Protozool.* **33** (2), 289–296. doi:10.1111/j.1550-7408.1986.tb05608.x. PMID: 3735157.
- Efstratiou, A., Ongerth, J. & Karanis, P. 2017 Evolution of monitoring for *Giardia* and *Cryptosporidium* in water. *Water Res.* **123**, 96–112. doi:10.1016/j.watres.2017.06.042. Epub 2017 Jun 18. PMID: 28651085.
- Elwin, K., Hadfield, S., Robinson, G., Crouch, N. & Chalmers, R. 2012 *Cryptosporidium viatorum* n. sp. (Apicomplexa: Cryptosporidiidae) among travellers returning to Great Britain from the Indian subcontinent, 2007–2011. *Int. J. Parasitol.* **42** (7), 675–682. doi:10.1016/j.ijpara.2012.04.016. Epub 2012 May 23. PMID: 22633952.
- Fayer, R. & Santín, M. 2009 *Cryptosporidium xiaoi* n. sp. (Apicomplexa: Cryptosporidiidae) in sheep (*Ovis aries*). *Vet. Parasitol.* **164** (2–4), 192–200. doi:10.1016/j.vetpar.2009.05.011. Epub 2009 May 19. PMID: 19501967.
- Fayer, R. & Xiao, L. 2007 *Cryptosporidium* and *Cryptosporidiosis*. CRC Press M12, pp. 25–576.
- Fayer, R., Speer, C. & Dubey, J. 1997 The general biology of *Cryptosporidium*. In: *Cryptosporidium and Cryptosporidiosis* (Fayer, R., ed.). CRC Press, Boca Raton, FL, pp. 1–41.
- Fayer, R., Morgan, U. & Upton, S. 2000 Epidemiology of *Cryptosporidium*: transmission, detection and identification. *Int. J. Parasitol.* **30** (12–13), 1305–1322. doi:10.1016/s0020-7519(00)00135-1. PMID: 11113257.
- Fayer, R., Trout, J., Xiao, L., Morgan, U., Lai, A. & Dubey, J. 2001 *Cryptosporidium canis* n. sp. from domestic dogs. *J. Parasitol.* **87** (6), 1415–1422. doi:10.1645/0022-3395(2001)087[1415:CCNSFD]2.0.CO;2. PMID: 11780831.
- Fayer, R., Santín, M. & Xiao, L. 2005 *Cryptosporidium bovis* n. sp. (Apicomplexa: Cryptosporidiidae) in cattle (*Bos taurus*). *J. Parasitol.* **91** (3), 624–629. doi:10.1645/GE-3435. PMID: 16108557.
- Fayer, R., Santín, M. & Trout, J. M. 2008 *Cryptosporidium ryanae* n. sp. (Apicomplexa: Cryptosporidiidae) in cattle (*Bos taurus*). *Vet. Parasitol.* **156** (3–4), 191–198. doi:10.1016/j.vetpar.2008.05.024. Epub 2008 May 23. PMID: 18583057.
- Fayer, R., Santín, M. & Macarasin, D. 2010 *Cryptosporidium ubiquitum* n. sp. in animals and humans. *Vet. Parasitol.* **172** (1–2), 23–32. doi:10.1016/j.vetpar.2010.04.028. Epub 2010 Apr 28. PMID: 20537798.
- Feng, Y. & Xiao, L. 2017 Molecular epidemiology of cryptosporidiosis in China. *Front. Microb.* **8**, 1701.
- Feng, Y., Ryan, U. & Xiao, L. 2018 Genetic diversity and population structure of *Cryptosporidium*. *Trends Parasitol.* **34** (11), 997–1011. doi:10.1016/j.pt.2018.07.009. Epub 2018 Aug 11. PMID: 30108020.
- Fletcher, O., Munnell, J. & Page, R. 1975 Cryptosporidiosis of the bursa of Fabricius of chickens. *Avian Dis.* **19** (3), 630–639. PMID: 1164328.
- Fujino, T. 1996 Infectivity of *Cryptosporidium* sp. isolated from chickens in Japan to turkeys, bobwhite quails, and several kinds of experimental animals (Japan). *Jpn. J. Parasitol.* **45**, 295–298.
- Gaibova, H. & Iskenderova, N. 2012 Prevalence of infection with Coccidia (Sporozoa, Apicomplexa) in the large and small cattle in the farm economies of Azerbaijan depending on the height above the sea level. *Proc. Azerbaijan Soc. Zool.* **4** (2), 101–106 (in Russian).
- Gaibova, H. & Iskenderova, N. 2014 Cryptosporidia (Cryptosporidiidae, Coccidea, Apicomplexa) of domestic ruminants and humans in Azerbaijan. In: 'Actual Problems of Parasitology in Georgia' Collection of Scientific Works, Vol. XII. Tbilisi, pp. 110–122 (in Russian).
- Gaibova, H. & Mamedova, S. in press Anthropogenic influence on the formation of intestinal Coccidia (Sporozoa, Apicomplexa) in reptiles of Azerbaijan. *Amurian Zoological Journal* (in Russian).
- Gaibova, H., Iskenderova, N. & Hajieva, N. 2011 Cryptosporidia of the Bactrian camel in Azerbaijan. In: *Proceedings of the Azerbaijan Institute of Zoology*, Baku, Elm, Vol. 29, pp. 347–351 (in Russian).
- Gaibova, H., Iskenderova, N. & Gurbanova, T. 2017a Cryptosporidia (*Cryptosporidium*, Coccidea, Apicomplexa) of wild terrestrial vertebrates in the Sheki-Zagatala region. *Proc. Zool. Inst.* **35**, 135–140 (in Russian).
- Gaibova, H., Iskenderova, N. & Gurbanova, T. 2017b Review of the modern state of the emerid coccides of terrestrial vertebrates of Azerbaijan. In: *Proceedings XIX International Scientific Conference with Elements of the Scientific School of Young Scientists 'Biological Diversity Caucasus and South Russia'*, 4–7 November, Makhachkala, pp. 423–425 (in Russian).
- Gaibova, H., Iskenderova, N., Gurbanova, T. & Novruzov, N. 2019 The prevalence of intestinal coccidian in turtles in Azerbaijan. In: *Materials of the XXI International Scientific Conference 'Biological Diversity of the Caucasus and the South of Russia'. Dedicated to the 25th Anniversary of the Ingush State University and the 80th Anniversary of the Birth of The Honored Scientist of the Republic of Ingushetia, Corresponding Member of the REA, Professor Tochiev Tugan Yunusovich (Magas, 15–18 November 2019)*, Magas, pp. 304–306 (in Russian).

- Gurbanova, T. 2015 Comparative analysis of *Cryptosporidium* (Coccidia, Eimeriida, *Cryptosporidium*) infection in cattle, sheep, and rodents in different ecosystems of Azerbaijan. *Bull. Moscow State Reg. Univ., Nat. Sci.* **4**, 22–28 (in Russian).
- Gurbanova, T. & Mamedova, S. 2013 Study of the species composition of Coccidia (Sporozoa, Eucoccidia) of the grey rat (*Rattus norvegicus*) from different regions of Azerbaijan. *J. V. N. Karazin Kharkiv Natl. Univ. Ser.: Biol.* **17** (1056), 96–101 (in Russian).
- Haciyeva, N. & Ahmadov, E. 2016 Intestinal parasites in domestic pigs (*Sus scrofa domestica*) in farms of Azerbaijan. *J. Entomol. Zool. Studies.* **4**, 170–173.
- Henriksen, S. & Pohlenz, J. 1981 Staining of *Cryptosporidia* by a modified Ziehl-Neelsen technique. *Acta Vet. Scand.* **22** (3–4), 594–596. PMID: 6178277.
- Heuschele, W., Oosterhuis, J., Janssen, D., Robinson, P., Ensley, P., Meier, J., Olson, T., Anderson, M. & Benirschke, K. 1986 *Cryptosporidial infections in captive wild animals*. *J. Wildl. Dis.* **22** (4), 493–496. doi:10.7589/0090-3558-22.4.493. PMID: 3503135.
- Holubová, N., Sak, B., Horčíčková, M., Hlášková, L., Květoňová, D., Menchaca, S., McEvoy, J. & Kváč, M. 2016 *Cryptosporidium avium* n. sp. (Apicomplexa: Cryptosporidiidae) in birds. *Parasitol. Res.* **115** (6), 2243–2251. doi:10.1007/s00436-016-4967-8. Epub 2016 Feb 23. PMID: 26905074; PMCID: PMC4864505.
- Holubová, N., Zikmundová, V., Limpouchová, Z., Sak, B., Konečný, R., Hlášková, L., Rajský, D., Kopacz, Z., McEvoy, J. & Kváč, M. 2019 *Cryptosporidium proventriculi* sp. n. (Apicomplexa: Cryptosporidiidae) in *Psittaciformes* birds. *Eur. J. Protistol.* **69**, 70–87. doi:10.1016/j.ejop.2019.03.001. Epub 2019 Mar 26. PMID: 30981203.
- Hoover, D., Hoerr, F., Carlton, W., Hinsman, E. & Ferguson, H. 1981 Enteric cryptosporidiosis in a naso tang, *Naso lituratus* Bloch and Schneider. *J. Fish. Dis.* **4**, 425–428.
- Horčíčková, M., Čondlová, Š., Holubová, N., Bohumil, S., Květoňová, D., Hlášková, L., Konečný, R., Sedláček, F., Clark, M., Giddings, C., McEvoy, J. & Kváč, M. 2019 Diversity of *Cryptosporidium* in common voles and description of *Cryptosporidium alticolis* sp. n. and *Cryptosporidium microti* sp. n. (Apicomplexa: Cryptosporidiidae). *Parasitology* **146** (2), 220–235. doi:10.1017/S0031182018001142. Epub 2018 Jul 17. PMID: 30012231; PMCID: PMC6994189.
- Inman, L. & Takeuchi, A. 1979 Spontaneous cryptosporidiosis in an adult female rabbit. *Vet. Pathol.* **16**, 89–95.
- Iseki, M. 1979 *Cryptosporidium felis* sp. n. (Protozoa, Eimeriorina) from the domestic cat. *Jpn. J. Parasitol.* **28**, 285–307.
- Ismailova, G. & Gaibova, H. 1987 Detection of *Cryptosporidium* in calves in the farms of Absheron. Current problems of Protozoology. In: *Proceedings of the IV All-Union Congress of Protozoologists. Abstracts of Papers*, Leningrad, Nauka, p. 135.
- Ježková, J., Horčíčková, M., Hlášková, L., Sak, B., Květoňová, D., Novak, J., Hofmannová, L., McEvoy, J. & Kvac, M. 2016 *Cryptosporidium testudinis* sp. n., *Cryptosporidium ducismarci* Traversa, 2010 and *Cryptosporidium tortoise* genotype III (Apicomplexa: Cryptosporidiidae) in tortoises. *Folia Parasitol. (Praha)* **63**. doi:10.14411/fp.2016.035. PMID: 27827334.
- Jirku, M., Valigurova, A., Koudela, B., Křížek, Y., Modry, D. & Šlapeta, J. 2008 New species of *Cryptosporidium* Tyzzer, 1907 (Apicomplexa) from amphibian host: morphology, biology and phylogeny. *Folia Parasitol. (Praha)* **55** (2), 81–94. PMID: 18666410.
- Karanis, P., Kourenti, C. & Smith, H. 2007 Waterborne transmission of protozoan parasites: a worldwide review of outbreaks and lessons learnt. *J. Water Health* **5**, 1–38. doi:10.2166/wh.2006.002. PMID: 17402277.
- King, B. & Monis, P. 2007 Critical processes affecting *Cryptosporidium* oocyst survival in the environment. *Parasitology* **134**, 309–323. doi:10.1017/S0031182006001491. Epub 2006 Nov 13. PMID: 17096874.
- Koinari, M., Lymbery, A. & Ryan, U. 2014 *Cryptosporidium* species in sheep and goats from Papua New Guinea. *Exp. Parasitol.* **141**, 134–137. doi:10.1016/j.exppara.2014.03.021. Epub 2014 Apr 3. PMID: 24703974.
- Koudela, B. & Modry, D. 1998 New species of *Cryptosporidium* (Apicomplexa, Cryptosporidiidae) from lizards. *J. Folia Parasitol.* **45**, 93–100.
- Kruse, H., Kirkemo, A. & Handeland, K. 2004 Wildlife as a source of zoonotic infections. *Emerg. Infect. Dis.* **10**, 2067–2072. doi:10.3201/eid1012.040707. PMID: 15663840; PMCID: PMC3323390.
- Kváč, M., Kestránová, M., Pinková, M., Květoňová, D., Kalinová, J., Wagnerová, P., Kotková, M., Vítovec, J., Ditrich, O., McEvoy, J., Stenger, B. & Sak, B. 2013 *Cryptosporidium scrofarum* n. sp. (Apicomplexa: Cryptosporidiidae) in domestic pigs (*Sus scrofa*). *Vet. Parasitol.* **191**, 218–227. doi:10.1016/j.vetpar.2012.09.005. Epub 2012 Sep 12. PMID: 23021264; PMCID: PMC3525736.
- Kváč, M., Hofmannová, L., Hlášková, L., Květoňová, D., Vítovec, J., McEvoy, J. & Sak, B. 2014 *Cryptosporidium erinacei* n. sp. (Apicomplexa: Cryptosporidiidae) in hedgehogs. *Vet. Parasitol.* **201** (1–2), 9–17. doi:10.1016/j.vetpar.2014.01.014. Epub 2014 Jan 28. PMID: 24529828.
- Kváč, M., Havrdová, N., Hlášková, L., Daňková, T., Kanděra, J., Ježková, J., Vítovec, J., Sak, B., Ortega, Y., Xiao, L., Modrý, D., Chelladurai, J., Prantlová, V. & McEvoy, J. 2016 *Cryptosporidium proliferans* n. sp. (Apicomplexa: Cryptosporidiidae): molecular and biological evidence of cryptic species within gastric *Cryptosporidium* of mammals. *PLoS ONE* **11** (1), e0147090. doi:10.1371/journal.pone.0147090. PMID: 26771460; PMCID: PMC4714919.
- Kváč, M., Vlnatá, G., Ježková, J., Horčíčková, M., Konečný, R., Hlášková, L., McEvoy, J. & Sak, B. 2018 *Cryptosporidium occultus* sp. n. (Apicomplexa: Cryptosporidiidae) in rats. *Eur. J. Protistol.* **63**, 96–104. doi:10.1016/j.ejop.2018.02.001. Epub 2018 Feb 15. PMID: 29506004.
- Lange, H., Johansen, O., Vold, L., Robertson, L., Anthonisen, I. & Nygard, K. 2014 Second outbreak of infection with a rare *Cryptosporidium parvum* genotype in schoolchildren associated with contact with lambs/goat kids at a holiday farm in Norway. *Epidemiol. Infect.* **142**, 2105–2113. doi:10.1017/S0950268813003002. Epub 2013 Dec 5. PMID: 24308502.
- Levine, N. D. 1980 Some corrections of coccidian (Apicomplexa: Protozoa) nomenclature. *J. Parasitol.* **66**, 830–834. PMID: 7463253.

- Li, X., Pereira, M., Larsen, R., Xiao, C., Phillips, R., Striby, K., McCowan, B. & Atwill, E. R. 2015 *Cryptosporidium rubeyi* n. sp. (Apicomplexa: Cryptosporidiidae) in multiple *Spermophilus* ground squirrel species. *Int. J. Parasitol. Parasit. Wildl.* **4** (3), 343–350. doi:10.1016/j.ijppaw.2015.08.005. PMID: 26543805; PMCID: PMC4589830.
- Lindsay, D., Upton, S., Owens, D., Morgan, U., Mead, J. & Blagburn, B. 2000 *Cryptosporidium andersoni* n. sp. (Apicomplexa: Cryptosporidiidae) from cattle, *Bos taurus*. *J. Eukaryot. Microbiol.* **47** (1), 91–95. doi:10.1111/j.1550-7408.2000.tb00016.x. PMID: 10651302.
- MacKenzie, W., Hoxie, N., Proctor, M., Gradus, M., Blair, K., Peterson, D., Kazmierczak, J., Addiss, D., Fox, K., Rose, J. & David, J. 1994 A massive outbreak in Milwaukee of *Cryptosporidium* infection transmitted through the public water supply. *N. Engl. J. Med.* **331**, 161–167. doi:10.1056/NEJM199407213310304. Erratum in: *N. Engl. J. Med.* 1994; 331 (15), 1035. PMID: 7818640.
- Mamedova, S. 2010 Intestinal coccidia (Eucoccidia, Sporozoa, Apicomplexa) of some amphibia in Azerbaijan. *Int. J. Protistol.* **6**, 218–222.
- Morgan-Ryan, U., Fall, A., Ward, L., Hijjawi, N., Sulaiman, I., Fayer, R., Thompson, R., Olson, M., Lal, A. & Xiao, L. 2002 *Cryptosporidium hominis* n. sp. (Apicomplexa: Cryptosporidiidae) from *Homo sapiens*. *J. Eukaryot. Microbiol.* **49** (6), 433–440. doi:10.1111/j.1550-7408.2002.tb00224.x. PMID: 12503676.
- Musaev, M., Gaibova, G. & Ismailova, G. 1996 Prevalence of Cryptosporidia in farm animals in Azerbaijan. *Parasitology* **30**, 478–486 (in Russian).
- Musaev, M., Gaibova, G., Ismailova, G. & Iskenderova, N. 1997 The cross-infection of birds and mammals with *Cryptosporidium* (Apicomplexa, Sporozoa) oocysts. In: *Study and protection of the animal world at the end of the century. Proceedings of the Scientific Conference Dedicated to the 75-th Anniversary of Academician M.A. Musaev*, Baku, Elm, pp. 55–57.
- Musaev, M., Gaibova, G., Ismailova, G., Alieva, F. & Iskenderova, N. 1998 The Coccidia of the Gallinaceous birds in Azerbaijan. *Parasitology* **30**, 478–486.
- O'Donogue, P. 1995 *Cryptosporidium* and cryptosporidiosis in man and animals. *Int. J. Parasitol.* **25**, 139–195. doi:10.1016/0020-7519(94)e0059-v. PMID: 7622324.
- Paperna, I. & Vilenkin, M. 1996 Cryptosporidiosis in the gourami *Thrichogaster leeri*: description of a new species and a proposal for a new genus, *Piscicryptosporidium*, for species infecting fish. *Dis. Aquat. Org.* **27**, 95–101.
- Pavlásek, I. 1999 Cryptosporidia: biology, diagnosis, host spectrum, specificity, and the environment. *Remed. Klinicka Mikrobiol.* **3**, 290–301.
- Pavlascek, I. & Ryan, U. 2008 *Cryptosporidium varanii* takes precedence over *C. saurophilum*. *Exp. Parasitol.* **118**, 434–437. doi:10.1016/j.exppara.2007.09.006. Epub 2007 Sep 14. PMID: 17945215.
- Pavlascek, I., Láviccková, M., Horák, P., Král, J. & Král, B. 1995 *Cryptosporidium varanii* n. sp. (Apicomplexa: Cryptosporidiidae) in Emerald monitor (*Varanus prasinus* Schlegel, 1893) in captivity in Prague zoo. *Gazella* **22**, 99–108.
- Plutzer, J. & Karanis, P. 2009 Genetic polymorphism in *Cryptosporidium* species: an update. *Vet. Parasitol.* **165**, 187–199. doi:10.1016/j.vetpar.2009.07.003. Epub 2009 Jul 9. PMID: 19660869.
- Power, M. & Ryan, U. 2008 A new species of *Cryptosporidium* (Apicomplexa: Cryptosporidiidae) from eastern grey kangaroos (*Macropus giganteus*). *J. Parasitol.* **94** (5), 1114–1117. doi:10.1645/GE-1508.1. PMID: 18973420.
- Proctor, S. & Kemp, R. 1974 *Cryptosporidium anserinum* sp. n. (Sporozoa) in a domestic goose *Anser anser* L., from Iowa. *J. Protozool.* **21** (5), 664–666. doi:10.1111/j.1550-7408.1974.tb03724.x. PMID: 4217367.
- Ren, X., Zhao, J., Zhang, L., Ning, C., Jian, F., Wang, R., Lv, C., Wang, Q., Arrowood, M. & Xiao, L. 2012 *Cryptosporidium tyzzeri* n. sp. (Apicomplexa: Cryptosporidiidae) in domestic mice (*Mus musculus*). *Exp. Parasitol.* **130** (3), 274–281. doi:10.1016/j.exppara.2011.07.012. Epub 2011 Jul 23. PMID: 21803038.
- Robinson, G., Wright, S., Elwin, K., Hadfield, S., Katzer, F., Bartley, P., Hunter, P., Nath, M., Innes, E. & Chalmers, R. 2010 Re-description of *Cryptosporidium cuniculus* Inman and Takeuchi, 1979 (Apicomplexa: Cryptosporidiidae): morphology, biology and phylogeny. *Int. J. Parasitol.* **40** (13), 1539–1548. doi:10.1016/j.ijpara.2010.05.010. Epub 2010 Jul 1. PMID: 20600069.
- Ryan, U. 2010 *Cryptosporidium* in birds, fish, and amphibians. *Exp. Parasitol.* **24**, 113–120. doi:10.1016/j.exppara.2009.02.002. Epub 2009 Feb 11. PMID: 19545515.
- Ryan, U. & Xiao, L. 2003 Proposals for a revised taxonomy of *Cryptosporidium* parasites. In: *Proceedings Workshop on the Application of Genetic Fingerprinting for the Monitoring of Cryptosporidium in Humans, Animals, and the Environment* (Latham, S. M., Smith, H. V. & Wastling, J. M. eds). Boulder, USA. Foundation of Water Research, Marlow, UK, pp. 13–32.
- Ryan, U., Fall, A., Ward, L., Hijjawi, N., Sulaiman, I., Fayer, R., Thompson, R., Olson, M., Lal, A. & Xiao, L. 2002 *Cryptosporidium hominis* n. sp. (Apicomplexa: Cryptosporidiidae) from *Homo sapiens*. *J. Eukaryot. Microbiol.* **49** (6), 433–440. doi:10.1111/j.1550-7408.2002.tb00224.x. PMID: 12503676.
- Ryan, U., Xiao, L., Read, C., Sulaiman, I., Monis, P., Lal, A., Fayer, R. & Pavlascek, I. 2003 A re-description of *Cryptosporidium galli* (Pavlascek, 1999) (Apicomplexa: Cryptosporidiidae) from birds. *J. Parasitol.* **89**, 809–813. doi:10.1645/GE-74RI. PMID: 14533694.
- Ryan, U., Monis, P., Enemark, H., Sulaiman, I., Samarasinghe, B., Read, C., Buddle, R., Robertson, I., Zhou, L., Thompson, R. & Xiao, L. 2004 *Cryptosporidium suis* n. sp. (Apicomplexa: Cryptosporidiidae) in pigs (*Sus scrofa*). *J. Parasitol.* **90**, 769–773. doi:10.1645/GE-202R1. PMID: 15357067.
- Ryan, U., Power, P. & Xiao, L. 2008 *Cryptosporidium fayeri* n. sp. (Apicomplexa: Cryptosporidiidae) from the Red Kangaroo (*Macropus rufus*). *J. Eukaryot. Microbiol.* **55**, 22–26. doi:10.1111/j.1550-7408.2007.00299.x. PMID: 18251799.
- Ryan, U., Fayer, R. & Xiao, L. 2014 *Cryptosporidium* species in humans and animals: current understanding and research needs. *Parasitology* **141**, 1667–1685. doi:10.1017/S0031182014001085. Epub 2014 Aug 11. PMID: 25111501.

- Ryan, U., Paparini, A., Tong, K., Yang, R., Gibson-Kueh, S., O'Hara, A., Lymbery, A. & Xiao, L. 2015 *Cryptosporidium huwei* n. sp. (Apicomplexa: Eimeriidae) from the guppy (*Poecilia reticulata*). *Exp. Parasitol.* **150**, 31–35. doi:10.1016/j.exppara.2015.01.009. Epub 2015 Jan 28. PMID: 25637783.
- Ryan, U., Paparini, A., Monis, P. & Hijjawi, N. 2016 It's official – *Cryptosporidium* is a gregrarine: what are the implications for the water industry? *Water Res.* **105**, 305–313. doi:10.1016/j.watres.2016.09.013. Epub 2016 Sep 9. PMID: 27639055.
- Slapeta, J. 2006 *Cryptosporidium* species found in cattle: a proposal for a new species. *Trends Parasitol.* **22**, 469–474.
- Šlapeta, J. 2013 Cryptosporidiosis and *Cryptosporidium* species in animals and humans: a thirty colour rainbow? *Int. J. Parasitol.* **43**, 957–970. doi:10.1016/j.ijpara.2013.07.005. Epub 2013 Aug 20. PMID: 23973380.
- Slavin, D. 1955 *Cryptosporidium meleagridis* (sp. nov.). *J. Comp. Pathol.* **65** (3), 262–266. doi:10.1016/s0368-1742(55)80025-2. PMID: 13242675.
- Smith, H., Caccio, S., Tait, A., McLauchlin, J. & Thompson, R. 2006 Tools for investigating the environmental transmission of *Cryptosporidium* and *Giardia* infections in humans. *Trends Parasitol.* **22**, 160–167. doi:10.1016/j.pt.2006.02.009. Epub 2006 Feb 28. PMID: 16503418.
- Sreter, T. & Varga, I. 2000 Cryptosporidiosis in birds: a review. *Vet. Parasitol.* **87**, 261–279. doi:10.1016/s0304-4017(99)00178-8. PMID: 10669097.
- Traversa, D. 2010 Evidence of a new species of *Cryptosporidium* infecting tortoises: *Cryptosporidium ducimarci*. *Parasit. Vect.* **3**, 21. doi:10.1186/1756-3305-3-21. PMID: 20338035; PMCID: PMC2857862.
- Tyzzer, E. 1907 A sporozoan found the peptic glands of the common mouse. *Proc. Soc. Exp. Biol. Med.* **5**, 12–13.
- Tyzzer, E. 1912 *Cryptosporidium parvum* (sp. nov.), a coccidium found in the small intestine of the common mouse. *Arch. Protistenkd.* **26**, 394–412.
- Tyzzer, E. 1929 Coccidiosis in gallinaceous birds. *Am. J. Hyg.* **10**, 269–383.
- Tzipory, S. & Campbell, I. 1981 Prevalence of *Cryptosporidium* antibodies in 10 animal species. *J. Clin. Microbiol.* **14**, 455–456. doi:10.1128/JCM.14.4.455-456.1981. PMID: 7026613; PMCID: PMC272003.
- Vanathy, K., Parija, S. C., Mandal, J., Hamide, A. & Krishnamurthy, S. 2017 Cryptosporidiosis: a mini-review. *Trop. Parasitol.* **7**, 72–80. doi:10.4103/tp.TP_25_17. PMID: 29114483; PMCID: PMC5652058.
- Vetterling, J., Jervis, H., Merrill, T. & Sprinz, H. 1971 *Cryptosporidium wrairi* sp. n. from the guinea pig *Cavia porcellus*, with an emendation of the genus. *J. Protozool.* **18**, 243–247.
- Xiao, L. 2010 Molecular epidemiology of cryptosporidiosis: an update. *Exp. Parasitol.* **124**, 80–89. doi:10.1016/j.exppara.2009.03.018. Epub 2009 Apr 7. PMID: 19358845.
- Xiao, L. & Feng, Y. 2008 Zoonotic cryptosporidiosis. *FEMS Immunol. Med. Microbiol.* **52**, 309–323. doi:10.1111/j.1574-695X.2008.00377.x. Epub 2008 Jan 18. PMID: 18205803.
- Xiao, L., Fayer, R., Ryan, U. & Upton, S. 2004 *Cryptosporidium* taxonomy: recent advances and implications for public health. *Clin. Microbiol. Rev.* **17**, 72–97. doi:10.1128/cmr.17.1.72-97.2004. PMID: 14726456; PMCID: PMC321466.
- Zahedi, A., Durmic, Z., Gofton, A., Kueh, S., Austen, J., Lawson, M., Callahan, L., Jardine, J. & Ryan, U. 2017 *Cryptosporidium homai* n. sp. (Apicomplexa: Cryptosporidiidae) from the guinea pig (*Cavia porcellus*). *Vet. Parasitol.* **245**, 92–101. doi:10.1016/j.vetpar.2017.08.014. Epub 2017 Aug 24. PMID: 28969844.
- Zha, H. & Jiang, J. 1994 The life cycle of *Cryptosporidium meleagridis* in quails. *Acta Vet. Zootech. Sinica* **25**, 273–278.

First received 6 February 2021; accepted in revised form 14 May 2021. Available online 26 May 2021