


***Cryptosporidium* spp. and *Eimeria* spp. (Apicomplexa: Eimeriorina) of freshwater Cyprinid fish species in the Kura River basin in Azerbaijan territory**

Simuzer Mamedova^{a,b} and Panagiotis Karanis ^{c,d,*}

^a Institute of Zoology, Ministry of Science and Education Republic of Azerbaijan, Baku, Azerbaijan

^b Department of Life Sciences, Khazar University, Baku, Azerbaijan

^c Faculty of Medicine and University Hospital, University of Cologne, Cologne, Germany

^d Department of Basic and Clinical Sciences, University of Nicosia Medical School, Nicosia, Cyprus

*Corresponding author. E-mail: karanis.p@unic.ac.cy

 PK, 0000-0002-0733-0470

ABSTRACT

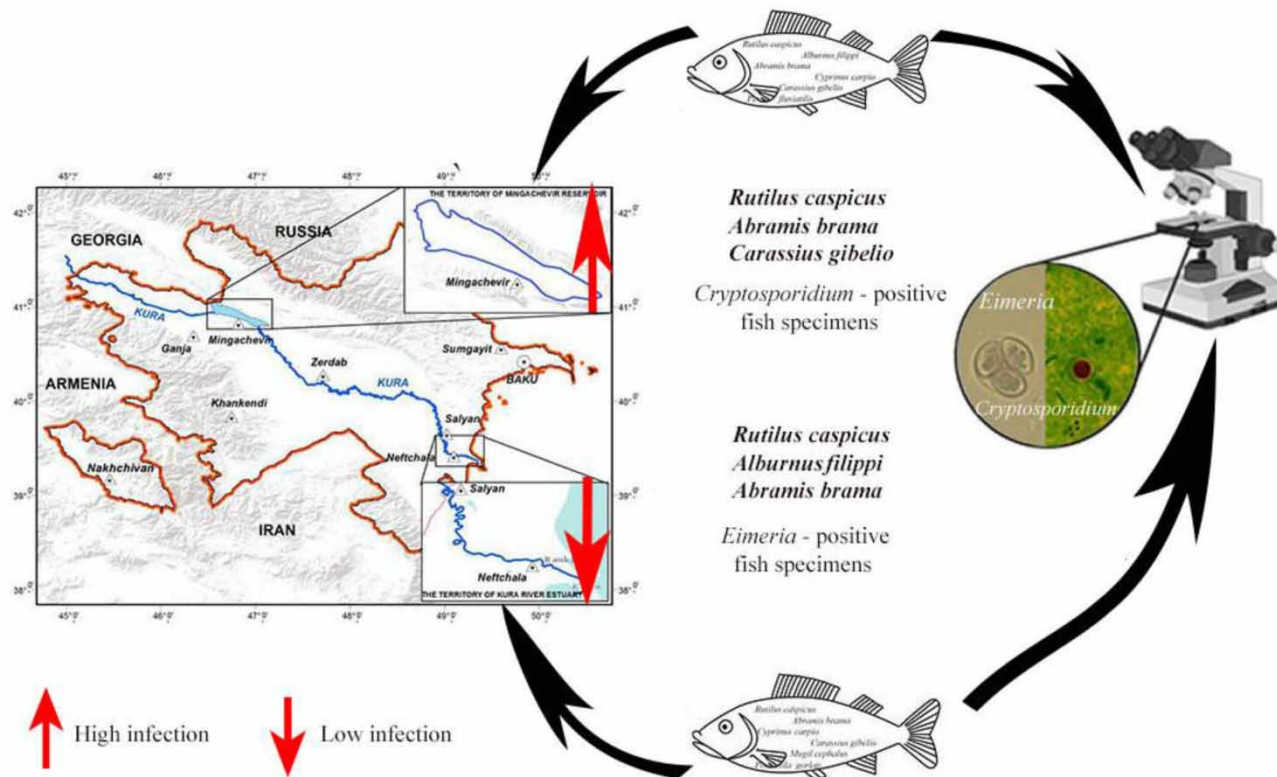
This study aims to determine the prevalence of *Cryptosporidium* and *Eimeria* spp. oocysts in fish specimens in the river Kura. It was conducted during the 2021–2022 at two sites: Mingachevir reservoir in central Azerbaijan and in Neftchala district where the river finally enters the Caspian Sea through a delta of the Kura River estuary. The diagnosis of oocysts was performed microscopically. Fine smears from the intestine epithelial layers stained by Ziehl-Neelsen for *Cryptosporidium* oocysts. To identify *Eimeria* oocysts, each fish's faecal material and intestinal scrapings were examined directly under a light microscope in wet samples on glass slides with a coverslip. Results revealed a prevalence of *Cryptosporidium* and *Eimeria* species infections in fish hosts from both territories *Rutilus caspicus*, *Alburnus filippi*, *Abramis brama orientalis* and *Carassius gibelio*. Of 170 investigated fish specimens, 8.8% (15/170) were infected with *Cryptosporidium* species oocysts. *Eimeria* species oocysts were identified in 20.6% (35/170). The presence of *Cryptosporidium* and *Eimeria* infections in fish specimens are natural infections. However, their presence in fish species may be attributed to the age of the fish species and water pollution. This is the first report regarding the prevalence of *Cryptosporidium* oocysts in fish species in Azerbaijan.

Key words: Azerbaijan, *Cryptosporidium*, *Eimeria*, freshwater fish, prevalence

HIGHLIGHTS

- Different fish species have been investigated from two territories of the Kura River.
- *Cryptosporidium* and *Eimeria* spp. oocysts are present in fish species in Azerbaijan.
- This is the first report of *Cryptosporidium* oocysts in fish in Azerbaijan.
- *Eimeria carpelli* is a wide-spread species of fish in Azerbaijan.

GRAPHICAL ABSTRACT



INTRODUCTION

Freshwater fish represent nearly a quarter of all vertebrate species (Cavin 2017) and are significant components of ecosystems. Fish are an excellent source of aquatic food, rich in calcium and phosphorus and a great source of minerals, such as iron, zinc, iodine, magnesium and potassium, which are required for growth and better human health. Fish consumption has increased at an average annual growth rate of 3.1%, far above the annual world population growth (1.6%). This high demand for fish products, with 156 million tonnes intended for human consumption in 2018, is supplied by capture fisheries and aquaculture production (FAO 2020).

Various agents such as helminths and protozoan parasites can negatively affect the fish population and cause significant economic losses to the farmers. The pathological impact of helminths on wild cyprinid fishes was the most pronounced pathological effect on freshwater breams (Karanis & Taraschewski 1993). Protozoan parasites are pathogens threatening fish health and production (Molnár 2006). In addition, protozoan organisms such as *Cryptosporidium* and *Eimeria* are also regarded as fish-derived pathogens. *Cryptosporidium* is more significant because many species of *Cryptosporidium* are zoonotic pathogens. *Eimeria* infection can cause severe health risks to fish in the wild, especially to the fish production enterprise. Since protozoan and metazoan parasites can infest edible fish worldwide, the problem of human health risks due to wild fish ingestion is an important issue. Preventing and managing fish disease minimizes production losses and increases aquaculture productivity.

Cryptosporidium and *Eimeria* are genera of protozoan Apicomplexa (Eimeriorina) parasites. These genera infect a range of vertebrates, including domesticated animals and fish (Duszynski *et al.* 2003; Dubey 2019; Holubová *et al.* 2020; Golomazou *et al.* 2021; Ježková *et al.* 2021; Zahedi *et al.* 2021).

Fish coccidia were identified and described 110 years ago (Thelohan 1890). Since then, many new species have been reported. The number of coccidian species affecting fish species has increased; to date, about 280 species of Coccidia have been described as infecting fish species. For 250,000 fish species, Coccidia of three families (Calyptosporidae,

Cryptosporidiidae, Eimeriidae) and eight genera (*Calyptospora*, *Cryptosporidium*, *Crystallospora*, *Eimeria*, *Epieimeria*, *Goussia*, *Isospora*, *Octosporella*) have been seen in Actinopterygii (Pugachev *et al.* 2012).

Cryptosporidium species are protozoan parasites that infect the microvilli of the mucosal membranes of the gastrointestinal tract and respiratory tract of animals and humans. Waterborne infectious agents are a significant public health concern in developed and developing nations (Karanis *et al.* 2007; Baldursson & Karanis 2011; Efstratiou *et al.* 2017; Bourli *et al.* 2023). Most reported waterborne outbreaks (60%) are counted as *Cryptosporidium*.

Piscine hosts for *Cryptosporidium* have been increasingly reported from different countries in recent years, reaffirming the ubiquitous nature of this protozoan parasite, which has been detected in a large number of free-living, cultured and ornamental fish species worldwide from both marine and freshwater environments (Golomazou & Karanis 2020; Golomazou *et al.* 2021; Couso-Pérez *et al.* 2022). *Cryptosporidium* species have been reported in 23 freshwater and 24 marine fish species (Golomazou *et al.* 2021). The first piscine host of *Cryptosporidium* found was the tropical fish *Naso lituratus*, in which *Cryptosporidium nazorum* was identified (Hoover *et al.* 1981). After the first description, different histological studies reported developmental stages of *Cryptosporidium* in several fish species' stomachs and intestines (Couso-Pérez *et al.* 2022).

Currently, the following five species are recognized as specific to fish hosts: *C. molnari*, initially characterized in wild gilt-head seabream (*Sparus aurata*) and European seabass (*Dicentrarchus labrax*) (Álvarez-Pellitero & Sitjà-Bobadilla 2002); *C. scopthalmi*, which has been only characterized genetically in wild turbot (*Scophthalmus maximus*) (Álvarez-Pellitero *et al.* 2004); *C. huwii* from guppy (*Poecilia reticulata*), golden tiger barb (*Puntigrus tetrazona*) and neon tetra (*Paracheirodon innesi*) (Ryan *et al.* 2015; Yang *et al.* 2015; Papparini *et al.* 2017); *C. bollandi* from angelfish (*Pterophyllum scalare*) and Oscar fish (*Astronotus ocellatus*) (Bolland *et al.* 2020) and recently proposed *C. abrahamseni* n. sp. from red-eye tetras (*Moenkhauisia sanctaefilomenae*) (Zahedi *et al.* 2021). Several piscine genotypes have been reported by Golomazou *et al.* (2021) and by Couso-Pérez *et al.* (2022). *Cryptosporidium* species have also been reported: zoonotic *C. parvum*, anthroponotic *C. hominis*, *C. xiaoi*, *C. scrofarum* and rat genotype III (Golomazou *et al.* 2021). *C. ubiquitous* was detected in two European sea bass (Moratal *et al.* 2022).

In fish hosts, *Cryptosporidium* is found either in the stomach or intestine. In most cases of *Cryptosporidium* infection, no clinical signs of disease are observed. However, several authors have described clinical manifestations such as emaciation, atrophy of skeletal muscle, flattening of the abdomen, low growth rate, anorexia, listlessness, whitish faeces, abdominal swelling and ascites (Hoover *et al.* 1981; Gratzek 1993; Camus & López 1996; Muench & White 1997; Álvarez-Pellitero & Sitjà-Bobadilla 2002; Álvarez-Pellitero *et al.* 2004; Ryan *et al.* 2004; Murphy *et al.* 2009; Gabor *et al.* 2011; Nematollahi *et al.* 2016).

The *Eimeria* are ubiquitous parasites of the vertebrate gut epithelium, which complete their development in a single host species. *Eimeria* species are a group of protozoan parasites common in many fish farming systems (Duszynski *et al.* 2003; Pugachev *et al.* 2012).

Species of the genus *Eimeria* are the most widespread among vertebrates; there are currently more than 1,700 of them, and this pattern is preserved for fish. About 180 species of coccidia of the genus *Eimeria* have been found in fish (Pugachev *et al.* 2012). Due to the zoonotic character of the genus *Cryptosporidium*, fish infection with *Eimeria* species was not widely studied in the last period as a *Cryptosporidium*. Little information is available on the occurrence, impact and risks associated with the infection in fish populations.

Infections of the genus *Cryptosporidium* and *Eimeria* coccidian have been described in amphibians, reptiles, birds and mammals in Azerbaijan (Gaibova *et al.* 2017; Gaibova & Mamedova 2021; Mamedova & Karanis 2021). There is no information on *Cryptosporidium* infection in freshwater fish in the same territory. A few studies have been conducted on Eimerian fish infection in Azerbaijan (Mikhailov 1975; Seyidli 1992; Mamedova & Ibrahimov 2018). The present study aims to investigate the prevalence of fish *Cryptosporidium* and *Eimeria* infections in a different part of the Kura River basin in the Azerbaijan region.

MATERIAL AND METHODS

Study area

The study was conducted during the 2 years (2021–2022) in Azerbaijan at two points of river Kura: Mingachevir reservoir and where the river finally enters the Caspian Sea through a delta of the Neftchala district – Kura River estuary (Figure 1). The Mingachevir Reservoir is the largest in the Caucasus. It is located between the Greater Caucasus Mountains to the northeast

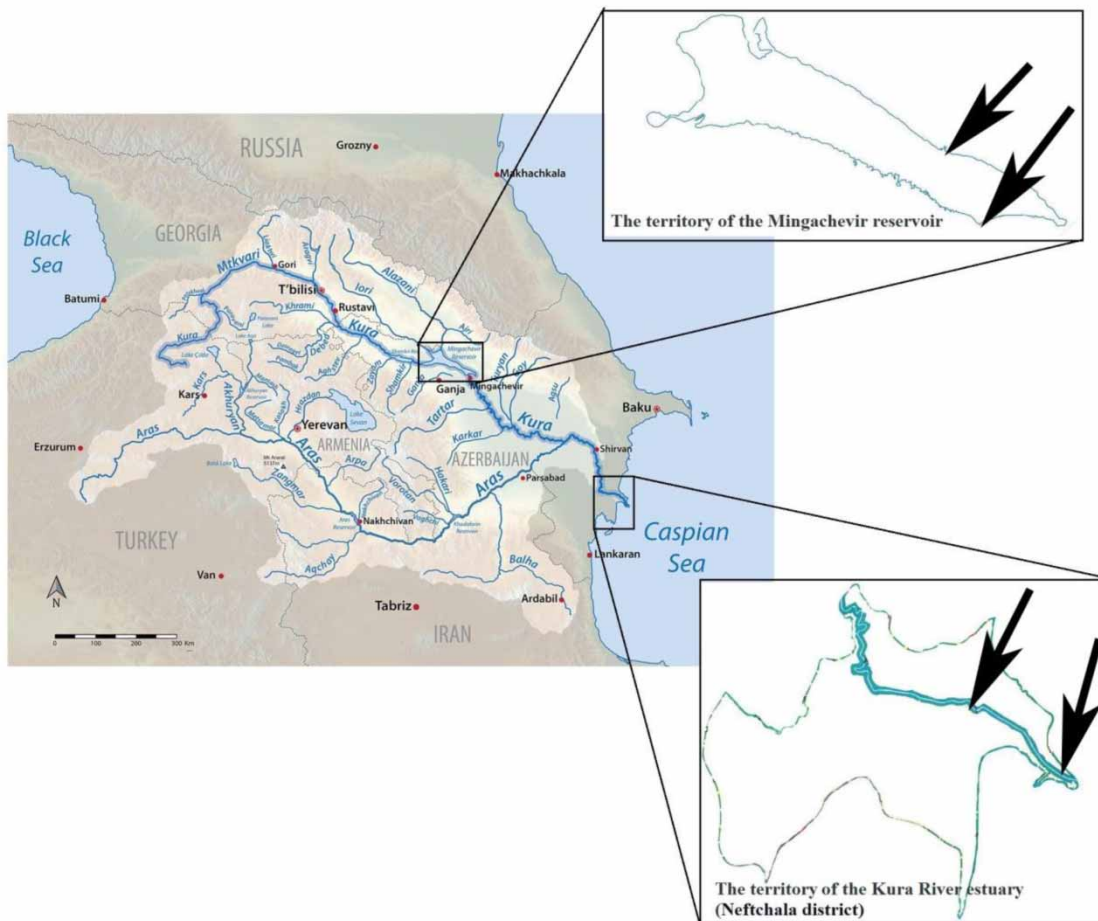


Figure 1 | The geographic location of the study area and sampling sites.

and the Lesser Caucasus Mountains to the southwest. This reservoir is a source for fishing. In the Kura River estuary, the Kura River enters the Caspian Sea by a delta in the Neftchala district in Azerbaijan.

The Kura is the largest transboundary river connecting the three countries in the South Caucasus. This river originates east of Turkey at an altitude of 2,200–2,700 m above sea level, flows through the eastern part of Georgia, crosses the border of Azerbaijan, enters the Mingachevir reservoir and into the Caspian Sea. The total length of the river is 1,515 km (941 miles). About 174 km of the river is in Turkey, 435 km is in Georgia and 906 km is in Azerbaijan. The catchment area in Azerbaijan and Georgia is 94,760 km². The water of the Kura River is formed seasonally from melting snow (36%), groundwater (30%), rains (20%), melting ice and snow in glaciers (14%) (Hasanov & Abbasov 2020).

Sample collection

During the present study, 170 fishes representing eight species in four families Cyprinidae, Mugilidae, Percidae and Gobiidae (Caspian roach (*Rutilus caspicus* Jakovlev, 1870) – 23, Kura bleak (*Alburnus filippi* Kessler, 1877) – 9, Freshwater bream (*Abramis brama orientalis* Berg, 1949) – 52, Common Carp (*Cyprinus carpio* Linnaeus, 1758) – 22, Silver Prussian carp (*Carassius gibelio* Bloch, 1782) – 46, European perch (*Persa fluviatilis* Linnaeus, 1758) – 8, Golden grey mullet (*Mugil cephalus* Linnaeus, 1758) – 8, Caspian bighead goby (*Ponticola gorlap* Iljin, 1949) – 2) were purchased directly on the shores of the water basin from local fishermen in Mingachevir (geographic coordinates: 40° 46' 29.9424" North, 47° 2' 12.6348" East) and Kura River estuary (geographic coordinates: 39° 22' 14.4048" North, 49° 19' 19.164" East) between August 2021 and September 2022 (Figure 2). All the species of fish are edible. No fish specimen included in the present work involved endangered or protected species. All collected fish were kept in a water reservoir until being then transported to the laboratory. The



Figure 2 | Some of the investigated fish species from the Kura River basin in Azerbaijan territory: (a) Silver Prussian carp (*Carassius gibelio* Bloch, 1782), (b) Freshwater bream (*Abramis brama orientalis* Berg, 1949), (c) Kura bleak (*Alburnus filippi* Kessler, 1877), (d) Common carp (*Cyprinus carpio* Linnaeus, 1758), European perch (*Persa fluviatilis* Linnaeus, 1758), (e) golden grey mullet (*Mugil cephalus* Linnaeus, 1758).

fish were transferred to the laboratory of Protozoology at the Institute of Zoology Ministry of Science and Education of the Republic of Azerbaijan for immediate investigation and analysis.

Sample processing and analysis

Fish species determination and total body length were recorded at the laboratory (Abdurahmanov 1962). Dissection was performed for each individual using sterile dissection material. Using a scalpel blade, each fish was cut on the ventral surface beginning from the operculum to the anal vent through. The contents (intestinal mucosa and faeces) of each gastrointestinal tract were carefully scraped and squeezed out.

Microscopic identification

The diagnosis of both parasites was performed microscopically. *Cryptosporidium* spp. oocysts have been identified in stool and intestinal mucosa smears stained by a modified Ziehl-Neelsen technique (Henriksen & Pohlenz 1981). Detected Eimerian oocysts were described micro morphometrically as the basis for traditional oocyst identification (Pellerdy 1974; Bauer 1984). The percentage of infected animals was calculated.

For *Cryptosporidium* oocysts scrapings of the intestinal mucosa and faeces were dropped on the slides, air-dried, fixed in absolute methanol and stained with carbol-fuchsin and methylene green by the Ziehl-Neelsen staining method (Henriksen & Pohlenz 1981). Oocysts (4–6 μm) often have distinct oocyst walls and stains from light pink to bright red. Any oocysts found were measured, length-to-width shape indices were calculated, and oocyst sizes were compared. The intensity of infection in the oocyst numbers was defined by calculating oocysts in faecal smears for 1,000 fields of vision (FV) at a magnification of $1,000\times$.

For *Eimeria* oocysts, impressions of faeces, mucous and intestinal scrapings samples were prepared from each fish on a glass slide with a coverslip and examined directly under a light microscope under $\times 20$ and $\times 40$ objectives lens and the presence of oocyst was recorded accordingly (Molnar 1977). Invasion intensiveness (II) with Eimerian oocysts was defined by

calculating oocysts in preparation for 400 FV at a magnification of 400×. Oocyst was identified according to the corresponding determinants of fish parasites (Bauer 1984).

RESULTS

The richest coccidian fauna is recorded from Cypriniformes in the four examined fish families. Only the cyprinid fish showed an infestation of *Cryptosporidium* spp. and *Eimeria* spp. Results revealed a lower prevalence of *Cryptosporidium* infection (15) (8.8%) than *Eimeria* infection (35) (20.6%) in fish hosts (Table 1).

As a result, we identified oocysts of *Cryptosporidium* spp. in samples from 15 of 170 freshwater fish (8.8%) by the Ziehl-Neelsen staining method. *Cryptosporidium* spp. were detected in the following 3 fish species: 2 Caspian roaches (*Rutilus caspicus*) – (2/13 (15.4%)), 10 Freshwater bream (*Abramis brama orientalis*) – (10/50 (20%)) and three Silver Prussian carp (*Carassius gibelio*) – (3/44 (6.8%)) (Table 1).

The *Cryptosporidium* spp. oocysts were characterized by a spherical to oval form with a smooth wall, an incomplete suture line of the oocyst wall and an acid-fast (red-pink) appearance on the greenback. The diameter of the oocysts ranged from 3.12–4.52 × 3.34–5.01 μm and had a shape index of 1.1–1.2 (Figure 3(a) and 3(b)). The intensity of infection in the oocyst numbers was significantly lower, with 1–2 oocysts in 1,000 fields.

Of all 170 examined fish, 35 (20.6%) were infected with *Eimeria* oocysts. Three fish species were infected with *Eimeria* oocysts: Caspian roaches (*Rutilus caspicus*) – 2/13 (15.4%), Kura bleak (*Alburnus filippi*) – 5/9 (55.6%) and Freshwater bream (*Abramis brama orientalis*) – 28/50 (56%) (Table 1).

Table 1 | Prevalence of *Cryptosporidium* spp. and *Eimeria* spp. for each species of fish from the Kura river basin in Azerbaijan territory

N	Common name	Species name	Geographic location	Mean fish size (cm)	Number of sampled fish specimens	<i>Cryptosporidium</i> -positive fish number (%)	<i>Eimeria</i> -positive fish number (%)
1	Caspian roach	<i>Rutilus caspicus</i> Jakovlev, 1870	Mingachevir reservoir	12.15 ± 2.6	13	2 (15.4)	2 (15.4)
			The territory of the Kura River estuary	18.55 ± 4.4	10	0	0
2	Kura bleak	<i>Alburnus filippi</i> Kessler, 1877	Mingachevir reservoir	14.35 ± 3.2	9	0	5 (55.6)
3	Freshwater bream	<i>Abramis brama orientalis</i> Berg, 1949	Mingachevir reservoir	12.65 ± 5.2	50	10 (20)	28 (56%)
			The territory of the Kura River estuary	20.85 ± 6.3	2	0	0
4	Common Carp	<i>Cyprinus carpio</i> Linnaeus, 1758	Mingachevir reservoir	41.25 ± 6.6	4	0	0
			The territory of the Kura River estuary	22.45 ± 5.5	18	0	0
5	Silver Prussian carp	<i>Carassius gibelio</i> Bloch, 1782	Mingachevir reservoir	15.15 ± 1.5	44	3 (6.8)	0
			The territory of the Kura River estuary	19.35 ± 3.2	2	0	0
6	European Perch	<i>Persa fluviatilis</i> Linnaeus, 1758	Mingachevir reservoir	48.25 ± 4.8	8	0	0
7	Golden grey mullet	<i>Mugil cephalus</i> Linnaeus, 1758	The territory of the Kura River estuary	13.35 ± 3.1	8	0	0
8	Caspian bighead goby	<i>Ponticola gorlap</i> Iljin, 1949	The territory of the Kura River estuary	42.25 ± 5.6	2	0	0
Total:					170	15 (8.8%)	35 (20.6%)

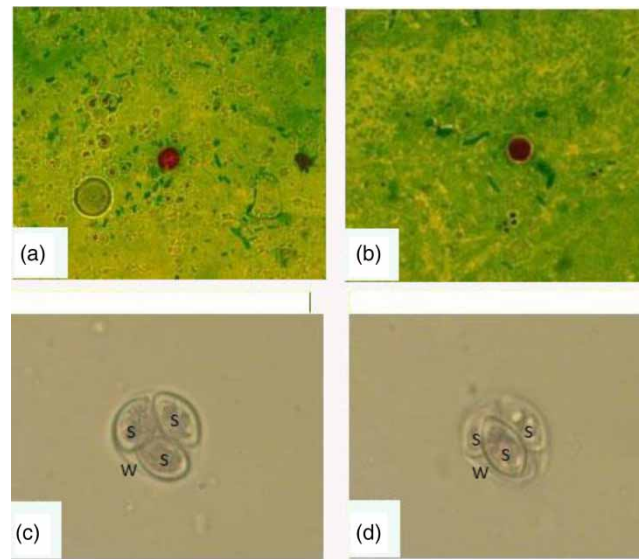


Figure 3 | (a, b) *Cryptosporidium* spp. oocysts (stained with modified Ziehl-Neelsen stain (mZN)) from *Abramis brama* intestinal contents (intestinal mucosa and faeces) coughed in the Mingachevir reservoir ($\times 100$). (c, d) *Eimeria carpelli* oocysts with four sporozoites inside. Three sporozoites (S) are visible. The material is from faeces, mucous and intestinal scrapings of *Abramis brama*. The specimens were coughed in the Mingachevir reservoir, S – sporozoites, W – wall of the oocyst ($\times 100$).

The oocysts of *Eimeria* were round, with a diameter of 12 to 14 μm and fragile walls. The micropyle, polar granule and oocyst residuum are absent. The sporocysts are ovoid bodies, 7.5 by 4.5 μm . The sporocysts also have thin walls (Figure 3(c) and 3(d)). The intensity of infection in the oocyst numbers was 2–3 oocysts in 400 fields.

Infected fish with *Cryptosporidium* and *Eimeria* oocysts were coughed in the Mingachevir reservoir. Among the fish we studied, most parasitic protozoal infections were found with *Abramis brama*. There were no *Cryptosporidium* and *Eimeria* infections in fish caught from the territory of the Kura River estuary (Table 1).

The prevalence of *Cryptosporidium* and *Eimeria* infections was higher in young specimens compared to in adults. Positive samples were found in smaller fish in size 12–15 cm. The prevalence for each host species is recorded in Table 1.

The infection rate for *Cryptosporidium* and *Eimeria* species was slightly greater in females than in males. *Cryptosporidium* spp. infections in females and males were detected in 16.9 and 3.7%, respectively. The results show that 37.7% of the females and 11.3% of the male fish were infected with *Eimeria* spp. oocysts (Table 2).

DISCUSSION

The identification of *Cryptosporidium* and *Eimeria* species has important implications for diagnosis and control as well as for epidemiology. Coccidian oocysts in the fish could be a bioindicator of animal and human faecal contamination of ponds, lakes and other water bodies or from wastewater.

Table 2 | The number of investigated and infected fish specimens with *Cryptosporidium* spp. and *Eimeria* spp. related to different sex groups of fish species from the Kura river basin in Azerbaijan territory

Species name	Number of sampled fish specimens	<i>Cryptosporidium</i> -positive fish positive/examined (%)		<i>Eimeria</i> -positive fish positive/examined (%)	
		Female	Male	Female	Male
<i>Rutilus caspicus</i>	23	2/14 (14.3)	0/9	2/14 (14.3)	0/9
<i>Alburnus filippi</i>	9	0/4	0/5	3/4 (75)	2/5 (40)
<i>Abramis brama orientalis</i>	52	9/31 (29)	1/21 (4.8)	24/31 (77.4)	4/21 (19)
<i>Carassius gibelio</i>	46	2/28 (7.1)	1/18 (5.6)	0/28	0/18
Total:	130	13/77 (16.9)	2/53 (3.7)	29/77 (37.7)	6/53 (11.3)

Detection methods for *Cryptosporidium*

Cryptosporidium infection can be detected in several ways. Immunofluorescence microscopy is the method of choice for the most outstanding sensitivity and specificity (followed closely by enzyme immunoassays). PCR is a more sensitive and more accessible method for interpreting *Cryptosporidium* species identification but requires more hands-on time to perform and is more expensive than microscopy. In the present investigations *Cryptosporidium* spp. identification was based on conventional morphometric criteria, such as oocyst morphology and measurements. The criteria agree with those applied by Fayer *et al.* (2000) and Ryan *et al.* (2002), who stated that morphometric measurement of oocysts represents the cornerstone of *Cryptosporidium* taxonomy and is one of the requirements for establishing a new species. Standard practice is the microscopy of faecal samples, which can be mounted on slides directly or after flotation/sedimentation. Staining methods are available to detect and identify the oocysts of *Cryptosporidium* species directly from stool samples. Modified Ziehl-Neelsen stain, traditionally used to most reliably and precisely detect the presence of *Cryptosporidium* oocysts, where oocysts appear purple on a blue background, is commonly used. After staining with modified Ziehl-Neelsen, the morphological appearance of detected *Cryptosporidium* oocysts obtained from fish in our study was a bright red, spherical, smooth wall, oocysts with an incomplete suture line, and with a size of $3.12\text{--}4.52 \times 3.34\text{--}5.01 \mu\text{m}$. The sizes of all five species of *Cryptosporidium* oocysts are not very different from each other (Álvarez-Pellitero & Sitjà-Bobadilla 2002; Álvarez-Pellitero *et al.* 2004; Ryan *et al.* 2015; Bolland *et al.* 2020; Zahedi *et al.* 2021). Therefore, molecular analyses are recommended for differentiation of *Cryptosporidium* species.

Eimeria species

Eimeria are the most widely species found among vertebrates. More than 180 *Eimeria* species have been reported in fish species (Pugachev *et al.* 2012). In Azerbaijan, only a few studies have been performed on fish coccidian infection (Mikhailov 1975; Seyidli 1992). Most Eimeriidae are species (or at least genus) specific and have similar life cycles. Traditionally, species of *Eimeria* have been identified by morphometry and morphological features of the sporulated oocysts and the specific host from which they originate. *Eimeria* species identification was conducted under a microscope based on oocyst morphology (size and shape) as previously reported (Pellerdy 1974; Pugachev *et al.* 2012; Berto *et al.* 2014). In the present investigations, oocysts were morphologically similar to *Eimeria carpelli* (Léger et Stankovitch 1921) – which are widespread species of fish (Bauer 1984; Duszynski *et al.* 2003). According to Pellerdy (1974), *E. carpelli* is the species primarily responsible for intestinal coccidiosis in fish. It occurs in adult carp specimens and it widely known in all countries with fish culture. Soviet authors regard it as a species of particularly great importance (Pellerdy 1974). *E. carpelli* is the major pathogenic agent for carp, which is the cause of coccidial enteritis (Molnár 2006). *E. carpelli* was identified as one of the species of Cypriniformes (Bauer 1984; Duszynski *et al.* 2003). Previously, *E. carpelli* was reported in Azerbaijan from the Mingachevir reservoir (Mikhailov 1975) and Kura River estuary (Mamedova & Ibrahimov 2018).

Distribution of the investigated protozoa

The lower prevalence of *Cryptosporidium* and *Eimeria* infection identified in the present study could have been explained by the age of the fish hosts. As noted in the result, a higher prevalence of *Cryptosporidium* spp. and *Eimeria* spp. was observed in younger fish. A higher prevalence could be expected in younger individuals. Most of the studied fish in the present study were adults. Fishes close to commercial size are more relevant for public health.

Female specimens had a higher prevalence compared to males. This could be due to the enormous spawning stress and osmoregulatory changes, making female specimens more susceptible to the infection.

One of the main goals of the present study was to evaluate the prevalence of *Cryptosporidium* and *Eimeria* species in fish species sampled in defined marine geographic areas surrounding the river Kura in Azerbaijan. Considering that many factors related to the host and the environment can influence host–parasite relationships (Sitjà-Bobadilla *et al.* 2005), we also aimed to determine the influence of host and environmental factors on *Cryptosporidium* and *Eimeria* prevalence in fish.

Fish diseases and aquaculture

Fish diseases are more frequent in aquaculture than in wild fisheries, where outbreaks are rare. An infectious agent may not spread quickly and easily in the oceans or seas, where waters are sparsely populated. Aquaculture populations are reared close at high densities, enabling pathogens to spread rapidly and efficiently (Fish Disease Under the Microscope 2016, World Fish <https://www.worldfishcenter.org/pages/fish-disease/>).

Fish are sensitive to changes in their environment and aquaculture systems; they are under more stress than in the wild. Stress factors include low oxygen levels, temperature changes, poor water quality and salinity fluctuations. When a fish is stressed, the effectiveness of its immune system is reduced, making it more susceptible to disease (Fish Disease Under the Microscope 2016, World Fish <https://www.worldfishcenter.org/pages/fish-disease/>).

Influence of environmental and anthropogenic factors

Climate and human interferences cause substantial river flow variability. As a result of human activities, water quality has also dropped significantly. Daily, large amounts of pollutants are discharged directly or indirectly into rivers and other water bodies. There are similar problems with water resources in the Kura River basin. The Kura River is the main water artery of our republic, and even before it enters the territory of Azerbaijan, it is subject to heavy pollution in neighbouring countries (Hasanov & Abbasov 2020). In the summer months, the thin blue-green coating covering the water surface in the Mingachevir reservoir proves the worsening of the ecological conditions in the entire Kura River. *Cryptosporidium* occurs worldwide, but infections are especially prevalent with poor water quality and sanitation. In this study, the prevalence of *Cryptosporidium* and *Eimeria* infection in fish in the Mingachevir reservoir is most likely based on the pollution of the river.

Water salinity is one of the major environmental factors influencing hydration. The water of the Caspian Sea is slightly saline (13‰), compared to the Caspian water with oceanic water, which contains three times less salt (Plotnikov & Aladin 2011). The water of the Kura Delta has been mixed with the Caspian Sea due to the recent decrease in the water level. This mixture has reached the Khilli settlement, about 15 km from the delta of Kura, located near Neftchala city. For this reason, the water of the Kura is so salty that not only the people but also cattle cannot drink it. Some studies suggest that *Cryptosporidium* oocysts can survive in seawater long (Fayer *et al.* 1998; Tamburrini & Pozio 1999). Another study indicated that *Cryptosporidium* infection occurs more frequently in freshwater than in marine fish (Reid *et al.* 2008; Certad *et al.* 2019; Reghaissia *et al.* 2022). In the present study, *Cryptosporidium* and *Eimeria* were not detected in fish sampled from the Kura River estuary. The water salinity could explain the absence of *Cryptosporidium* and *Eimeria* infections in fish in the water of the Kura River estuary.

The Caspian Sea region is one of the oldest oil-producing areas in the world. The ecology of the Caspian Sea is being endangered due to several issues, such as petroleum extraction. One of the problems with petroleum operations is the impact of drilling fluid and significant water pollution. Land degradation, water problems and pollution occur in Azerbaijan due to oil production and industrial activity. About 30,000 hectares of land on the Absheron Peninsula of Azerbaijan is polluted by oil products and various industrial wastes (Efendiyeva 2000).

Some studies have shown that essential oils and numerous chemical disinfectants could be promising antiprotozoal agents, opening perspectives to discovering more effective drugs for treating diseases caused by protozoa (Fayer 2008). Water can be contaminated by oil and gas oxidation products such as glutaraldehyde and hydrogen peroxide. Glutaraldehyde was the most effective in halting excystation of sporozoites and infection in cell monolayers (Wilson & Margolin 1999). Hydrogen peroxide was described as an effective disinfectant against *C. parvum* oocysts (Barbee *et al.* 1999; Dellling *et al.* 2016). The absence of *Cryptosporidium* and *Eimeria* infections in fish caught from the territory of the Kura River estuary could have been explained by the contamination of the water with petroleum and oil products.

The absence of *Cryptosporidium* and *Eimeria* infections in fish caught from the territory of the Kura River estuary in the present study may have been due to the age of the fish that were sampled (all were adult), water salinity, and the contamination of the water with petroleum and oil. All these results need comprehensive studies. Future studies should consider the possibility of sampling throughout the year to determine whether seasonality may influence prevalence. Moreover, it is necessary to detect more isolates and to perform molecular and morphological studies.

CONCLUSIONS

The present study reported the prevalence of *Cryptosporidium* and *Eimeria* in freshwater fish in River Kura in Azerbaijan's territory. This report is the first regarding the prevalence of *Cryptosporidium* oocysts in fish in the study area. Based on the morphometric criteria of the isolated oocysts, only one *E. carpelli* was identified in the study territory. Future studies on piscine *Eimeria* and *Cryptosporidium* should include molecular and ultrastructural characterizations.

Given the importance of the fish as a source of income for people living in the area and a natural heritage of the country as negative impacts of the parasite on fish and human health, detailed studies with a focus on zoonotic, epidemiological, control and treatment aspects of the parasites species of freshwater fish are imperative.

AUTHOR CONTRIBUTIONS

Both authors contributed to the conception of the study. S. M. rendered support in material collection, laboratory work, formal investigation, data analysis, and drafting the manuscript. P. K. conceptualized the whole article, developed the methodology, validated the data, wrote the review and edited it, and supervised the whole process. Both authors have read and approved the final manuscript.

FUNDING

This research received no specific grant from public, commercial, or not-for-profit funding agencies.

DATA AVAILABILITY STATEMENT

All relevant data are included in the paper or its Supplementary Information.

CONFLICT OF INTEREST

The authors declare there is no conflict.

REFERENCES

- Abdurahmanov, Y. A. 1962 *Рыбы пресных вод Азербайджана. (Freshwater Fish of Azerbaijan)*. National Academy of Sciences, Baku, 405 p.
- Álvarez-Pellitero, P. & Sitjà-Bobadilla, A. 2002 *Cryptosporidium molnari* n. sp. (Apicomplexa: Cryptosporidiidae) infecting two marine fish species, *Sparus aurata* L. and *Dicentrarchus labrax* L. *Int. J. Parasitol.* **32**, 1007–1021. doi:10.1016/s0020-7519(02)00058-9.
- Álvarez-Pellitero, P., Quiroga, M. I., Sitjà-Bobadilla, A., Redondo, M. J., Palenzuela, O., Padrós, F., Vázquez, S. & Nieto, J. M. 2004 *Cryptosporidium scophthalmi* n. sp. (Apicomplexa: Cryptosporidiidae) from cultured turbot *Scophthalmus maximus*. Light and electron microscope description and histopathological study. *Dis. Aquat. Org.* **62**, 133–145. doi:10.3354/dao062133.
- Baldursson, S. & Karanis, P. 2011 Waterborne transmission of protozoan parasites: A review of worldwide outbreaks – an update 2004–2010. *Wat. Res.* **45** (20), 6603–6614. doi:10.1016/j.watres.2011.10.013.
- Barbee, S. L., Weber, D. J., Sobsey, M. D. & Rutala, W. A. 1999 Inactivation of *Cryptosporidium parvum* oocyst infectivity by disinfection and sterilization processes. *Gastrointest Endosc.* **49** (5), 605–611. doi:10.1016/s0016-5107(99)70389-5.
- Bauer, O. N. 1984 *Определитель паразитов пресноводных рыб фауны СССР (Key to Parasites of Freshwater Fishes of the Fauna of the USSR)*. Part I – *Izdat. Nauka, Leningrad*, 428 p.
- Berto, B. P., McIntosh, D. & Lopes, C. W. G. 2014 Studies on coccidian oocysts (Apicomplexa: Eucoccidiorida). *Rev. Bras. Parasitol. Vet.* **23** (1), 1–15. <http://dx.doi.org/10.1590/S1984-29612014001>.
- Bolland, S., Zahedi, A., Oskam, C., Murphy, B. & Ryan, U. 2020 *Cryptosporidium bollandi* n. sp. (Apicomplexa: Cryptosporidiidae) from angelfish (*Pterophyllum scalare*) and Oscar fish (*Astronotus ocellatus*). *Exp. Parasitol.* **217**, 107956. <https://doi.org/10.1016/j.exppara.2020.107956>.
- Bourli, P., Eslahi, A. V., Tzoraki, O. & Karanis, P. 2023 Waterborne transmission of protozoan parasites: A review of worldwide outbreaks – an update 2017–2022. *J. Water Health* **21** (10), 1421–1447. doi:10.2166/wh.2023.094.
- Camus, A. C. & López, M. K. 1996 Gastric cryptosporidiosis in the juvenile red drum. *J. Aquat. Anim. Health* **8**, 167–172. doi:10.1577/1548-8667(1996)008 < 0167:GCIJRD > 2.3.CO;2.
- Cavin, L. 2017 *Freshwater Fishes: 250 Million Years of Evolutionary History*. ISTE Press Ltd, London.
- Certad, G., Follet, J., Gantois, N., Hammouma-Ghelboun, O., Guyot, K., Benamrouz-Vanneste, S., Fréalle, E., Seesao, Y., Delaire, B., Creusy, C., Even, G., Verrez-Bagnis, V., Ryan, U., Gay, M., Aliouat-Denis, C. & Viscogliosi, E. 2019 Prevalence, molecular identification, and risk factors for *cryptosporidium* infection in edible marine fish: A survey across sea areas surrounding France. *Front. Microbiol.* **10**, 1037. doi:10.3389/fmicb.2019.01037.
- Couso-Pérez, S., Ares-Mazás, E. & Gómez-Couso, H. 2022 A review of the current status of *Cryptosporidium* in fish. *Parasitology* **149**, 444–456. doi:10.1017/S0031182022000099.
- Delling, C., Holzhausen, I., Dausgies, A. & Lendner, M. 2016 Inactivation of *Cryptosporidium parvum* under laboratory conditions. *Parasitology* **115** (2), 863–866. doi:10.1007/s00436-015-4813-4.
- Dubey, J. P. 2019 *Coccidiosis in Livestock, Poultry, Companion Animals, and Humans*, 1st edn. CRC Press, Boca Raton, FL. <https://doi.org/10.1201/9780429294105>.
- Duszynski, D., Lee, C. & Upton, S. 2003 Coccidia (Eimeriidae) of Cypriniformes (cyprinids). <https://www.k-state.edu/parasitology/worldcoccidia/CYPRINIFORMES> (accessed 1 July 2023).
- Efendiyeva, I. M. 2000 Ecological problems of oil exploitation in the Caspian Sea area. *J. Pet. Sci. Eng.* **28** (4), 227–231. [https://doi.org/10.1016/S0920-4105\(00\)00081-4](https://doi.org/10.1016/S0920-4105(00)00081-4).
- Efstratiou, A., Ongerth, J. & Karanis, P. 2017 Evolution of monitoring for *Giardia* and *Cryptosporidium* in water. *Wat. Res.* **123**, 96–112. doi:10.1016/j.watres.2017.06.042.

- FAO. (Food and Agriculture Organization of the United Nations). 2020 *The State of World Fisheries and Aquaculture*. In: *Sustainability in Action; The State of the World Series* (D'Aiotti, L., Dias, P., Federighi, G., McMenomy, T., Mulligan, F., Skot, J. & Vaz, S., eds). FAO, Rome, Italy, pp. 1–73.
- Fayer, R., 2008 General biology. In: *Cryptosporidium and Cryptosporidiosis*, 2nd edn. (Fayer, R. & Xiao, L., eds). CRC Press, Boca Raton, pp. 1–42.
- Fayer, R., Graczyk, T. K., Lewis, E. J., Trout, J. M. & Farley, C. A. 1998 Survival of infectious *Cryptosporidium parvum* oocysts in seawater and eastern oysters (*Crassostrea virginica*) in the Chesapeake Bay. *Appl. Environ. Microbiol.* **64** (3), 1070–1074. doi:10.1128/AEM.64.3.1070-1074.1998.
- Fayer, R., Morgan, U. & Upton, S. 2000 Epidemiology of *Cryptosporidium*: Transmission, detection and identification. *Int. J. Parasitol.* **30** (12–13), 1305–1322. doi:10.1016/s0020-7519(00)00135-1.
- Fish Disease Under the Microscope. 2016 World Fish <https://www.worldfishcenter.org/pages/fish-disease/> (accessed 19 July 2023).
- Gabor, L. J., Srivastava, M., Titmarsh, J., Dennis, M., Gabor, M. & Landos, M. 2011 Cryptosporidiosis in intensively reared barramundi (*Lates calcarifer*). *J. Vet. Diagn. Invest.* **23**, 383–386. doi:10.1177/104063871102300235.
- Gaibova, H. D. & Mamedova, S. O. 2021 Антропогенное влияние на формирование кишечной кокцидии (Sporozoa, Apicomplexa) у рептилий Азербайджана (Anthropogenic influence on the formation of intestinal Coccidia (Sporozoa, Apicomplexa) in reptiles of Azerbaijan). *Am. Zool. J.* **13** (3), 353–368. doi:10.33910/2686-9519-2021-13-3-353-368.
- Gaibova, H., Iskenderova, N. & Gurbanova, T. 2017 Review of the modern state of the emerald coccidians of terrestrial vertebrates of Azerbaijan. In *Proceedings XIX International Scientific Conference with Elements of the Scientific School of Young Scientists 'Biological Diversity Caucasus and South Russia*, 4–7 November, Makhachkala, pp. 423–425.
- Golomazou, E. & Karanis, P. 2020 *Cryptosporidium* species in fish: An update. *Environ. Sci. Proc.* **2** (1), 13. doi:10.3390/envirosciproc2020002013.
- Golomazou, E., Malandrakis, E. E., Panagiotaki, P. & Karanis, P. 2021 *Cryptosporidium* in fish: Implications for aquaculture and beyond. *Water Res.* **201**, 117357. <https://doi.org/10.1016/j.watres.2021.117357>.
- Gratzek, J. B., 1993 Parasites associated with freshwater tropical fishes. In: *Fish Medicine* (Stoskopf, M. K. ed.). W.B. Saunders, Philadelphia, pp. 576–577.
- Hasanov, S. & Abbasov, R. 2020 Kura River. 'Too healthy life' Ecological Public Union. Ecological portal. <https://www.ecolifeinfo.az/en/kura-river/> (accessed 19 July 2023).
- Henriksen, S. & Pohlenz, J. 1981 Staining of cryptosporidia by a modified Ziehl-Neelsen technique. *Acta Vet. Scand.* **22** (3–4), 594–596.
- Holubová, N., Tůmová, L., Sak, B., Hejzlarová, A., Konečný, R., McEvoy, J. & Kváč, M. 2020 Description of *Cryptosporidium ornithophilus* n. sp. (Apicomplexa: Cryptosporidiidae) in farmed ostriches. *Parasit. Vectors* **13**, 340. doi:10.1186/s13071-020-04191-2.
- Hoover, D. M., Hoerr, F. J., Carlton, W. W., Hinsman, E. J. & Ferguson, H. W. 1981 Enteric cryptosporidiosis in a naso tang, *Naso lituratus*, Bloch and Schneider. *J. Fish. Dis.* **4**, 425–428. doi:10.1111/j.1365-2761.1981.tb01152.x.
- Ježková, J., Limpouchová, Z., Prediger, J., Holubová, N., Sak, B., Konečný, R., Květoňová, D., Hlásková, L., Rost, M., McEvoy, J., Rajský, D., Feng, Y. & Kváč, M. 2021 *Cryptosporidium myocastoris* n. sp. (Apicomplexa: Cryptosporidiidae), a species adapted to the nutria (*Myocastor coypus*). *Microorganisms* **9**, 813. doi:10.3390/microorganisms9040813.
- Karanis, P. & Taraschewski, H. 1993 Host parasite interface of *Caryophyllaeus laticeps* (Eucestoda, Caryophyllidae) in three species of fish. *J. Fish. Dis.* **16**, 371–379. doi:10.1111/j.1365-2761.1993.tb00870.x.
- Karanis, P., Kourenti, C. & Smith, H. 2007 Waterborne transmission of protozoan parasites: A worldwide review of outbreaks and lessons learnt. *J. Wat. Health* **5**, 1–38. doi:10.2166/wh.2006.002.
- Mamedova, S. & Ibrahimov, S. 2018 Parasitic protozoans of commercial fishes of the Kura River estuary. *J. V. N. Karazin Kharkiv Natl Univ. Ser. Biol.* **31**, 99–106. doi:10.26565/2075-5457-2018-31-9.
- Mamedova, S. & Karanis, P. 2021 *Cryptosporidium* spp. infections in livestock and wild animals in Azerbaijan territory. *J. Water Health* **19** (4), 545–562. Doi:10.2166/wh.2021.050.
- Mikhailov, T. K. 1975 Паразиты рыб водных объектов Азербайджана (систематика, динамика и происхождение) (*Parasites of Fish of Water Bodies of Azerbaijan (Systematics, Dynamics and Origin)*). Elm, Baku. 299 p.
- Molnar, K. 1977 Comments on the nature and methods of collection of fish coccidia. *Parasitol. Hung.* **10**, 41–45. http://publication.nhmu.hu/pdf/parhung/Parasit_Hung_1977_Vol_10_41.pdf.
- Molnár, K., 2006 Phylum Apicomplexa. In: *Fish Diseases and Disorders: Protozoan and Metazoan Infections* (Woo, P. T. K., ed.). CABI Publishing, Cambridge, pp. 183–204.
- Moratal, S., Dea-Ayuela, M. A., Martí-Marco, A., Puigcercós, S., Marco-Hirs, N. M., Doménech, C., Corcuera, E., Cardells, J., Lizana, V. & López-Ramon, J. 2022 Molecular characterization of *Cryptosporidium* spp. in cultivated and wild marine fishes from Western Mediterranean with the first detection of zoonotic *Cryptosporidium ubiquitum*. *Animals* **12**, 1052. <https://doi.org/10.3390/ani12091052>.
- Muench, T. R. & White, M. R. 1997 Cryptosporidiosis in a tropical freshwater catfish (*Plecostomus* spp.). *J. Vet. Diagn. Invest.* **9**, 87–90. doi:10.1177/104063879700900118.
- Murphy, B. G., Bradway, D., Walsh, T., Sanders, G. E. & Snekvik, K. 2009 Gastric cryptosporidiosis in freshwater angelfish (*Pterophyllum scalare*). *J. Vet. Diagn. Invest.* **21**, 722–727. doi:10.1177/104063870902100523.

- Nematollahi, A., Jaber, S., Ashrafi Helan, J. & Sheikhzadeh, N. 2016 Histopathological study on parasites in freshwater ornamental fishes in Iran. *J. Parasit. Dis.* **40**, 756–759. doi:10.1007/s12639-014-0573-9.
- Paparini, A., Yang, R., Chen, L., Tong, K., Gibson-Kueh, S., Lymbery, A. & Ryan, U. M. 2017 *Cryptosporidium* in fish: Alternative sequencing approaches and analyses at multiple loci to resolve mixed infections. *Parasitology* **144**, 1811–1820. doi:10.1017/S0031182017001214.
- Pellerdy, L. P. 1974 *Coccidia and Coccidiosis*, 2nd edn. Verlag Paul Parey, Berlin, 959 p.
- Plotnikov, I. S. & Aladin, N. V. 2011 An overview of hybrid marine and lacustrine seas and saline lakes of the world. *Lakes Reserv.: Res. Manag.* **16**, 97–108. https://doi.org/10.1111/j.1440-1770.2011.00452.x.
- Pugachev, O. N., Krilov, M. V. & Belova, L. M. 2012 *Кокцидии отряда Eimeriida рыб России и сопредельных территорий (Fish Coccidia of the Order Eimeriida of Russia and Adjacent Territories)*. RAS Zoological Institute, St.-Petersburg, 101 p.
- Reghaissia, N., Maxamhud, S., Laatamna, A., Dahmane, A., Berima, R., Abdelli, A., Hakem, A., Baroudi, D. & Tsaousis, A. 2022 First epidemiological report on the prevalence and associated risk factors of *Cryptosporidium* spp. in farmed marine and wild freshwater fish in Central and Eastern Algeria. *Acta Parasit.* **67**, 1152–1161. https://doi.org/10.1007/s11686-022-00560-2.
- Reid, A., Lymbery, A., Ng-Hublin, J., Tweedle, S. & Ryan, U. 2008 Identification of novel and zoonotic *Cryptosporidium* species in marine fish. *Vet. Parasitol.* **168** (3–4), 190–195. Doi:10.1016/j.vetpar.2009.11.015.
- Ryan, U., Fall, A., Ward, L., Hijjawi, N., Sulaiman, I., Fayer, R., Thompson, R., Olson, M., Lal, A. & Xiao, L. 2002 *Cryptosporidium hominis* n. sp. (Apicomplexa: Cryptosporidiidae) from *Homo sapiens*. *J Eukaryot. Microbiol.* **49** (6), 433–440. doi:10.1111/j.1550-7408.2002.tb00224.x.
- Ryan, U., O'Hara, A. & Xiao, L. 2004 Molecular and biological characterization of a *Cryptosporidium molnari*-like isolate from a guppy (*Poecilia reticulata*). *Appl. Environ. Microbiol.* **70** (6), 3761–3765. doi:10.1128/AEM.70.6.3761-3765.2004.
- Ryan, U., Paparini, A., Tong, K., Yang, R., Gibson-Kueh, S., O'hara, A., Lymbery, A. & Xiao, L. 2015 *Cryptosporidium huwui* n. sp. (Apicomplexa: Eimeriidae) from the guppy (*Poecilia reticulata*). *Exp. Parasitol.* **150**, 31–35. doi:10.1016/j.exppara.2015.01.009.
- Seyidli, Y. M. 1992 Фауна рыб-паразитов Большого Кызылагачского залива Каспийского моря (Fish Parasite Fauna of the Big Kyzylagach Bay of the Caspian Sea). PhD thesis in biology dis./ – Baku, 1992. – 188 s.
- Sitjā-Bobadilla, A., Padrós, F., Aguilera, C. & Alvarez-Pellitero, P. 2005 Epidemiology of *Cryptosporidium molnari* in Spanish gilthead sea bream (*Sparus aurata* L.) and European sea bass (*Dicentrarchus labrax* L.) cultures: From hatchery to market size. *Appl. Environ. Microbiol.* **71**, 131–139. doi:10.1128/AEM.71.1.131-139.2005.
- Tamburrini, A. & Pozio, E. 1999 Long-term survival of *Cryptosporidium parvum* oocysts in seawater and in experimentally infected mussels (*Mytilus alloprovincialis*). *Int. J. Parasitol.* **29** (5), 711–715. https://doi.org/10.1016/S0020-7519(99)00033-8.
- Thelohan, P. 1890 Sur deux coccidies nouvelles, parasites de l'épinoche et de la sardine (on two new coccidia, parasites of stickleback and sardine). *C. R. Soc. Biol.* **42**, 345–348.
- Wilson, J. A. & Margolin, A. B. 1999 The efficacy of three common hospital liquid germicides to inactivate *Cryptosporidium parvum* oocysts. *J. Hosp. Infect.* **42** (3), 231–237. doi:10.1053/jhin.1999.0553.
- Yang, R., Palermo, C., Chen, L., Edwards, A., Paparini, A., Tong, K., Gibson-Kueh, S., Lymbery, A. & Ryan, U. 2015 Genetic diversity of *Cryptosporidium* in fish at the 18S and actin loci and high levels of mixed infections. *Vet. Parasitol.* **214**, 255–263. doi.org/10.1016/j.vetpar.2015.10.013.
- Zahedi, A., Bolland, S. J., Oskam, C. L. & Ryan, U. 2021 *Cryptosporidium abrahamseni* n. sp. (Apicomplexa: Cryptosporidiidae) from red-eye tetra (*Moenkhausia sanctaefilomenae*). *Exp. Parasitol.* **223**, 108089. doi:10.1016/j.exppara.2021.108089.

First received 13 January 2024; accepted in revised form 15 March 2024. Available online 26 March 2024