

ORIGINAL ARTICLE

Image guided navigation system—a new technology for complex endoscopic endonasal surgery

R Eliashar, J-Y Sichel, M Gross, E Hocwald, I Dano, A Biron, A Ben-Yaacov, A Goldfarb, J Elidan

Postgrad Med J 2003;**79**:686–690

See end of article for authors' affiliations

Correspondence to:
Dr Ron Eliashar,
Department of
Otolaryngology/Head
and Neck Surgery,
Hadassah University
Hospital, Jerusalem, Israel;
ron@eliashar.com

Submitted 21 January 2003
Accepted 1 May 2003

Purpose: Endoscopic endonasal surgery (EES) has become the standard practice in sinonasal and anterior skull base surgery. The purpose of this manuscript is to describe experience using a new technology—the image guided navigation system (IGNS)—in complex cases undergoing EES. The advantages and disadvantages of computer aided surgery are discussed.

Patients and methods: A total of 165 endoscopic endonasal procedures were performed between April 2001 and January 2003. IGNS was used in 34 patients in whom it was assumed that the ability to identify surgical sites accurately could be compromised by previous surgery, massive recurrent polyposis, or abnormal anatomy, or when biopsies had to be taken from specific anatomic locations (for example, clivus, wall of sphenoid sinus, orbital apex). The precision of the navigation system, total operating room time, surgeon's satisfaction and confidence, and intraoperative and postoperative complications were recorded.

Results: In 33 out of 34 patients the surgical procedure was uneventful. One patient with an atelectatic maxillary sinus developed a minor complication of preseptal orbital haematoma. In 94% the IGNS provided accurate anatomical localisation with less than 2 mm localisation error (1.1–2.0 mm, mean 1.6 mm). In all cases the surgical team felt that the system increased the intraoperative safety factor for the patient. The overall operating room time at the end of the study was 15 minutes longer than when regular EES was used.

Conclusions: IGNS enables a new level of efficiency and safety in EES. Nevertheless, it is not advised for surgeons who are not familiar with regular EES. For the experienced endoscopist, however, IGNS is a valuable new tool in complex procedures.

Endoscopic endonasal surgery (EES) has become the surgical treatment of choice in many patients who require sinonasal or anterior skull base surgery. Successful EES requires a thorough knowledge of the anatomy, in particular the relationship of the nose and sinuses to adjacent vulnerable structures such as the orbit or base of skull.¹ Indeed, major surgical risks in EES include partial loss of vision or blindness, diplopia, damage to the cribriform plate or to the roof of the ethmoid sinuses, and injury to the internal carotid artery in the wall of the sphenoid sinus.²

Three dimensional image guided navigation system (IGNS) is increasingly acknowledged as a useful technology for EES.¹ The purpose of this manuscript is to describe our experience using computer aided EES in potentially complex cases and to discuss the advantages and disadvantages of IGNS.

PATIENTS AND METHODS

Patients

Patients were elected to undergo computer aided EES (instead of regular EES) when it was assumed that the ability to identify surgical sites accurately could be compromised by previous surgery, massive recurrent polyposis, abnormal anatomy, etc, or when biopsies had to be taken from specific anatomic locations (for example, clivus, wall of sphenoid sinus, orbital apex).

Image guidance navigation system

The LandmarX ENT Image Guidance System (Xomed Surgical Products, Jacksonville, FL, USA) was used in all patients scheduled for computer aided EES. This system enables real time surgical navigation using preoperative computed tomographic images. The system includes a

monitor, a computer, an optical camera, a reference head frame, and specialised optical probes (fig 1). The reference frame and each optical probe contain infrared emitting diodes which transmit infrared light to the optical camera. The camera identifies the location of each source of light and relays this information into the computer. The computer then determines the exact location in space of the tip of the probe. Because the reference frame is attached rigidly to the patient's head, any movement is detected and the computer compensates mathematically for the deviation.

Computer aided EES

The process of computer aided EES is as follows:

- Preoperative computed tomography is performed after special fiducial markers are attached to the patient's face. The following protocol is currently being used: axial slices, 1:1 pitch, contiguous non-overlapping slices, 1.3 mm slice thickness, 340 × 340 matrix, no tilt. The data from computed tomography is transferred to the computer in the operating room via the local network.
- The computer software restructures the computed tomographic images and displays them on the screen in different perspectives (axial, coronal, sagittal). A three dimensional model of the patient's anatomy is built (fig 2).

Abbreviations: EES, endoscopic endonasal surgery; IGNS, image guided navigation system

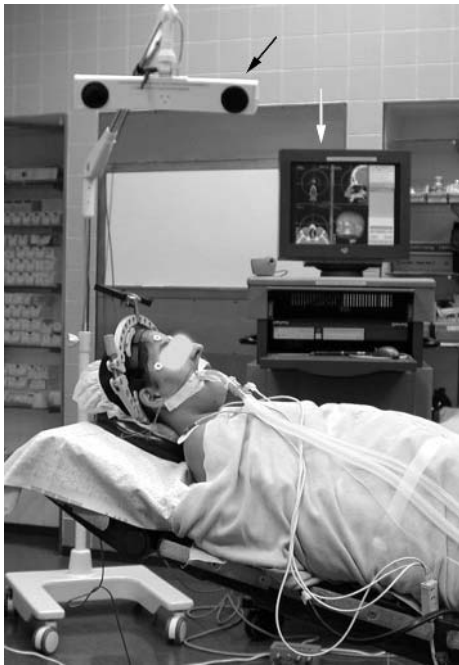

Figure 1 The navigation system includes a monitor and a computer, an optical digitising camera, a reference head frame, and specialised optical probes (not shown).

- A “map” relating computed tomographic data to physical points (that is, the patient’s anatomy) is derived from a process named “co-registration” (fig 2). After attaching the reference frame to the patient’s head, the surgeon selects particular points (“landmarks”) from the

computed tomography images. He then selects corresponding points from the patient’s external anatomy (specific anatomical points around the skull, such as the tragus or fiducials) by means of an optical probe. By analysing the relationship between these points the computer software can build a map, which matches each point in the computed tomography data with its corresponding point on the patient’s anatomy. Green and yellow spheres/circles illustrate the regions within which the localisation error deviates 1 mm or less (green) and 2 mm or less (yellow).

- Intraoperative navigation: whenever the surgeon selects a point from the patient’s anatomy (for example, the internal carotid artery in the wall of the sphenoid sinus) using the tip of one of the optical probes, the computer uses the above “map” to identify the corresponding point on the computed tomography images. The point is then displayed on the monitor within all the different image planes (fig 3). The surgeon then knows exactly where the tip of the probe is located in the patient’s anatomy and can perform safe surgery. It is important to understand that only preoperative scanning provides the computed tomography data for the operation. This means that tissue changes occurring during surgery do not show on the screen.

Evaluation of computer aided ESS

System precision, total operating room time, surgeon’s satisfaction, and intraoperative and postoperative complications were recorded. System precision was determined by:

- The maximum predicted localisation error calculated by the system itself.
- By pointing at anatomical landmarks (tip of inferior and middle turbinates, nasolacrimal duct, medial: superior

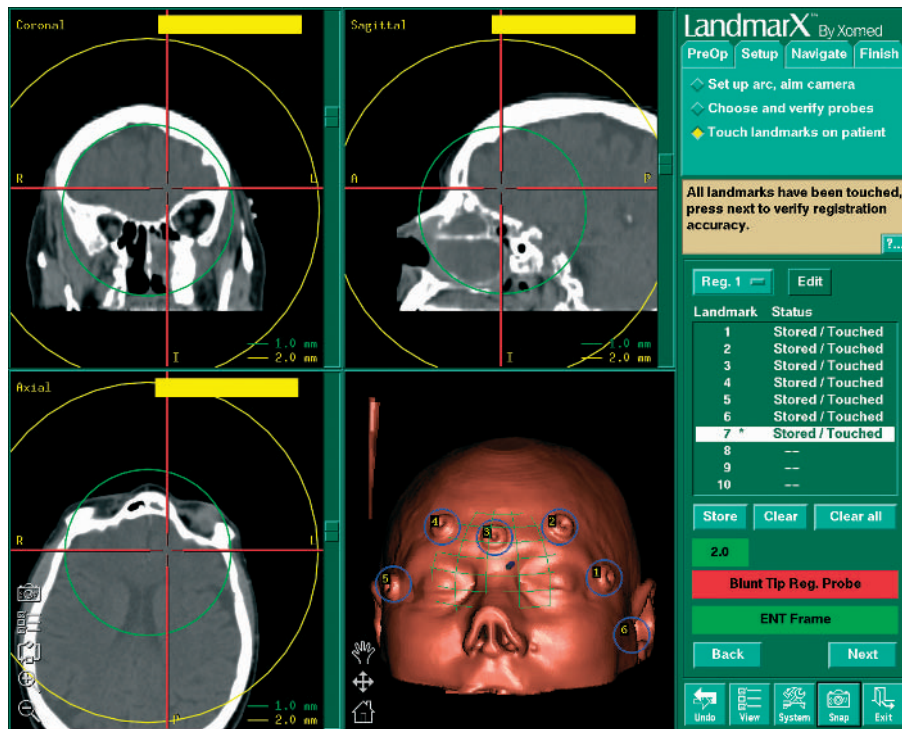

Figure 2 Computed tomography of a patient with both frontoethmoidal and maxillary mucocoeles was transferred to the system computer. The computer software restructured the computed tomography images and displayed them on the screen in different perspectives (axial, bottom left; coronal, top left; sagittal, top right; three dimensional model, bottom right). After the process of “co-registration” green and yellow circles illustrated the regions within which the localisation error deviated 1 mm or less (green) and 2 mm or less (yellow).

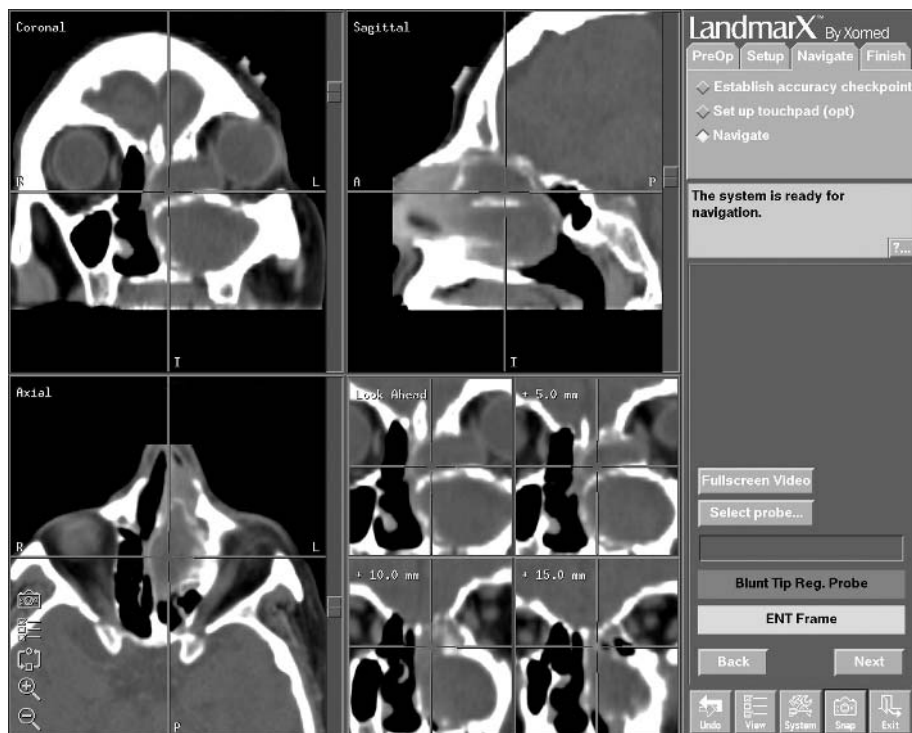


Figure 3 During surgery, the surgeon selected a point inside the maxillary mucocele using the tip of a specialised optical probe. The computer used the “map” to identify and display the corresponding point on the computed tomography images (cross hairs). In this case, the surgeon used a “look ahead” view instead of a three dimensional view (bottom right), in which he could “look forward” for a distance of up to 15 mm from the tip of the probe.

part of posterior choana) and measuring the distance in millimetres between these structures on the computed tomogram and the cross hairs of the pointer displayed on the screen.

At the end of each procedure the senior surgeon recorded his level of satisfaction from the navigation system by the following grading system: 1, not satisfied; 2, slightly satisfied; 3, satisfied; 4, very satisfied.

RESULTS

One hundred and sixty five patients underwent EES in the Department of Otolaryngology/Head and Neck Surgery, Hadassah University Hospital, Jerusalem, Israel, between April 2001 and January 2003. Thirty four patients (20%) were elected to undergo computer aided EES after presuming possible difficulty in identifying the surgical site with utmost accuracy or when a biopsy had to be taken from a specific

anatomic location. The age of the patients ranged from 21 to 67 years (mean 46). Indications for surgery in patients undergoing computer aided EES are shown in table 1.

One hundred and thirty one patients underwent regular EES without IGNS. Seventy four patients (56%) underwent functional EES for chronic sinusitis, 31 (24%) nasal polypectomy, 10 (8%) excision of a mucocele, and 16 (12%) surgery for fungal sinusitis. One operation had to be terminated prematurely due to extensive bleeding and another due to a malformation, which rendered the operation on that side to be unsafe. The other 129 operations were completed successfully. There were three minor complications that resolved spontaneously: two patients developed preseptal haematoma and one patient developed periorbital subcutaneous emphysema.

All 34 computer aided EES cases, which were all more complex than the regular EES cases, were completed successfully. In 33 out of 34 patients the surgical procedure was uneventful. One of our last patients, who had an atelectatic maxillary sinus (which exposes the medial orbital wall to surgical trauma) and who underwent a fourth revision nasal polypectomy, developed a complication of preseptal orbital haematoma which resolved spontaneously. In 32 out of 34 cases (94%) the IGNS provided accurate anatomical localisation with less than 2 mm localisation error (1.1–2.0 mm, mean 1.6 mm). Localisation errors of 2.2 mm and 2.3 mm were achieved in two patients. In all cases the surgical team felt that the system provided increased intraoperative safety for the patient by assisting in navigating through diseased or surgically revised complex anatomy (mean satisfaction level 3.94). This may have led to some over-estimated self confidence, which caused us to overlook the position of the medial wall of the maxillary sinus in the only case suffering from a complication. When we first started using IGNS the overall operating room time was 30 minutes more than in regular EES. Since then it has been reduced by 15 more minutes. We have reason to believe

Table 1 Indications for computer aided endoscopic endonasal surgery (EES) in current study

Indication for computer aided EES	No of patients
Revision functional EES	7
Revision nasal polypectomy	7
Frontal sinus surgery	3
Frontoethmoidal mucocele	5
Sphenoidal lesion	3
Endoscopic excision of tumour	2
Biopsy from orbital apex	1
Biopsy from clivus	2
Endoscopic closure of cerebrospinal fluid leak	4

Box 1: Advantages of computer aided EES**Advantages**

- Accurate localisation of lesions:
 - Increased safety of patients.
 - Surgeon reassurance.
 - Simplification of complex operations.
- Sagittal reconstruction and a three dimensional imaging capacity:
 - Understanding of complex anatomy.
 - Improved learning curve for residents.

Disadvantages

- Preoperative computed tomography:
 - “Yesterday’s” computed tomography.
 - Additional irradiation.
- Longer operating room time (expected to be reduced when more experience is gained).
- Danger of complacency.
- Expensive equipment.

that the time spent in the operating room will further decrease as we gain more and more experience in computer aided EES.

DISCUSSION

Minimally invasive procedures have become standard practice in operations involving the sinus system or the anterior skull base. Image guided surgery, which is also used by other disciplines (such as neurosurgery, orthopaedic surgery, and maxillofacial surgery), represents a new technology with applicability to some patients undergoing functional EES for medically refractory rhinosinusitis. It also expands the ability to perform minimally invasive EES for non-infectious pathologies of the sinuses, orbits, and anterior skull base.^{2,3}

Undoubtedly, a thorough knowledge of the anatomy remains essential for performing safe EES. However, malformations, previous operations, and massive polyposis may interfere greatly with intraoperative orientation, thus exposing the patient to major risks. IGNS is an important aid to surgeons in identifying anatomic landmarks in difficult cases, thus reducing the stress placed on the surgeon and augmenting patients’ safety.⁴ By improving the surgical accuracy, IGNS greatly reduces the risk of major intracranial or intraorbital complications.^{4,5} It also offers a sagittal reconstruction and a three dimensional imaging capacity, which greatly improves the accuracy and precision of EES in complex areas (such as the frontal recess).⁶

Computer aided EES technology is also helpful for training purposes, since visualisation in different sectional planes augments the understanding of normal and pathological anatomy.⁵ Indeed, there are data suggesting that computer aided EES enhances surgical efficiency and improves the learning curve of residents.⁷

As mentioned before, a preoperative scanning provides the computed tomography data which are used later. This means that tissue changes occurring during surgery are not seen on the screen. An intraoperative computed tomogram with updating of the IGNS might provide a solution for that obstacle. However, an intraoperative computed tomography scanner is expensive, lengthens the procedure, and occupies

extra space in the operating room. Moreover, the surgeon performing EES is mainly concerned with bony landmarks, and is thus less influenced by soft tissue changes. It is therefore generally agreed that updating the computed tomography data with an intraoperative computed tomogram cannot be recommended for EES.¹

IGNS can utilise either electromagnetic (radiofrequency) or optical (infrared) signals for localising instruments within the surgical field. Most systems require special headsets to be worn by patients during surgery in order to monitor head position.⁸ Like other surgeons,⁹ we have also found the optical based IGNS, which we use, to be useful and convenient.

We described the process of computer aided EES and reported on our experience with IGNS in a variety of cases, ranging from revision functional EES and nasal polypectomy, to more complicated endoscopic procedures such as biopsies from delicate areas (for example, orbital apex) or closure of cerebrospinal fluid fistulas. Because the IGNS was at our disposal only one day a week (we had to share it with the neurosurgical and the orthopaedic departments), we were limited with the number of patients whom we could schedule for computer aided EES. Therefore, we decided to utilise the IGNS for the most complicated cases only. This *a priori* selection did not enable us to conduct a controlled assessment study, but we did use criteria previously employed for evaluating the profitability and accuracy of image guided systems.^{10–13} Considering the limitations of IGNS (box 1), we are convinced that our selection of patients was justified. Although our evaluation of the surgeon’s satisfaction from the accuracy of the system and of the self confidence gained from using IGNS were not an objective evaluation, we believe that the subjective feelings expressed by experienced endoscopists are an important measure, and are worth considering.

In conclusion: computer aided EES appears to be a useful tool. Nevertheless, the endoscopic surgeon must have a thorough knowledge of the basic anatomy of the nose, sinuses, and anterior skull base, as well as of the various surgical techniques. Computer aided EES should not by any means be performed by surgeons who are not familiar with regular EES. For the experienced endoscopist, computer aided EES is a valuable tool for complex procedures. The advantages and disadvantages of computer aided EES as we see them are summarised in box 1. Like other authors,^{13,14} we believe that for the experienced endoscopist, computer aided EES enables a new level of efficiency in EES.

Authors’ affiliations

R Eliashar, J-Y Sichel, M Gross, E Hocwald, I Dano, A Biron, A Ben-Yaacov, A Goldfarb, J Elidan, Department of Otolaryngology/Head and Neck Surgery, Hadassah University Hospital, Jerusalem, Israel

REFERENCES

- 1 Cartellieri M, Vorbeck F. Endoscopic sinus surgery using intraoperative computed tomography imaging for updating a three-dimensional navigation system. *Laryngoscope* 2000;**110**:292–6.
- 2 Olson G, Citardi MJ. Image-guided functional endoscopic sinus surgery. *Otol Head Neck Surg* 2000;**123**:188–94.
- 3 Neumann AM, Pasquale-Nibles K, Bhuta T, et al. Image-guided transnasal endoscopic surgery of the paranasal sinuses and anterior skull base. *Am J Rhinol* 1999;**13**:449–54.
- 4 Caversaccio M, Bachler R, Ladrach K, et al. Frameless computer-aided surgery system for revision endoscopic sinus surgery. *Otol Head Neck Surg* 2000;**122**:808–13.
- 5 Heermann R, Schwab B, Issing PR, et al. Image-guided surgery of the anterior skull base. *Acta Otolaryngol* 2001;**121**:973–8.
- 6 Anand VK, Kacker A. Value of radiologic imaging and computer assisted surgery in surgical decisions of the anterior skull base lesions. *Rhinology* 2000;**38**:17–22.
- 7 Casiano RR, Numa WA Jr. Efficacy of computed tomographic image-guided endoscopic sinus surgery in residency training programs. *Laryngoscope* 2000;**110**:1277–82.
- 8 Metson RB, Gliklich RE, Cosenza MJ. A comparison of image guidance systems for sinus surgery. *Laryngoscope* 1998;**108**:1164–70.

- 9 **Metson RB**, Cosenza MJ, Cunningham MJ, et al. Physician experience with an image guidance system for sinus surgery. *Laryngoscope* 2000;**110**:972–6.
- 10 **Luxenberger W**, Kole W, Stammberger H, et al. Computer assisted localization in endoscopic sinus surgery—state of the art? The Insta Trak system. *Laryngorhinootologie* 1999;**78**:318–25.
- 11 **Vorbeck F**, Cartellieri M, Ehrenberger K, et al. Intraoperative navigation in paranasal sinus surgery with the Philips “Neuroguide” system. *Radiologie* 2000;**40**:227–32.
- 12 **Vorbeck F**, Cartellieri M, Ehrenberger K, et al. Experiences in intraoperative computer-aided navigation in ENT sinus surgery with the Aesculap navigation system. *Comput Aided Surg* 1998;**3**:306–11.
- 13 **Koele W**, Stammberger H, Lackner A, et al. Image guided surgery of paranasal sinuses and anterior skull base—five years experience with InstaTrak-System. *Rhinology* 2002;**40**:1–9.
- 14 **Fried MP**, Moharir VM, Shin J, et al. Comparison of endoscopic sinus surgery with and without image guidance. *Am J Rhinol* 2002;**16**:193–7.

IMAGES IN MEDICINE.....

Palmar striated xanthomas

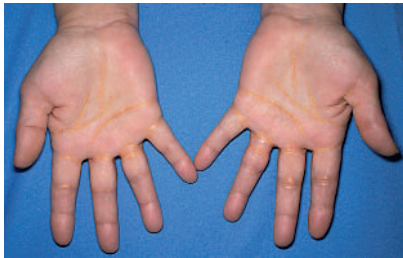

Figure 1 Patient's hands showing palmar striated xanthomas and yellowish discoloration along the palmar creases.



Figure 2 Comparison of patient's serum showing lipaemia (bottle on the right) with a control serum.

A 52 year old woman presented to the emergency department with two hours of central chest pain. She had no past medical history of ischaemic heart disease, diabetes, or hypertension. She had a family history of ischaemic heart disease; her brother had a myocardial infarction when 50 years old. She was taking no medication.

She smoked 20 cigarettes per day and had a 38 pack year history. On examination she was found to have palmar striated xanthomas (fig 1) and she was found to have hypothyroid facies on general examination. Her systemic examination was normal. Electrocardiography revealed T-wave inversion in lateral leads. Serial troponin I measurements were <0.3 mmol/l (Bayer Centaur: normal <0.3 mmol/l). Her serum was lipaemic (fig 2). Lipid profile revealed a serum cholesterol of 14.2 mmol/l and triglyceride of 9.3 mmol/l. Thyroid function tests were consistent with hypothyroid state with a thyroid stimulating hormone concentration of 45 mU/l and free thyroxine of 7 pmol/l. A coronary angiogram revealed mild diffuse disease. She was diagnosed to have familial type III hyperlipoproteinaemia and primary hypothyroidism. She was started on statin therapy, thyroxine, and antianginal medication. One of her three children was found to have a raised serum cholesterol concentration.

Type III hyperlipoproteinaemia, also known as remnant hyperlipidaemia, dysbetalipoproteinaemia or “broad beta disease”, is a rare genetic dyslipoproteinaemia characterised by accumulation in the plasma of remnant lipoprotein particles. Affected individuals have a substantially increased cardiovascular risk. Palmar striated xanthomas and tuberoeruptive xanthomas, which may coalesce to form tuberous xanthomas, are pathognomonic of this condition. The majority of patients are homozygous for the apoprotein E₂ variant, reducing binding of chylomicron remnants and intermediate density lipoprotein to hepatic apoprotein E and low density lipoprotein receptors respectively, and causing their accumulation. This genetic substrate alone is insufficient for the clinical expression of the disease. An additional inherited or acquired lipid disorder, for example hypothyroidism as in this case, is required (1% of the population have the apo E₂/E₂ genotypes, but only 0.01% have type III hyperlipidaemia).

D V Nagarajan, P A Boreham, V J Parfitt

Department of Medicine and Cardiology, Frenchay Hospital, Frenchay Park Road, Bristol BS16 1LE, UK; darbhamulla@aol.com