

CLASSIFICATION OF LEFT ATRIAL APPENDAGE MORPHOLOGY USING DEEP LEARNING

Mikayle A. Holm^{1,2}, Alex Deakyné^{1,3}, Erik Gaasedelen^{1,3}, Weston Upchurch^{1,3}, Paul A. Iaizzo^{1,2,3}

¹Departments of Surgery, ²Biomedical Engineering, and ³Bioinformatics and Computational Biology
University of Minnesota
Minneapolis, MN, USA

ABSTRACT

Atrial fibrillation, a common cardiac arrhythmia, can lead to blood clots in the left atrial appendage (LAA) of the heart, increasing the risk of stroke. Understanding the LAA morphology can indicate the likelihood of a blood clot. Therefore, a classification convolutional neural network was implemented to predict the LAA morphology. Using 2D images of 3D models created from MRI scans of fixed human hearts and a pre-trained network, an 8.7% error rate was achieved. The network can be improved with more data or expanded to classify the LAA from the automatically segmented DICOM datasets and measure the LAA ostia.

Keywords: left atrial appendage, deep learning

INTRODUCTION

Atrial fibrillation (AF) is a common cardiac arrhythmia where the atria of the heart do not contract normally [1]. Certain AF patients are at a higher risk of stroke due to the potential for thromboembolism and therefore are routinely anti-coagulated. However, permanent anti-coagulation is associated with high risks of bleeding or a need for frequent blood testing [1]. A percutaneous left atrial appendage (LAA) occlusion device may be a good alternative for such patients.

There are four “coined” morphologies for the human LAA: ‘chicken wing’, ‘windsock’, ‘cauliflower’, and ‘cactus’ [1,2]. Determining which morphology a patient has typically indicates the likelihood of stroke and can influence which LAA occlusion device and device size the physician chooses to implant [1].

Deep learning can help classify a patient’s LAA morphology to assist physicians in determining best treatment pathway for a given patient. Here we describe a classification convolutional neural network that predicts the LAA morphologies from 3D

objects created from segmented MRI scans of fixed human hearts.

METHODS

MRI scans of 16 fixed human hearts available from the Visible Heart[®] Laboratories were used as our dataset. The LAA’s were segmented and 3D models were computationally created. The ground-truth labels were generated by an anatomical expert classifying the relative LAA morphology of each model. Two dimensional images (size 224x224 pixels) of these 3D models were taken from different angles to generate a larger dataset and generate more robust models. Of the 116 images used, 32 were cauliflower, 54 were chicken wings, and 30 were windsocks. No examples of the cactus morphology were available. Next, this dataset was split into 80% training and 20% validation datasets. An example of the images used are shown in Figure 1.

A pre-trained ResNet34 architecture [3] (Figure 2) was employed and cross entropy loss was used as the loss function to train the network. A batch size of 8 was used along with numerous transformations including random horizontal and vertical flips, rotations, and lightings. The network was trained for 4 epochs with the pre-trained layers frozen, then followed by 10 epochs with the layers unfrozen and using a learning rate of 1×10^{-4} and one cycle policy [4].

¹ Contact author: iaizz001@umn.edu

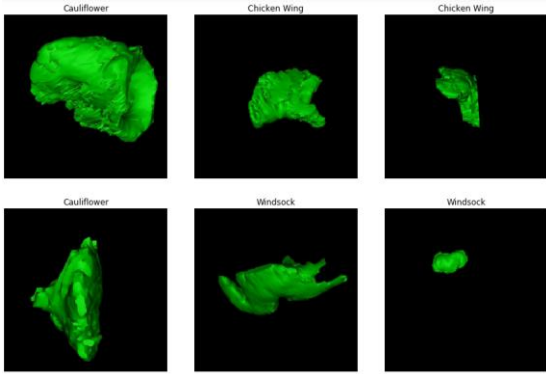


Figure 1. Images of the computational 3D models of chicken wing, windssock, and cauliflower LAA's which were used to train and validate the network.

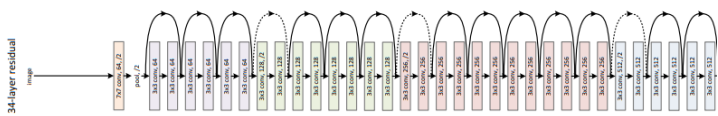


Figure 2. ResNet34 architecture.

RESULTS

The network was able to achieve an error rate of 8.7% in the classifications of these LAAs. A random collage of the validation results are presented in Figure 3. The top labels are the ground truths and the bottom labels are the predicted morphologies, determined by the network. Additionally, a confusion matrix is presented (Figure 4) which highlights what morphologies are being misclassified by the network in the validated set. Clearly the cauliflower is the most difficult of the three to correctly predict, as indicated by two incorrect guesses. Therefore, more data is required to better train the network to correctly predict a cauliflower morphology. Additionally, data of the cactus morphology would allow for more specific classifications of various LAAs.

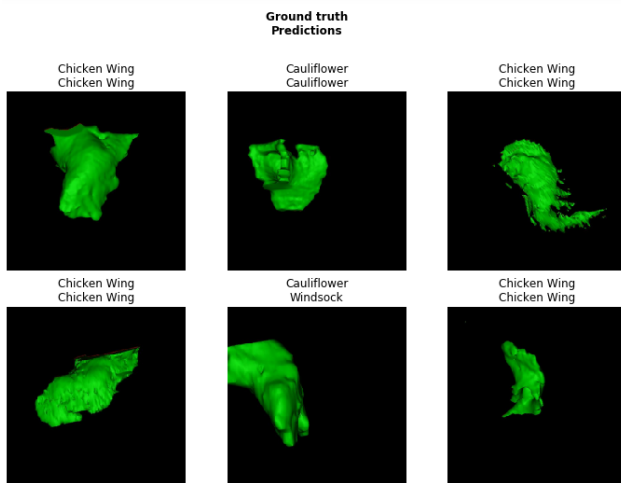


Figure 3. Examples of the validation images classified by the network. The top label is the ground truth and the bottom label is the morphology predicted by the network.

Confusion matrix

		Cauliflower	Chicken Wing	Windssock
Actual	Cauliflower	4	1	1
	Chicken Wing	0	11	0
	Windssock	0	0	6
		Cauliflower	Chicken Wing	Windssock
		Predicted		

Figure 4. The confusion matrix showing which LAA morphology the network is predicting correctly and incorrectly.

CONCLUSION

This computational network has the potential to rapidly identify a patient's LAA morphology which may be used to indicate the potential risks of stroke and the need for an occlusion device placement. Using a neural network to classify LAA morphology will save time in the clinic. Though the currently employed dataset is small and results are preliminary, the network showed strong promise as there was only an 8.7% error rate. With more data, there will likely be an improvement in the accuracy of the network predictions. The next steps in this project include classifying the LAA from the automatically segmented [5] DICOM data and taking measurements of the LAA ostium as this an important parameter for sizing of various LAA occlusion devices.

REFERENCES

- [1] De Backer O, Arnous S, Ihlemann N, et. al. Percutaneous left atrial appendage occlusion for stroke prevention in atrial fibrillation: an update. *Open Heart* 2014.
- [2] Wang Y, Di Biase L, Horton RP, et. al. Left atrial appendage studied b computed tomography to help planning for appendage closure device placement. *Journal of Cardiovascular Electrophysiology* 2010.
- [3] He K, Zhang X, Ren S, Sun J. Deep Residual Learning for Image Recognition. *arXiv:1506.02640* 2016.
- [4]Smith L. Cyclical Learning Rate for Training Neural Networks. *arXiv:1506.01186* 2017.
- [5] Deakne A, Gaasedelen E, Iaizzo, PA. A Deep Learning Approach for the Automatic Identification of the Left Atrium within CT Scans. *Proceedings of the 2019 Design of Medical Devices Conference* 2019.