

DMD2020-9042

MINIMIZING COTTON BALL RETENTION IN NEUROLOGICAL PROCEDURES

Raphael Bechtold¹, Benjamin Garlow, Renee Liu,
Arushi Tandon, Alexandra Szewc, William Zhu,
Olivia Musmanno
Johns Hopkins University
Baltimore, Maryland, United States

Noah Gorelick, Ian Suk, Dr. Judy Huang, Dr.
Henry Brem, and Dr. Amir Manbachi
Johns Hopkins Medical Institution
Baltimore, Maryland, United States

George Coles
Applied Physics Laboratory
Laurel, Maryland, United States

ABSTRACT

Neurosurgical operations are long and intensive medical procedures, during which the surgeon must constantly have an unobscured view of the brain in order to be able to properly operate, and thus must use a variety of tools to clear obstructions (like blood and fluid) from the operating area. Currently, cotton balls are the most versatile and effective option to accomplish this as they absorb fluids, are soft enough to safely manipulate the brain, act as a barrier between other tools and the brain, and function as a spacer to keep anatomies of the brain open and visible during the operation. While cotton balls allow neurosurgeons to effectively improve visibility of the operating area, they may also be accidentally left in the brain upon completion of the surgery. This can lead to a wide range of post-operative risks including dangerous immune responses, additional medical care or surgical operations, and even death. This project seeks to develop a unique medical device that utilizes ultrasound technology in order to minimize cotton retention after neurosurgical procedures in order to reduce undesired post-operative risks, and maximize visibility.

Keywords: Cotton balls, Ultrasound, Textiloma, Visibility

INTRODUCTION

Approximately 22.6 million people around the world are affected by a neurological injury or disorder every year, and 13.8 million of those patients need a surgical operation³. This constitutes 13.8 million opportunities annually for cotton balls to be used during surgery and potentially left behind post-operatively. Therefore, maintaining unobstructed visibility throughout surgery while simultaneously prioritizing surgical patient well-being is critical. Surgical cotton left unintentionally can cause seizures, epilepsy, memory loss, and headaches

which may end up being permanent^{1,2}. Retained cotton can also induce potentially life-threatening immunologic responses, impair post-operative imaging, lead to a misdiagnosis, and will always require an additional correctional surgery^{1,3,4}. Retained cotton may not present symptoms for months or years postoperatively while the body undergoes an immune response to the aseptic fibrous tissue and a gossypiboma (a foreign object, that is left behind during an operation that radiologically mimics recurrent tumor or abscess) forms around the cotton ball. There have been 50 recorded cases of gossypiboma since 1973¹. Moreover, the accidental retention of cotton balls will require additional medical care or surgical operations for patients as well as additional medical expenses and costly lawsuits against the hospital, with the estimated annual cost of retained surgical items being \$2.4 million for healthcare systems, as well as 70% of the objects left behind being absorbents^{2,5}. However, there is currently no existing means to reliably detect cotton balls prior to surgical closure. Thus, there is a need for an intraoperative ultrasound device that can effectively detect cotton balls specifically designed for neurosurgical procedures.

1.1 ULTRASOUND TECHNOLOGY FEASIBILITY

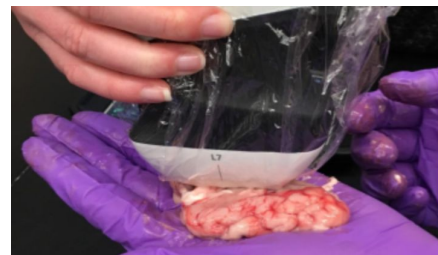
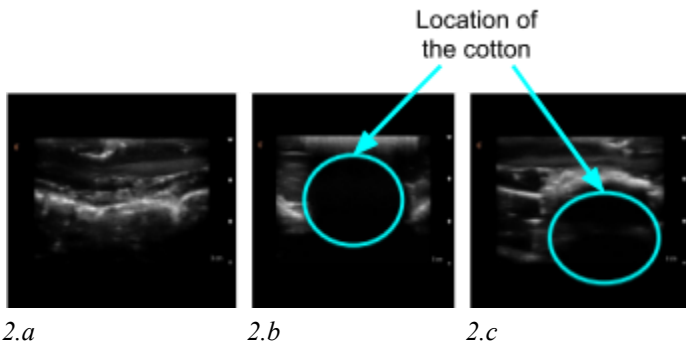
Figure 1: Pig brain used for ultrasound testing

¹ Raphael Bechtold: rbechtold@jhu.edu



2.a 2.b 2.c
Figure 2: Ultrasound scans of pig brain (2.a), pig brain with cotton the surface (2.b), pig brain with cotton 2cm deep (2.c)

Preliminary experiments have been performed using an ultrasound device to detect cotton within a pig brain (*fig. 1*). First, the pig brain was scanned for a control image (*fig. 2a*). A ~3cm diameter cotton ball was then wedged into a sulcus on the surface of the pig brain and the probe was used to capture an image (*fig. 2b*). This was repeated with cotton underneath the brain and similar results were found (*fig. 2c*). These results are very promising as they show a distinct dark spot where there was cotton. This experiment shows that cotton and brain matter respond to different acoustic frequencies and appear as differentiable materials to an ultrasound device.

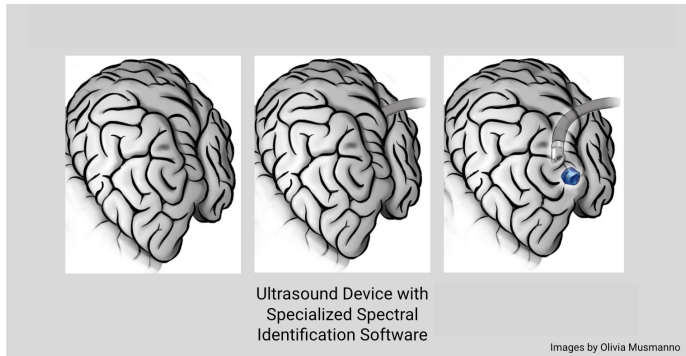


Figure 3: Shows potential design for the foreign body detection device.

An effective medical device to detect retained cotton would be a custom ultrasound transducer probe head with a 180 degree field of view that is able to rotate 360 degrees so as to detect foreign bodies (*fig. 3*)—namely cotton balls of 3mm diameter or greater—up to 8 cm deep within the brain. The device would be capable of quantifying the contrast between the cotton and the blood-brain background by automatically detecting cotton through the novel ultrasound probe and an integrated AI software technology. For the purposes of image analytics, the contrast between the cotton and its blood and brain environment may be operationally defined as:

$$CNR = \frac{I_c - I_b}{I_b}$$

where CNR represents the contrast to noise ratio, I_c is the intensity of the ultrasound scan produced by cotton and I_b is the intensity of the ultrasound scan produced by the blood/brain background. Through this contrast definition, a spectral analysis of the data, and a machine learning segmentation algorithm, the AI integrated device will be able to automatically detect cotton in the brain—minimizing cotton retention, and significantly improving patient outcomes.

ACKNOWLEDGEMENTS

We would like to thank Dr. Amir Manbachi, George Coles, Dr. Judy Huang, Dr. Henry Brem, and Noah Gorelick for their continued support and insight on this project.

REFERENCES

- [1] Peloquin P, Vannemreddy PSSV, Watkins LM, Byrne RW. Intracranial cotton ball gossypiboma mimicking recurrent meningioma: Report of a case with literature review for intentional and unintentional foreign body granulomas. *Clin Neurol Neurosurg.* 2012;114(7):1039-1041. doi:10.1016/j.clineuro.2012.01.046
- [2] Ribalta T, McCutcheon IE, Neto AG, et al. Textiloma (gossypiboma) mimicking recurrent intracranial tumor. *Arch Pathol Lab Med.* 2004.
- [3] Dewan MC, Rattani A, Fiegehen G, et al. Global neurosurgery: the current capacity and deficit in the provision of essential neurosurgical care. Executive Summary of the Global Neurosurgery Initiative at the Program in Global Surgery and Social Change. *J Neurosurg.* 2018;130(4):1055-1064. doi:10.3171/2017.11.jns171500
- [4] Jury Verdict Review and Analysis. (n.d.). - MEDICAL MALPRACTICE - BREACH OF STANDARD OF CARE ALLEGED AGAINST NEUROSURGEON IN PERFORMANCE OF CRANIOTOMY - DEFENDANT ALLEGEDLY LEAVES COTTON BALL INSIDE BRAIN - SEVERE BRAIN DAMAGE - FRONTAL LOBE DAMAGE - MEMORY DEFICIT - LEFT-SIDED HEMIPLEGIA. Retrieved October 5, 2018, from https://www.jvra.com/verdict_trak/article.aspx?id=29710
- [5] Lagasse, J. (2016, May 6). Damages from left-behind surgical tools top billions as systems seek end to gruesome errors. Retrieved from <https://www.healthcarefinancenews.com/news/damages-left-behind-surgical-tools-top-billions-systems-see-end-gruesome-errors>.