

INTRODUCING A COST-EFFECTIVE RADIOPAQUE SCALE DESIGN FOR INTRA-OPERATIVE USE

Roopam Dey^{1,3}, Giancarlo Beukes^{1,2}

¹Division of Biomedical Engineering,
Department of Human Biology,
University of Cape Town, South Africa

³Division of Orthopaedic Surgery,
Department of Surgery, Groote Schuur Hospital,
University of Cape Town,
Western Cape, South Africa.

Gokul Nair^{1,2}, Sudesh Sivarasu^{1*}

²Impulse Biomedical (Pty) Ltd,
Cape Town,
Western Cape, South Africa.

ABSTRACT

Radiopaque scales have numerous uses in the field of surgery, especially orthopaedic surgery. Scales of this nature can be used to guide surgeons by taking intra-operative measurements, pinpoint insertion points on bones and detect locations of deformations and tumours inside the body. Despite this, these scales are not used widely enough because of its high cost and that there are no widely acceptable ways of developing them from off the shelf materials. This paper details the method of inventing a novel low-cost radiopaque scale using off the shelf materials such as Barium Sulfate and Iodinated Contrast Agent (ICA). The radiopaque scale was manufactured using Perspex® and was filled with the contrast agents. The scales were then scanned using low-dose X-ray machines. The scale filled with Barium was found to be provide a better contrast image suggesting that the Barium to be a better high-contrast agent when compared to iodine and is recommended for use.

Keywords: scales, surgery, radiopaque, barium sulfate, ICA, intra-operative.

INTRODUCTION

Intra-surgical guidance to surgeons is often provided by scales which are embedded with radiopaque markings made with metals, such as lead [1]. The use of lead and the difficulty of manufacturing the scales embedded with lead, make these radiopaque scales very costly (\$405.70 including shipping) and inaccessible to local hospitals in developing countries in Africa. Non-lead radiopaque scales have recently been introduced to the market but no information about the contrast agent used in these scales are available [2]. Moreover, these scales costing around \$70 do not have shipping options to South Africa making them unreachable for the local hospitals.

Medial Patella-Femoral Ligament (MPFL) reconstruction surgery is one of the arthroscopic techniques where radiopaque scales and markers are used intra-operatively to evaluate the direction of tunnel drilling and locating the graft insertion landmarks on patella and femur [3,4]. Previously, the authors developed a patented low-cost MPFL reconstruction guide which was coupled with a radiopaque scale constructed with off-the-shelf materials [5,6]. A similar concept was used to develop a scale to improve the accuracy of diagnosing knee joint ligament injuries using a novel laxity measuring stress radiography device [7]. This study aims to compare the use of common contrast

*Contact author: sudesh.sivarasu@uct.ac.com. 7.17 Anatomy Building, Division of Biomedical Engineering, Faculty of Health Sciences, University of Cape Town, Observatory, Cape Town – 7925.

agents, used in medical imaging settings, Barium sulfate [8] and Iodinated Contrast Agent (ICA) [9] as a contrast medium for use as part of a low-cost radiopaque scale.

RADIOPAQUE SCALE DESIGN

The scale was designed using SolidWorks® (Dassault Systems, Waltham USA) and was manufactured using clear Perspex®. The dimensions of the scale were 100mmx100mmx3mm. The linear measurement markers on the scale surface were made by drilling 1.5mm deep grooves, at 10mm from each other. The grooves were filled with radiopaque agents such as barium sulfate powder and ICA (Figure 1). The scale was then covered with a ConTract® self-adhesive transparent plastic to reduce spillage. The barium and the iodine were obtained from the radiology imaging facility at the University of Cape Town Private Hospital, South Africa.



FIGURE 1: Radiopaque scale design with filled with two separate agents.

TESTING METHODS AND RESULTS

Both scales were imaged using a low dose X-ray scanner, Lodox® (Johannesburg, SA) at the Faculty of Health Sciences, University of Cape Town, South Africa. The scanning took place at 120kV, 200mA for 22.0ms. The images generated, are illustrated in Figure 2. A metallic reference object was placed next to the scales to act as a control and reference point.

From the image, the perceived contrast and brightness of the Barium sulfate filled scale was observed to be greater than the ICA filled scale. This image was further processed in MATLAB® (Mathworks Inc., USA) to extract the RGB values for the metal, and the radiopaque agent filled regions of the two scales were extracted. Three scans were taken of each test setup (illustrated in Figure 2), and 3 test setups were conducted by removing the agent from scale with soap each time and adding fresh agent, resulting in a total of 9 scans. The average observed value for the metal piece was [255, 255, 255], which was expected and validates the use of the object as a control, the average observed value for the barium filled region of the scale was [252, 252, 252] and that of the iodine filled region of the scale was [151, 151, 151]. This suggests that using barium

sulfate as a radiopaque agent is better than ICA and provides brighter regions in a radiographic image which is almost comparable to metal.

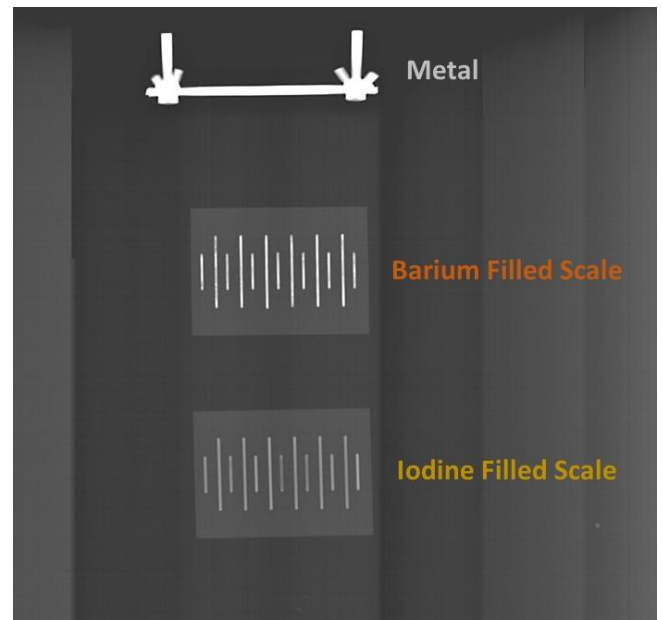


FIGURE 2: Radiographic image of the scales along with a metal object used as the control.

CONCLUSIONS

It can be inferred from this study that ICA and barium sulfate can be utilized for off-the-shelf radiopaque scale development. The total cost of manufacturing such a scale is less than 2 USD which is significantly lower than the current commercial radiopaque scales (~400 USD). Barium sulfate powder filled radiopaque scales provide better contrast compared to iodine solution.

ACKNOWLEDGEMENTS

The authors would like to thank the staff at the UCT Private Hospital radiology facility and Mr. Tyrone de Wet along with Mr. Charles Harris for their timely support.

REFERENCES

- [1] Alimed®. *Radiopaque Scale*. Available: <https://www.alimed.com/radiopaque-scale.html> [Accessed Feb. 27, 2020].
- [2] Supratech®. *Radiopaque Rulers*. Available: <https://www.supertechx-ray.com/RadiopaqueRulers/index.php> [Accessed Feb. 27, 2020].

[3] Golant A, Quach T, and Rosen JE. *Medical Patellofemoral Ligament Reconstruction with a Looped Semitendinosus Tendon, Using Knotless Anchor Fixation on the Patella and Hybrid Fixation on the Femur*. *Arthroscopy Techniques*. 3:2, e211 – e216. (2014). <http://dx.doi.org/10.1016/j.eats.2013.10.001>

[4] Godin JA, Karas V, Visgauss JD, and Garrett WE. *Medial Patellofemoral Ligament Reconstruction Using a Femoral Loop Button Fixation Technique*. *Arthroscopy Techniques*. 4:5, e601 – e607. (2015). <https://doi.org/10.1016/j.eats.2015.06.005>

[5] Dey R, Patnaik S, Steiner S, and Sivarasu S. *Low-Cost Three-Dimensional Printed Surgical Drill-Guiding Device for MPFL Reconstruction (Pat-Rig)*. *Journal of Medical Devices*. 10:2. (2016). <https://doi.org/10.1115/1.4033205>

[6] Dey R, Patnaik S, and Sivarasu S. *Novel Device to Accurately Locate Femoral Insertion Landmark in Medial*

Patellofemoral Ligament (MPFL) Reconstruction. *Design of Medical Device Conference* 2017. <https://doi.org/10.1115/DMD2017-3500>

[7] Beukes G, Patnaik S, and Sivarasu S. *In Vitro Functional Verification of a Novel Laxity Measurement Stress Radiography Device*. *Frontiers in Biomedical Devices, BIOMED* – 2018. <https://doi.org/10.1115/DMD2018-6943>

[8] Periard M. *Adverse Effects and Complications Related to the Use of Barium Sulphate Contrast Media for Radiological Examinations of the Gastrointestinal Tract*. *Canadian Journal of Medical Radiation Technology*. 34:3, 3-9. (2003). [https://doi.org/10.1016/s0820-5930\(09\)60005-0](https://doi.org/10.1016/s0820-5930(09)60005-0)

[9] Pasternak J, and Williamson E. *Clinical Pharmacology, Uses, and Adverse Reactions of Iodinated Contrast Agents: A Primer for the Non-radiologist*. *Mayo Clin Proc*. 87:4, 390-402. (2012). <https://doi.org/10.1016/j.mayocp.2012.01.012>