

# Supplemental Oxygen Improves Diabetic Macular Edema: A Pilot Study

Quan Dong Nguyen,<sup>1</sup> Syed Mahmood Shah,<sup>1</sup> Elizabeth Van Anden,<sup>1</sup> Jennifer U. Sung,<sup>1</sup> Susan Vitale,<sup>2</sup> and Peter A. Campochiaro<sup>1,3</sup>

**PURPOSE.** Diabetic macular edema (DME) is the most common cause of moderate visual disability in persons of working age in the United States. The pathogenesis of DME is poorly understood. In this study, the effect of retinal hypoxia in the development and maintenance of DME was investigated.

**METHODS.** Five patients with chronic DME despite at least one focal laser photocoagulation treatment (nine eyes) received 4 L/min of inspired oxygen by nasal cannula for 3 months. Best corrected visual acuity (VA) and retinal thickness, assessed by optical coherence tomography (OCT), were measured at baseline, during 3 months of oxygen treatment, and for 3 months after stopping oxygen.

**RESULTS.** After 3 months of oxygen therapy, nine of nine eyes with DME at baseline showed a reduction in thickness of the center of the macula. Foveal thickness (FTH) above the normal range was reduced by an average of 43.5% (range, 14%–100%), excess foveolar thickness (CEN) was reduced by an average of 42.1% (range, 13%–100%), and excess macular volume was reduced by an average of 54% (range, 35%–100%). Statistical analyses suggested that these changes were unlikely to be due to chance ( $P = 0.0077$  by Wilcoxon signed-rank test). Three eyes showed improvement in VA by at least 2 lines, one by slightly less than 2 lines, and five eyes showed no change. Three months after discontinuation of oxygen, five of the nine eyes showed increased thickening of the macula compared with when oxygen was discontinued.

**CONCLUSIONS.** Supplemental inspired oxygen may decrease macular thickness due to DME, suggesting that retinal hypoxia is involved in the development and maintenance of DME. (*Invest Ophthalmol Vis Sci.* 2004;45:617–624) DOI:10.1167/iovs.03-0557

Diabetic retinopathy is the most common cause of visual loss in persons of working age in the United States.<sup>1</sup> Severe vision loss is usually due to retinal neovascularization

(NV), and the most common cause of moderate visual disturbance is DME. This is true even though scatter laser photocoagulation provides benefit for retinal NV<sup>2</sup> and focal laser photocoagulation treatment is beneficial in patients with diabetic macular edema (DME).<sup>3</sup> Therefore, additional treatments are needed for further reduction of the high prevalence of visual morbidity caused by these conditions. To develop new treatments, it is necessary to identify targets for drug treatment by elucidating molecular mechanisms.

Several lines of evidence have suggested that retinal hypoxia (ischemia) is the basic underlying cause of retinal NV.<sup>4–13</sup> The pathogenesis of DME is not as well understood as that of retinal NV. It occurs when retinal vessels leak fluid into the macula, and the excess extracellular fluid causes the macula to become thickened. Microaneurysms (MAs) are often identified by fluorescein angiography as sites of leakage that contribute to DME. The mechanism by which MAs form is unknown, but there is evidence to suggest that high levels of VEGF predispose to MA formation,<sup>14</sup> and increased levels of VEGF in the retina are found early in the course of diabetic retinopathy.<sup>15,16</sup> VEGF is also a good candidate as a contributor to generalized leakage of the retinal vasculature, because sustained release of VEGF in the vitreous cavity causes widespread leakage from retinal vessels.<sup>17</sup>

We hypothesize that retinal hypoxia contributes to DME by release of VEGF and potentially other mediators that are capable of causing leakage. One way to begin to explore this hypothesis is to decrease retinal hypoxia in patients with DME and determine whether reduction of DME occurs. Oxygenation of the retina can be improved by increasing the concentration of inspired oxygen.<sup>18</sup> In this study, we treated patients with DME with supplemental inspired oxygen and determined the effect on visual acuity and retinal thickness assessed by optical coherence tomography (OCT).

## MATERIALS AND METHODS

### Patient Eligibility and Exclusion Criteria

Patients were required to be 18 years of age or older with clinically significant macular edema (CSME) secondary to diabetic retinopathy for at least 3 months to be considered for the study. Eligibility was limited to eyes with CSME and no evidence of epiretinal membrane or vitreous traction by biomicroscopy or OCT. Fluorescein leakage from macular blood vessels was a requirement. Previous pericardial or intravitreal injection of steroids, focal laser photocoagulation, or scatter laser photocoagulation were allowed only if performed more than 3 months before entry into the study. Other exclusion criteria were the presence of any retinal disease other than diabetic retinopathy, media opacification sufficient to interfere with evaluation of the retina, chronic hypoxemia due to lung or heart disease, anemia (hemoglobin < 8.0 g/dL), or a history of smoking within the previous 12 months. Eligible patients were referred to the principal investigator (PI; QDN), who discussed study objectives, activities, benefits, and risks, including all issues recommended by the Joint Committee on Clinical Investigations of the Johns Hopkins Medical Institutions. Informed consent was obtained for all patients who decided to partici-

From the Departments of <sup>1</sup>Ophthalmology and <sup>3</sup>Neuroscience, Johns Hopkins University School of Medicine, Baltimore, Maryland; and the <sup>2</sup>Division of Epidemiology and Clinical Research, National Eye Institute, National Institutes of Health, Bethesda, Maryland.

Presented in part at the 2002 Meeting of the American Academy of Ophthalmology, Orlando, Florida, November 2002.

Supported by Grant EY13552 and a K23 Career Development Award from the National Eye Institute (QDN). PAC is the George S. and Dolores Doré Eccles Professor of Ophthalmology and Neuroscience.

Submitted for publication June 3, 2003; revised August 12 and September 29, 2003; accepted October 27, 2003.

Disclosure: **Q.D. Nguyen**, None; **S.M. Shah**, None; **E. Van Anden**, None; **J.U. Sung**, None; **S. Vitale**, None; **P.A. Campochiaro**, None

The publication costs of this article were defrayed in part by page charge payment. This article must therefore be marked "advertisement" in accordance with 18 U.S.C. §1734 solely to indicate this fact.

Corresponding author: Peter A. Campochiaro, Maumenee 719, The Wilmer Eye Institute, The Johns Hopkins University School of Medicine, 600 North Wolfe Street, Baltimore, MD 21287-9277; pcampo@jhmi.edu.

pate in the study. If both eyes of a patient were eligible, then both eyes were included in the study. The study conformed to the provisions of the Declaration of Helsinki.

### Study Visits

At baseline and 1, 2, 3, 4, and 6 months after baseline, patients had measurement of best corrected visual acuity by Early Treatment Diabetic Retinopathy Study (ETDRS) protocol,<sup>3</sup> slit lamp biomicroscopy, measurement of macular thickness and volume by OCT, fundus photography, fluorescein angiography, measurement of oxygen saturation by pulse oximetry, serum erythropoietin (EPO), and a complete blood count. At baseline and 3 and 6 months, patients underwent measurement of hemoglobin A<sub>1c</sub> (HbA<sub>1c</sub>).

To maximize continuity and consistency, all baseline and follow-up study examinations were performed by the PI, all protocol refractions and VA measurements were performed in standard fashion by a clinical coordinator, and all OCT examinations were performed by a single investigator (SMS) masked to all other study parameters.

### Optical Coherence Tomography

Scans were performed with an OCT scanner (model 2000; Carl Zeiss Meditec, Dublin, CA) with the accompanying software (A6.1 version; Carl Zeiss Meditec), by selecting the radial scanning pattern, which performs six OCT linear scans 6 mm in length centered on the fovea at equally spaced angular orientations.<sup>19</sup> The images were automatically analyzed by the OCT computer software using the retinal mapping algorithm, which determines retinal thickness by measuring the distance between the outer and inner reflectivity band of the OCT section (Figure 1). The software samples macular thickness at 600 points, 70  $\mu\text{m}$  apart, along each of the intersecting lines and records resultant data as a false-color topographic map and as numeric averages of the measurements for each of the nine ETDRS retinal fields. Foveal thickness (FTH, in micrometers, defined as the mean height of the neurosensory retina in a central 1-mm-diameter disc; foveolar center thickness (CEN, in micrometers), defined as the mean of the six central macular measurements; and total macular volume (TMV, in cubic millimeters), were automatically computed by the OCT software and recorded.

The excess FTH, CEN, and TMV were calculated by subtracting the average normal value (based on OCT in normal eyes of patients with diabetes but no retinopathy) from the measurement at each time point. The percentage decrease in DME at month 3 was obtained by subtracting the excess at month 3 from the excess at baseline and then dividing by the excess at baseline. The percentage difference from baseline at month 6 was obtained by subtracting the excess at month 6 from the excess at baseline and then dividing by the excess at baseline. Normal values were  $179 \pm 17 \mu\text{m}$  and  $158 \pm 20 \mu\text{m}$  for FTH and CEN, respectively,<sup>20</sup> and  $6.47 \pm 0.38 \text{ mm}^3$  for TMV (Shah SM, Nguyen QD, Campochiaro PA, unpublished data, 2003). When values declined to the normal range, the excess was considered to be 0% and the percentage change to be 100%.

### Oxygen Therapy

All patients were given 4 L/min of oxygen delivered by nasal cannula. The patients were instructed to use the oxygen continuously every day for 3 months, including when sleeping, with removal of the cannula only during showers. Each patient was provided with a permanent, stationary oxygen concentrator to be used at home, as well as unlimited portable oxygen tanks (Professional Respiratory Services, Inc., Owings Mills, MD) to be used when away from home. The respiratory service returned to the homes of patients each month to check for the amount of expected usage and to refill the oxygen tank.

### Statistical Analysis

Statistical analyses of change in macular thickness and volume over time were made with the Wilcoxon signed rank test (Stata, ver. 8.0; Stata Corp., College Station, TX).

## RESULTS

### Patient Characteristics

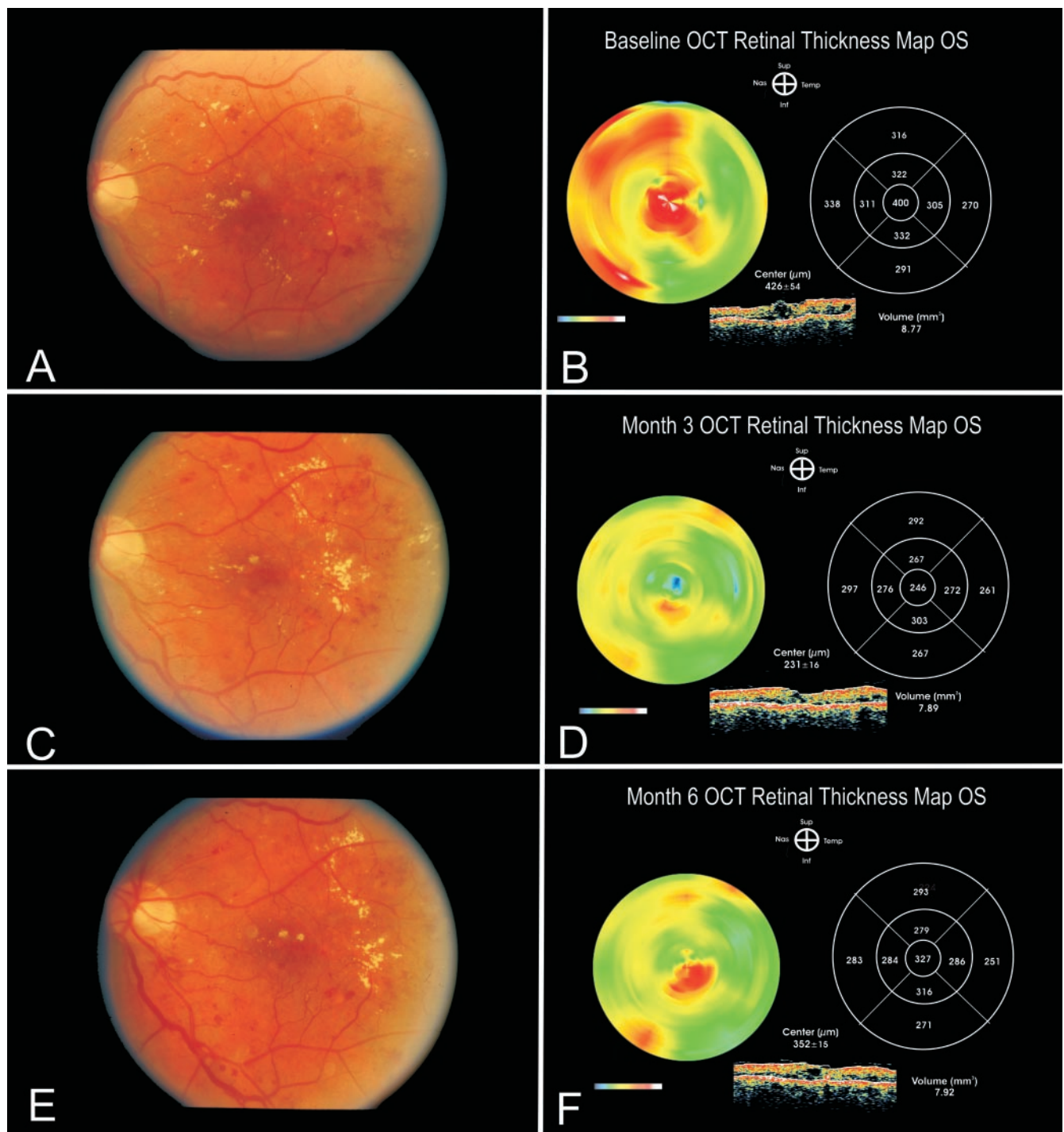
The three men and two women in the study ranged in age from 52 to 69 years and had had type 2 diabetes mellitus for an average of 9.2 years (range, 4–13; Table 1 and Supplemental Table 4, see <http://www.iovs.org/cgi/content/full/45/2/617/DC1>). All the patients had received at least one focal laser photocoagulation treatment in each eye for DME, but despite an average of 2.7 laser treatments per eye, all except one eye had persistent DME.

For both FTH and CEN, six eyes were above the normal range by 200  $\mu\text{m}$  or more (severe DME), two eyes had moderate DME with measurements 90 to 200  $\mu\text{m}$  above normal, and 1 eye had mild DME, 70 to 90  $\mu\text{m}$  above normal (Figs. 2, 3). Macular volume is an assessment of edema throughout the entire macula. Based on measurements in 19 eyes of 13 patients (age range 26–54 years) with normal retinas and no history of eye disease, the normal mean for macular volume is  $6.47 \text{ mm}^3$  (Shah SM, Nguyen QD, Campochiaro PA, unpublished data, 2003). Five of the six eyes with severe DME based on foveal and foveolar thickening, had large increases above normal in macular volume ranging from 2.30 to  $5.75 \text{ mm}^3$ , indicating diffuse edema throughout the posterior pole. The typical fundus appearance of severe diffuse DME is shown in Figure 1A (LE of patient 1), and the corresponding retinal thickness map generated by OCT shows severe thickening of the center of the macula and the areas superonasal and superotemporal to the fovea (Fig. 1B, red areas on color-coded map).

### Effect of Supplemental Oxygen on Central Macular Thickness and Macular Volume

After 3 months of supplemental oxygen, the thickening of the central macula was reduced in all nine eyes (Table 2, Figs. 2, 3). A very dramatic effect was seen in the six eyes, with severe thickening of the central macula at baseline, in which the average decrease in foveal and foveolar thickening was 130.5  $\mu\text{m}$  (range, 42–308) and 142.3  $\mu\text{m}$  (range, 45–318), respectively. Figure 1 shows an example of this dramatic effect. The reproducibility of OCT measurements is high, and within a 95% confidence interval, changes of more than 42  $\mu\text{m}$  in FTH or 54  $\mu\text{m}$  in CEN are unlikely to be due to random variation.<sup>21</sup> The two eyes with moderate thickening at baseline (RE and LE of patient 5) showed a smaller decrease in foveal (46 and 61  $\mu\text{m}$ , respectively) and foveolar thickening (56 and 68  $\mu\text{m}$ , respectively). The one eye with mild central thickening at baseline (RE of patient 3), showed 11- and 10- $\mu\text{m}$  decreases in foveal and foveolar thickening. The six eyes that had severe diffuse DME, all showed substantial decreases in TMV (Fig. 4) with an average decrease of 1.48  $\text{mm}^3$  (range, 0.21 to 2.65). The three eyes with mild and moderate diffuse DME at baseline (RE of patient 3 and both eyes of patient 5), also showed improvement, and although the absolute decline was modest, it represented a large proportion of the excess volume. One of these 3 eyes (RE of patient 3) had a decrease in macular volume of only 0.30  $\text{mm}^3$ , but it represented 100% of the excess macular volume, indicating complete resolution of DME.

The percentage decrease in excess central macular thickening or macular volume takes into account the starting point and provides a measure of how much of the edema has resolved. After 3 months of supplemental oxygen, the average decrease in excess FTH, CEN, and TMV in the nine eyes with DME at baseline was 43.5% (range, 14%–100%), 42.1% (13%–100%), and 54.0% (35%–100%), respectively. The likelihood that each of these three measurements would change in the same direction by these magnitudes by chance is very small ( $P = 0.0077$  by Wilcoxon signed rank test).



**FIGURE 1.** Fundus appearance and retinal thickness map of the left eye of patient 1 at baseline (A, B), after 3 months of treatment with oxygen (C, D), and 3 months after withdrawal of oxygen (E, F). At baseline, the fundus showed scattered hemorrhages and exudates (A), and the retinal thickness map generated by OCT (B) showed severe thickening throughout the macula. The thickest areas of retina, corresponding to the red areas on the color-coded map are in the center of the macula, supero- and inferonasally. The cross-section showed a large cyst in the center of the macula. After 3 months of oxygen, there was an increase in exudates in the temporal part of the macula (C). As interstitial fluid is resorbed, serum proteins tend to precipitate. Thus, it is common for exudates to increase during the initial stages of resolution of edema. The color-coded map showed a marked decrease in red area, indicating substantial decrease in macular thickening, and the cross-section showed a decrease in the size of the cyst in the center of the macula (D). Three months after withdrawal of oxygen, there was little change in the appearance of the retina (E), but the retinal thickness map showed worsening of the edema (F). Note the reappearance of red in the center of the color-coded map and the increase in the size of the foveal cyst in the cross-section. Color scale: blue, thinnest; red, thickest.

Three months after oxygen was discontinued, five of nine eyes showed increases in CEN and TMV (Table 2, Figs. 2-4). All these eyes had had severe DME at baseline. The left eye of

patient 1 is a typical example of severe DME that improved during oxygen treatment and then worsened after cessation of oxygen (Fig. 1). The eye with mild DME at baseline, the two

TABLE 1. Clinical Histories of Study Patients

Patient	Age	Gender	Type and Years of Diabetes	Years and Severity of DR	Years and Severity of CSME	Previous Focal Laser Treatments and Months Since Last Laser
1 RE	55	M	Type 2, 11	8, Severe NPDR	6, Severe	3, 4
1 LE				8, Severe NPDR	5, Severe	3, 4
2 RE	62	M	Type 2, 13	10, PDR	6, Severe	2, 5
2 LE				10, Moderate NPDR	8, Severe	4, 4
3 RE	52	F	Type 2, 12	8, Moderate NPDR	5, Mild	3, 6
3 LE				8, Moderate NPDR	7, Moderate	4, 4
4 RE	69	M	Type 2, 6	5, Moderate NPDR	3, Severe	1, 4
4 LE				5, Moderate NPDR	3, Resolved	3, 6
5 RE	66	F	Type 2, 4	3, Moderate NPDR	2, Moderate	2, 4
5 LE				3, Moderate NPDR	2, Moderate	2, 4

Severity of diabetic retinopathy (DR) is based on criteria established in the ETDRS,<sup>3</sup> with nonproliferative diabetic retinopathy (NPDR), classified as moderate or severe, and proliferative diabetic retinopathy (PDR). The severity of clinically significant macular edema (CSME) is based on assessment by biomicroscopy with contact lens.

eyes with moderate DME at baseline, and one of the eyes with severe DME remained stable, despite cessation of oxygen.

**Effect of Supplemental Oxygen on Visual Acuity**

Table 3 shows the best corrected visual acuity measurements at baseline, after 3 months of supplemental oxygen and an additional 3 months without. After 3 months of oxygen, four eyes showed more than 1 line of improvement in vision, and three of the four showed roughly a halving of the visual angle,

a commonly used end point for identification of visual improvement in clinical trials. Four of the eyes showed no change in visual acuity. One eye was 20/32 at baseline, 20/40 after 3 months of oxygen, and 20/25 after an additional 3 months without oxygen. This is unlikely to represent a true change in visual acuity while receiving oxygen, because it was less than 1 line and was present on only one measurement. The one eye that lacked DME at baseline showed a decrease of 1 line in visual acuity after 3 months of oxygen, but experienced an

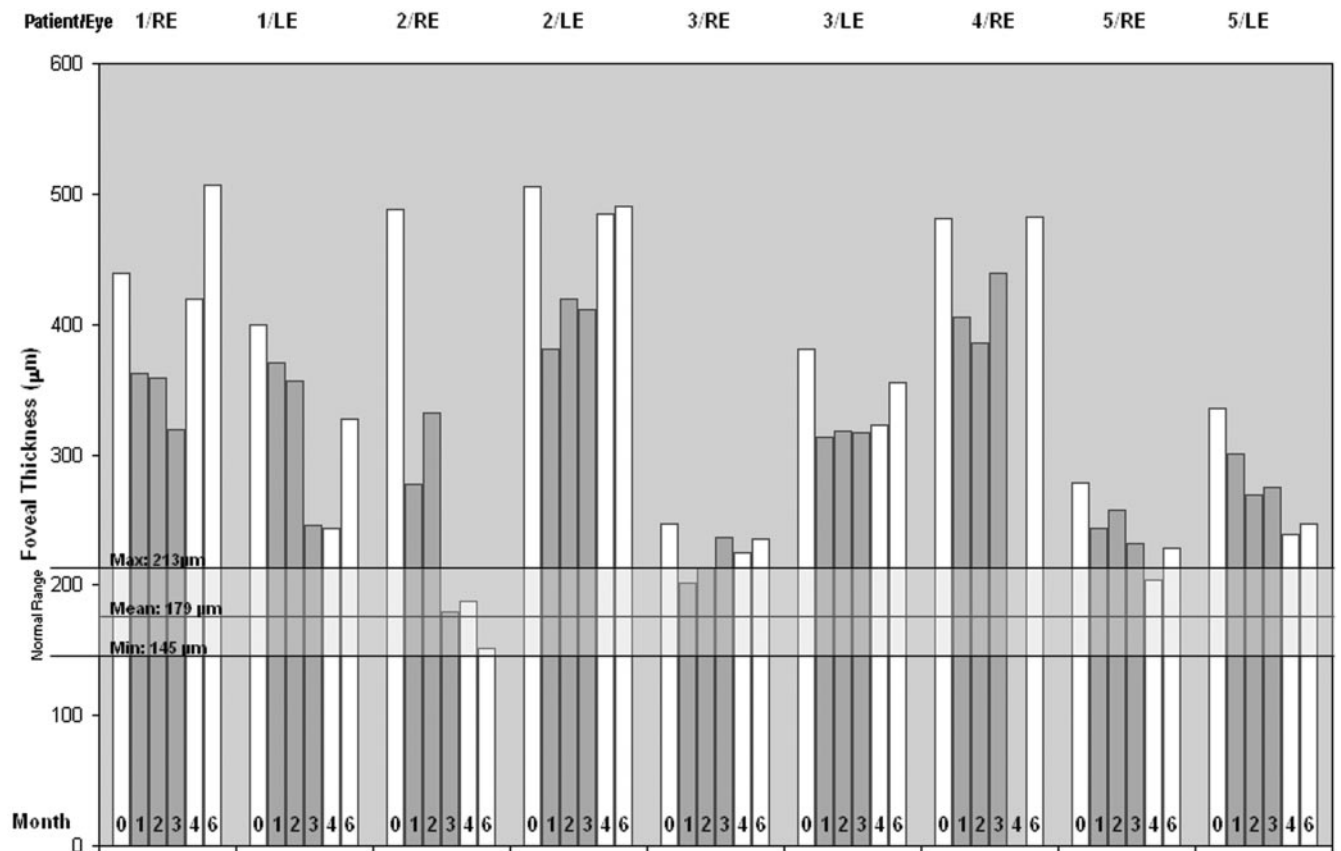


FIGURE 2. The effect of supplemental oxygen on FTH. OCT was performed at baseline, during the 3 months of treatment with oxygen and for an additional 3 months after withdrawal of oxygen. The measurements for FTH at baseline and at months 1, 2, 3, 4, and 6 are plotted. (□) Baseline and months 4 and 6 represent periods when the patients were not receiving oxygen; (■) months 1, 2, and 3, denote periods when the patients were receiving oxygen. The normal FTH for patients with diabetes but no retinopathy was 179 ± 17 µm. The maximum and minimum values represent two standard deviations above and below the mean value. Patient 4 had a vitreous hemorrhage in the right eye during the month-4 visit; thus, no OCT measurement was obtained (no data shown).

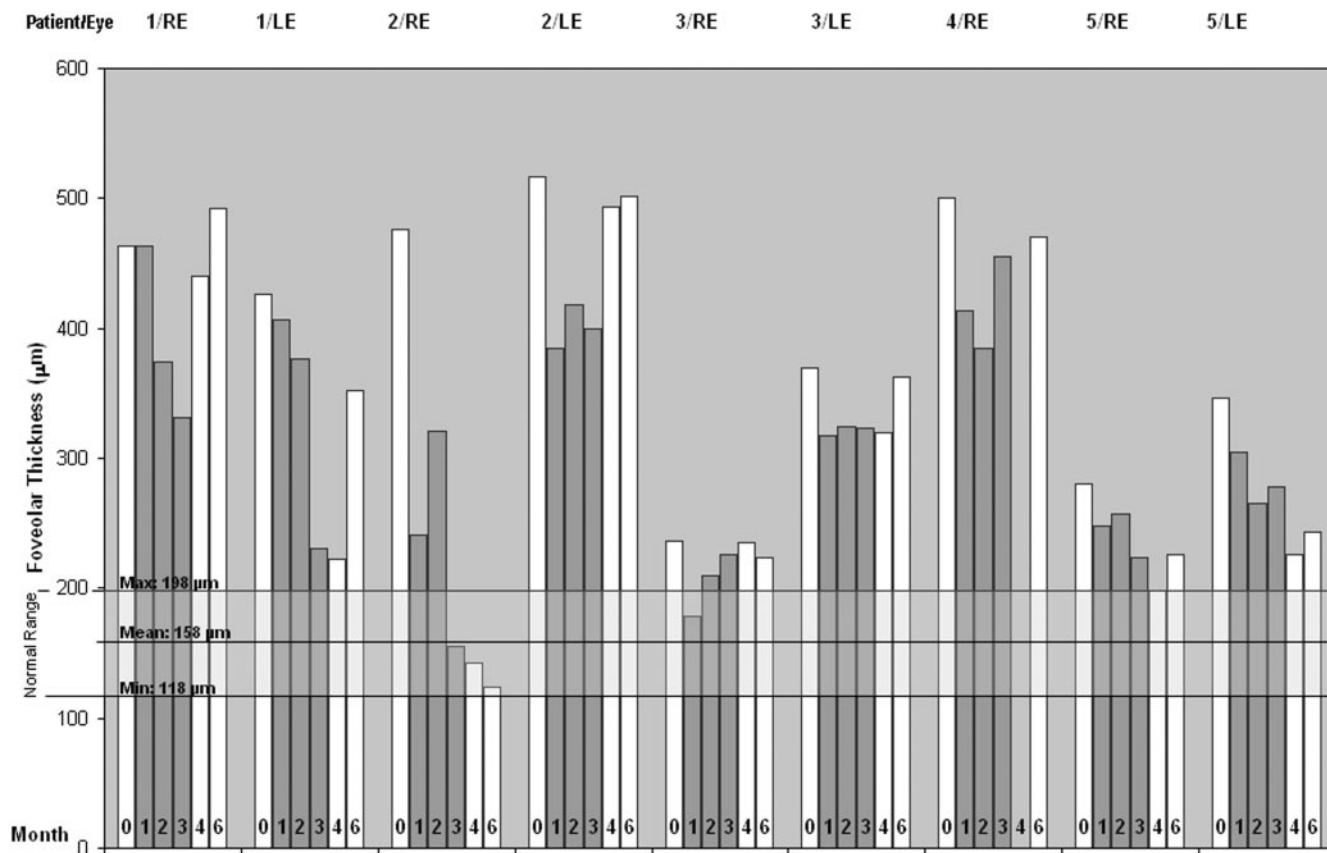


FIGURE 3. The effect of supplemental oxygen on CEN. OCT measurements were performed at the time points described in Figure 2. (□) Baseline and months 4 and 6, represent periods when the patients were not on oxygen; (■) months 1, 2, and 3, denote periods when the patients were receiving oxygen. The normal CEN for patients with diabetes but no retinopathy was 158 ± 20 µm. Mean, maximum, minimum values and the explanation of absence of data for patient 4 (RE) are as described in Figure 2.

additional decrease after oxygen was stopped, and therefore it is unlikely that the change in vision was due to oxygen.

**Assessment of Oxygenation**

Oxygen saturation measured by pulse oximetry was fairly high in all the patients at baseline (94%, 97%, 99%, 99%, and 100%). All patients had oxygen saturation of 100% while receiving supplemental oxygen. At 6 months, 4 of the patients had 98% saturation and one had 96% (Supplemental Table 5, see <http://www.iovs.org/cgi/content/full/45/2/617/DC1>). Erythropoietin (EPO) is a hypoxia-regulated gene and EPO levels are increased by chronic hypoxemia. EPO levels were measured to

determine whether they might be decreased by supplemental oxygen and thereby serve as a means to assess compliance; however, there was no consistent pattern of variation in EPO levels, and they were judged to not be useful (data not shown).

**Glycemic Control during Study**

Changes in glycemic control can affect diabetic retinopathy; therefore, we monitored HbA1C levels throughout the study. There were no substantial changes in HbA1C in four of the five patients during the study (Supplemental Table 6, see <http://www.iovs.org/cgi/content/full/45/2/617/DC1>). Patient 3 had an increase in HbA1C from 8.0% at baseline to 9.2% at 3 months.

TABLE 2. FTH, CEN, and TMV Measurements by OCT

Patient	Baseline	Month 1	Month 2	Month 3	Month 4	Month 6
1 RE	439/463/12.22	362/374/11.57	359/366/11.49	319/331/10.19	420/440/12.56	507/492/12.64
LE	400/426/8.77	370/407/8.80	357/377/8.58	246/231/7.89	244/222/8.04	327/352/7.92
2 RE	488/476/9.99	277/241/8.17	332/321/8.23	180/155/7.34	187/143/7.25	152/124/7.09
LE	506/517/9.60	381/384/6.88	419/418/9.03	411/400/8.12	485/494/8.92	491/501/9.08
3 RE	247/236/6.77	202/178/6.18	213/210/6.03	236/226/6.26	225/235/6.18	235/224/6.29
LE	381/370/6.78	313/317/6.43	318/324/6.47	317/323/6.57	323/320/6.79	355/363/6.78
4 RE	481/500/10.51	405/414/8.58	386/385/9.01	439/455/8.88	VH	482/470/10.50
LE	N/A, no DME					
5 RE	278/280/7.59	243/248/7.20	258/257/6.75	232/224/7.07	204/198/7.17	228/226/7.04
LE	336/346/9.74	301/305/9.10	269/265/8.63	275/278/8.52	239/226/8.56	247/243/8.32

Data are presented as the FTH/CEN/TMV determined by OCT. FTH and CEN are in micrometers, and TMV is in cubic millimeters. Patients had OCT measurements on each eye at baseline and at months 1, 2, and 3 while receiving supplemental oxygen, and at months 4 and 6 after withdrawal of oxygen. The FTH, CEN, and TMV were automatically computed by the OCT software. VH, vitreous hemorrhage; N/A, not applicable.

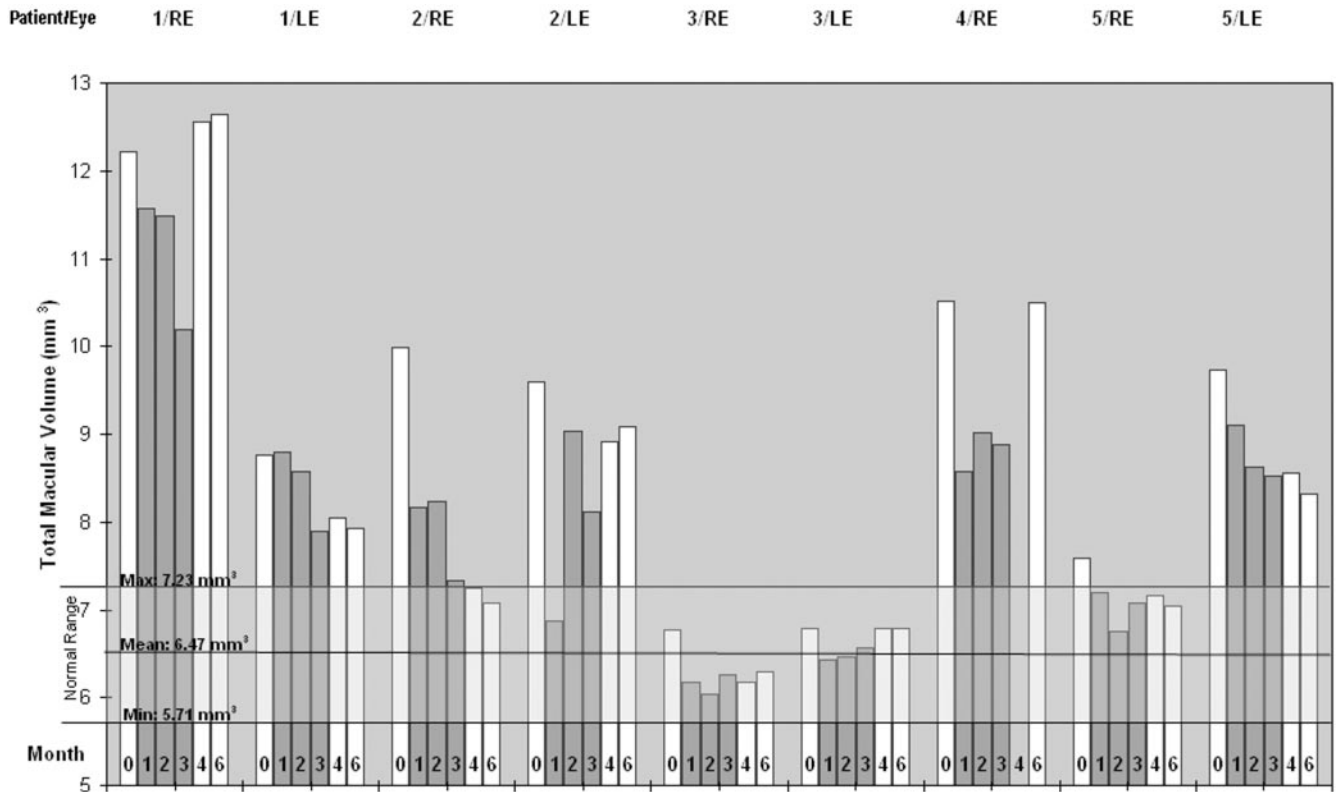


FIGURE 4. The effect of supplemental oxygen on TMV. OCT measurements were performed at the time points described in Figure 2. (□) Baseline and months 4 and 6, represent periods when the patients were not on oxygen; (■) months 1, 2, and 3, denote periods when the patients were receiving oxygen. The normal TMV for patients with diabetes but no retinopathy was  $6.47 \pm 0.38 \mu\text{m}$ . Mean, maximum, minimum values and the explanation of absence of data for patient 4 (RE) are as described in Figure 2.

Worsening of glycemic control is not likely to cause improvement in DME and thus is unlikely to affect our results. Insulin treatment was modified, in consultation with the patient's primary physician, and the patient was referred to nutritional services.

Additional systemic and ophthalmic data for the patients are listed in Supplemental Table 4, which is available online at <http://www.iovs.org/cgi/content/full/45/2/617/DC1>.

## DISCUSSION

In this study, we explored whether hypoxia contributes to the pathogenesis of DME by observing the effect of reducing retinal hypoxia. All eyes with DME showed reduction in

thickening of the center of the macula and reduction in macular volume measured by OCT. Four of the nine eyes showed large decreases of more than  $90 \mu\text{m}$  in foveal and foveolar thickening. In the other five eyes, there was less thickening at baseline and correspondingly less reduction in thickening. A useful way to assess the response is to determine the amount of reduction in excess thickening (i.e., thickening above the normal cutoff point). There were decreases in excess FTH of 43.5%, excess CEN of 42.1%, and excess TMV of 54.0%. Therefore, three different measures of macular edema demonstrated very similar levels of improvement due to supplemental oxygen.

TABLE 3. Effect of Supplemental Oxygen on Visual Acuity

Patient	Baseline	Month 3	Month 6	Improvement with O <sub>2</sub>
1 RE	20/50	20/50	20/50	No
1 LE	20/50	20/32	20/40	Yes
2 RE	20/160	20/80	20/64	Yes
2 LE	20/50	20/50	20/50	No
3 RE	20/32	20/40	20/25	No
3 LE	20/50	20/50	20/40	No
4 RE	20/64	20/64	20/64	No
4 LE	20/80	20/100	20/160	N/A, no DME
5 RE	20/250	20/126	20/200	Yes
5 LE	20/126	20/80	20/126	Yes

Best corrected visual acuity was measured using charts and procedures employed in the ETDRS. Visual acuities are recorded for the LE of patient 4, but they are not applicable (N/A) for determination of effect of O<sub>2</sub> on macular edema-induced visual loss, because the LE did not have diabetic macular edema (DME). The mild decrease in vision was judged to be due to fibrotic changes in the fovea from chronic macular edema and possibly from focal laser treatments.

If improved oxygenation of the retina due to supplemental oxygen were the cause for the improvement in DME, it would be expected that discontinuation of oxygen would result in return of hypoxia and gradual loss of the beneficial effect. Five of nine eyes that showed decreased macular thickening after 3 months of supplemental oxygen showed increased thickening by 3 months after stopping oxygen. Each of the four eyes that remained stable for 3 months after stopping oxygen had relatively mild macular edema at the end of the oxygen treatment period: One had improved into the normal range, 2 were very close to normal (232 and 236  $\mu\text{m}$ ), and the fourth had FTH of 275  $\mu\text{m}$ . Only one of the five eyes that worsened after stopping oxygen had improved to an FTH less than 300  $\mu\text{m}$  during the period of oxygen treatment, and it remained stable for the first month after oxygen treatment and then deteriorated (Fig. 2).

It is likely that edema exacerbates retinal hypoxia by increasing the distance that oxygen from the choroid must diffuse to compensate for poor oxygen delivery to the inner retina from compromised retinal vessels. A reasonable hypothesis that could explain our observation of prolonged benefit (of at least 3 months) in retinas that achieved near-normal thickness is that improved oxygenation may allow an escape from a vicious cycle brought on by the combination of hypoxia and edema. If thickening is near normal when oxygen is stopped, then oxygenation from the choroid may be sufficient to compensate for decreased retinal vascular perfusion, at least for a time. It should be noted that each of the eyes that remained stable had had at least two focal laser treatments. One hypothesis regarding the mechanism of focal laser is that it destroys photoreceptors, the biggest consumers of oxygen in the retina, thereby decreasing oxygen consumption by the outer retina, which allows more oxygen from choroidal vessels to reach the inner retina and compensate for decreased retinal perfusion. Sustained benefit in eyes previously treated with focal laser that achieved near normal macular thickness during supplemental oxygen treatment is consistent with this hypothesis. Perhaps severe thickening promotes a refractory response to focal laser, because despite decreased consumption of oxygen from the choroid by the outer retina, the oxygen cannot diffuse all the way through the thickened retina and alleviate hypoxia in the inner retina, and that may be the driving force of the edema. By alleviating hypoxia, supplemental oxygen may allow improvement in macular thickness, and if thickness decreases below a critical point, then the benefits from focal laser photocoagulation alone may be realized, resulting in stability despite cessation of oxygen. Longer follow-up of patients with sustained benefit 3 months after stopping oxygen will help to provide evidence for or against this hypothesis. If further evidence supports our hypothesis, then supplemental oxygen may be more than simply a useful tool for exploring the role of hypoxia in the genesis and maintenance of DME. It may also be an important addition to our treatments for DME.

Four of nine eyes with DME showed improvement in visual acuity after 3 months of supplemental oxygen. Although a modest improvement in visual acuity in four of nine patients would be weak evidence of a supplemental oxygen-induced effect on its own and would be meaningless without controls, when combined with the observation that nine of nine patients showed a substantial decrease in macular thickening and volume, this hint of a functional effect takes on added significance. It is reasonable to expect that improvement in vision would lag behind decreased macular thickness, and 3 months may not be sufficient to achieve improved vision in all eyes. Furthermore, chronic edema

results in permanent visual loss, and lost vision is rarely regained after successful focal laser photocoagulation treatment.<sup>3</sup> Therefore, additional studies are needed to test longer-duration oxygen treatment in patients with chronic macular edema, as well as patients with recent-onset macular edema who are less likely to have irreversible vision loss, to better assess the potential for supplemental oxygen-induced visual benefit in patients with DME.

In this era of multicenter, randomized, placebo-controlled clinical trials, there is a tendency to view uncontrolled interventional case studies with skepticism. Skepticism is appropriate when evaluating small pilot trials, but the value of such uncontrolled preliminary studies should not be underestimated. This study shows a consistent oxygen-induced effect that is unlikely to be due to chance. Although it is important to confirm the results with a controlled trial, which has been initiated, it will take more than a year to complete such a study. In the meantime, we hope that the scientific community will examine our results in the five patients reported herein, consider their implications, and find new ways to test our theory that hypoxia plays a critical role in the development and maintenance of DME.

## References

1. Klein R. Retinopathy in a population-based study. *Trans Am Ophthalmol Soc.* 1992;90:561-594.
2. The Diabetic Retinopathy Study Research Group. Photocoagulation treatment of proliferative diabetic retinopathy: clinical application of Diabetic Retinopathy Study (DRS) findings. DRS Report Number 8. *Ophthalmology.* 1981; 88:583-600.
3. The Early Treatment Diabetic Retinopathy Study Research Group. Photocoagulation for diabetic macular edema. ETDRS report number 1. *Arch Ophthalmol.* 1985; 103:1796-1806.
4. Adamis A, Miller J, Bernal M, et al. Increased vascular endothelial growth factor levels in the vitreous of eyes with proliferative diabetic retinopathy. *Am J Ophthalmol.* 1994;118:445-450.
5. Aiello L, Avery R, Arrigg P, et al. Vascular endothelial growth factor in ocular fluid of patients with diabetic retinopathy and other retinal disorders. *N Engl J Med.* 1994;331:1480-1487.
6. Malecaze F, Clamens S, Simorre-Pinatel V, et al. Detection of vascular endothelial growth factor messenger RNA and vascular endothelial growth factor-like activity in proliferative diabetic retinopathy. *Arch Ophthalmol.* 1994;112:1476-1482.
7. Pe'er J, Shweiki D, Itin A, et al. Hypoxia-induced expression of vascular endothelial growth factor by retinal cells is a common factor neovascularizing ocular diseases. *Lab Invest.* 1995;72:638-645.
8. Okamoto N, Tobe T, Hackett S, et al. Transgenic mice with increased expression of vascular endothelial growth factor in the retina: a new model of intraretinal and subretinal neovascularization. *Am J Pathol.* 1997;151:281-291.
9. Aiello L, Pierce E, Foley E, et al. Suppression of retinal neovascularization in vivo by inhibition of vascular endothelial growth factor (VEGF) using soluble VEGF-receptor chimeric proteins. *Proc Natl Acad Sci USA.* 1995;92:10457-10461.
10. Robinson G, Pierce E, Rook S, et al. Oligodeoxynucleotides inhibit retinal neovascularization in a murine model of proliferative retinopathy. *Proc Natl Acad Sci USA.* 1996;93:4851-4856.
11. Adamis A, Shima D, Tolentino M, et al. Inhibition of vascular endothelial growth factor prevents retinal ischemia-associated iris neovascularization. *Arch Ophthalmol.* 1996;114:66-71.
12. Seo M, Kwak N, Ozaki H, et al. Dramatic inhibition of retinal and choroidal neovascularization by oral administration of a kinase inhibitor. *Am J Pathol.* 1999;154:1743-1753.
13. Ozaki H, Seo M, Ozaki K, et al. Blockade of vascular endothelial cell growth factor receptor signaling is sufficient to completely prevent retinal neovascularization. *Am J Pathol.* 2000;156:679-707.
14. Tolentino M, Miller J, Gragoudas E, et al. Intravitreal injections of vascular endothelial growth factor produce retinal ischemia and

- microangiopathy in an adult primate. *Ophthalmology*. 1996;103:1820-1828.
15. Litty G, McLeod D, Merges C, et al. Localization of vascular endothelial growth factor in human retina and choroid. *Arch Ophthalmol*. 1996;114:971-977.
  16. Viores S, Chan C, Viores M, et al. Increased vascular endothelial growth factor (VEGF) and transforming growth factor beta (TGFbeta) in experimental autoimmune uveoretinitis: upregulation of VEGF without neovascularization. *J Neuroimmunol*. 1998;89:43-50.
  17. Ozaki H, Hayashi H, Viores S, et al. Intravitreal sustained release of VEGF causes retinal neovascularization in rabbits and breakdown of the blood-retinal barrier in rabbits and primates. *Exp Eye Res*. 1997;64:505-517.
  18. Linsenmeier R, Yancey C. Effects of hyperoxia on the oxygen distribution in the intact cat retina. *Invest Ophthalmol Vis Sci*. 1989;30:612-618.
  19. Polito A, Shah S, Haller J, et al. Comparison between retinal thickness analyzer and optical coherence tomography for assessment of foveal thickness in eyes with macular disease. *Am J Ophthalmol*. 2002;134:240-251.
  20. Hee M, Puliafito C, Duker J, et al. Topography of diabetic macular edema with optical coherence tomography. *Ophthalmology*. 1998;105:360-370.
  21. Massin P, Vicaute E, Haouchine B, et al. Reproducibility of retinal mapping using optical coherence tomography. *Arch Ophthalmol*. 2001;119:1135-1142.