

Simultaneous but Not Prior Inhibition of VEGF165 Enhances the Efficacy of Photodynamic Therapy in Multiple Models of Ocular Neovascularization

Meihua Ju,¹ Carolina Mailhos,¹ John Bradley,¹ Tracy Dowie,¹ Mary Ganley,¹ Gary Cook,¹ Perry Calias,¹ Norbert Lange,² Anthony P. Adamis,¹ David T. Shima,¹ and Gregory S. Robinson¹

PURPOSE. To investigate the effect of the combined treatment of photodynamic therapy and specific VEGF165 inhibition with pegaptanib sodium (Macugen; Eyetech Pharmaceuticals, Lexington, MA) on ocular neovascularization.

METHODS. Photodynamic therapy's (PDT's) effects on the integrity of pegaptanib sodium were analyzed by HPLC, a VEGF165-binding assay, and a VEGF165-induced tissue factor gene expression assay. The effects of mono- or combined treatment on vessel growth and regression were determined in a murine corneal neovascularization model. The effects of combined treatment on vessel growth were also determined in a murine choroidal neovascularization model.

RESULTS. PDT did not affect the chemical composition of pegaptanib sodium nor the efficacy of pegaptanib sodium in the inhibition of VEGF165 binding to Flt-1 and VEGF165-induced gene expression. In an animal model of effects on existing ocular neovascular lesions (corneal neovascularization), PDT monotherapy yielded an initial regression of these vessels, but there followed a rapid regrowth. In contrast, pegaptanib sodium monotherapy yielded little regression but potently abrogated further vessel growth. The combination of pegaptanib sodium and PDT resulted in the regression of the neovascular lesions, as observed with PDT alone, but also prevented significant vessel regrowth, leading to a significantly greater reduction in lesion size than did each monotherapy. In addition, there was a significantly greater effect of the combination of pegaptanib sodium and PDT on lesion size in choroidal neovascularization than with each monotherapy. Pretreatment with pegaptanib sodium appeared to decrease the efficacy of PDT-induced vessel regression in corneal neovascularization, and as such the enhanced efficacy over monotherapy when the agents were delivered simultaneously was not observed.

CONCLUSIONS. Although the combined simultaneous treatment of ocular neovascularization with PDT and pegaptanib sodium may provide a more effective approach for the regression and

overall treatment of CNV associated with AMD, the order of addition of these treatments may play a role in achieving optimal efficacy. (*Invest Ophthalmol Vis Sci.* 2008;49:662-670) DOI:10.1167/iovs.07-0195

Age-related macular degeneration (AMD) is the leading cause of blindness in individuals over 50 years of age in the United States and Europe.¹⁻³ Two distinct forms of AMD have been identified: nonexudative, or dry, AMD and exudative, or wet, AMD. Although less frequent (10%-20% of all cases), wet AMD has a dramatic impact on visual acuity and in most cases occurs secondary to the development of choroidal neovascularization (CNV) in the macular region. Choroidal neovessels that break through Bruch's membrane and traverse the subretinal space are highly permeable producing an accumulation of fluids and causing both mechanical and cellular damage to the outer retina.⁴

Currently, there is a limited number of approved treatments for wet AMD, including photodynamic therapy (PDT)⁵ and the local inhibition of vascular endothelial growth factor A (VEGF-A).⁶⁻⁸ Since 2001, photodynamic therapy has been the standard of care for the treatment of patients with CNV secondary to AMD.⁹⁻¹¹ In verteporfin-mediated PDT, the photosensitizer is applied intravenously, followed by irradiation of the treated area with nonthermal light ($\lambda = 689$ nm). The activation of the photosensitizer leads to the local production of reactive oxygen species that trigger vascular occlusion through a complex cascade of molecular, cellular, and physiological events. Because of the predominantly vascular localization of the photosensitizer directly after administration, collateral damage to neighboring tissues is not extensive.¹¹ PDT is effective primarily in patients with predominantly classic CNV where it has been shown to stabilize or slow vision loss by significantly reducing CNV growth and vascular leakage. However, PDT has no beneficial effect in patients with purely occult CNV.¹² Furthermore, the increased expression of VEGF-A and the decreased expression of pigment epithelium-derived factor (PEDF) after PDT may be responsible for the recurrence of CNV, necessitating multiple retreatments and thus the increased potential risk of serious adverse side effects.¹³

A recently approved treatment for CNV is the local inhibition of VEGF-A.⁶⁻⁸ VEGF-A is involved in the development and growth of CNV and functions as a potent growth factor as well as a potent vascular permeability agent.^{14,15} VEGF-A expression is upregulated in ocular samples from patients with AMD as well as from experimental animal models of CNV.^{16,17} Moreover, administration of VEGF-A can induce experimental CNV in animals.¹⁸ Inhibiting VEGF-A in the subretinal space has been shown to delay, and even cause regression of, the pathogenesis observed with AMD.^{6,8} Two drugs that inhibit the activity of VEGF-A have recently been approved for the treatment of AMD, Macugen (pegaptanib sodium injection), a function-blocking aptamer, and Lucentis (ranibizumab injection; Genentech, South San Francisco, CA), a function-blocking antibody.^{6,19} The active moiety of Macugen is an aptamer, a

From ¹(OSI) Eyetech Pharmaceuticals, Farmingdale, New York; and the ²Laboratory of Pharmaceutics and Biopharmaceutics, Section of Pharmaceutical Sciences, University of Geneva, Geneva, Switzerland.

Submitted for publication February 14, 2007; revised August 10 and October 1, 2007; accepted December 14, 2007.

Disclosure: **M. Ju**, (OSI) Eyetech Pharmaceuticals (E); **C. Mailhos**, (OSI) Eyetech Pharmaceuticals (E); **J. Bradley**, (OSI) Eyetech Pharmaceuticals (E); **T. Dowie**, (OSI) Eyetech Pharmaceuticals (E); **M. Ganley**, (OSI) Eyetech Pharmaceuticals (E); **G. Cook**, (OSI) Eyetech Pharmaceuticals (E); **P. Calias**, (OSI) Eyetech Pharmaceuticals (E); **N. Lange**, None; **A.P. Adamis**, (OSI) Eyetech Pharmaceuticals (E); **D.T. Shima**, (OSI) Eyetech Pharmaceuticals (E); **G.S. Robinson**, (OSI) Eyetech Pharmaceuticals (E)

The publication costs of this article were defrayed in part by page charge payment. This article must therefore be marked "advertisement" in accordance with 18 U.S.C. §1734 solely to indicate this fact.

Corresponding author: Gregory S. Robinson, Shire HGT, 700 Main Street, Cambridge, MA 02139; grobinson@shire.com.

pegylated synthetic RNA-based oligonucleotide composed of 28 nucleotide bases. Pegaptanib binds to the major pathogenic isoform of VEGF-A VEGF165 with high specificity and affinity, inhibiting the binding of VEGF165 to the cellular receptors, VEGFR-1 and -2.²⁰ The active component of Lucentis is ranibizumab, a humanized Fab antibody fragment that binds and inhibits the activity of all VEGF-A isoforms. The ability of Macugen and Lucentis to inhibit the activity of VEGF-A and halt the progression of all subtypes of AMD provides strong evidence of VEGF-A's pivotal role in this pathologic condition.

PDT is effective in only specific subtypes of AMD, and the initial reduction in CNV is followed by vessel regrowth believed to result from the release of VEGF-A as a result of hypoxia.²¹ As pegaptanib sodium selectively inhibits the action of VEGF165 and halts the progression of neovascularization in animal models and in patients with AMD, we reasoned that a combination of PDT and pegaptanib sodium would improve the procedure's efficacy by reducing neovascular lesion size as well as by preventing its regrowth. Using a corneal neovascularization model, we found enhanced efficacy of combination treatment of pegaptanib sodium and PDT when administered simultaneously. However, the enhanced efficacy of combination treatment was not maintained when pegaptanib sodium was administered before PDT. Finally, the enhanced efficacy we observed with combination treatment delivered simultaneously, was also observed in a choroidal neovascularization model, another model of ocular neovascularization used to represent AMD. Together, these data reveal that an effective combined treatment regimen may provide a safe and more beneficial option in the clinical setting.

MATERIALS AND METHODS

Laser Irradiation In Vitro

A stock solution of Visudyne (verteporfin for injection; BPD-MA; purchased from Michel Sickenberg, Lausanne, Switzerland; 1 mg/mL in PBS) was prepared and kept in the dark until use. A stock solution of pegaptanib sodium (10 mM; EYE001, Eyetech Pharmaceuticals, Lexington, MA) was mixed with verteporfin (Visudyne; Novartis, Basel, Switzerland) in either PBS or PBS containing fetal calf serum (10%), such that the final concentration of pegaptanib sodium was 10 μ M and of verteporfin was 1 μ g/mL. Samples were irradiated through an optical fiber-based light distributor (FD1; Medlight SA, Renens, Switzerland) at a rate of 200 mW/cm² with a light dose of 50 J/cm² at 689 nm (Ceramopectec, Bonn, Germany).

HPLC Analysis

The chromatographic purity of pegaptanib sodium was determined by HPLC using both anion exchange and reversed-phase methods. For anion exchange analysis, an HPLC system (A1100; Agilent, Palo Alto, CA) was used, operated at 80°C with an analytical column (DNA Pac PA-100 column; 4.6 \times 250 mm; Dionex Corp., Sunnyvale, CA) and a variable-wavelength UV detector with collection at 260 nm. Mobile phase A consisted of 1% acetonitrile and 10 mM Tris (pH 8), and mobile phase B consisted of 1% acetonitrile, 10 mM Tris, 1 M ammonium chloride (pH 8). A multistep gradient (0%–40% B in 21 minutes, 54% B at 30 minutes, and 80% B at 43 minutes) and a flow rate of 1.5 mL/min were used. For reversed-phase analysis, a separation module (Alliance 2695; Waters, Milford, MA) was used, operated at 30°C with a PRP-1 column (4.6 \times 250 mm, 10 μ m; Hamilton Co., Reno, NV), and a photodiode array detector (2996; Waters) with data extracted at 260 nm. Mobile phase A was an aqueous solution of triethylammonium acetate, whereas mobile phase B was 100% acetonitrile. Gradient conditions (5%–70% B in 40 minutes) and a flow rate of 1 mL/min were used in the analysis. All chromatograms were acquired and processed by the system software (Empower; Waters). The concentration of pegaptanib sodium was determined based on a calibration curve from 25 to 500 μ g/mL ($R^2 = 0.9974$).

Tissue Factor Assay

Tissue factor mRNA expression was determined in low-passage human umbilical vein endothelial cells (HUVECs, <3 passages; Cascade Biologics, Portland, OR) that were plated at a density of 3.0×10^5 cells/well and cultured overnight in complete medium (Medium 200 supplemented with low serum growth supplement; Cascade Biologics). The cells were then serum starved for 4 hours before a 1-hour treatment with either human VEGF165 (12.5 ng/mL; Peprotech, Rocky Hill, NJ) or VEGF165 and pegaptanib sodium (10 nM). RNA was extracted, and quantitative fluorogenic PCR performed (7700 Sequence Detection System; Applied Biosystems, Inc. [ABI], Foster City, CA).

Flt-1 Binding Assay

Binding of VEGF165 to Flt-1 was determined by using I¹²⁵VEGF165 (GE Healthcare, Piscataway, NJ). The 96-well plates were coated with anti-human IgG1 Fc fragment-specific antibody (R&D Systems, Minneapolis, MN) and after block of nonspecific sites (Super Block buffer; Pierce, Rockford IL), chimeric human Flt-1/Fc receptor (R&D Systems, Inc.) in binding buffer (PBS with 1 mM calcium chloride, 1 mM magnesium chloride, and 0.01% HSA [pH 7.4]) was added for 2 hours. A set of 10 fivefold dilutions of pegaptanib sodium were mixed with 0.01 μ Ci I¹²⁵VEGF165 in binding buffer. After incubation (15 minutes), the samples were added to wells of the receptor-coated plate for 2 to 3 hours. Wells were then washed four times with binding buffer. Bound I¹²⁵VEGF165 was solubilized and quantified. Background counts (solubilization buffer only) were subtracted from all samples and then I¹²⁵VEGF165: receptor binding ratios were expressed relative to the binding of just I¹²⁵VEGF165 in the absence of pegaptanib. All data points were analyzed with nonlinear regression (one site competition; Prism 4; GraphPad Software, San Diego, CA) from which half-maximum inhibition (IC₅₀) of pegaptanib was calculated.

Animals and Anesthesia

C57BL/6 mice (Charles River Laboratory, Wilmington, MA) were treated in accordance with the ARVO Statement for the Use of Animals in Ophthalmic and Vision Research. The animals were anesthetized with intramuscular ketamine hydrochloride (25 mg/kg) and xylazine (10 mg/kg) and their pupils dilated with 1% tropicamide. The mice were euthanized with a lethal dose of ketamine and xylazine administered by intraperitoneal injection. Adult (6-week old) male mice were used to generate corneal NV and choroidal NV models. All experimental groups consisted of five animals per group unless otherwise specified.

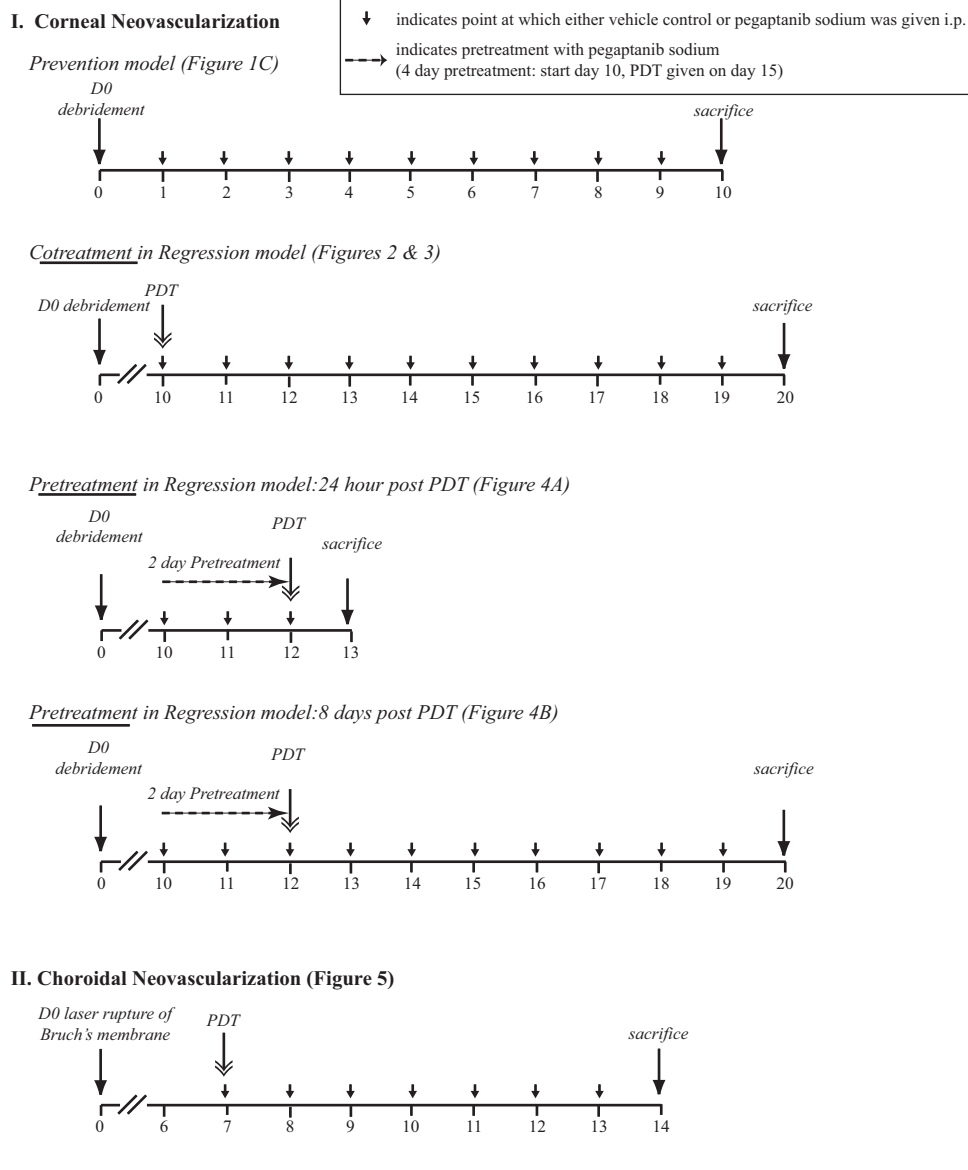
Corneal NV Model

An established mouse model of corneal NV²² was used with the following modification: In brief, NaOH (2 μ L of 0.2 mM) was applied topically to both eyes of each animal. The corneal and limbal epithelia were removed by applying a rotary motion parallel to the limbus with a no. 21 blade (Feather, Osaka, Japan). After epithelial debridement, the animals were randomized into treatment groups.

Corneal NV Quantification

Fluorescein isothiocyanate-concanavalin A perfusion (ConA; Vector Laboratories, Burlingame, CA) was used to label patent vasculature. In brief, mice received 20 μ g/g of ConA while deeply anesthetized. After 30 minutes, the eyes were enucleated, fixed with 4% paraformaldehyde (PFA) for 1 hour at 4°C, and the corneas were flatmounted. Anti-platelet endothelial cell adhesion molecule-1 antibody (PECAM-1, clone MEC 13.3; BD Biosciences, San Diego, CA) was used to immunostain both patent and occluded vasculature. In brief, the eyes were enucleated and fixed with 4% PFA for 1 hour at 4°C. The corneas were washed in PBS and incubated overnight with PECAM-1 at 4°C in PBS containing 10% goat serum and 1% Triton X-100. The tissues were washed four times in PBS, followed by incubation with an Alexa 488- or 546-conjugated secondary antibody (Invitrogen-Molecular Probes,

TABLE 1. Experimental Procedures and Dosing Regimes



Eugene, OR) overnight at 4°C. Corneal NV was visualized with an epifluorescence microscope (DMRA2; Leica, Deerfield, IL) and quantified with imaging software (Metamorph; Universal Imaging Corp., Downingtown, PA). The blood vessel area was quantified as follows: The perimeter of the entire corneal flatmount and the area of the cornea bounded by in-growing blood vessels were traced. Subtraction of the inner corneal area from the entire corneal area provided the value of the total blood vessel area. Blood vessel area was expressed as a percentage of the total corneal area. Statistical analysis was performed with the Student *t*-test.

Choroidal Neovascularization Model

Choroidal neovascularization (CNV) was generated by using a previously described technique²³ with the following modifications. Four burns were generated with diode laser photocoagulation (75- μ m spot size, 0.1-s duration, 90 mW; Oculight SL laser; Iridex, Mountain View, CA) and a handheld coverslip as a contact lens. Burns were localized to the 3-, 6-, 9-, and 12-o'clock positions of the posterior pole of the retina. Formation of a bubble at the time of laser application indicated rupture of Bruch's membrane and was an important factor for success-

ful induction of CNV. Therefore, only those mice in which a bubble formed for all four laser burns were included in the study.

Choroidal NV Quantitation

After enucleation of the eyes, choroidal flatmounts were obtained by removing the cornea, and the lens and then peeling the neural retina away from the underlying retinal pigment epithelium. Radial cuts allowed the eye cup to be laid flat. Choroidal flatmounts were fixed with 4% PFA for 1 hour at 4°C and stained with anti-PECAM-1, as detailed earlier. Imaging of choroidal flatmounts was performed as described for corneal flatmounts. However, neovascularization was quantified by drawing a perimeter around areas of hyperfluorescence associated with each burn.

PDT Application

Pegaptanib sodium was administered by intraperitoneal (IP) injection at a dose of 50 mg/kg/d. For pretreatment, pegaptanib sodium was administered at specified time points before PDT. Table 1 summarizes the experimental protocols and dosing regimens used in this study. Vertepor-

fin was administered by intravenous injection at a dose of 1 mg/kg. Five minutes after administration of verteporfin, the eyes were exposed to 689 nm laser light (50 J/cm² at 200 mW/cm²; Ceralas PDT 689; Ceramptec, Bonn, Germany). PDT-induced vessel obliteration was determined 24 hours after PDT. Vessel regression was determined 10 days after PDT.

RESULTS

The Molecular Composition and Efficacy of Pegaptanib Sodium Are Unaffected by PDT

Since effective PDT requires laser irradiation and the release of reactive oxygen species through photoactivation of verteporfin, we were initially concerned of a potential destructive effect of PDT on the aptamer, pegaptanib sodium, when the two agents were used in combination. However, after laser irradiation, HPLC analysis revealed no degradation of the aptamer, as determined by the peak profile (corresponding to pegaptanib sodium) or the number of peaks (representing degradation products) between laser-irradiated and nonirradiated samples (Supplementary Fig. S1A, online at <http://www.iovs.org/cgi/content/full/49/2/662/DC1>). In addition, laser-irradiated samples containing a range of concentrations of verteporfin (0.1–10 μg/mL) had no significant effect on pegaptanib sodium (Supplementary Fig. S1B). Therefore, it does not appear that PDT has an effect on the molecular composition of pegaptanib sodium.

Although the structure of the aptamer remained unchanged on treatment with PDT, it is possible that subtle oxidation changes of the molecule could affect its activity. Therefore, we tested the effect of PDT on the biological activity of pegaptanib sodium. Tissue factor expression is upregulated by VEGF-A and has been used as a marker for the VEGF-A signaling pathway. Pegaptanib sodium significantly reduced the induction of tissue factor expression on VEGF165 treatment at an IC₅₀ concentration of 1 nM. Pretreatment of the samples with either laser alone, Visudyne alone or with laser treatment in the presence of Visudyne did not affect the inhibitory activity of pegaptanib sodium (Fig. 1A). Furthermore, inclusion of FBS (10%) in the solution of pegaptanib sodium, to produce a more physiologically relevant environment, had no effect on the efficacy of pegaptanib sodium. Next, we examined the effect of PDT on the ability of pegaptanib sodium to inhibit binding of VEGF165 to its receptor VEGFR-1 (Flt-1). Neither laser treatment alone nor laser treatment in the presence of Visudyne affected the efficacy of pegaptanib sodium at inhibiting VEGF165 binding to VEGFR-1 (Fig. 1B).

Since Visudyne and pegaptanib sodium would coexist at therapeutic concentrations in the eye when coadministered, we used a murine corneal NV model to determine any potential adverse effects of Visudyne on the efficacy of pegaptanib sodium. We found that 10 days after corneal scarring, daily pegaptanib sodium treatment produced an 80% inhibition of corneal neovascular growth (Fig. 1C). Of note, Visudyne did not affect the activity of pegaptanib sodium. Taken together, these data reveal a lack of interaction between both compounds and that PDT with Visudyne does not diminish the activity of pegaptanib sodium *in vitro* or *in vivo*.

Characterization of PDT Monotherapy for Corneal NV

To evaluate the efficacy of the coadministration of PDT and pegaptanib sodium, we first characterized the effect of PDT alone in the murine corneal NV model. Neovessels that grow in the corneal NV model remain stable for more than 28 days after injury (epithelium debridement) without natural neovessel regression. Therefore, this provides a means of examining the ability of agents to reduce neovascular lesions and to inhibit neovessel growth.²⁴ Moreover, administration of PDT to the

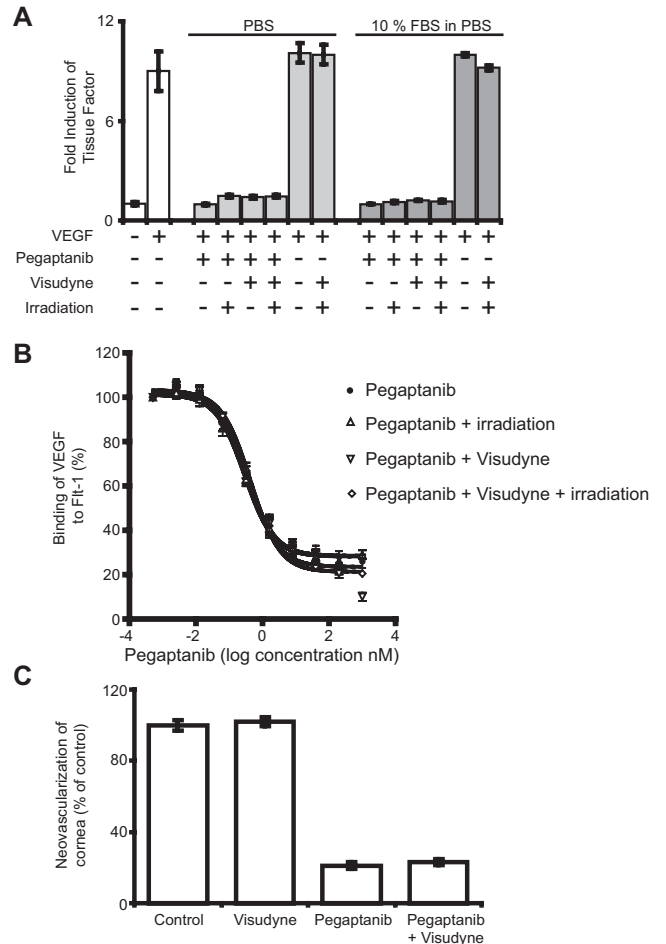


FIGURE 1. PDT did not affect the efficacy of pegaptanib sodium. (A) A tissue culture-based assay of VEGF165-induced gene expression. Pegaptanib sodium (10 nM) significantly inhibited the induction of tissue factor on treatment of HUVECs with VEGF165 (12.5 ng/mL). No difference in the efficacy of pegaptanib sodium was noted in the presence of FBS (10%). Neither irradiation nor verteporfin affected the efficacy of pegaptanib sodium. (B) Binding assay of VEGF165 to the Flt-1 receptor; the IC₅₀ (1 nM) of pegaptanib sodium is not significantly affected by irradiation, verteporfin, or both in combination. (C) The efficacy of pegaptanib sodium in the inhibition of corneal NV was unaffected in the presence of verteporfin *in vivo*. Data are the mean \pm SEM and are the mean result of at least three independent experiments.

rodent cornea is accessible, and quantitation of the corneal neovascular lesions is accurate and reproducible allowing excellent evaluation of the efficacy of combinations of different agents.

Administration of PDT to neovessels 10 days after corneal scarring produced a rapid loss of these vessels, with the greatest loss occurring 24 hours after treatment (Fig. 2). However, this loss of neovessels was not maintained and the area of corneal NV increased progressively over the next 9 days. By day 20 (10 days after PDT), vessel regrowth occupied an area similar to that on the pretreatment day (day 10; Fig. 2). Therefore, although the neovascular area was reduced compared with the untreated control at all time points after PDT, we noted a substantial regrowth of neovessels after PDT.

Effect on NV of Simultaneous Use of PDT and Pegaptanib Sodium in Reducing Blood Vessel Area versus Either Agent Alone

Since pegaptanib sodium appears to be unaffected by PDT, we examined the effect of the simultaneous administration of both

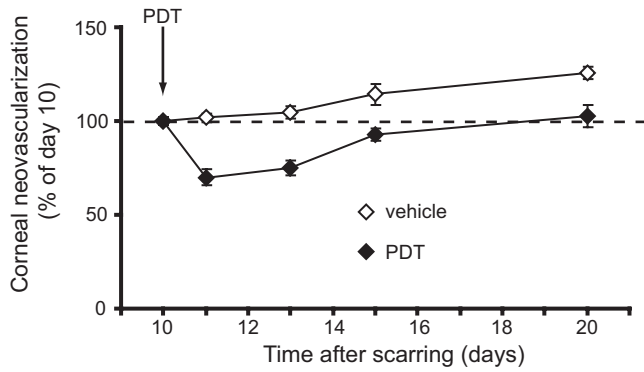


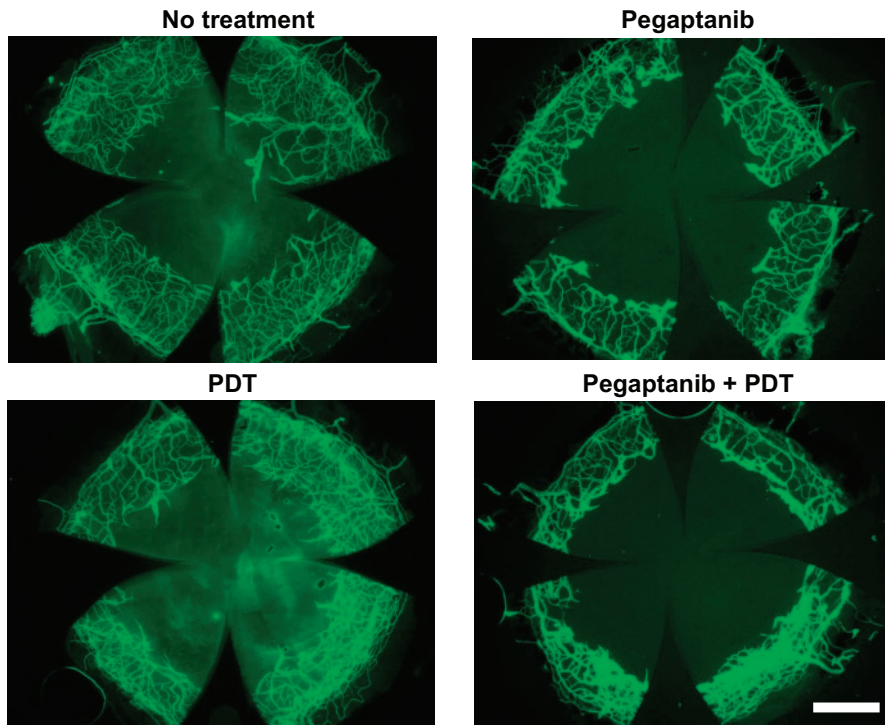
FIGURE 2. PDT initially reduced NV in the cornea, but there was subsequent regrowth of vessels. Corneas were scraped on day 0 and the animals were treated with PDT on day 11. The corneas were isolated on days 11, 13, 15, and 20. Corneal NV was quantified and is represented as a percentage of that determined on day 10. *Dotted line:* corneal NV on day 10.

therapies for the treatment of aberrant ocular NV. In untreated animals, we noted a 20% continuation in new vessel growth from days 10 to 20. Pegaptanib sodium monotherapy between days 10 and 20, inhibited all new vessel growth but did not cause regression of the existing neovessels. When pegaptanib sodium was administered to animals together with PDT on day 10, a dramatic reduction in corneal NV was observed by day 20 (Fig. 3). There was a 62% regression in corneal vascularization in the combined group (Fig. 3B). Thus, in the presence of pegaptanib sodium, vessel regrowth after PDT was prevented (compare Fig. 2, day 20 with Fig. 3B). Therefore, the combined treatment of PDT and pegaptanib sodium resulted in a greater reduction in NV than either PDT or pegaptanib sodium treatments alone.

Effect of Pretreatment with Pegaptanib Sodium on the Efficacy of PDT-Induced Lesion Regression

The simultaneous administration of pegaptanib sodium and PDT produced a significant reduction in corneal NV. In an

A. Sample images of corneal NV on day 20



B. Quantification of corneal NV on days 11 and 20

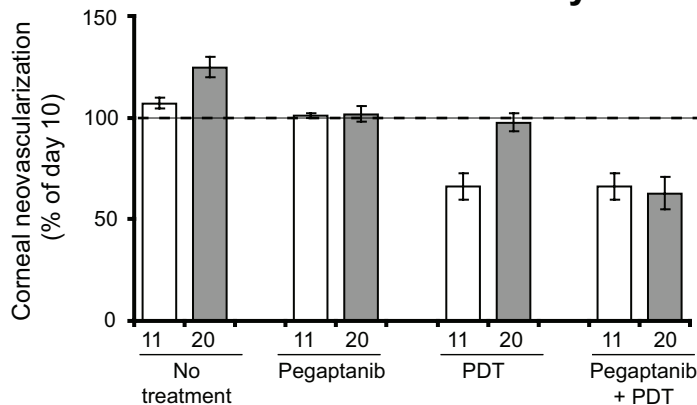


FIGURE 3. Combination treatment with PDT and pegaptanib sodium significantly reduced corneal NV. (A) Representative images of entire corneal flatmounts showing NV at day 20. Scale bar, 500 μ m. (B) Quantification of corneal NV at days 11 and 20. Data are the mean \pm SEM and are the mean result of at least three independent experiments.

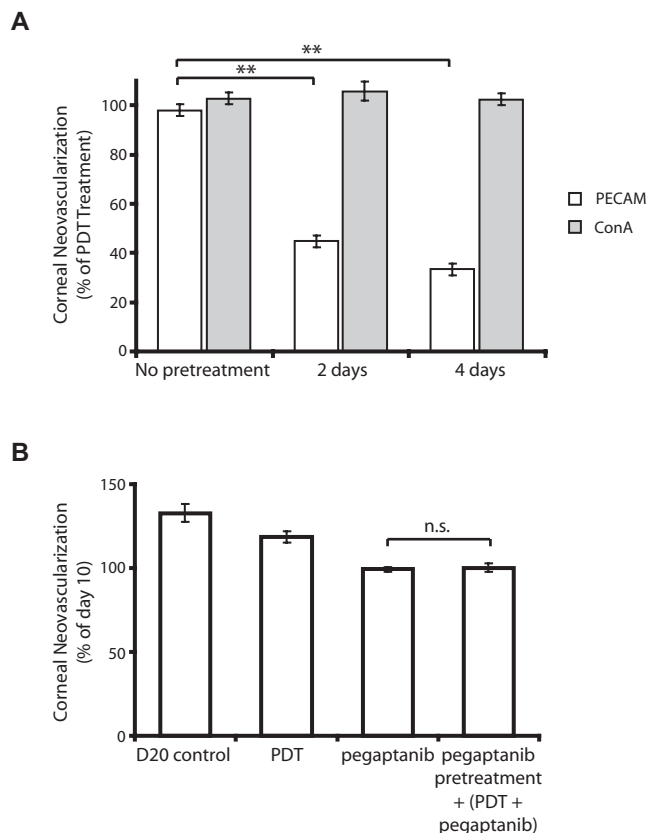


FIGURE 4. Pretreatment with pegaptanib sodium reduces the efficacy of PDT in the corneal model of NV. **(A)** Corneal NV regression was quantified at days 11, 13, and 15 corresponding to no pretreatment, 2 and 4 days' pretreatment of pegaptanib sodium before PDT on days 10, 12, and 14. Total vasculature was immunostained with PECAM-1, and patent vasculature was labeled with ConA perfusion. Change in corneal NV is represented as a percentage of corneal NV change caused by PDT alone. $^{**}P < 0.01$; one-way ANOVA with Bonferroni post hoc test. **(B)** Animals were pretreated with pegaptanib sodium for 2 days (days 10 and 11) before PDT on D12 and continued with pegaptanib sodium treatment until day 19. Quantification of corneal NV occurred at day 20. Data are the mean \pm SEM and are the mean result of at least three independent experiments.

effort to determine whether pretreatment with pegaptanib sodium would improve efficacy over cotreatment, we examined the effect of administering pegaptanib sodium 2 or 4 days before PDT (at days 12 and 15, respectively; Table 1) in the murine corneal NV model. Changes in the corneal neovascular area were analyzed 24 hours after PDT. Two-day pretreatment with pegaptanib sodium reduced the initial ablation of corneal NV after PDT by $\sim 60\%$ (Fig. 4A). Similar data were observed with a 4-day pegaptanib sodium pretreatment. Examination of vascular regression (PECAM-1 immunostain) versus vessel occlusion (ConA infusion) suggested that pegaptanib sodium did not inhibit PDT-induced thrombosis of vessels, but rather the subsequent vessel regression observed 24 hours after PDT (Fig. 4A, compare with Fig. 2). In an effort to determine the effect of pegaptanib sodium pretreatment on the overall effect of combination therapy, animals with corneal NV were pretreated with pegaptanib sodium 2 days before PDT therapy (Table 1). The extent of NV was examined at day 20. Pegaptanib sodium pretreatment before PDT resulted in a loss of the enhanced effect observed after the simultaneous treatment with these agents (Fig. 4B; compare to Fig. 3).

Effect of Simultaneous Addition of PDT and Pegaptanib Sodium versus Either Agent Alone in Reducing Blood Vessel Area in the Choroidal NV Model

Although it was more technically challenging to quantify, we compared the effect of simultaneous addition of PDT and pegaptanib sodium in a choroidal NV model since this approach more accurately relates to the aberrant blood vessel growth that occurs in AMD.

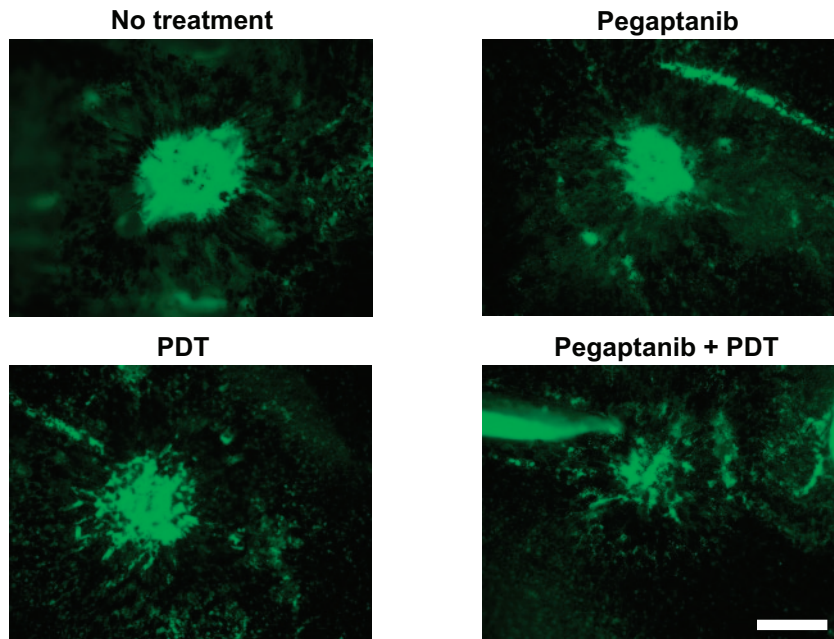
In this model, laser-induced CNV lesions on Bruch's membrane were generated on day 0, and tissues were harvested on day 14. Animals were treated with either pegaptanib sodium alone from days 7 to 14, with PDT on day 7, or both (Table 1). Although PDT or pegaptanib sodium monotherapy showed some inhibition of CNV and the treatment with pegaptanib sodium alone resulted in the prevention of new growth from day 7 to 14, the combined treatment with both agents was more effective than treatment with either agent alone at reducing CNV lesion size (Fig. 5). These data confirm our observations in the corneal NV model and suggest that simultaneous cotreatment of pegaptanib sodium with PDT may provide a more efficacious treatment option for the sustained regression of choroidal NV in AMD.

DISCUSSION

Neovascular AMD is a complex disease process involving inflammation as well as vessel, connective tissue, and neuronal abnormalities.²⁵ A combination of inhibitors, targeting both VEGF-A and PDGF-B pathways, were recently shown to inhibit NV more effectively than either single inhibitor in different ocular disease models.²⁶ In our present study, the combined treatment of PDT and pegaptanib sodium significantly reduced NV in two different ocular angiogenesis models, corneal and choroidal NV, and this combined treatment was superior to either agent used as a monotherapy. Ocular diseases associated with aberrant angiogenesis are chronic and become symptomatic over many years. A more effective treatment would target not only the actively growing neovascularity but also preexisting pathologic vessels. Unlike some animal models of ocular NV that present natural vessel regression over time,^{26,27} corneal NV is maintained for up to 4 weeks after injury,²⁴ making it an optimal model to study vessel regression. Using this model, we identified a significantly increased efficacy of cotreatment when pegaptanib sodium and PDT were administered simultaneously. In addition, using laser-burn induced choroidal NV, which more closely models the NV of AMD, we found a similar effect when these agents were delivered simultaneously.

PDT is an established modality for the treatment of solid tumors and neovascular AMD. A major hallmark of the events after PDT is the release of a wide variety of potent mediators, including vasoactive substances, components of the complement and clotting cascades, acute phase proteins, proteases, peroxidases, radicals, leukocyte chemoattractants, cytokines, growth factors, and other immunoregulators.^{26,28} Ferrario et al.²⁹ described substantially increased VEGF-A levels in vivo in a mouse mammary carcinoma after PDT and a smaller increase in cultured tumor cells of the same species, suggesting a dual mechanism with a less intensive primary cellular response and a secondary more pronounced hypoxia-induced effect. VEGF-A is upregulated by hypoxia and is a major stimulator for ischemic NV, with increased expression in the retina and vitreous of patients with ischemic retinopathies.^{30,31} VEGF-A alone is sufficient to induce neovascular growth, even in the absence of hypoxia.^{32,33} Schmidt-Erfurth et al.³⁴ have suggested that a similar sequence of events occurs in ocular PDT. Consistent with the above findings,

A. Sample images of choroidal NV on day 14



B. Quantification of choroidal NV

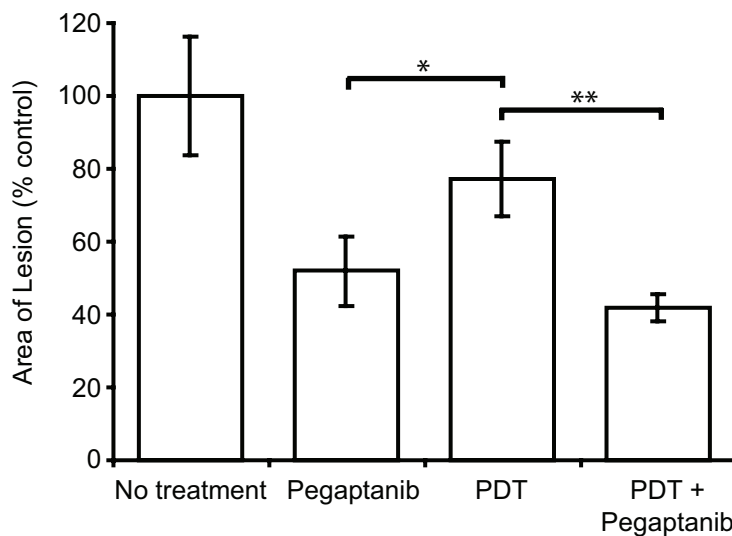


FIGURE 5. Combination treatment with PDT and pegaptanib sodium significantly reduced choroidal NV. CNV was generated on day 0. The animals were treated with pegaptanib sodium from days 7 to 14, PDT was performed on day 10. (A) Representative images of choroidal NV at day 14. (B) Quantification of the area of hyperfluorescence at day 14. Data are the mean \pm SEM and are the mean result of at least three independent experiments. * $P < 0.05$, ** $P < 0.01$; one-way ANOVA with Bonferroni post hoc test.

a recent study suggested that revascularization after PDT is caused by angiogenesis rather than by recanalization.³⁵ Pathologic vessels resulting from aberrant angiogenesis in the adult are highly dependent on VEGF-A, although there is mounting evidence of pathologic vessel resistance to anti-VEGF-A therapy as time progresses.^{26,36} Therefore, we reasoned that combination treatment with pegaptanib and PDT would both ablate established vessels (PDT) and inhibit regrowth due to increased expression of VEGF-A (pegaptanib).

As the effects of verteporfin PDT on an aptamer are unknown, we showed in the present study that the activity of pegaptanib was not affected by verteporfin and/or PDT. The combined use of PDT and pegaptanib sodium resulted in dramatic vessel regression 10 days after PDT in the corneal NV model. This reduction was the combined result of the acute vessel ablation after PDT and the antiangiogenic effect of pegaptanib sodium (Fig. 3). It is apparent that the neovessels were reduced in length as well as in complexity

after the combined treatment. Although we hypothesized the application of anti-VEGF-A compounds before PDT might result in greater efficacy, pretreatment with pegaptanib sodium before PDT resulted in reduced efficacy of PDT and a loss of the significant decrease in NV observed after simultaneous treatment with these agents. One can hypothesize different scenarios for why the efficacy of PDT was compromised by prior treatment with pegaptanib. First, the pretreatment schedule with pegaptanib may have affected the inflammatory component of PDT and thereby reduced the efficacy of the treatment. Pegaptanib has been shown to interfere with the inflammatory process by modulating leukocyte migration and adherence to endothelial cells.^{37,38} Second, local injection of an anti-VEGF agent may affect the delivery of verteporfin to the sites of NV, hence reducing the effective concentration of the photoactive agent. Although the underlying mechanisms are presently unknown, it is evident that the potential benefits of combi-

nation therapy are critically dependent on the simultaneous administration of PDT and pegaptanib.

Combination therapy is becoming an accepted paradigm for the treatment of AMD, as it has been for oncology indications. The combination of PDT and intravitreal triamcinolone acetonide (IVTA) has been applied to patients with subfoveal CNV secondary to AMD.^{39,40} Studies in the monkey model of choroidal NV and the FOCUS study have shown that the combination of ranibizumab and PDT is superior to verteporfin PDT alone for all primary and secondary efficacy outcomes.⁴¹ Our recent work in the chick chorioallantoic membrane assay has shown that inhibition of VEGF-A enhances the effect of PDT in vessel regression.⁴² The studies described in this article show that simultaneous administration of PDT and pegaptanib provides improved results compared with either agent given as a monotherapy. The significant vessel regression effects observed in the present study suggest that the combined use of PDT and pegaptanib sodium may provide a beneficial option for any ocular disease in which NV plays a major role. However, the mode, dosage, and timing of administration of these agents in combination may have to be considered to ensure optimal efficacy.

References

- Congdon N, O'Colmain B, Klaver CC, et al. Causes and prevalence of visual impairment among adults in the United States. *Arch Ophthalmol*. 2004;122:477-485.
- Friedman DS, O'Colmain BJ, Munoz B, et al. Prevalence of age-related macular degeneration in the United States. *Arch Ophthalmol*. 2004;122:564-572.
- Kocur I, Resnikoff S. Visual impairment and blindness in Europe and their prevention. *Br J Ophthalmol*. 2002;86:716-722.
- Ambati J, Ambati BK, Yoo SH, Ianchulev S, Adamis AP. Age-related macular degeneration: etiology, pathogenesis, and therapeutic strategies. *Surv Ophthalmol*. 2003;48:257-293.
- Soubrane G, Bressler NM. Treatment of subfoveal choroidal neovascularisation in age related macular degeneration: focus on clinical application of verteporfin photodynamic therapy. *Br J Ophthalmol*. 2001;85:483-495.
- Gragoudas ES, Adamis AP, Cunningham ET Jr, Feinsod M, Guyer DR. Pegaptanib for neovascular age-related macular degeneration. *N Engl J Med*. 2004;351:2805-2816.
- Siddiqui MA, Keating GM. Pegaptanib: in exudative age-related macular degeneration. *Drugs*. 65:1571-1577, 2005; discussion 1578-1579.
- Ferrara N, Damico L, Shams N, Lowman H, Kim R. Development of ranibizumab, an anti-vascular endothelial growth factor antigen binding fragment, as therapy for neovascular age-related macular degeneration. *Retina*. 2006;26:859-870.
- Bressler NM. Photodynamic therapy of subfoveal choroidal neovascularization in age-related macular degeneration with verteporfin: two-year results of 2 randomized clinical trials-tap report 2. *Arch Ophthalmol*. 2001;119:198-207.
- Blumenkranz MS, Bressler NM, Bressler SB, et al. Verteporfin therapy for subfoveal choroidal neovascularization in age-related macular degeneration: three-year results of an open-label extension of 2 randomized clinical trials-TAP Report no. 5. *Arch Ophthalmol*. 2002;120:1307-1314.
- Oleinick NL, Evans HH. The photobiology of photodynamic therapy: cellular targets and mechanisms. *Radiat Res*. 1998;150: S146-156.
- Verteporfin In Photodynamic Therapy Study Group. Verteporfin therapy of subfoveal choroidal neovascularization in age-related macular degeneration: two-year results of a randomized clinical trial including lesions with occult with no classic choroidal neovascularization—verteporfin in photodynamic therapy report 2. *Am J Ophthalmol*. 2001;131:541-560.
- Tatar O, Adam A, Shinoda K, et al. Expression of VEGF and PEDF in choroidal neovascular membranes following verteporfin photodynamic therapy. *Am J Ophthalmol*. 2006;142:95-104.
- Adamis AP, Shima DT. The role of vascular endothelial growth factor in ocular health and disease. *Retina*. 2005;25:111-118.
- Kvanta A, Alverer PV, Berglin L, Seregard S. Subfoveal fibrovascular membranes in age-related macular degeneration express vascular endothelial growth factor. *Invest Ophthalmol Vis Sci*. 1996;37:1929-1934.
- Lopez PF, Sippy BD, Lambert HM, Thach AB, Hinton DR. Trans-differentiated retinal pigment epithelial cells are immunoreactive for vascular endothelial growth factor in surgically excised age-related macular degeneration-related choroidal neovascular membranes. *Invest Ophthalmol Vis Sci*. 1996;37:855-868.
- Wada M, Ogata N, Otsuji T, Uyama M. Expression of vascular endothelial growth factor and its receptor (KDR/flk-1) mRNA in experimental choroidal neovascularization. *Curr Eye Res*. 1999;18:203-213.
- Kwak N, Okamoto N, Wood JM, Campochiaro PA. VEGF is major stimulator in model of choroidal neovascularization. *Invest Ophthalmol Vis Sci*. 2000;41:3158-3164.
- Heier JS, Antoszyk AN, Pavan PR, et al. Ranibizumab for treatment of neovascular age-related macular degeneration: a phase I/II multicenter, controlled, multidose study. *Ophthalmology*. 2006;113:642 e641-644.
- Ishida S, Usui T, Yamashiro K, et al. VEGF164-mediated inflammation is required for pathological, but not physiological, ischemia-induced retinal neovascularization. *J Exp Med*. 2003;198:483-489.
- Ng EW, Adamis AP. Targeting angiogenesis, the underlying disorder in neovascular age-related macular degeneration. *Can J Ophthalmol*. 2005;40:352-368.
- Joussen AM, Poulaki V, Mitsiades N, et al. VEGF-dependent conjunctivalization of the corneal surface. *Invest Ophthalmol Vis Sci*. 2003;44:117-123.
- Mori K, Ando A, Gehlbach P, et al. Inhibition of choroidal neovascularization by intravenous injection of adenoviral vectors expressing secreted endostatin. *Am J Pathol*. 2001;159:313-320.
- Moromizato Y, Stechschulte S, Miyamoto K, et al. CD18 and ICAM-1-dependent corneal neovascularization and inflammation after limbal injury. *Am J Pathol*. 2000;157:1277-1281.
- Ferris FL 3rd, Fine SL, Hyman L. Age-related macular degeneration and blindness due to neovascular maculopathy. *Arch Ophthalmol*. 1984;102:1640-1642.
- Jo N, Mailhos C, Ju M, et al. Inhibition of platelet-derived growth factor B signaling enhances the efficacy of anti-vascular endothelial growth factor therapy in multiple models of ocular neovascularization. *Am J Pathol*. 2006;168:2036-2053.
- Pierce EA, Avery RL, Foley ED, Aiello LP, Smith LE. Vascular endothelial growth factor/vascular permeability factor expression in a mouse model of retinal neovascularization. *Proc Natl Acad Sci USA*. 1995;92:905-909.
- Ochsner M. Photophysical and photobiological processes in the photodynamic therapy of tumours. *J Photochem Photobiol B*. 1997;39:1-18.
- Ferrario A, von Tiehl KF, Rucker N, Schwarz MA, Gill PS, Gomer CJ. Antiangiogenic treatment enhances photodynamic therapy responsiveness in a mouse mammary carcinoma. *Cancer Res*. 2000;60:4066-4069.
- Uehara M, Inokuchi T, Sano K, ZuoLin W. Expression of vascular endothelial growth factor in mouse tumours subjected to photodynamic therapy. *Eur J Cancer*. 2001;37:2111-2115.
- Shweiki D, Itin A, Soffer D, Keshet E. Vascular endothelial growth factor induced by hypoxia may mediate hypoxia-initiated angiogenesis. *Nature*. 1992;359:843-845.
- Malecaze F, Clamens S, Simorre-Pinatel V, et al. Detection of vascular endothelial growth factor messenger RNA and vascular endothelial growth factor-like activity in proliferative diabetic retinopathy. *Arch Ophthalmol*. 1994;112:1476-1482.
- Tolentino MJ, Miller JW, Gragoudas ES, Chatzistefanou K, Ferrara N, Adamis AP. Vascular endothelial growth factor is sufficient to produce iris neovascularization and neovascular glaucoma in a nonhuman primate. *Arch Ophthalmol*. 1996;114:964-970.
- Schmidt-Erfurth U, Schlotzer-Schrehardt U, Cursiefen C, Michels S, Beckendorf A, Naumann GO. Influence of photodynamic therapy on expression of vascular endothelial growth factor (VEGF), VEGF receptor 3, and pigment epithelium-derived factor. *Invest Ophthalmol Vis Sci*. 2003;44:4473-4480.

35. Petermeier K, Tatar O, Inhoffen W, et al. Verteporfin photodynamic therapy induced apoptosis in choroidal neovascular membranes. *Br J Ophthalmol*. 2006;90:1034-1039.
36. Bergers G, Song S, Meyer-Morse N, Bergsland E, Hanahan D. Benefits of targeting both pericytes and endothelial cells in the tumor vasculature with kinase inhibitors. *J Clin Invest*. 2003;111:1287-1295.
37. Ishida S, Usui T, Yamashiro K, et al. VEGF164 is proinflammatory in the diabetic retina. *Invest Ophthalmol Vis Sci*. 2003;44:2155-2162.
38. Usui T, Ishida S, Yamashiro K, et al. VEGF164(165) as the pathological isoform: differential leukocyte and endothelial responses through VEGFR1 and VEGFR2. *Invest Ophthalmol Vis Sci*. 2004;45:368-374.
39. Gee MS, Procopio WN, Makonnen S, Feldman MD, Yeilding NM, Lee WM. Tumor vessel development and maturation impose limits on the effectiveness of anti-vascular therapy. *Am J Pathol*. 2003;162:183-193.
40. Bradley J, Ju M, Robinson GS. Combination therapy for the treatment of ocular neovascularization. *Angiogenesis*. 2007;10:141-148.
41. Heier JS, Boyer DS, Ciulla TA, et al. Ranibizumab combined with verteporfin photodynamic therapy in neovascular age-related macular degeneration: year 1 results of the FOCUS Study. *Arch Ophthalmol*. 2006;124:1532-1542.
42. Zuluaga M-F, Mailhos C, Robinson GS, Shima DT, Gurny R, Lange N. Synergies of VEGF inhibition and photodynamic therapy in the treatment of age-related macular degeneration. *Invest Ophthalmol Vis Sci*. 2007;48:1767-1772.