

IQCB1 Mutations in Patients with Leber Congenital Amaurosis

Alejandro Estrada-Cuzcano,^{1,2,3} Robert K. Koenekoop,⁴ Frauke Coppeters,⁵ Susanne Kohl,⁶ Irma Lopez,⁴ Rob W. J. Collin,^{1,2,3} Elfride B. W. De Baere,⁵ Debbie Roeleveld,¹ Jonab Marek,⁴ Antje Bernd,⁶ Klaus Rohrschneider,⁷ L. Ingeborgh van den Born,⁸ Françoise Meire,⁹ Irene H. Maumenee,¹⁰ Samuel G. Jacobson,¹¹ Carel B. Hoyng,² Eberhart Zrenner,⁶ Frans P. M. Cremers,^{1,3} and Anneke I. den Hollander^{1,2,3}

PURPOSE. Leber congenital amaurosis (LCA) is genetically heterogeneous, with 15 genes identified thus far, accounting for ~70% of LCA patients. The aim of the present study was to identify new genetic causes of LCA.

METHODS. Homozygosity mapping in >150 LCA patients of worldwide origin was performed with high-density SNP microarrays to identify new disease-causing genes.

RESULTS. In three isolated LCA patients, the authors identified large homozygous regions on chromosome 3 encompassing the *IQCB1* gene, which has been associated with Senior-Loken syndrome (SLSN), characterized by nephronophthisis and retinal degeneration. Mutation analysis of *IQCB1* in these three patients and a subsequent cohort of 222 additional LCA patients identified frameshift and nonsense mutations in 11 patients diagnosed with LCA. On re-inspection of the patient's

disease status, seven were found to have developed SLSN, but four maintained the diagnosis of LCA as the kidney function remained normal.

CONCLUSIONS. Results show that the onset of renal failure in patients with *IQCB1* mutations is highly variable, and that mutations are also found in LCA patients without nephronophthisis, rendering *IQCB1* a new gene for LCA. However, these patients are at high risk for developing renal failure, which in early stages is often not recognized and can cause sudden death from fluid and electrolyte imbalance. It is therefore recommended that all LCA patients be screened for *IQCB1* mutations, to follow them more closely for kidney disease. (*Invest Ophthalmol Vis Sci.* 2011;52:834–839) DOI:10.1167/iov.10-5221

From the Departments of ¹Human Genetics and ²Ophthalmology, Radboud University Nijmegen Medical Centre, Nijmegen, The Netherlands; ³Nijmegen Center of Molecular Life Sciences, Radboud University Nijmegen, Nijmegen, The Netherlands; ⁴McGill Ocular Genetics Centre, McGill University Health Centre, Montreal, Canada; ⁵Center for Medical Genetics, Ghent University Hospital, Ghent, Belgium; ⁶Department of Ophthalmology, University of Tübingen, Tübingen, Germany; ⁷Department of Ophthalmology, University of Heidelberg, Heidelberg, Germany; ⁸Rotterdam Eye Hospital, Rotterdam, The Netherlands; ⁹HUDERF-Erasme Hospital Brussels, University Hospital of the Free University of Brussels, Brussels, Belgium; ¹⁰Department of Ophthalmology, University of Illinois Eye and Ear Infirmary, Chicago, Illinois; and ¹¹Department of Ophthalmology, Scheie Eye Institute, University of Pennsylvania, Philadelphia, Pennsylvania.

Supported by the Radboud University Nijmegen Medical Center, the Foundation Fighting Blindness USA (BR-GE-0507-0381-RAD (AIdH), The Netherlands Organization for Scientific Research (916.56.160) (AIdH), the Foundation Fighting Blindness Canada (AIdH, FPMC, RKK), the Fonds de la Recherche en Santé Québec (RKK), the Canadian Institutes of Health Research (RKK), Fonds Wetenschappelijk Onderzoek (FC, EBWDB), and Stichting Wetenschappelijk Onderzoek Oogziekenhuis (AIdH, FPMC, LlvdB).

Submitted for publication January 17, 2010; revised March 4 and July 13, 2010; accepted August 16, 2010.

Disclosure: **A. Estrada-Cuzcano**, None; **R.K. Koenekoop**, None; **F. Coppeters**, None; **S. Kohl**, None; **I. Lopez**, None; **R.W.J. Collin**, None; **E.B.W. De Baere**, None; **D. Roeleveld**, None; **J. Marek**, None; **A. Bernd**, None; **K. Rohrschneider**, None; **L.I. van den Born**, None; **F. Meire**, None; **I.H. Maumenee**, None; **S.G. Jacobson**, None; **C.B. Hoyng**, None; **E. Zrenner**, None; **F.P.M. Cremers**, None; **A.I. den Hollander**, None

Corresponding author: Anneke I. den Hollander, Department of Ophthalmology, Radboud University Nijmegen Medical Centre, Philips van Leydenlaan 15, 6525 EX, Nijmegen, The Netherlands; a.denhollander@antrg.umcn.nl.

Leber congenital amaurosis (LCA [MIM204000]; Mendelian Inheritance in Man, National Center for Biotechnology, Bethesda, MD) is the most severe form of early-onset retinal blindness and typically becomes evident in the first year of life. The frequency is variably estimated as 1/30,000¹ and 1/81,000.² Poor visual function is accompanied by nystagmus (pendular or roving eye movements), photophobia, sluggish or near-absent pupillary responses, hyperopia, extinguished or severely reduced rod and cone signals on the electroretinogram (ERG), and a highly variable retinal appearance. LCA is generally inherited in an autosomal recessive manner and is genetically heterogeneous. Fifteen genes have been associated with LCA, which explain approximately 70% of the patients, whereas 30% of LCA patients are currently “unsettled” and likely have mutations in yet to be discovered genes (<http://www.sph.uth.tmc.edu/RetNet/>). The known genes that are causative for LCA participate in a diverse group of functional pathways, including photoreceptor development (*CRB1* [MIM 604210], *CRX* [MIM 602225]), phototransduction (*GUCY2D* [MIM 600179], *AIPL1* [MIM 604392]), retinoid metabolism (*RPE65* [MIM 180069], *LRAT* [MIM 604863], *RDH12* [MIM 608830]), ciliary transport (*CEP290* [MIM 610142], *TULP1* [MIM 602280], *RPGRIP1* [MIM 605446], *LCA5* [MIM 611408]), guanine synthesis (*IMPDH1* [MIM146690]), and outer segment phagocytosis by the retinal pigment epithelium (*MERTK* [MIM 604705]). Additionally, the functional pathways in which *RD3* [MIM180040] and *SPATA7* [MIM 609868] participate remain unknown.

One of these genes, *CEP290* (also known as *NPHP6*), represents the most common cause of LCA identified until now, accounting for 20% of LCA patients of northern European descent,^{3,4} although lower frequencies (5%) have been reported in other populations.^{5,6} In addition, *CEP290* is also associated with several severe multisystem diseases in which

blindness due to retinal degeneration is only part of the phenotype, such as Joubert (JBTS), Meckel (MKS), Bardet-Biedl (BBS), and Senior-Loken syndromes (SLSN).^{7–12} JBTS is characterized by a mid-hindbrain malformation (called the molar tooth sign on imaging studies), hypotonia, developmental delay, and retinal dystrophy and may also be associated with nephronophthisis, congenital hepatic fibrosis, and polydactyly. MKS is an early embryonic multisystem disorder characterized by malformations of the central nervous system (typically occipital meningoencephalocele), polydactyly, cystic kidney dysplasia, and ductal proliferation in the portal area of the liver. BBS includes progressive retinal degeneration, obesity, polydactyly, hypogenitalism, cognitive impairment, and kidney dysplasia. Finally, SLSN is an autosomal recessive disease with the main features of nephronophthisis (*NPHP* [MIM 256100]), a cystic kidney disease, and retinal degeneration.

CEP290 has been shown to interact with several centrosomal and microtubule-associated proteins,^{11,13–17} including *RPGR* (mutated in patients with X-linked retinitis pigmentosa), *RPGRIP1* (LCA), *CC2D2A* (JBTS and MKS), and *IQCB1* (also known as *NPHP5*) (SLSN). Knockdown studies of *CEP290* and *IQCB1* in zebrafish reveal similar phenotypes that recapitulate some of the characteristics of JBTS, and a synergistic effect on the severity of the phenotype was observed after combined knockdown of zebrafish *CEP290* and *IQCB1*.¹⁶ *CEP290* and *IQCB1* both localize to the connecting cilium of the photoreceptor, where they form part of a multiprotein complex that regulates the transport of cargo molecules to the outer segment of the photoreceptor.^{13,16,18} All SLSN patients with mutations in *IQCB1* were shown to suffer from severe retinal dystrophy, while the age of onset of the renal disease is variable.¹⁸

In our continuing efforts to identify new LCA genes, we have genotyped >150 LCA patients by SNP arrays and identified three LCA patients with large homozygous regions encompassing the *IQCB1* gene. This finding together with the reported interaction between the *IQCB1* and *CEP290* proteins,¹⁶ and the severe retinal dystrophy seen in SLSN patients with *IQCB1* mutations (not unlike LCA), prompted us to test the hypothesis that mutations in *IQCB1* cause nonsyndromic LCA. In this study, we report mutation analysis of the *IQCB1* gene in 225 LCA patients, which revealed mutations in 11 patients of nine families. On reevaluation of the renal function seven patients were subsequently diagnosed as SLSN, but four LCA patients did not show signs of renal disease. Our results show that *IQCB1* mutations can cause LCA without nephronophthisis, although we cannot exclude that some patients may develop kidney disease later in life.

MATERIAL AND METHODS

Subjects and Clinical Evaluation

Two hundred twenty-five unrelated LCA patients of worldwide origin were included in the study. The diagnosis of LCA was given to patients with blindness or severe visual impairment before the age of six months, onset of nystagmus within the first few weeks of life, and a nondetectable ERG before the age of one year. Patients were examined by acuity testing, slitlamp biomicroscopy, cycloplegic refraction (1% cyclogel drops), funduscopy, and ERG testing. Acuity testing was done with age-appropriate measures. After the diagnosis of LCA was ensured, DNA was collected after informed consents were signed. Ethical approval was given to all participating institutions and conformed to the tenets of the Declaration of Helsinki.

To exclude known mutations in the LCA genes, all patient samples were analyzed with a genotyping microarray based on arrayed primer extension (APEX) technology (Asper Ophthalmics, Tartu, Estonia).¹⁹ DNA samples of 93 LCA patients were genotyped and analyzed for

homozygous regions previously by den Hollander and co-workers.²⁰ Sixty additional DNA samples were analyzed in this study as described previously by den Hollander using 250 K NspI SNP microarrays (Affymetrix, Santa Clara, CA).

Mutation Analysis

Primers for amplification of the coding exons and splice junctions of *IQCB1* were selected by ExonPrimer (<http://ihg2.helmholtz-muenchen.de/ihg/ExonPrimer.html>) and Primer3 (http://biotools.umassmed.edu/bioapps/primer3_www.cgi). PCR products were purified with 96-well filter plates (Multiscreen HTS-PCR; Millipore, Bedford, MA) or by gel extraction (Qia-Quick Gel Extraction Kit; Qiagen, Valencia, CA). Sequencing was performed with dye terminator chemistry (BigDye Terminator, ver. 3 on a 3100.3730 or 3730XL DNA Analyzer; Applied Biosystems, Inc. [ABI], Foster City, CA).

RESULTS

Identification of *IQCB1* Mutations in LCA Patients

In a previous study²⁰ as well as the present one we performed genome-wide homozygosity mapping in a cohort of >150 LCA patients using SNP microarrays. In two isolated LCA patients (42108 and 42109) without known consanguinity and one isolated LCA patient from a consanguineous marriage (BE77905), we identified large homozygous regions encompassing the *IQCB1* gene. The region in patient 42108 spans 17 Mb (1435 SNPs) and is the largest homozygous region identified in this patient's genome. In patient 42109 the interval spans 6 Mb (521 SNPs), but several larger homozygous regions were identified on other chromosomes (the region encompassing the *IQCB1* gene ranks ninth). In patient BE77905 the largest homozygous region encompassing the *IQCB1* gene spans 26 Mb (2337 SNPs).

Direct sequencing of all 13 coding exons of *IQCB1* was therefore performed in patients 42108, 42109, and BE77905. A homozygous 2 bp deletion in exon 6 (c.424_425delTT) of *IQCB1* was identified in patient 42108, which introduces a shift in the open reading frame (Table 1). A homozygous 2 bp duplication in exon 11 (c.1074_1075dup) was identified in patient BE77905, which also introduces a shift in the open reading frame (Table 1). No mutation was detected in patient 42109. The two mutations identified in patients 42108 and BE77905 were previously reported by Otto et al.¹⁸ in patients with SLSN. Because of this finding, we carried out *IQCB1* sequence analysis in 222 additional LCA patients, identifying frameshift and nonsense mutations in nine additional patients of seven families (Table 1).

Two of the mutations (p.R502X and p.Q512X) have not been reported before, while all other mutations were previously identified in patients with SLSN.^{18,21} In a Puerto Rican family, a homozygous nonsense mutation (p.R461X) segregated in a pseudodominant fashion in two affected siblings (MOGL3772 and MOGL3773) and their affected mother (MOGL430). The father carries the mutation p.R461X heterozygously.

Clinical Findings

Reevaluation of the renal function in all 11 patients led to the diagnosis of SLSN in seven patients (Table 2). Thus, in four patients, the diagnosis remains nonsyndromic LCA, despite regular follow-up and inspection of the kidney status. The seven patients with SLSN developed nephronophthisis between ages 3 and 50 years. The other patients retained normal kidney function up to their current ages (age range 3–34 years).

TABLE 1. *IQCB1* Mutations Detected in This Study

Patient ID	Country	Allele 1		Allele 2	
		DNA Variant	Protein Defect	DNA Variant	Protein Defect
42108	Germany	c.424_425del	p.F142PfsX5	c.424_425del	p.F142PfsX5
12786	Germany	c.424_425del	p.F142PfsX5	c.1518_1519del	p.H506NfsX13
BE77905	Morocco	c.1074_1075dup	p.A359EfsX3	c.1074_1075dup	p.A359EfsX3
13079	The Netherlands	c.424_425del	p.F142PfsX5	c.1535_1536insATAGC	p.Q512X
42125	Germany	c.825_828del	p.R275SfsX6	c.1069C>T	p.Q357X
42110	Germany	c.825_828del	p.R275SfsX6	c.1518_1519del	p.H506NfsX13
MOGL3572	United States	c.1465C>T	p.R489X	c.1518_1519del	p.H506NfsX13
MOGL430	Puerto Rico	c.1381C>T	p.R461X	c.1381C>T	p.R461X
MOGL3773*	Puerto Rico	c.1381C>T	p.R461X	c.1381C>T	p.R461X
MOGL3772*	Puerto Rico	c.1381C>T	p.R461X	c.1381C>T	p.R461X
MOGL3309	Italy	c.1504A>T	p.R502X	c.1504A>T	p.R502X

* Daughters of MOGL430.

The ocular phenotypes of SLSN and LCA patients with *IQCB1* mutations are similar and seem to be indistinguishable from each other in this study. The phenotype of LCA patients with *IQCB1* mutations resembles classical LCA with early onset pendular nystagmus, poor fixation at birth, and a nondetectable rod and cone ERG early in the disease process. In addition, all patients in this cohort were found to have high hyperopic refractions (+3.00 to +7.50 D). The acuities at later ages were variable and ranged from 20/70 at age 15 (12786) to light perception at age 10 (MOGL3309).

Two retinal features of patients with *IQCB1* mutations are not typical of the retinal phenotypes associated with the currently known 15 LCA genes. Usually the initial peripheral retinal examination in a 1-to-2-year-old patient with LCA is essentially normal, with relatively normal-appearing retinal pigment epithelium (RPE), foveal appearance, optic disc, and mild narrowing of the retinal arterioles. Pigmentary changes and degeneration of the retina often occur much later. Interestingly in one of the youngest patients (MOGL3309) retinal changes were already prominent at age 18 months, as we noted a striking "lobular" pattern of hypo- and hyperpigmentation outside the retinal arcades (Fig. 1A). This same pattern of abnormalities was seen in another LCA patient (42108) (Fig. 1B) with *IQCB1* mutations at age 34 years. Patient 42125 also has hypopigmentation outside the arcades, but this is not in the clear "lobular" pattern as the previous two (Fig. 1C). Patient 12786 does not show the lobular changes but has a diffuse RPE atrophy with intraretinal pigment epithelial changes (Fig. 1D).

One of the 12 patients (13079) in our cohort had cataract and keratoconus. Other ocular findings that can be associated with LCA (optic disc pallor, maculopathy, macular coloboma) were not seen in these patients.

DISCUSSION

In this study, we describe *IQCB1* mutations in patients with SLSN and in LCA patients without renal failure. This study also confirms the power of genome-wide homozygosity mapping to identify the genetic defect in non-consanguineous patients with an autosomal recessive disease.²¹⁻²⁵

The initial diagnosis of LCA in our cohort of patients was made using strict criteria (poor fixation at birth or within 6 months of age, pendular nystagmus, amaurotic pupils, nondetectable or severely diminished rod and cone ERG amplitudes before age one year, and absence of systemic disease), but a clinical reevaluation of the 11 patients with *IQCB1* mutations showed manifestation of nephronophthisis in seven of them, prompting a change in diagnosis to SLSN. However, four patients maintained normal kidney function up to their current

ages (age range 3-34 years). Considering that the median age for the manifestation of end-stage renal disease in infantile, juvenile, and adolescent nephronophthisis is 1, 13, and 19 years old, respectively,²⁶⁻²⁸ we had expected that if a patient with *IQCB1* mutations is destined to develop kidney disease and failure, our patients would develop renal failure early (before the age of 19 years). However, Otto et al.²¹ extended the range of ages at which end-stage renal disease commences to between age 8 and 47, which is consistent with our results ranging from 3 to 50 years of age. Based on the wide age range in the onset of end-stage renal disease, and the lower mean age of the patients in this study without renal failure compared with those with nephronophthisis (15 vs. 28 years), we cannot exclude that some patients identified in our study will develop renal disease at a later age. Consequently, it is of major importance to search for signs of nephronophthisis in patients with *IQCB1* mutations. Because of the mild symptoms in the early stages, there is often a delay in the diagnosis of nephronophthisis. This causes a risk for sudden death from fluid and electrolyte imbalance.²⁷ Nephronophthisis patients receiving kidney transplants have excellent outcomes that are shown to be better compared with the general pediatric transplant population.²⁹ We therefore recommend that all LCA patients be screened for *IQCB1* mutations to follow them more closely for kidney disease.

When we compared the *IQCB1* mutations found in patients with SLSN^{18,21} with those with LCA to determine possible correlations between type or location of the mutations and the resulting phenotypes in our patients, we did not find any significant patterns. The mutations that were identified in the four LCA patients without renal disease were previously found in patients with SLSN.^{18,21,29} All *IQCB1* mutations were deleterious mutations, presumably resulting in nonfunctional or absent *IQCB1* protein. The wide variability in onset, or even absence, of kidney failure suggests the presence of unknown genetic and/or environmental modifier effects and factors. In line with this hypothesis, a genetic modifier in *RPGRIP1L* has recently been described to affect the severity of retinal degeneration in ciliopathies.³⁰

The retinal dystrophy of our LCA patients who later developed SLSN and those LCA patients who did not is indistinguishable. Of interest is the fact that we found very similar retinal phenotypes in three unrelated patients with *IQCB1* mutations (Figs. 1A, 1B). We documented in these three patients a "lobular" pattern of hypo- and hyperpigmentation around the vascular arcades. We have not seen this pattern in LCA patients with mutations in other LCA genes. We have seen hypopigmented and salt-and-pepper changes in other LCA genetic subtypes but not like the ones we have observed in LCA

TABLE 2. Clinical Characteristics of Patients with IQCB1 Mutations

Patient ID	Sex	Current Age (y)	Kidney Findings	Visual Acuity	Refractive Error (Diopter)	Fundus	ERG	Perimetry
42108	F	34	Normal	0.1/0.1(20/200)	Hyperopia (+6.5)	Vitreous cells, optic nerve normal, narrowed retinal vessels, no foveolar light reflex, relatively preserved RPE in posterior pole, and hypopigmented spots surrounded by hyperpigmented areas in a "lobular" pattern outside the arcades	Nondetectable	Concentric narrowing to >5°
BE77905	F	3	Normal	0.01/0.01	Hyperopia (+5.0 OD, +4.0 OS)	Granular fundus (salt-and-pepper pigmentation); macula and optic disc normal	Nondetectable (1 year)	NA
12786	F	15	Normal	0.30/0.30 (20/70)	Esotropia of the right eye	Granular flecks at the posterior pole, normal optic nerve	Nondetectable	NA
13079	M	38	Nephronophthisis, kidney transplant at age 33	No light perception	NA	Peripheral pigmentations and Coats's like changes	Nondetectable (1 year)	NA
42125	M	28	Nephronophthisis, chronic sclerotic tubulo-interstitial nephropathy with extensive tubular atrophy; dialysis since age 23	0.05/0.05 (20/400)	Hyperopia (+7.5)	Normal optic nerve, slightly narrowed and straightened retinal vessels, very mild macular RPE atrophy, peripheral hypopigmented areas with mild RPE clumping	Nondetectable	Concentric narrowing to 5°
42110	F	56	Nephronophthisis; dialysis since age 50	0.1/0.2	Hyperopia (+5.5 OD, +6.0 OS)	NA	Minimal responses in 33 Hz flicker	Concentric narrowing to 8°
MOGL3572	M	8	Normal	Fix and follow inconsistently	Hyperopia (+6.0)	Granular-appearing fundus; normal optic nerve	Nondetectable	NA
MOGL430	M	37	Nephronophthisis, kidney transplant at age 24	Light perception	NA	NA	Nondetectable	NA
MOGL3773*	F	16	Nephronophthisis, dialysis since age 13	Light perception	NA	NA	Nondetectable	NA
MOGL3772*	F	12	Nephronophthisis, kidney transplant at age 9	Light perception	NA	NA	Nondetectable	NA
MOGL3509	F	10	Nephronophthisis diagnosed at age 3	Light perception	Hyperopia (+3.0 OD, +5.5 OS)	Optic nerve normal-appearing, narrowed retinal arterioles, relatively normal-appearing fovea and macula, hypopigmented areas surrounded by hyperpigmented areas in a "lobular" pattern	Nondetectable	NA

* Daughters of MOGL430. NA, not available.

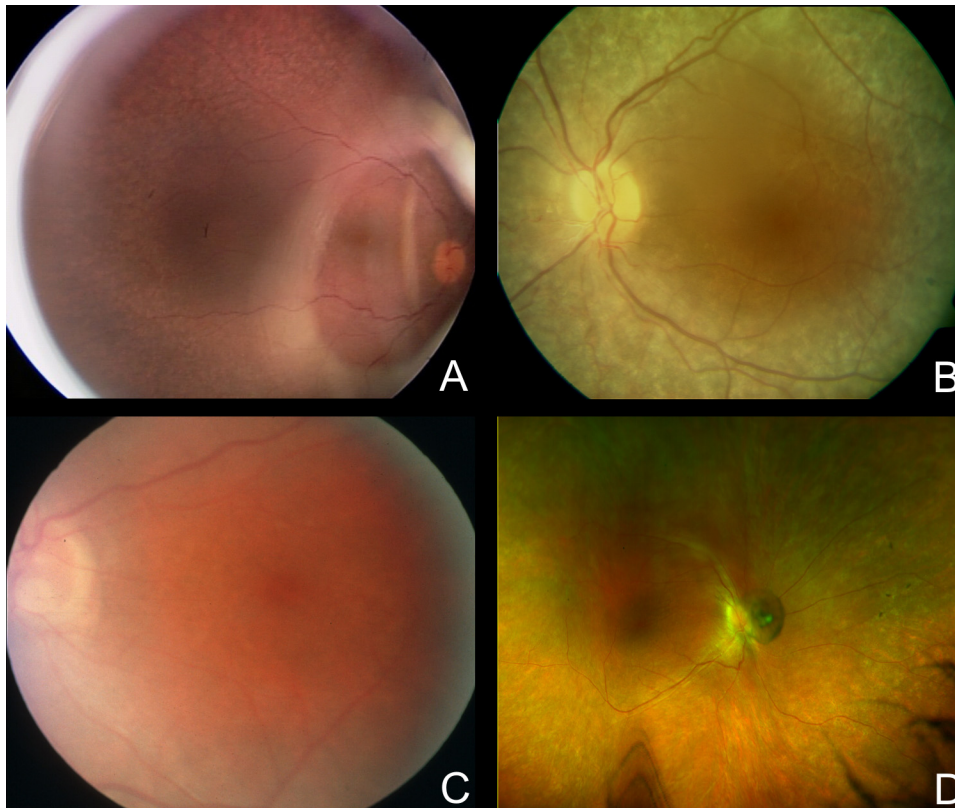


FIGURE 1. Fundus pictures of patients with *IQCB1* variants. (A) Retacam retinal photograph of the right eye of MOGL3309 at age 18 months. Note the relatively normal color of the optic disc, the narrowing of the retinal arterioles, and the relatively normal-appearing fovea and macula. Outside the arcades are hypopigmented areas surrounded by hyperpigmented lesions in a “lobular pattern.” (B) Retinal photograph of the left eye of patient 42108 at age 34 years old, showing a very similar retinal pattern as MOGL3309, with a relatively normal-appearing optic disc and vessels and striking “lobular pattern” of hypo- and hyperpigmentary changes outside the vascular arcade. (C) Retinal photograph of the left eye of patient 42125 at age 28 years old, showing a slightly hazy retina, with relatively normal optic disc appearance, an abnormal peripapillary white ring and narrow retinal arterioles, and no pigmentary changes or lobular retinal changes. (D) The retinal photograph of the right eye at age 15 years old of patient 12786 shows a relatively small optic disc of good color with a prominent white, peripapillary ring, narrow arterioles, a normal appearing macula, and absence of intraretinal flecks or lobular

changes seen in (A) and (B) but does clearly show hypopigmented lesions, especially around the vascular arcades. There is diffuse RPE atrophy and beaten metal changes, more prominent nasally and superiorly, with a small number of intraretinal pigment changes. There is retinal remodelling, with straightening of the retinal vessels.

patients with *IQCB1* mutations. Salt-and-pepper changes are well known in patients with *LRAT* and with *RPE65* mutations, but these salt (hypopigmented)-and-pepper (pigmented) changes are very fine and subtle.^{20,31} The hypopigmented changes alternating with hyperpigmented changes observed in LCA patients with *IQCB1* mutations are large and lobular (Figs. 1A, 1B, and 1D). Further genotype-phenotype correlation studies must be performed to confirm this disease pattern. Some ocular findings are more often found with certain LCA genotypes and may be characteristic for them.^{32–34} In the cohort of 225 patients that was analyzed in this study, *IQCB1* mutations were identified in 11 probands of nine families. When we exclude patients that were diagnosed as SLSN after the molecular analysis, the frequency of *IQCB1* mutations in LCA patients is estimated to be 2%. The most frequent mutations identified in this study (p.F142PfsX5, p.H506NfsX13, p.R275SfsX6) were found in patients of European ancestry, in concordance with previous studies.^{18,21} This result could suggest a core of founder mutations whose origin may be northern Europe (involving Germany, The Netherlands, and Switzerland).

In conclusion, this study shows that the onset of renal failure in patients with *IQCB1* mutations is highly variable, and that mutations are also found in LCA patients without nephronophthisis. The severity or absence of renal failure might be caused by unknown modifier alleles and/or environmental factors. Because of the importance of finding kidney disease as early as possible, as early intervention improves patient management and clinical outcome, we suggest that LCA patients should be routinely tested for *IQCB1* mutations. Those LCA patients with *IQCB1* mutations should then be routinely and regularly tested for kidney dysfunction with simple clinical tests. Consequently, we also recommend that all

known *IQCB1* mutations are added to the Asper Ophthalmic LCA disease chip¹⁹ and advise ophthalmologists to incorporate this directive into their clinical practices.

Acknowledgments

The authors thank all the LCA patients and their families for their participation.

References

1. Koenekoop RK. An overview of Leber congenital amaurosis: a model to understand human retinal development. *Surv Ophthalmol.* 2004;49:379–398.
2. Stone EM. Leber congenital amaurosis: a model for efficient genetic testing of heterogeneous disorders: LXIV Edward Jackson memorial lecture. *Am J Ophthalmol.* 2007;144:791–811.
3. Perrault I, Delphin N, Hanein S, et al. Spectrum of NPHP6/CEP290 mutations in Leber congenital amaurosis and delineation of the associated phenotype. *Hum Mutat.* 2007;28:416.
4. den Hollander AI, Koenekoop RK, Yzer S, et al. Mutations in the CEP290 (NPHP6) gene are a frequent cause of Leber congenital amaurosis. *Am J Hum Genet.* 2006;79:556–561.
5. Simonelli F, Ziviello C, Testa F, et al. Clinical and molecular genetics of Leber's congenital amaurosis: a multicenter study of Italian patients. *Invest Ophthalmol Vis Sci.* 2007;48:4284–4290.
6. Vallespin E, Lopez-Martinez MA, Cantalapiedra D, et al. Frequency of CEP290 c. 2991_1655A > G mutation in 175 Spanish families affected with Leber congenital amaurosis and early-onset retinitis pigmentosa. *Mol Vis.* 2007;13:2160–2162.
7. Baala L, Audollent S, Martinovic J, et al. Pleiotropic effects of CEP290 (NPHP6) mutations extend to Meckel syndrome. *Am J Hum Genet.* 2007;81:170–179.

8. Frank V, den Hollander AI, Bruchle NO, et al. Mutations of the CEP290 gene encoding a centrosomal protein cause Meckel-Gruber syndrome. *Hum Mutat.* 2008;29:45–52.
9. Helou J, Otto EA, Attanasio M, et al. Mutation analysis of NPHP6/CEP290 in patients with Joubert syndrome and Senior-Loken syndrome. *J Med Genet.* 2007;44:657–663.
10. Leitch CC, Zaghoul NA, Davis EE, et al. Hypomorphic mutations in syndromic encephalocele genes are associated with Bardet-Biedl syndrome. *Nat Genet.* 2008;40:443–448.
11. Sayer JA, Otto EA, O'Toole JF, et al. The centrosomal protein nephrocystin-6 is mutated in Joubert syndrome and activates transcription factor ATF4. *Nat Genet.* 2006;38:674–681.
12. Valente EM, Silhavy JL, Brancati F, et al. Mutations in CEP290, which encodes a centrosomal protein, cause pleiotropic forms of Joubert syndrome. *Nat Genet.* 2006;38:623–625.
13. Chang B, Khanna H, Hawes N, et al. In-frame deletion in a novel centrosomal/ciliary protein CEP290/NPHP6 perturbs its interaction with RPGR and results in early-onset retinal degeneration in the rd16 mouse. *Hum Mol Genet.* 2006;15:1847–1857.
14. Gorden NT, Arts HH, Parisi MA, et al. CC2D2A is mutated in Joubert syndrome and interacts with the ciliopathy-associated basal body protein CEP290. *Am J Hum Genet.* 2008;83:559–571.
15. Kim J, Krishnaswami SR, Gleeson JG. CEP290 interacts with the centriolar satellite component PCM-1 and is required for Rab8 localization to the primary cilium. *Hum Mol Genet.* 2008;17:3796–3805.
16. Schafer T, Putz M, Lienkamp S, et al. Genetic and physical interaction between the NPHP5 and NPHP6 gene products. *Hum Mol Genet.* 2008;17:3655–3662.
17. Tsang WY, Bossard C, Khanna H, et al. CP110 suppresses primary cilia formation through its interaction with CEP290, a protein deficient in human ciliary disease. *Dev Cell.* 2008;15:187–197.
18. Otto EA, Loeyes B, Khanna H, et al. Nephrocystin-5, a ciliary IQ domain protein, is mutated in Senior-Loken syndrome and interacts with RPGR and calmodulin. *Nat Genet.* 2005;37:282–288.
19. Zernant J, Kulm M, Dharmaraj S, et al. Genotyping microarray (disease chip) for Leber congenital amaurosis: detection of modifier alleles. *Invest Ophthalmol Vis Sci.* 2005;46:3052–3059.
20. den Hollander AI, Lopez I, Yzer S, et al. Identification of novel mutations in patients with Leber congenital amaurosis and juvenile RP by genome-wide homozygosity mapping with SNP microarrays. *Invest Ophthalmol Vis Sci.* 2007;48:5690–5698.
21. Otto EA, Helou J, Allen SJ, et al. Mutation analysis in nephronophthisis using a combined approach of homozygosity mapping, CEL I endonuclease cleavage, and direct sequencing. *Hum Mutat.* 2008;29:418–426.
22. Collin RWJ, Littink KW, Klevering BJ, et al. Identification of a 2 Mb human ortholog of Drosophila eyes shut/spacemaker that is mutated in patients with retinitis pigmentosa. *Am J Hum Genet.* 2008;83:594–603.
23. den Hollander AI, Koenekoop RK, Mohamed MD, et al. Mutations in LCA5, encoding the ciliary protein lebercilin, cause Leber congenital amaurosis. *Nat Genet.* 2007;39:889–895.
24. Thiadens AAHJ, den Hollander AI, Roosing S, et al. Homozygosity mapping reveals PDE6C mutations in patients with early-onset cone photoreceptor disorders. *Am J Hum Genet.* 2009;85:240–247.
25. Hildebrandt F, Heeringa SF, Ruschendorf F, et al. A systematic approach to mapping recessive disease genes in individuals from outbred populations. *PLoS Genet.* 2009;5:e1000353.
26. Gagnadoux MF, Habib R. Polycystic kidney-disease in children. *Pediatrics.* 1989;44:539–544.
27. Hildebrandt F, Waldherr R, Kutt R, Brandis M. The nephronophthisis complex: clinical and genetic aspects. *Clin Invest.* 1992;70:802–808.
28. Omran H, Fernandez C, Jung M, et al. Identification of a new gene locus for adolescent nephronophthisis, on chromosome 3q22 in a large Venezuelan pedigree. *Am J Hum Genet.* 2000;66:118–127.
29. Hamiwka LA, Midgley JP, Wade AW, Martz KL, Grisaru S. Outcomes of kidney transplantation in children with nephronophthisis: an analysis of the North American Pediatric Renal Trials and Collaborative Studies (NAPRTCS) registry. *Pediatr Transplant.* 2008;12:878–882.
30. Khanna H, Davis EE, Murga-Zamalloa CA, et al. A common allele in RPGRIP1L is a modifier of retinal degeneration in ciliopathies. *Nat Genet.* 2009;41:739–745.
31. Lorenz B, Gyurus P, Preising M, et al. Early-onset severe rod-cone dystrophy in young children with RPE65 mutations. *Invest Ophthalmol Vis Sci.* 2000;41:2735–2742.
32. Galvin JA, Fishman GA, Stone EM, Koenekoop RK. Clinical phenotypes in carriers of Leber congenital amaurosis mutations. *Ophthalmology.* 2005;112:349–356.
33. Dharmaraj S, Leroy BP, Sohocki MM, et al. The phenotype of Leber congenital amaurosis in patients with AIPL1 mutations. *Arch Ophthalmol.* 2004;122:1029–1037.
34. den Hollander AI, Roepman R, Koenekoop RK, Cremers FPM. Leber congenital amaurosis: genes, proteins and disease mechanisms. *Prog Ret Eye Res.* 2008;27:391–419.