

Effect of Methylimidazole-Induced Hypothyroidism in a Model of Low Retinal Neovascular Incidence

Bruce A. Berkowitz,^{1,2} Hongmei Luan,¹ and Robin L. Roberts¹

PURPOSE. To determine the effect of methylimidazole (MMI)-induced hypothyroidism in a newborn rat model of low retinal neovascular (NV) incidence.

METHODS. Control and MMI-exposed newborn rats were raised either in room air or variable oxygen (40/15) until P14. All groups were then exposed to room air between postnatal day (P)14 and P20. Dams drank either tap water or water containing MMI. Eyes of animals in all groups were enucleated, and retinas were removed and stained with adenosine diphosphate and analyzed for peripheral avascularity, vascular density, and NV incidence and severity.

RESULTS. In the control group, MMI treatment did not promote the development of retinal NV although a linear relationship ($r = 0.99$, $P < 0.01$) was found between increased MMI dose and lower peripheral retinal vascular densities. In all the 40/15 groups, peripheral retinal vascular densities were lower ($P < 0.05$) than normal and were not a function of MMI dose. Increased MMI dose produced increased retinal incidence of NV ($r = 0.99$, $P < 0.05$).

CONCLUSIONS. These data are consistent with the notions that thyroid function contributes to normal retinal vascular density and that hypothyroidism can play a permissive role in the development of retinal NV. (*Invest Ophthalmol Vis Sci.* 2004; 45:919-921) DOI:10.1167/iovs.03-0914

Very-low-birth-weight infants are at substantially higher risk for blinding complications, such as the development of retinal neovascularization (NV) associated with retinopathy of prematurity (ROP). To minimize the impact of retinal NV on vision, photocoagulation is currently used, but it is a destructive approach that is not always effective. A better understanding is needed of the pathogenic factors involved in the formation of retinal NV in ROP so that new methods of prevention and treatment can be developed.

To date, studies have demonstrated an important link between insulin-like growth factor (IGF)-1 and normal and abnormal retinal vascular development.¹⁻³ IGF-1 is, among other functions, a downstream modulator of thyroid activity. Infants born very prematurely (<27 weeks) are more likely to have low thyroxine (T_4) levels, indicating an abnormal hypothalamus-pituitary-thyroid axis function.^{4,5} These considerations raise the possibility that hypothyroidism may be involved in the formation of retinal NV.

From the ¹Department of Anatomy and Cell Biology, Wayne State University, Detroit, Michigan; and the ²Kresge Eye Institute, Wayne State University, Detroit, Michigan.

Supported by National Eye Institute Grant EY10221 (BAB).

Submitted for publication August 21, 2003; revised October 1 and October 13, 2003; accepted November 17, 2003.

Disclosure: **B.A. Berkowitz**, None; **H. Luan**, None; **R.L. Roberts**, None

The publication costs of this article were defrayed in part by page charge payment. This article must therefore be marked "advertisement" in accordance with 18 U.S.C. §1734 solely to indicate this fact.

Corresponding author: Bruce A. Berkowitz, Department of Anatomy and Cell Biology, Wayne State University School of Medicine, 540 E. Canfield, Detroit, MI 48201; baberko@med.wayne.edu.

In this study, we used a clinically relevant model of ROP involving newborn rats exposed to a variable oxygen environment from postnatal day (P)0 to P14 and then to room air between P15 and P20.⁶⁻⁸ In animals exposed to an oxygen environment that alternates between 40% and 15% every other day (the 40/15 model), only a small percentage (<10%) of the rat pups exhibit 1 clock hour of NV in the peripheral retina.⁷ We hypothesized that hypothyroidism would substantially decrease retinal vessel density in control rats and increase retinal NV in the 40/15 model. To investigate, we measured peripheral retinal vessel density, avascularity, and the incidence and severity of retinal NV in treated control and 40/15 rat pups with MMI, a drug used clinically to treat hyperthyroidism. MMI produces reversible hypothyroidism in normal rats and alters retinal development.⁹⁻¹⁴

METHODS

The animals were treated in accordance with the NIH Guide for the Care and Use of Laboratory Animals and the ARVO Statement for the Use of Animals in Ophthalmic and Vision Research.

MMI

Between P0 and P20, rat pups were raised in room air and received MMI (0.05%, 0.1%, 0.13%, or 0.15% wt/vol; Sigma-Aldrich, St. Louis, MO), added to the drinking water of the dam. Control dams and their pups drank untreated water. In the control and 0.13% and 0.15% MMI-treated 40/15 groups, measurements of T_4 , thyroid stimulating hormone (TSH), and IGF-1 were performed (Anilytics Inc., Gaithersburg, MD) on pooled blood samples. Pooled blood samples were used because of the limited amount of blood available from individual newborn rats (<30 g). However, retinal histopathology was not investigated, because 0.13% and 0.15% MMI doses usually resulted in substantial (>90%) pup attrition (data not shown).

Animal Model

Table 1 shows the number of animals in each group. The newborn rat model of ROP has been described in detail elsewhere.⁷ Briefly, Sprague-Dawley dams and litters (12-15 pups per litter) were housed in modified pediatric incubators where the oxygen levels were varied between 40% and 15% (40/15) every 24 hours for the first 14 days after birth. Rats were then allowed to recover in room air (21%) during the next 6 days until P20. The drinking water in one of two cages per incubator was supplemented with MMI between P0 and P20. Holes in the sides of the pediatric incubators were purposely not sealed so that the incubators would be somewhat leaky and minimize the unwanted buildup of carbon dioxide. Although we did not directly assess whether airflow at the holes reversed during the variable oxygen exposure, it is unlikely that this happened, because the computer-controlled (Oxycycler; Biospherix, Ltd., Redfield, NY) variable oxygen procedure constantly maintain positive pressure inside the incubator by injecting the appropriate mixture of 100% oxygen or nitrogen to maintain either a 40% or 15% oxygen environment. In addition, each incubator housed one untreated and one MMI-treated 40/15 cage and so these groups experienced similar variable oxygen exposures.

TABLE 1. Summary of Pathology

| Group | Body Weight (g) | Peripheral Vascular Density* (AU) | Peripheral Avascular Incidence (%) | Peripheral Avascular Severity (%) | Neovascular Severity (Clock Hours) |
|------------------------------------|-----------------|-----------------------------------|------------------------------------|-----------------------------------|------------------------------------|
| C (<i>n</i> = 20) | 34.3 ± 1.4 | 100 ± 5 | 0 | — | — |
| C + 0.05% MMI (<i>n</i> = 18) | 22.6 ± 1.0† | 76 ± 2† | 0 | — | — |
| C + 0.1% MMI (<i>n</i> = 14) | 14.9 ± 0.3†‡ | 53 ± 3†‡ | 0 | — | — |
| 40/15 (<i>n</i> = 113) | 32.8 ± 1.8 | 63 ± 2† | 0 | — | 1† |
| 40/15 + 0.05% MMI (<i>n</i> = 26) | 18.9 ± 0.7†§ | 52 ± 1†‡¶ | 19 (5/26)† | 4.1 ± 0.5 | 2† |
| 40/15 + 0.1% MMI (<i>n</i> = 21) | 14.4 ± 0.4†‡§ | 67 ± 3† | 48 (10/21)† | 6.5 ± 0.8 | 2† |

* Normalized to C group.

† *P* < 0.05, compared with C.

‡ *P* < 0.05, compared with C + 0.05%.

§ *P* < 0.05, compared with 40/15.

¶ *P* ≤ 0.05, compared with 40/15 + 0.05% MMI.

|| *P* < 0.05, compared with 40/15 + 0.1% MMI.

Histology Analysis

Histologic analyses were performed as previously described on adenosine diphosphatase (ADPase)-stained flatmounts.¹⁵ Briefly, on day 20 of life, rat pups were killed while under urethane anesthesia (0.083 mL of a 36% solution of urethane/20 g animal weight, intraperitoneally, freshly made daily; Aldrich, Milwaukee, WI), by intracardiac injection of a saturated solution of potassium chloride (KCl). Both eyes were enucleated and the retinas removed as previously described.¹⁵ The extent of peripheral avascularity (i.e., the peripheral avascular severity or the ratio of the size of central vascular to the size of peripheral avascular retina was determined with NIH Image (available by ftp at zippy.nimh.nih.gov/ or at http://rsb.info.nih.gov/nih-image; developed by Wayne Rasband, National Institutes of Health, Bethesda, MD) from the captured image of ADPase-stained flatmounts, as previously described.¹⁶ Vascular density was measured by first converting the captured image to a binary image by manually adjusting the threshold level so that most of the vessels were highlighted with a minimum of background (as assessed visually). In all analyzable quadrants, a fixed size region of interest was placed over the peripheral retina, and the ratio of black to white pixels was determined for each quadrant. Ratios from all four quadrants in both eyes were averaged and used as a single data point. To compare the extent of peripheral avascularity and vascular density, a two-sided unpaired Student's *t*-test was performed. NV incidence was determined from the ADPase-stained flatmounts from the ratio of the number of rats with any detectable retinal NV to the total number of rats in that group.¹⁷ Severity was determined only from retinas with some degree of NV.¹⁷ Retinal NV was identified as abnormal vascular structures (multicellular tufts or sheets) emanating from the normal vasculature at the junction of the vascular and avascular retina. To determine NV severity, three investigators independently scored each ADPase-stained retinal flatmount according to clock hours of NV in a masked fashion. The median number of clock hours per retina of the three investigators is reported. To determine severity of NV, the examiner mentally superimposed a clock face on the retinal surface and determined the number of clock-hour (a score from 0 to 12) areas containing abnormal vessel growth. To compare the severity, a two-sample Mann-Whitney rank sum test (two-sided) was used. To compare the incidence, a χ^2 test was performed (2×2). *P* < 0.05 was considered significant.

RESULTS

A summary of the body weights, peripheral avascular incidence, vascular density, and retinal NV incidence and severity in all groups in the study is presented in Table 1 and Figure 1. Compared with non-MMI control pups, newborn rats raised in room air and receiving MMI exhibited significant (*P* < 0.05)

changes (Table 1). Retinal NV was not found in control retinas, although retinal vascular density in the peripheral retina was significantly lower (*P* < 0.05) in both groups of MMI-treated pups than in the control group.

Compared with untreated 40/15 pups, 40/15 newborn rats receiving either 0.05% or 0.1% MMI exhibited significant (*P* < 0.05) changes in body weight, peripheral avascular incidence and severity, and NV incidence (Table 1, Fig. 1). Furthermore, retinal NV incidence was linearly related (*r* = 0.99, *P* < 0.05) to the dose of MMI in the dams' drinking water (Fig. 1). No significant (*P* > 0.05) difference in NV severity was found between treated and untreated 40/15 groups.

DISCUSSION

In this study, we investigated the effect of MMI-induced hypothyroidism in a model of low retinal NV incidence. MMI treatment is an established method of inducing thyroid dysfunction in rodent models.^{18–20} Compared with untreated age-matched control animals, 0.13% and 0.15% MMI-treated 40/15 rats had significantly (*P* < 0.05) lower T4 (0 [*n* = 14] vs. 3.0 ± 0.1 [*n* = 20] μ g/dL, respectively, mean ± SEM), elevated TSH levels in (22.7 ± 1.9 [*n* = 14] vs. 1.3 ± 0.1 [*n* = 20] ng/mL), and lower plasma IGF-1 levels (2.63 ± 0.2 [*n* = 17] vs. 6.40 ± 0.7 [*n* = 10] nM). Hypothyroidism was not directly measured at

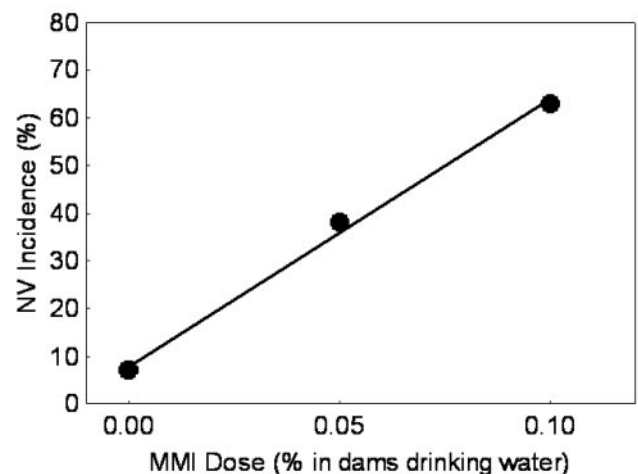


FIGURE 1. Plot of the retinal NV incidence versus dose of MMI in the 40/15 groups. A linear relationship (*r* = 0.99, *P* < 0.05) was found.

lower doses of MMI or in MMI-treated control animals. However, based on the similar body weights of the untreated control and 40/15 groups, as well as between treated groups, it seems likely that MMI also effectively produced low thyroid function in the control rats and that the 40/15 procedure, per se, did not alter thyroid function. Although we cannot rule out other possible actions of MMI, it appears to be a useful approach for studying the role of hypothyroidism in experimental ROP.

The present data in control rats (Table 1) are consistent with the results of Hellstrom et al.² and others,^{9,13,20,21} who reported that subnormal IGF-1 levels are associated with attenuation of retinal vessel development. Vascular density was lower in the 40/15+0.05% MMI group than in both 40/15 untreated and 40/15+0.1% MMI groups, but the densities in these latter two groups did not differ. Given the small number of groups involved ($n = 3$), more work is needed to determine whether this "dip" in vascular density at the 0.05% MMI dose represents a trend or simply a scatter in the data. Nonetheless, a lower-than-normal vessel density was found in all the MMI treatment groups.

It has been suggested that ROP is initiated by early, lower-than-normal IGF-1-induced delayed retinal vascular growth after premature birth.² In this scenario, initially low plasma IGF-1 levels result in impaired vascular development, and, as maturing avascular retina becomes presumably hypoxic, vascular endothelial growth factor accumulates in the vitreous.² As IGF-1 levels increase with age, retinal NV subsequently develops.² The present experiments in control rats are consistent with this hypothesis. MMI-treated control rats demonstrated significant reductions in peripheral vascular density but did not have large avascular regions (Table 1). It is not clear that lower vascular density is sufficient to produce retinal hypoxia. In addition, IGF-1 was probably maintained at lower-than-normal levels throughout the experimental period. Under these conditions (lack of avascular retina and constantly subnormal serum IGF-1 levels), development of retinal NV was not expected.

In contrast, experiments in 40/15 rats did not completely support the hypothesis. First, similar to control rats treated with MMI, untreated 40/15 rats had subnormal retinal vascular density without regions of avascular retina, and no evidence for growth retardation (based on similar body weight between 40/15 and control rats). Nonetheless, retinal NV developed in these rats (7% incidence, 1 clock hour severity). Second, in 40/15 rats, serum IGF-1 levels were probably constantly lower than normal throughout the 20-day time course and so one might not expect the finding of an association between MMI dose and NV incidence. Further, in preliminary experiments using the standard 40/15 timing protocol and MMI treatment only between P0 and P10, an anticipated increase in retinal NV over untreated 40/15 rats at P20 was not found (data not shown). More work is needed to clarify which aspects of hypothyroidism (e.g., only low IGF-1 or some combination of other hormonal changes) act in promoting retinal NV. Nonetheless, taken together, the results in the present study demonstrate for the first time that if some risk of NV already exists, hypothyroidism can have a positive synergistic effect on the appearance of retinal NV.

References

- Smith LE, Shen W, Perruzzi C, et al. Regulation of vascular endothelial growth factor-dependent retinal neovascularization by insulin-like growth factor-1 receptor. *Nat Med*. 1999;5:1390-1395.
- Hellstrom A, Perruzzi C, Ju M, et al. Low IGF-I suppresses VEGF-survival signaling in retinal endothelial cells: direct correlation with clinical retinopathy of prematurity. *Proc Natl Acad Sci USA*. 2001;98:5804-5808.
- Hellstrom A, Carlsson B, Niklasson A, et al. IGF-I is critical for normal vascularization of the human retina. *J Clin Endocrinol Metab*. 2002;87:3413-3416.
- Kirsten D. The thyroid gland: physiology and pathophysiology. *Neonatal Network*. 2000;19:11-26.
- Beeram MR, Wilson DP. Hypothyroxinemia of prematurity: rite of passage or therapeutic necessity? *Tex Med*. 2000;96:60-63.
- Roberto KA, Tolman BL, Penn JS. Long-term retinal vascular abnormalities in an animal model of retinopathy of prematurity. *Curr Eye Res*. 1996;15:932-937.
- Penn JS, Henry MM, Wall PT, Tolman BL. The range of PaO₂ variation determines the severity of oxygen-induced retinopathy in newborn rats. *Invest Ophthalmol Vis Sci*. 1995;36:2063-2070.
- Penn JS, Henry MM, Tolman BL. Exposure to alternating hypoxia and hyperoxia causes severe proliferation retinopathy in the newborn rat. *Pediatr Res*. 1994;36:724-731.
- Vargas F, Fernandez-Rivas A, Garcia EJ, Garcia dR. Endothelium-dependent and endothelium-independent vasodilation in hyperthyroid and hypothyroid rats. *Pharmacology*. 1995;51:308-314.
- Sevilla-Romero E, Munoz A, Pinazo-Duran MD. Low thyroid hormone levels impair the perinatal development of the rat retina. *Ophthalmic Res*. 2002;34:181-191.
- Takiguchi Y, Satoh N, Hashimoto H, Nakashima M. Reversal effect of thyroxine on altered vascular reactivity in diabetic rats. *J Cardiovasc Pharmacol*. 1989;13:520-524.
- Takiguchi Y, Satoh N, Hashimoto H, Nakashima M. Changes in vascular reactivity in experimental diabetic rats: comparison with hypothyroid rats. *Blood Vessels*. 1988;25:250-260.
- Tilton RG, Pugliese G, Chang K, et al. Effects of hypothyroidism on vascular 125I-albumin permeation and blood flow in rats. *Metabolism*. 1989;38:471-478.
- Navegantes LC, Silveira LC, Santos GL. Effect of congenital hypothyroidism on cell density in the ganglion cell layer of the rat retina. *Braz J Med Biol Res*. 1996;29:665-668.
- Berkowitz BA, Berlin ES, Zhang W. Variable supplemental oxygen during recovery does not reduce retinal neovascular severity in experimental ROP. *Curr Eye Res*. 2001;22:401-404.
- Penn JS, Henry MM. Evaluation of blood vessel assessment techniques in animals with retinal vascular disease. *J Ophthalmic Photogr*. 1996;18:26-34.
- Penn JS, Tolman BL, Lowery LA. Variable oxygen exposure causes preretinal neovascularization in the newborn rat. *Invest Ophthalmol Vis Sci*. 1993;34:576-585.
- Ramos S, Goya L, Martin MA, Escriva F, Pascual-Leone AM. Influence of hypothyroidism on circulating concentrations and liver expression of IGF-binding proteins mRNA from neonatal and adult rats. *J Endocrinol*. 2002;172:363-373.
- Ramos S, Goya L, Alvarez C, Pascual-Leone AM. Mechanism of hypothyroidism action on insulin-like growth factor-I and -II from neonatal to adult rats: insulin mediates thyroid hormone effects in the neonatal period. *Endocrinology*. 1998;139:4782-4792.
- Cristovao FC, Bisi H, Mendonca BB, Bianco AC, Bloise W. Severe and mild neonatal hypothyroidism mediate opposite effects on Leydig cells of rats. *Thyroid*. 2002;12:13-18.
- Ramos S, Goya L, Alvarez C, Martin MA, Pascual-Leone AM. Effect of thyroxine administration on the IGF/IGF binding protein system in neonatal and adult thyroidectomized rats. *J Endocrinol*. 2001;169:111-122.