

# In Vivo Retinal Nerve Fiber Layer Thickness Measured by Optical Coherence Tomography Predicts Visual Recovery after Surgery for Parachiasmal Tumors

Helen V. Danesh-Meyer,<sup>1</sup> Taras Papchenko,<sup>1</sup> Peter J. Savino,<sup>2</sup> Andrew Law,<sup>3</sup> James Evans,<sup>4</sup> and Greg D. Gamble<sup>5</sup>

**PURPOSE.** Restoration of visual function after neurosurgery for parachiasmal tumors is variable and unpredictable. The current study was conducted to determine whether in vivo retinal nerve fiber layer (RNFL) thickness measurements predict the visual recovery of such patients.

**METHODS.** Forty patients undergoing surgical resection of parachiasmal lesions were prospectively assessed before surgery with a neuro-ophthalmic examination, involving standard automated visual field (VF) testing and optical coherence tomography (OCT) measurements of RNFL thickness, which was the prespecified marker for axonal loss. Tests were repeated within 6 weeks after surgery.

**RESULTS.** Thinner preoperative RNFL thickness was associated with worse visual acuity (VA) and VF mean deviation (MD). Patients with normal preoperative RNFL had significant improvement in mean VA after surgery, from 20/40 to 20/25 ( $P = 0.028$ ), whereas patients with thin RNFL did not improve (20/80 to 20/60,  $P = 0.177$ ). Eyes with normal RNFL showed improvement in MD ( $-7.0$  dB before surgery,  $-3.5$  dB after surgery,  $P = 0.0007$ ) unlike eyes with thin RNFLs, which had no significant improvement after surgery ( $-15.3$  dB before and  $-13.3$  dB after surgery,  $P = 0.191$ ). RNFL thickness increased by 1% after surgery among all eyes ( $P = 0.04$ ). Eyes with severe VF defects ( $MD \leq -10$  dB) but normal preoperative RNFL thickness showed a postoperative improvement in MD of 14.6 dB compared with 1.6 dB ( $P < 0.0001$ ) in eyes with thin RNFL before surgery, despite no difference in MD before surgery (normal RNFL MD,  $-22.3$  dB; thin RNFL MD,  $-20.8$  dB;  $P = 0.7$ ).

**CONCLUSIONS.** Patients who have objectively measurable RNFL loss at the time of surgery for chiasmal compressive lesions are less likely to have return of VA or VF after surgery. (*Invest Ophthalmol Vis Sci.* 2008;49:1879-1885) DOI:10.1167/iovs.07-1127

From the Departments of <sup>1</sup>Ophthalmology and <sup>5</sup>Medicine, University of Auckland, Auckland, New Zealand; <sup>2</sup>Neuro-ophthalmology Service, Wills Eye Institute, Philadelphia, Pennsylvania; the <sup>3</sup>Department of Neurosurgery, Auckland Hospital, Auckland, New Zealand; and the <sup>4</sup>Department of Neurosurgery, Thomas Jefferson University, Philadelphia, Pennsylvania.

Supported by Alcon NZ, which provided TP unrestricted support as an Optic Nerve Research Fellow.

Submitted for publication August 29, 2007; revised October 4, 2007, and January 23, 2008; accepted March 20, 2008.

Disclosure: **H.V. Danesh-Meyer**, None; **T. Papchenko**, Alcon NZ (F); **P.J. Savino**, None; **A. Law**, None; **J. Evans**, None; **G.D. Gamble**, None

The publication costs of this article were defrayed in part by page charge payment. This article must therefore be marked "advertisement" in accordance with 18 U.S.C. §1734 solely to indicate this fact.

Corresponding author: Helen V. Danesh-Meyer, Department of Ophthalmology, University of Auckland, Private Bag 92019, Auckland, New Zealand; h.daneshmeyer@auckland.ac.nz.

Optic nerve compression by mass lesions at the optic chiasm produces loss of visual acuity (VA), color vision, and visual field (VF) defects. Although it is well recognized that visual improvement may occur after surgical excision of a parachiasmal lesion, this recovery is variable and unpredictable.<sup>1-10</sup>

Previous reports have evaluated a variety of candidate measures, including duration of symptoms, size of tumor, preoperative VA and visual field, and optic nerve head appearance. However, studies have shown conflicting results. Some studies have identified as predictive such parameters as age,<sup>6,7,9</sup> preoperative VA,<sup>9</sup> or visual field loss.<sup>6,8</sup> Others have demonstrated no correlation of these variables (age, preoperative VA,<sup>6-8</sup> or visual field loss<sup>9</sup>) with recovery. Other investigators have considered the length of a patients' visual symptoms<sup>7</sup> as important information to determine recovery,<sup>9</sup> yet this also been shown to be unreliable.<sup>3,6,8</sup> Studies investigating tumor size and morphologic appearance have also shown conflicting results.<sup>5-7</sup> Optic atrophy has been reported by some investigators to correlate with degree of recovery,<sup>7</sup> but the grading and reporting of optic nerve pallor is subjective.<sup>9</sup> Hence, presently, there is no reliable predictor of recovery. Methods that would predict the visual outcome of surgery would be welcome both to tailor management strategies regarding the timing and necessity of surgery and to counsel patients on their likely ultimate visual function.

As failure of recovery is a consequence of irreversible damage to retinal ganglion cell axons (RGCs), the type of measurement that is needed would identify anatomic alteration or dysfunction in RGCs or their axons caused by the chiasmal disorder.<sup>11</sup> Optical coherence tomography (OCT) was developed to quantify the thickness of the retinal nerve fiber layer (RNFL) around the optic nerve head and the whole retinal thickness in vivo by performing cross-sectional imaging of internal tissue microstructure by measuring the echo time delay of back-scattered infrared light using an interferometer and a low-coherence light source. The chief clinical application of OCT to date has been in examination of retinal disorders. However, recently, RNFL thinning measured by OCT has been shown to be topographically related in both location and severity to decreases in visual field sensitivity in compressive optic neuropathies, suggesting that OCT provides an objective measure of RGC axonal presence in normal eyes and their loss or other alteration in eyes with chiasmal compression.<sup>12</sup>

These findings stimulated the hypothesis that the presence of axonal loss quantified by RNFL measurement would be associated with a diminished chance for visual recovery in persons with parachiasmal lesions after surgical intervention. The purpose of the present study was to assess prospectively the relation between the degree of axonal loss before surgery and visual function recovery after surgery, using RNFL measurement by OCT as the prespecified marker of axonal loss.

## METHODS

### Patients

Forty consecutive patients with chiasmal compression syndromes were prospectively recruited from the Neuro-ophthalmology and Neurosurgery Departments of the University of Auckland, New Zealand, and the Wills Eye Institute, Philadelphia, Pennsylvania. The research adhered to the tenets of the Declaration of Helsinki. The institutional review committees had approved the research and informed consent had been obtained. Exclusion criteria comprised unreliable VF testing (>33% false positives, or false negatives, or fixation losses), any anterior segment, retinal, posterior segment, or optic nerve disease other than compressive optic neuropathy, including known glaucoma, cup-to-disc ratio asymmetry of greater than 0.2, focal notching, or optic nerve hemorrhage. In each patient, the presence of a chiasmal lesion was confirmed by magnetic resonance imaging (MRI). Patients were excluded from the study if they had undergone any previous radiotherapy or medical treatment. In the preoperative assessment, all patients underwent testing of VA, refraction, slit lamp biomicroscopy, applanation intraocular pressure measurement, stereoscopic fundus evaluation, VF testing with a perimeter (Humphrey Visual Field Analyzer 2 [HFA2], 24-2 program, SITA Standard; Carl Zeiss Meditec, Dublin, CA), and OCT Fast RNFL scan. After surgery, repeated measurements of VA, color vision testing with Ishihara plates, intraocular pressure measurement, slit lamp biomicroscopy, fundus examination, OCT RNFL measurement, and VF testing were undertaken. Preoperative assessments were performed up to 2 months before surgery, and postoperative visits occurred up to 6 weeks after surgery.

Five patients did not meet the entrance criteria to the study, four due to inability to undergo VF testing, either before or after surgery, and one because of not meeting the study's time frames for the preoperative assessment. Of the remaining 70 eyes (of 35 patients), 7 were excluded from this analysis due to unreliable VFs at either the pre- or postoperative assessment.

### Optical Coherence Tomography

Quantitative RNFL measurements were obtained using the Stratus OCT (Carl Zeiss-Meditec, Inc.) instrument with software version 3.0.1. The optical principles and applications of the OCT have been described in detail elsewhere.<sup>12</sup> The software provides RNFL thickness for each clock hour position and for each quadrant of the optic nerve head. The average RNFL thickness for the entire circumference around the optic disc, in the mean of three scans at a diameter of 3.4 mm was obtained for each eye. We included only RNFL scans that were evaluated as "good," as judged by the appearance of the RNFL pictures. The OCT is a noninvasive and rapid test, with the time for image acquisition being less than a second.

For some portions of the analysis, we stratified the eyes of our patients into two groups, those classified as having a normal nerve, and those who had a thin nerve. Eyes in the thin-nerve group had average preoperative RNFL thicknesses that were thinner than 97.5% of normal values derived from an age-matched normative database (data from Carl Zeiss Meditec, Inc.). Eyes in the normal nerve group had RNFL values within the 97.5 percentile of normative values. This cutoff was chosen to take into account the broad range of normal RNFL thicknesses.

### Automated Perimetry

Automated perimetry was conducted using the 24-2 Swedish Interactive Threshold Algorithm (SITA) on the HFA2 instrument (Carl Zeiss Meditec, Inc.) with a Goldmann size III stimulus on a 31.5-apostilb background.

### Statistical Analysis

All data on RNFL thicknesses are presented as the mean  $\pm$  SD. Pearson's correlation coefficients and linear regression analysis were con-

ducted to correlate OCT-measured RNFL thickness (in micrometers) in the thin and normal nerve groups to corresponding VF sectors before surgery and at the postoperative visit. The eyes were stratified into thin and normal nerve groups based on their RNFL thickness. For linear and multiple regression analyses, RNFL thickness was treated as a parametric variable, as it obeyed continuous normal distribution. Normality of the distribution was tested with Shapiro-Wilk statistics. VF sensitivity was treated as the dependent variable and RNFL thickness as the independent variable in all regressions assessing the relationship between VF sensitivity and RNFL thickness. Evidence of nonlinearity was assessed using a significance level of 0.05. Differences between thin and normal nerve groups are reported from two sample Student's *t*-tests. General estimating equations (GEEs; with the GENMOD procedure of SAS) were used to take into account the correlation between eyes in the same subject<sup>13</sup> (since two eyes of the same individual have optic disc measures that are more similar than those of unrelated persons). Analyses were conducted with commercial software (SAS, ver. 9.1; SAS Institute Inc., Cary, NC). Another program (Prism, ver. 4.2; Graphpad, Inc., San Diego, CA) was used to calculate the area under the receiver operating characteristic (ROC) function. All tests were two-tailed and  $P < 0.05$  was considered statistically significant.

## RESULTS

### Baseline Preoperative Data

The average age of patients was 45 years (SD  $\pm$ 16; range, 18-77) with an equal number of men (49%) and women (51%). The majority of the patients (27 patients, 49 eyes) had a diagnosis of pituitary adenoma (77%). The remaining 23% had cystic lesions (three patients, six eyes), meningioma (two patients, four eyes), and craniopharyngioma (one patient, one eye), an extrinsic granulomatous mass with histology consistent with neurosarcooidosis (one patient, two eyes), and paracalcinoid aneurysm (one patient, one eye). Indications for surgery included: impaired visual function (VA, color vision, or VF abnormalities) for 30 patients, and endocrinological reasons in 5 patients. Preoperative mean best-corrected VA (BCVA) was 20/50 (range, 20/16 to hand movements). A mean of 76% of Ishihara color plates were identified correctly before surgery (SD  $\pm$ 37.2%; range, 0%-100%). Mean  $\pm$  SD MD on VF testing was  $-9.6 \pm 9.8$  (range,  $-34.1$  to 0.6) and mean pattern standard deviation (PSD) was  $6.1 \pm 4.9$  (range, 1.1 to 16.8). The mean  $\pm$  SD preoperative RNFL thickness was  $89.7 \pm 20.1$   $\mu$ m (range, 38.0 to 124.8  $\mu$ m) among all eyes. Forty-three (68%) eyes met the RNFL criteria for normal, and 20 (32%) eyes for the thin group.

Thin preoperative RNFL thickness was associated with worse VA and VF MD (Table 1). Eyes classified as having normal RNFL identified significantly more Ishihara color plates correctly than did the eyes in the thin-RNFL group (83.0% vs. 63.7%,  $P = 0.036$ ; Table 1). In addition, eyes with normal RNFL thickness at baseline had less severe VF defects before surgery (MD,  $-7.0$  dB vs.  $-15.3$  dB,  $P = 0.01$ ).

### Change in Visual Function after Surgical Decompression

Eyes with normal RNFL measurement showed a significant improvement in VA, from a mean of 20/40 to 20/25 after surgery ( $P = 0.028$ ; Table 2), whereas eyes with thin RNFL did not improve significantly (20/80 to 20/60;  $P = 0.177$ ). Eyes with normal RNFL, showed an improvement in MD from  $-7.0$  dB before surgery to  $-3.5$  dB after surgery ( $P = 0.0007$ ). There was no significant improvement in MD between baseline assessment (MD,  $-15.3$  dB) and postoperative visit (MD,  $-13.3$  dB,  $P = 0.191$ ) in eyes with thin RNFLs. The RNFL layer increased by 5.5% ( $P = 0.056$ ) in eyes with thin RNFLs and by 1% in all eyes ( $P = 0.04$ , Table 2).

**TABLE 1.** Difference in Visual Function and OCT Parameters for Thin Nerve and Normal Nerve Groups at Preoperative Assessment

	Normal Nerve	Thin Nerve	<i>P</i>
BCVA	20/40 [20/16-CF]	20/80 [20/16-HM]	0.064
Ishihara plates (%)	82.9 (33.7) [0-100]	64.7 (41.6) [0-100]	0.036
Visual Fields (MD in dB)	-7.0 (8.4) [-34.1-0.3]	-15.3 (10.3) [-33.6-0.6]	0.012
RNFL Thickness ( $\mu\text{m}$ )			
Average	100.4 (12.9) [81.2-124.8]	66.8 (12.2) [38.0-82.8]	<0.0001
Superior quadrant	128.6 (21.0) [88-170]	89.4 (22.3) [47.0-120.3]	<0.0001
Nasal quadrant	80.8 (16.5) [52-111.3]	48.5 (11.8) [28-69]	<0.0001
Inferior quadrant	122.9 (18.8) [80.7-158.0]	86.9 (20.9) [38.3-115.0]	<0.0001
Temporal quadrant	69.0 (14.4) [33.3-103.1]	46.7 (12.9) [27.0-84.3]	<0.0001

Data in parentheses are the SD and in brackets are the range.

Patients were evaluated to determine whether RNFL predicted the likelihood of recovery of visual function. Ninety-seven percent of eyes with normal RNFLs achieved VA of 20/40 or better, compared with 72% with thin RNFLs ( $P = 0.02$ ; odds ratio, 11.5; 95% CI, 1.2-108.8). Similarly, 94% of eyes with normal RNFLs achieved VA of 20/30 compared with 67% of those with preoperative thin RNFLs ( $P = 0.039$ ; odds ratio, 7.5; 95% CI, 1.3-41.1). Likewise, eyes with normal RNFLs had significantly improved VF, with 71% improving to final MD of  $-3.5$  dB or better, compared with 28% of eyes with thin RNFL ( $P = 0.007$ ; odd ratio, 6.4; 95% CI, 1.7-23.1). Fifty-five percent of eyes with normal RNFL compared to 22% of those with thin RNFL ( $P = 0.037$ ) achieved an MD of  $-2.0$  dB by 6 weeks after surgery.

### Relationship of RNFL with Visual Function in Eyes with Severe Visual Field Defects

Figure 1 shows a clear cutoff between preoperative average RNFL thickness in the thin group and normal group between values of 75 and 80  $\mu\text{m}$ . There were 19 eyes with a baseline MD  $\leq -10$  dB (moderate to severe VF defects); of those eyes with an average RNFL thickness  $>80$   $\mu\text{m}$ , all had a  $>10$ -dB change in MD from before to after surgery. Eyes with significant VF defects (MD worse or equal to  $-10$  dB) but normal RNFL thickness before surgery showed a mean postoperative improvement in MD of  $14.6 \pm 3.1$  dB (SD) compared with those with MD worse or equal to  $-10$  dB and thin RNFL measurement, who improved on average by only  $1.6 \pm 14.7$  dB ( $P < 0.0001$ ) despite no difference in MD at their baseline visit (normal RNFL MD,  $-22.3$  dB; thin RNFL MD,  $-20.8$  dB;  $P = 0.7$ , Fig. 1). We compared the difference in RNFL thickness among the eyes with baseline MD of worse than or equal to  $-10$  dB between eyes that showed a mild improvement in VF recovery (MD improving by  $\geq 2$  dB) and those with a dramatic improvement (MD improving by  $\geq 10$  dB) from the preoperative baseline. Eyes that improved 10 dB or more had a mean  $\pm$  SD RNFL thickness of  $105.2 \pm 16.5$   $\mu\text{m}$ , compared with a mean RNFL thickness of  $61.7 \pm 13.1$   $\mu\text{m}$  ( $P < 0.0001$ ) in eyes that

did not improve by this criterion (Fig. 2B). There was a similar significantly thicker RNFL in eyes that improved by 2 dB or more, compared with those that did not (Fig. 2A).

Linear regression lines comparing change in VA and MD after surgery demonstrate that patients with poor VA or MD but with normal RNFL before surgery have a significantly greater recovery of vision than those with the same preoperative level of visual function but thin RNFL with the difference in recovery slope being significantly different from 0 in those with normal RNFL but not in those with thin RNFL (Fig. 3). Linear regression analysis of the eyes in the thin- and normal-nerve groups that reached near-normal VF after surgery (final MD of  $-2$  dB or better) showed that the eyes with thicker RNFL are more likely to achieve this final outcome up until the RNFL thickness of approximately 85  $\mu\text{m}$ , after which there was no added benefit of having a thicker RNFL.

ROC curve analysis demonstrates that RNFL thickness is an excellent predictor for recovery of BCVA to 20/40 or better (area under the curve of 0.89,  $P = 0.002$ ) and for dramatic improvement in MD by 10 dB or more (area under the curve of 0.78,  $P = 0.013$ ) in the immediate postoperative period (Fig. 4). The two independent predictors of MD at postoperative assessment (up to 6 weeks after surgery) in the eyes with severe VF defect at the baseline (MD of  $-10$  dB or worse) were average RNFL thickness in the inferior quadrant of the disc at baseline ( $P = 0.0001$ ) and MD at baseline ( $P = 0.0024$ ). Examination of partial  $R^2$  values revealed that average RNFL thickness in the inferior quadrant of the disc at baseline explained 61% of the variance in the MD at postoperative assessment and the MD at baseline explained further 18%.

### DISCUSSION

Although it is well established that recovery of visual function occurs in a significant proportion of patients after surgery for chiasmatic compressive lesions, it is also recognized that this recovery is highly variable.<sup>2-10</sup> Prognostic indicators for potential improvement in function after surgery for parachiasmatic

**TABLE 2.** Change in Visual Function and OCT Parameters from Preoperative to Postoperative Assessment for the Normal and Thin Nerve Groups

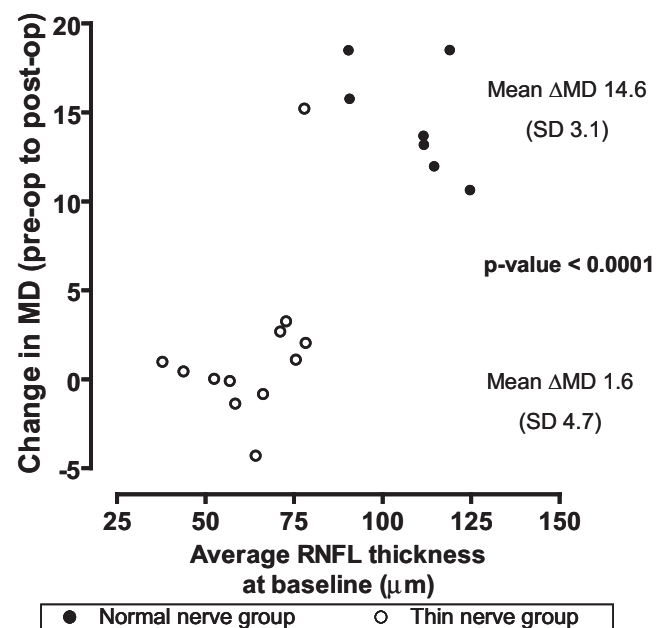
	Pre-op Assessment	Post-op Assessment	P
BCVA			
Normal	20/40 [20/16-CF]	20/25 [20/16-CF]	0.028
Thin	20/80 [20/16-HM]	20/60 [20/16-PL]	0.177
All	20/50 [20/16-HM]	20/30 [20/16-PL]	0.01
Ishihara plates (%)			
Normal	82.9 (33.7) [0-100]	87.3 (29.1) [16.7-100]	0.122
Thin	64.7 (41.6) [0-100]	67.0 (44.1) [0-100]	0.717
All	76.8 (37.2) [0-100]	79.5 (36.6) [0-100]	0.114
Visual fields MD (dB)			
Normal	-7.0 (8.4) [-34.1-0.3]	-3.5 (5.2) [-19.9-1.3]	0.0007
Thin	-15.3 (10.3) [-33.6-0.6]	-13.3 (10.6) [-33.6-0.5]	0.191
All	-9.6 (9.8) [-34.1-0.6]	-7.1 (8.9) [-33.6-1.3]	0.0003
Average RNFL thickness ( $\mu\text{m}$ )			
Normal	100.4 (12.9) [81.2-124.8]	101.8 (12.7) [84.2-131.1]	0.280
Thin	66.8 (12.2) [38.0-82.8]	70.5 (14.7) [40.6-86.9]	0.056
All	89.7 (20.1) [38.0-124.8]	90.3 (20.2) [40.6-131.1]	0.040

Data in parentheses are the SD and in brackets are the range.

lesions would offer physicians the ability to tailor treatment plans and to counsel the patient regarding the outcome of the intervention. To date, there have been contradictory findings regarding factors that may predict the degree of visual recovery. Factors such as shorter duration of symptoms, younger age, lack of optic disc pallor, and better preoperative VA have been associated with better postoperative recovery of visual function by some investigators (Cohen et al.<sup>9</sup>), but not others.<sup>3,6,8,14,15</sup>

The present study is the first to establish a clinical marker that correlates strongly with the degree of visual recovery after surgical intervention in patients with significant visual loss as a result of chiasmal compression. The degree of reversibility of visual dysfunction with compression of the anterior visual pathway is related to the loss of RNFL thickness, as measured by the OCT. In patients with normal RNFL thickness, visual function shows large improvements in the presence of advanced preoperative VF or acuity loss, whereas patients with thin RNFL and advanced VF defect demonstrate significantly less improvement. The study demonstrated that there is an increasing probability of improvement to near normal visual function (VA better than 20/40 or mean deviation within 2 dB of normal) with increasing RNFL thickness up to approximately 85  $\mu\text{m}$ , after which there is no further improvement in visual function.

Other objective tests have been investigated as predictors of visual outcome after removal of parachiasmal lesions. Both the



**FIGURE 1.** Comparison of the magnitude of MD change from pre- to postoperative assessment in the thin group and normal group among the eyes with baseline MD  $\leq$  -10 dB.



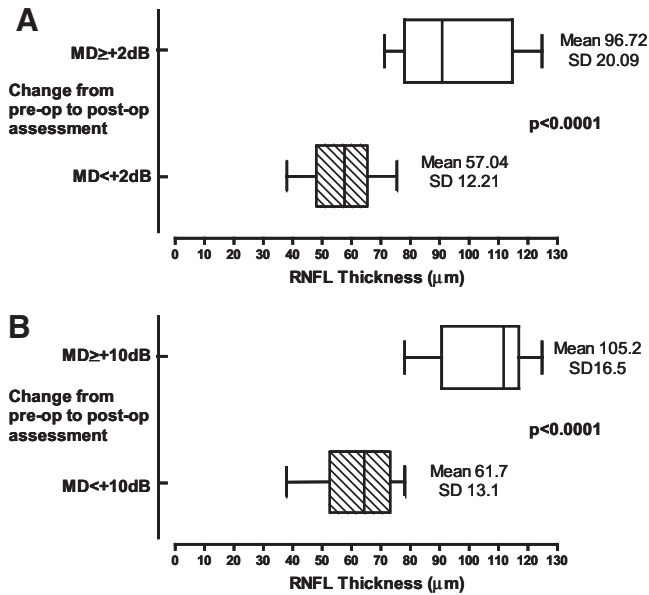


FIGURE 2. Difference in RNFL thickness between the eyes in which MD improved by at least 2 dB (A) and at least 10 dB (B) from preoperative to postoperative assessments, among the eyes with the severe baseline VF defect of -10 dB or worse.

amplitude and the velocity of visually evoked potential (VEP) are decreased in compressive optic neuropathies. Even patients with profound decreases in VEP may show complete recovery of VEP within minutes of decompression, suggesting that one mechanism for the depressed VEP is nerve conduction blockade, which is relieved by surgical intervention.<sup>16-18</sup> However, VEP data share with VF findings the limitation that they denote functional loss that is reversible, rather than providing prognostic value. They do not differentiate between decrease in visual function due to reversible factors, such as conduction block, and irreversible factors, such as actual retrograde RGC degeneration.<sup>19-22</sup> In addition, delays in latency in the VEP recording may occur in retinal dysfunction and cannot be considered pathognomonic of optic nerve disease.<sup>23</sup> The pattern electroretinogram (PERG), another objective test of retinal function, originates from the inner retinal layers and provides an assessment of RGC function.<sup>24-27</sup> Like the VEP, it requires complex equipment, electrodes that are placed on the eye, and a relatively time-consuming test procedure. Reports have sug-

gested that an abnormal PERG correlates with lack of postoperative recovery.<sup>28</sup> However, although the chance of VF improvement after surgery is greater in those eyes with a normal PERG, 34% of such eyes showed deterioration or no change in VF, indicating that PERG was not able to predict VA recovery.

The potential for recovery of visual dysfunction caused by compressive lesions of the anterior visual pathway may depend on the degree and duration of axonal injury.<sup>14,24,25,29</sup> There are several underlying pathophysiologic mechanisms that contribute to the visual dysfunction but are not associated with significant axonopathy and are potentially reversible. Conduction block, which may be due to direct compression or ionic concentrations insufficient to support saltatory conduction, is reversible within minutes to hours with removal of the compressive lesion.<sup>6,30</sup> Restoration of axoplasmic transport and remyelination are processes that take longer to occur and may be associated with the continued recovery over weeks to months.<sup>1,31-34</sup>

However, some patients with relatively normal RNFL do not recover normal VA or VF function, perhaps due to incomplete remyelination. Experimental chronic compression of the optic nerve in cats demonstrated evidence of demyelination within a week and subsequent remyelination, though the reconstructed myelin sheaths were thinner than normal, with reduced intranodal distances.<sup>35</sup> Even at 18 months after spinal cord compression, remyelinated fibers exhibited inappropriately thin myelin sheaths.<sup>35</sup> Hence, although such remyelination may be associated with restored conduction of action potentials and recovery of spatial vision it remains unknown whether remyelination is capable of restoring the ability of previously demyelinated central fibers to impulse at physiological frequencies.<sup>33,34</sup> A further possible explanation is that the time frame of our postoperative visit (up to 6 weeks) was too short to capture recovery and that these patients may show slower recovery of visual function because of more severe preoperative visual dysfunction. It has been demonstrated in a cat model that the percentage of nerve fibers lost from the retinogeniculate visual pathways determined the length of time required for visual recovery. Cats that lost many fibers required a long time to recover.<sup>33</sup> Alternatively, surgical trauma may result in damage to the axons and influence visual recovery, which clearly would have not been detected by the preoperative RNFL measurement. Finally, some eyes may have intact RNFL at the retinal level, but damage that had already occurred at the level of the chiasm leads to subsequent RGC death, precluding improvement in function.

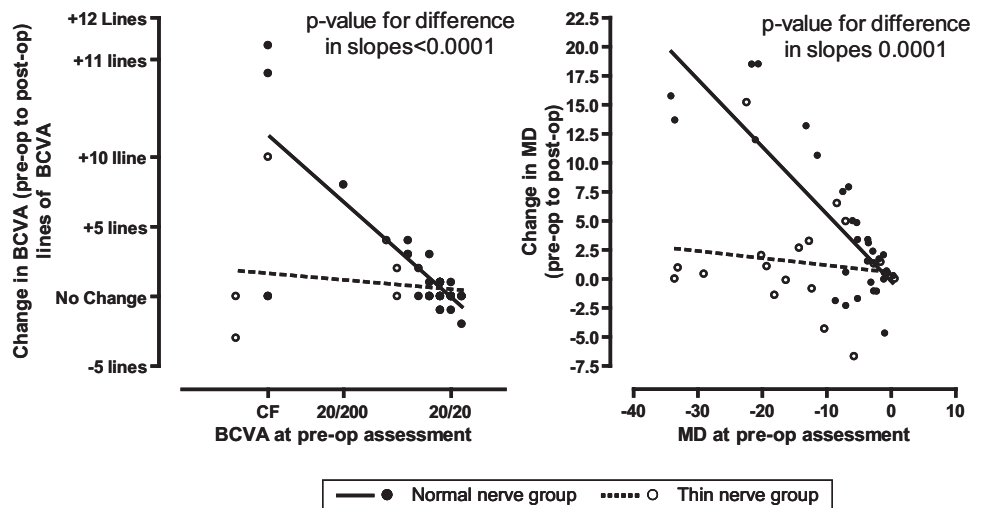


FIGURE 3. Regression lines comparing change in BCVA and MD between pre- and postoperative assessments in the eyes belonging to the thin and normal nerve groups according to their BCVA and MD at the preoperative visit.

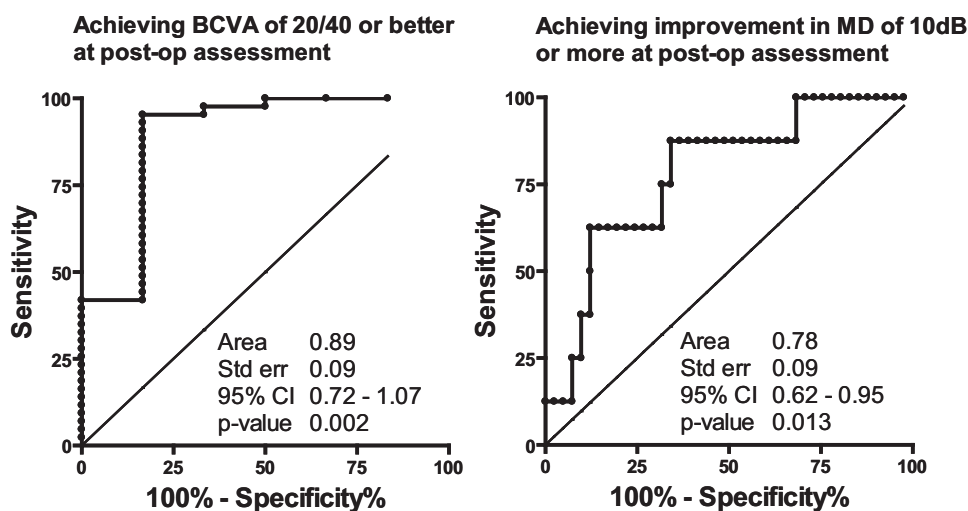


FIGURE 4. ROC curves for RNFL thickness at the baseline as a predictor of subsequent BCVA recovery to 20/40 or better and MD improvement by 10 dB or more after surgery among all eyes.

One interesting finding in our data was a very modest increase in RNFL thickness after surgery in eyes overall, which was of greater magnitude in those with thin RNFL than in normal RNFL eyes. It may be that RGC whose axons are injured at the chiasmal area undergo an initial phase of reversible injury before axon and cell body loss that involves individual axon thinning.<sup>36</sup> After removal of the chiasmal lesions, the slight thickening of the RNFL may result from restoration of normal axon diameter in these RGCs. If confirmed by future studies, this indicates that we have identified that there is anatomic reversible injury that parallels the functional reversibility in chiasmal compression. The advent of highly objective measurements of RNFL thickness by OCT instrumentation may provide further insights into subtle, reversible changes in RGC axons that have been invisible to clinical evaluation in the past.

Finally, in this study 15% of our patients had normal VF test results and thin RNFLs. This may be analogous to the well-known preperimetric glaucoma. The present study is the first to suggest that damage to the anterior visual pathway may occur before identifiable VF loss in patients with compressive optic neuropathy (preperimetric compressive optic neuropathy) and requires further study to detail the nature of this finding.

This study has several limitations. Because compression of the anterior visual pathway often impairs VA, poor fixation by these patients could impair the reliability of VF testing. However, we used strict reliability criteria and excluded unreliable VFs to minimize this effect. Second, there is inherent variability in the OCT RNFL measurement, with a broad range of findings among normal persons. In part this is due to instrument error and in part to the high variability in the number of RGCs among eyes. The reproducibility of Stratus OCT measurements recently has been demonstrated using intraclass correlation, with coefficients for standard density scanning of 83% for mean RNFL thickness. We performed three good-quality OCT scans at each visit with the average of the three being used in the analysis. Third, our study included a variety of chiasmal disorders, with the majority having pituitary adenomas. Hence, the findings are particularly applicable to this cohort of patients. In addition, some of the improvement in VF after surgery may be attributable to the learning curve. Finally, the study involved a comparison of preoperative to postoperative recovery up to 6 weeks, whereas visual function is known to continue to improve for months and up to several years. Long-term follow-up of these patients will provide a greater understanding of the relationship between RNFL thickness and final visual outcome.

In conclusion, RNFL thickness provides a quantitative measure of the amount of viable axonal tissue and is a novel preoperative

marker that aids in predicting of the degree of visual recovery in patients with chiasmal compression after a decompression procedure. The benefit in having such a clinical biomarker that is rapid, noninvasive, and convenient to measure is its usefulness in planning of management strategies including the timing of surgery, counseling patients on prognosis, and potentially monitoring disease progression. Further investigation is warranted to corroborate these preliminary findings in larger studies and in wider a range of underlying diseases.

## References

- Kerrison JB, Lynn MJ, Baer CA, et al. Stages of improvement in visual fields after pituitary tumor resection. *Am J Ophthalmol*. 2000;130(6):813-820.
- Laws ER Jr, Trautmann JC, Hollenhorst RW Jr. Transsphenoidal decompression of the optic nerve and chiasm: visual results in 62 patients. *J Neurosurg*. 1977;46(6):717-722.
- Powell M. Recovery of vision following transsphenoidal surgery for pituitary adenomas. *Br J Neurosurg*. 1995;9(3):367-373.
- Svien HJ, Love JG, Kennedy WC, et al. Status of vision following surgical treatment for pituitary chromophobe adenoma. *J Neurosurg*. 1965;22:47-52.
- Ciric I, Mikhael M, Stafford T, et al. Transsphenoidal microsurgery of pituitary macroadenomas with long-term follow-up results. *J Neurosurg*. 1983;59(3):395-401.
- Findlay G, McFadzean RM, Teasdale G. Recovery of vision following treatment of pituitary tumours: application of a new system of visual assessment. *Trans Ophthalmol Soc UK*. 1983;103:212-216.
- Lennerstrand G. Visual recovery after treatment for pituitary adenoma. *Acta Ophthalmol (Copenh)*. 1983;61(6):1104-1117.
- Gnanalingham KK, Bhattacharjee S, Pennington R, et al. The time course of visual field recovery following transsphenoidal surgery for pituitary adenomas: predictive factors for a good outcome. *J Neurol Neurosurg Psychiatry*. 2005;76(3):415-419.
- Cohen AR, Cooper PR, Kupersmith MJ, et al. Visual recovery after transsphenoidal removal of pituitary adenomas. *Neurosurgery*. 1985;17(3):446-452.
- Ogden TE. Nerve fiber layer of the primate retina: thickness and glial content. *Vision Res*. 1983;23(6):581-587.
- Danesh-Meyer HV, Carroll SC, Foroozan R, et al. Relationship between retinal nerve fiber layer and visual field sensitivity as measured by optical coherence tomography in chiasmal compression. *Invest Ophthalmol Vis Sci*. 2006;47(11):4827-4835.
- Schuman JS, Pedut-Kloizman T, Hertzmark E, et al. Reproducibility of nerve fiber layer thickness measurements using optical coherence tomography. *Ophthalmology*. 1996;103(11):1889-1898.
- Liang K ZS. Longitudinal data analysis using generalized linear models. *Biometrika*. 1986;73:13-22.

14. Kayan A, Earl CJ. Compressive lesions of the optic nerves and chiasm: pattern of recovery of vision following surgical treatment. *Brain*. 1975;98(1):13-28.
15. Sleep TJ, Hodgkins PR, Honeybul S, et al. Visual function following neurosurgical optic nerve decompression for compressive optic neuropathy. *Eye*. 2003;17(5):571-578.
16. Gutin PH, Klemme WM, Lagger RL, et al. Management of the unresectable cystic craniopharyngioma by aspiration through an Ommaya reservoir drainage system. *J Neurosurg*. 1980;52(1):36-40.
17. Feinsod M, Selhorst JB, Hoyt WF, Wilson CB. Monitoring optic nerve function during craniotomy. *J Neurosurg*. 1976;44(1):29-31.
18. Lewis T PG, Rothschild P. Centripetal paralysis arising out of arrested blood flow to limb, including notes on from of tingling. *Heart*. 1931;16:1-32.
19. Breclj J. A VEP study of the visual pathway function in compressive lesions of the optic chiasm: full-field versus half-field stimulation. *Electroencephalogr Clin Neurophysiol*. 1992;84(3):209-218.
20. Janaky M, Benedek G. Visual evoked potentials during the early phase of optic nerve compression in the orbital cavity. *Doc Ophthalmol*. 1992;81(2):197-208.
21. Siliprandi R, Bucci MG, Canella R, Carmignoto G. Flash and pattern electroretinograms during and after acute intraocular pressure elevation in cats. *Invest Ophthalmol Vis Sci*. 1988;29(4):558-565.
22. Pizzorusso T, Fagiolini M, Porciatti V, Maffei L. Temporal aspects of contrast visual evoked potentials in the pigmented rat: effect of dark rearing. *Vision Res*. 1997;37(4):389-395.
23. Holder GE. Electrophysiological assessment of optic nerve disease. *Eye*. 2004;18(11):1133-1143.
24. Holder GE. The pattern electroretinogram in anterior visual pathway dysfunction and its relationship to the pattern visual evoked potential: a personal clinical review of 743 eyes. *Eye*. 1997;11:924-934.
25. Holder GE. Significance of abnormal pattern electroretinography in anterior visual pathway dysfunction. *Br J Ophthalmol*. 1987;71(3):166-171.
26. Maffei L, Fiorentini A, Bisti S, Hollander H. Pattern ERG in the monkey after section of the optic nerve. *Exp Brain Res*. 1985;59(2):423-425.
27. Ruther K, Ehlich P, Philipp A, et al. Prognostic value of the pattern electroretinogram in cases of tumors affecting the optic pathway. *Graefes Arch Clin Exp Ophthalmol*. 1998;236(4):259-263.
28. Parmar DN, Sofat A, Bowman R, et al. Visual prognostic value of the pattern electroretinogram in chiasmal compression. *Br J Ophthalmol*. 2000;84(9):1024-1026.
29. Elkington SG. Pituitary adenoma: preoperative symptomatology in a series of 260 patients. *Br J Ophthalmol*. 1968;52(4):322-328.
30. Smith KJ, Blakemore WF, McDonald WI. The restoration of conduction by central remyelination. *Brain*. 1981;104(2):383-404.
31. Smith EJ, Blakemore WF, McDonald WI. Central remyelination restores secure conduction. *Nature*. 1979;280(5721):395-396.
32. Jacobson SG, Eames RA, McDonald WI. Optic nerve fibre lesions in adult cats: pattern of recovery of spatial vision. *Exp Brain Res*. 1979;36(3):491-508.
33. Clifford-Jones RE, Landon DN, McDonald WI. Remyelination during optic nerve compression. *Trans Ophthalmol Soc UK*. 1980;100:274-275.
34. Kaufmann D, Wray SH, Lorange R, et al. An analysis of the pathophysiology and the development of treatment strategies for compressive optic nerve lesions using pattern electroretinogram and visual evoked potential. *Neurology*. 1986;36(suppl 1):232.
35. Harrison BM, McDonald WI. Remyelination after transient experimental compression of the spinal cord. *Ann Neurol*. 1977;1(6):542-551.
36. Morgan JE. Retinal ganglion cell shrinkage in glaucoma. *J Glaucoma*. 2002;11(4):365-370.