

# A Study of Retinal Penetration of Intravitreal Tenecteplase in Pigs

Anthony S. L. Kwan, Sarojini Vijayasekaran, Ian L. McAllister, Paula K. Yu, and Dao-Yi Yu

**PURPOSE.** To determine the degree of retinal penetration of intravitreal tenecteplase in a porcine model.

**METHODS.** Fluorescence-tagged tenecteplase (50  $\mu\text{g}$  in 0.1 mL physiologic saline) was injected into the vitreous of the right and left eyes at 24 and 6 hours before death, respectively, in six nonvitrectomized pigs. Retinal penetration was assessed on frozen sections by epifluorescence microscopy and statistical analysis was performed. Frozen sections of two eyes without injection (control) were also assessed.

**RESULTS.** Labeling of fluorescence-tagged tenecteplase was seen in all the layers of the retina at both time points with more intense signal at 24 hours after injection ( $P < 0.05$ ).

**CONCLUSIONS.** Fluorescence-tagged tenecteplase can penetrate all the layers of the retina of porcine eyes after intravitreal injection. Intravitreal tenecteplase may be useful in the management of subretinal hemorrhage. (*Invest Ophthalmol Vis Sci.* 2006;47:2662–2667) DOI:10.1167/iovs.05-1019

Submacular hemorrhage (SRH) is a serious event that may be caused by several conditions including trauma, retinal macroaneurysm, age-related macular degeneration (AMD), high myopia, and complications of vitreoretinal surgery.<sup>1</sup> The natural history of SRH is variable. Visual recovery may be good in some cases; however, the prognosis is generally poor for large, thick SRHs and those associated with AMD.<sup>2–5</sup> Several methods have been described for the treatment of SRH, including pneumatic displacement, with<sup>6,7</sup> or without<sup>8</sup> adjunctive treatment of tissue plasminogen activator (tPA), and vitrectomy surgery with drainage of SRH, with<sup>9–11</sup> or without tPA.<sup>12,13</sup> tPA is a naturally occurring endogenous serine protease with a molecular mass of 70 kDa.<sup>14</sup> It forms a complex with fibrin to activate plasminogen to plasmin, which, in turn, lyses fibrin and other procoagulant proteins into soluble degradation products, thus dissolving the blood clot. Through dissolution of fibrin, tPA is believed to reduce the fibrin-mediated clot's adherence to the retina and thus to decrease photoreceptor damage during the removal of SRH. It is unclear, however, how tPA penetrates the retina to reach the subretinal clots when it is used intravitreally and without direct injection into the subretinal space. Furthermore, the ability of tPA to diffuse through the retina and into the subretinal space has been questioned in an experimental model.<sup>15</sup>

Toxicity profiles for tPA injected intravitreally were established in both rabbit<sup>16</sup> and cat<sup>17,18</sup> retina. In humans, retinal toxicity is variable and toxic effects have been reported at what is considered by some to be therapeutic doses.<sup>19,20</sup> Recently, a third-generation thrombolytic agent has been developed to address some of the shortcomings of tPA. Tenecteplase (TNK) is a variant of native tPA that has been produced by recombinant DNA technology, having undergone multiple-point mutations at the T, N, and K domains.<sup>21,22</sup> TNK has been tested extensively in clinical trials<sup>23–25</sup> for the treatment of myocardial infarction. The issue of retinal toxicity of intravitreal TNK has been addressed in a previous study.<sup>26</sup> Doses of up to 100  $\mu\text{g}$  TNK appear to be safe for intravitreal injection in rabbits, with no evidence of retinal toxicity. These data suggest a wider therapeutic window for TNK than for tPA and may indicate that higher doses of TNK can be used, which may be more effective in dissolving thicker SRHs.

The purpose of this study was to determine whether TNK can pass through the retina to reach the subretinal space after intravitreal injections into nonvitrectomized eyes in a porcine model.

## MATERIALS AND METHODS

All animal procedures were approved by the Animal Ethics Committee of the University of Western Australia and conformed to the ARVO Statement for the Use of Animals in Ophthalmic and Vision Research and the policies in the Guide to the Care and Use of Laboratory Animals of the National Institutes of Health.

Seven pigs (~10 kg each) aged 4 weeks were used in the study. Six pigs received bilateral intravitreal fluorescence-conjugated TNK injections in a two-stage procedure, with the right and left eyes receiving injections 24 and 6 hours before death, respectively. The right eye was injected first, followed by the left eye 18 hours later. Fluorescence-labeled TNK was injected into the midvitreous cavity under direct vision through the operating microscope and contact lens. TNK (Metyse; Boehringer Ingelheim, NSW, Australia) was conjugated with a superior, highly photostable green fluorescent dye, AlexaFluor 488 ( $\text{C}_{39}\text{H}_{44}\text{N}_8\text{Na}_2\text{O}_{13}\text{S}_3$ ), with an excitation and emission maxima of 495 and 519 nm (custom synthesis of TNK by Invitrogen [Eugene, OR] for Invitrogen Australia Pty Ltd). Conjugation was performed according to the method described by Kamei et al.,<sup>15</sup> in which the L-arginine (vehicle) of tPA was replaced with N-acetyl arginine, conjugated with the dye and thereafter separated with L-arginine as the eluting solvent.

Six of the pigs were sedated with an intramuscular injection of 4.4 mg/kg Zoletil 100 (250 mg Tiletamine and 250 mg Zolazepam; Virbac Laboratories, Ltd., Peakhurst, NSW, Australia). The animals were then masked and maintained on halothane, oxygen, and nitrous oxide. The pupils were dilated with 2.5% phenylephrine hydrochloride and 1% tropicamide. A 26-gauge needle was introduced into the vitreous cavity transsclerally, 2 to 3 mm posterior to the superotemporal limbus and under direct vision through a planoconcave contact lens and an operating microscope. The needle bevel was visualized in the midvitreous cavity and 0.1 mL of the fluorescence-TNK conjugate at a concentration of 50  $\mu\text{g}/0.1$  mL physiologic saline solution was injected into each eye at the specified time points. To ensure the stability of the fluorescence-TNK conjugate, the drug was freshly diluted just before injection.

From the Lions Eye Institute, Centre for Ophthalmology and Visual Science, the University of Western Australia, Nedlands, Australia.

Supported by the National Health and Medical Research Council of Australia and the Ophthalmic Research Institute of Australia.

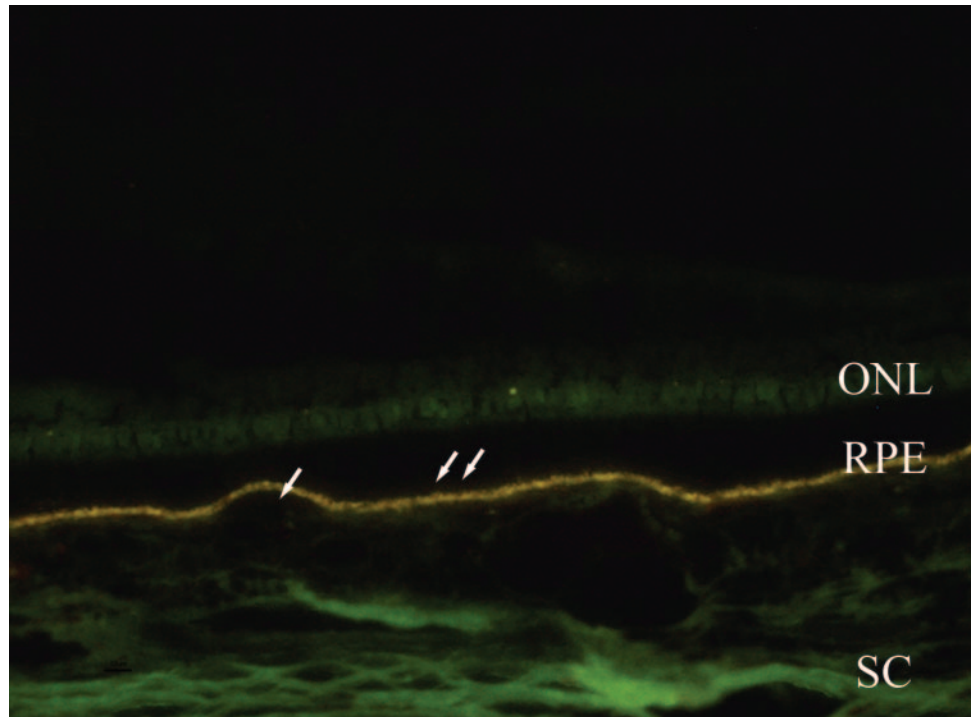
Submitted for publication August 3, 2005; revised November 16 and December 15, 2005; accepted March 27, 2006.

Disclosure: A.S.L. Kwan, None; S. Vijayasekaran, None; I.L. McAllister, None; P.K. Yu, None; D.-Y. Yu, None

The publication costs of this article were defrayed in part by page charge payment. This article must therefore be marked "advertisement" in accordance with 18 U.S.C. §1734 solely to indicate this fact.

Corresponding author: Ian L. McAllister, Lions Eye Institute, Centre for Ophthalmology and Visual Science, The University of Western Australia, Nedlands, WA 6009, Australia; ianmca@cylfene.uwa.edu.au.

**FIGURE 1.** Epifluorescence micrographs of a frozen section of a normal porcine retina taken from the posterior pole, as seen through a fluorescence-detection filter. Autofluorescence label was *yellow* in a linear configuration along the retinal pigment epithelium (RPE), *brown* in the rod outer segments (*double arrow*) and red blood cells (*arrow*) within the retinal and choroidal blood vessels, and faint *green* in the outer nuclear layer (ONL) of the photoreceptor cells, choroid, and sclera (SC).



tion. The needle was left in situ for a further 20 seconds after injection it was withdrawn, to avoid reflux from the entry site. Chloramphenicol ointment 1% (Chlorosig; Sigma Pharmaceuticals Ltd., Castle Hill, Australia) was applied to the eyes after surgery, and the pigs were allowed to recover before death. One normal pig without injection was used as the control.

For histologic analysis, all the experimental and control eyes were enucleated and fixed in 4% paraformaldehyde for 24 hours at 4°C. Four retinal samples, each measuring 3 mm<sup>2</sup>, were taken from the posterior pole of each eye. The samples were embedded in optimal cutting temperature compound (OCT; Pro Sci Tech Pty Ltd., Kirwan, Queensland, Australia) in frozen blocks. Ten-micrometer-thick sections were cut on a cryostat (CM 3050S; Leica, Heidelberg, Germany). Sections were analyzed and photographed without performing any other procedures in order to avoid washing away labeled protein/TNK. The distribution of the labeled protein was visualized under an epifluorescence microscope equipped with a fluorescence-relevant detection filter (excitation and emission maxima 495 and 519 nm). To ensure that the fluorescence distribution and intensity are related only to the amount of TNK present, all the observations and photographs were taken at a preset setting on the microscope which was used for all the sections in the analysis. The intensity of the fluorescence-labeled TNK signal of all the retinal samples from the 6- and 24-hour time points was evaluated and graded from coded photographs according four grades: 0, no fluorescent signal above that of background auto fluorescence; 1, weak; 2, moderate; and 3, intense fluorescent labeling above background autofluorescence. Statistical analysis for significance was performed with Wilcoxon's matched signed rank test for nonparametric data.

## RESULTS

The central retinal artery was observed to be patent in all eyes, and no retinal damage was seen in any of the eyes after the injections at the time of surgery. Fluorescence-labeled TNK, when injected into the midvitreal cavity under direct vision through the operating microscope and contact lens, pooled in the vitreal and fluoresced bright green.

On examination of the frozen sections through a fluorescence-relevant detection filter, autofluorescence was observed in all the eyes, including those injected with fluorescence-labeled TNK and in the control eye without injection. Autofluorescence appeared yellow in a linear configuration along the retinal pigment epithelium, brown in the rod outer segments and red blood cells within the retinal blood vessels, and a faint green in the outer nuclear layer choroid and sclera. Autofluorescence of the sclera was more marked.

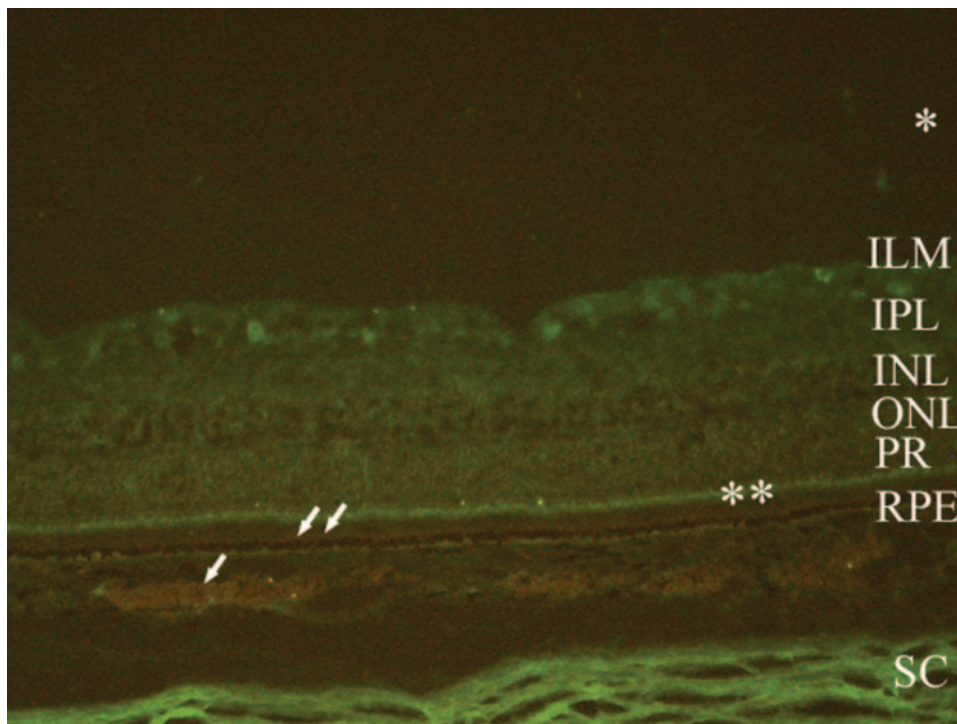
In the control animal, Autofluorescence was observed in both eyes (Fig. 1). At 6 hours after injection (left eyes), in addition to autofluorescence, a weak fluorescent signal (grade 1) was observed in four of the six eyes in all the layers of the retina, including the inner limiting membrane, ganglion cell layer, inner nuclear layer, photoreceptor cell layer, and plexiform layers. The signal was more pronounced at the level of the inner segments of the photoreceptor cell layer, along the internal limiting membrane (ILM) and matrix surrounding the retinal ganglion cell axons. Fluorescence also appeared above the inner limiting membrane in one of the eyes (Fig. 2).

In two of the six eyes 6 hours after injection, no difference was found compared with the autofluorescence in the control eyes. Fluorescence was seen above and close to the inner limiting membrane in one of the eyes. There was no distinct green fluorescent labeling of the rest of the retinal layers.

At 24 hours after injection of labeled TNK (right eyes), bright green fluorescence of labeled TNK was seen in the all six eyes in all the layers of the retina at varying intensity (Table 1): intense signal (grade 3) in three of the six eyes (Fig. 3), moderate (grade 2) in two, and weak (grade 1) in one. Fluorescence was seen just above the inner limiting membrane in five of these eyes. Wilcoxon's matched signed rank test for nonparametric data showed a significant difference between the signals at 6 and 24 hours after injection ( $P < 0.05$ ).

## DISCUSSION

To remove SRHs atraumatically, subretinal tPA was used. Through dissolution of fibrin, tPA can reduce the fibrin-medi-



**FIGURE 2.** Epifluorescence micrographs of a frozen section of porcine eye injected with fluorescently labeled TNK, taken from the posterior pole of the retina at 6 hours after surgery, as seen through a fluorescence-detection filter. The autofluorescence labeling is as described in Figure 1. Weak TNK signal was visible in all the layers of the retina, including the inner limiting membrane (ILM) ganglion cell layer, inner nuclear layer (INL), photoreceptor cell layer (PR), and inner (IPL) and outer plexiform layers and in the vitreous gel (\*). The signal was more pronounced in the inner segment portion of the photoreceptor cell layer (\*\*), in the inner limiting membrane and the surrounding matrix.

ated clot adherence to the retina and thus reduce photoreceptor damage during its removal. The liquefied SRH may also be evacuated through a small retinotomy, minimizing surgery-induced damage to the retina and RPE. Early results were promising, but there were limitations with subretinal tPA injection. Vitreoretinal surgery including retinotomy has potential complications: a long intraoperative waiting time for fibrinolysis to occur, the moderate fibrin affinity of tPA, and the risk of retinal toxicity at high doses.<sup>19</sup>

Intravitreal tPA injection and pneumatic displacement of subretinal blood away from the fovea was originally described by Heriot (unpublished data, 1997). He was able to displace blood away from the fovea successfully in 19 of 20 eyes. Hassan et al.<sup>6</sup> reported a similar high success rate in a multicenter, retrospective, noncomparative case study. The complication rate appeared to be low. Ohji et al.<sup>8</sup> demonstrated that intravitreal injection of gas without tPA, followed by prone positioning, was effective in displacing submacular blood in 60% of eyes in this small series. However, it has been suggested that patients in whom thick blood is apparent beneath the RPE in the foveal area and those with massive hemorrhages (extending well beyond the vascular arcades) are not good candidates for this procedure.<sup>27</sup>

Although it was noted in an animal model that the color of the clotted blood changed after intravitreal injection of tPA,

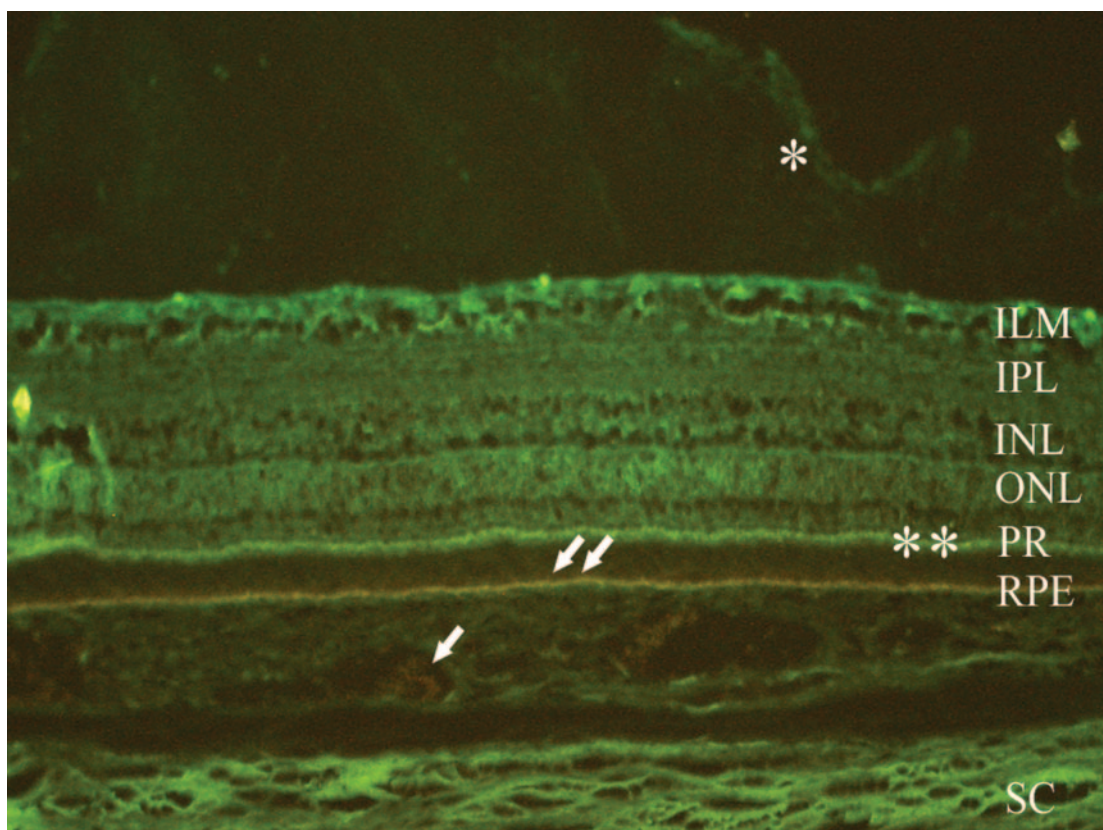
there has been doubt as to whether tPA can diffuse through the retina to reach the subretinal space.<sup>28</sup> Drug delivery to the outer retina via the vitreous poses a great challenge because of the diffusional barriers of the neural retina<sup>15,29-31</sup> caused by its anatomic and physiological characteristics. The inner and outer limiting membranes and the interphotoreceptor matrix of the neural retina are rich in glycosaminoglycans,<sup>32-35</sup> which may have diffusional barrier properties. It has been proposed that molecular weight and, more important, the charge of molecules introduced into the vitreous may affect their ability to diffuse across the membranes.<sup>31</sup> The cationic charge of a molecule is a limiting factor to diffusion, probably due to its binding to biomacromolecules of the neural retina, especially in the inner limiting membrane, and therefore is poorly transferred through the retina, whereas for anionic or neutral charge molecules, this is unlikely to happen. Kamei et al.<sup>15</sup> have demonstrated in rabbits (Dutch-pigmented) that tPA conjugated to negatively charged fluorescein isothiocyanate (FITC; Invitrogen; molecular probes product information sheet) injected intravitreally does not penetrate the retina. In their study, FITC-labeled tPA was present at the vitreous surface of the retina in a linear array in all 36 eyes studied. No FITC signal was observed in the neural retina or in the eyes with the subretinal clot.

Kamei et al.<sup>15</sup> believed that the inability of tPA to penetrate the retina was not due to a diffusional barrier to molecules of the size of tPA (70 kDa), as albumin with a molecular mass (68 kDa) similar to tPA has been shown to reach the subretinal space from the vitreous after experimental retinal detachment.<sup>36</sup> Takeuchi et al.<sup>36</sup> reported that FITC conjugated to albumin made no difference in the rate of diffusion through the retina of this molecule from the vitreous, in an experimental model of retinal detachment in the rabbit.<sup>36</sup> Kamei et al.<sup>15</sup> attributed the failure of tPA to penetrate the retina to specific binding to heparin and fibronectin, explaining why in their experiment the labeled tPA pooled along the internal limiting membrane and the vitreous cortex.<sup>15</sup> In our study, TNK, which is a molecule very similar to tPA conjugated to AlexaFluor with a charge similar to that of FITC (Invitrogen; molecular probes

**TABLE 1.** Fluorescence Grade of TNK

Pig	Grade	
	6 Hours	24 Hours
1	0	2
2	0	1
3	1	3
4	1	2
5	1	3
6	1	3

0, Absence; 1, weak; 2, moderate; 3, strong.



**FIGURE 3.** Epifluorescence micrographs of a frozen section of porcine eye injected with fluorescently labeled TNK, taken from the posterior pole of the retina at 24 hours after surgery, as seen through a fluorescence-detection filter. Autofluorescence label is as described in Figure 1. Strongly labeled TNK signal is seen in all the layers of the retina including the inner limiting membrane (ILM), ganglion cell layer, inner nuclear layer (INL), photoreceptor cell layer (PR), and inner (IPL) and outer plexiform layers and in the vitreous gel (\*). The signal was more pronounced in the inner segment portion of the photoreceptor cell layer (\*\*\*) and in the ILM.

product information sheet), was able to penetrate all layers of the retina easily after intravitreal injection. The dyes conjugated to tPA in Kamei et al. and AlexaFluor 488 are both negatively charged and have molecular masses of less than 1 kDa, which would not have significantly increased the molecular mass of the conjugated drugs. It is unlikely that this small increase in the weight would have influenced diffusion. In addition, tPA (pI 7.5–8.5) ([http://biotech.nhctc.edu/BT220/section\\_1\\_7\\_0.html](http://biotech.nhctc.edu/BT220/section_1_7_0.html), UniProtKB/Swiss-Prot entry P00750/available in the public domain through the New Hampshire Biotechnology Center, New Hampshire Community Technical College, Portsmouth, NH) in the rabbit vitreous (at a pH of 7.3)<sup>37</sup> would be cationic, and TNK (the manufacturer's internal investigations resulted in a pI range between 5.5 and 7.7 due to glycosylation primarily due to sialylation in an IEF pattern greater than 10) in the pig vitreous (at pH 7.3)<sup>38</sup> would be neutral, anionic, or very weakly positively charged. Therefore, it would have been expected that TNK (without the aid of the dye) would diffuse through the neural retina. Nevertheless, it is possible that the rate at which TNK diffused through the retina was enhanced by the dye. This is unlikely, as TNK is neutral, negatively charged, or not strongly cationic at the pH of the vitreous of the pig and therefore, even without the addition of the dye is unlikely to bind to the negatively charged macromolecules of the neural retina. Similarly, it would not have been expected for tPA to diffuse through the retina, being cationic in the rabbit vitreous. Albumin carrying a negative charge (pI 4.9) ([http://biotech.nhctc.edu/BT220/section\\_1\\_7\\_0.html](http://biotech.nhctc.edu/BT220/section_1_7_0.html)) in the rabbit vitreous was able to diffuse through the neural retina.

We believe the failure of tPA to penetrate the retina in the rabbit model reported by Kamei et al.<sup>15</sup> may be due to the charge of tPA and/or may represent a species difference. The rabbit, although used as an experimental model, due to its availability and convenience and because the size of the eye is similar to the human eye, has several features that are different from the human eye. The rabbit eye has a merangiotic (i.e., only partially vascularized with choroidal circulation only, except at the medullary ray/myelin wings) the retina being devoid of intraretinal vasculature outside the myelin wings. It has been shown that the Müller fibers in rabbit are very powerful. The “feet,” their radial expansions of their processes as they approach the inner limiting membrane, can be very large.<sup>39</sup> Perhaps having features such as these that are different from the pig and human provides diffusional barriers peculiar to this species.

Our study was conducted on pigs with a holangiotic retina (i.e., fully vascularized, with a choroidal and retinal circulation) similar to humans. In this study, fluorescence labeled TNK was shown to be able to penetrate the majority of the pigs' retinas 6 hours after intravitreal injection (four of six eyes) and all retinas after 24 hours. The labeling was visible in all the retinal layers, indicating that there was no specific barrier to the diffusion process, although there was a slightly stronger labeling at the inner limiting membrane and around the matrix surrounding ganglion cell axons. It is possible that, at these sites, anatomic features led to some retardation of the movement across the retina but permitted a significant amount of the drug to pass through. There was a second fluorescent signal enhancement at the inner segment portion of the pho-

toreceptor layer. This may also be due to a slowing down of diffusion at the external limiting membrane where some accumulation occurred or, a lack of TNK penetration into the tightly packed outer segment-RPE complex. This is not unexpected, as we have not induced a retinal detachment or subretinal clots in this study.

The fluorescent signal in the retinal layers was more intense in eyes that had been labeled with TNK for 24 hours. At this time point, all the eyes had TNK penetration of various intensities from grade 1 to 3. Three of these eyes had grade 3 intensity, whereas after 6 hours, four of the labeled eyes had intensity of grade 1. These results suggested that the diffusion of labeled TNK was time dependent and TNK retinal penetration was achieved in all eyes 24 hours after injection at a therapeutic dose of 50  $\mu\text{g}/0.1$  mL. There was an individual variability in the amount of TNK penetration. Labeled TNK was also present along the surface of the retina just above the inner limiting membrane, perhaps because some parts of the vitreous cortex which showed TNK label had not detached during dissecting and processing of the tissue. The results of this study suggest that porcine retina, which is very similar to the human in its structure, accurately reflects the ability of TNK to penetrate the retina to lyse an SRH after intravitreal injection in humans.

Toxicity profiles for tPA injected intravitreally were established in rabbit and in cat retina. In the rabbit, at doses greater than 50  $\mu\text{g}$ , large necrotic retinal holes, bullous retinal detachment, and marked retinal vessel attenuation occurred.<sup>40</sup> In the human, there are conflicting reports of dose-related toxicity. Hesse et al.<sup>20</sup> reported four patients with SRH who, after receiving 100  $\mu\text{g}$  of intravitreal tPA, developed exudative retinal detachment followed by hyperpigmentation of the RPE in the area of previously detached retina. In other studies, eyes appeared to accommodate injections of 100  $\mu\text{g}/0.1$  mL without harmful effect.<sup>6</sup> An absolutely safe intraocular dose of tPA has not been established, and many studies have used a lower dose (25  $\mu\text{g}$ ).<sup>18,41</sup> The toxicity of the commercial tPA to the retina has been attributed to L-arginine, one of the components of the vehicle that carries the drug, which prevents self-degradation of tPA.<sup>18</sup> Unfortunately, no commercial tPA is now available without the arginine vehicle, and thus cautious use of commercial tPA is the only way to prevent toxicity in humans.

TNK is a third-generation thrombolytic agent, developed to address some of the shortcomings of tPA. It is a variant of native tPA that has been produced by recombinant DNA technology, having undergone multiple-point mutations. In the treatment of acute myocardial infarction, TNK has been tested extensively in clinical trials (Assessment of Safety and Efficacy of a New Thrombolytic Agent [ASSENT-1] and [ASSENT-2]).<sup>23-25</sup> It is superior to tPA as it is less toxic (ratio of arginine to drug is a third less than in tPA) than tPA (product information, Boehringer Ingelheim), has a longer plasma half-life (approximately 18 vs. 4 minutes) than tPA, slower plasma clearance, 14-fold greater fibrin specificity, and 80-fold greater resistance to inhibition by plasminogen activator inhibitor (PAI)-I.<sup>21,22</sup> With its longer half-life and slower plasma clearance, TNK can be given as a bolus injection rather than an infusion over 90 minutes as the case with tPA, to achieve the same thrombolytic effects in acute myocardial infarction. In SRH, where tPA is used in conjunction with vitrectomy, it is impractical to wait for the recommended time of 45 minutes for the full effect of tPA to take place, if one is attempting to aspirate the hemorrhage. Therefore, TNK with its short contact time has a clear advantage.<sup>1</sup> With its high fibrin specificity, TNK binds with a greater affinity to the fibrin-rich clot, and to a much lesser extent, to the circulating plasminogen than tPA. TNK, therefore, is less likely to decrease the availability of plasminogen

around the subretinal clot and, with its greater resistance to PAI-I, should be more effective in clot lysis.

In conclusion, we have shown that intravitreal injection of fluorescence-labeled TNK can result in intraretinal diffusion 24 hours after injection. Intravitreal TNK followed by pneumatic displacement may be useful in the management of SRH. TNK will penetrate the retina and is a more effective fibrinolytic agent with potentially less toxic effects. Human trials are being planned to examine the role of TNK in the management of SRH.

## References

- Hochman MA, Seery CM, Zarbin MA. Pathophysiology and management of subretinal hemorrhage. *Surv Ophthalmol.* 1997;42:195-213.
- Bennett SR, Folk JC, Blodi CF, Klugman M. Factors prognostic of visual outcome in patients with subretinal hemorrhage. *Am J Ophthalmol.* 1990;109:33-37.
- Avery RL, Fekrat S, Hawkins BS, Bressler NM. Natural history of subfoveal subretinal hemorrhage in age-related macular degeneration. *Retina.* 1996;16:183-189.
- Berrocal MH, Lewis ML, Flynn HW Jr. Variations in the clinical course of submacular hemorrhage. *Am J Ophthalmol.* 1996;122:486-493.
- Scupola A, Coscas G, Soubrane G, Balestrazzi E. Natural history of macular subretinal hemorrhage in age-related macular degeneration. *Ophthalmologica.* 1999;213:97-102.
- Hassan AS, Johnson MW, Schneiderman TE, et al. Management of submacular hemorrhage with intravitreal tissue plasminogen activator injection and pneumatic displacement. *Ophthalmology.* 1999;106:1900-1906.
- Olivier S, Chow DR, Packo KH, MacCumber MW, Awh CC. Subretinal recombinant tissue plasminogen activator injection and pneumatic displacement of thick submacular hemorrhage in Age-Related macular degeneration. *Ophthalmology.* 2004;111:1201-1208.
- Ohji M, Saito Y, Hayashi A, Lewis JM, Tano Y. Pneumatic displacement of subretinal hemorrhage without tissue plasminogen activator. *Arch Ophthalmol.* 1998;116:1326-1332.
- Kamei M, Tano Y, Maeno T, Ikuno Y, Mitsuda H, Yuasa T. Surgical removal of submacular hemorrhage using tissue plasminogen activator and perfluorocarbon liquid. *Am J Ophthalmol.* 1996;121:267-275.
- Lewis H. Intraoperative fibrinolysis of submacular hemorrhage with tissue plasminogen activator and surgical drainage. *Am J Ophthalmol.* 1994;118:559-568.
- Vander JF. Tissue plasminogen activator irrigation to facilitate removal of subretinal hemorrhage during vitrectomy. *Ophthalmic Surg.* 1992;23:361-363.
- de Juan E Jr, Machemer R. Vitreous surgery for hemorrhagic and fibrous complications of age-related macular degeneration. *Am J Ophthalmol.* 1988;105:25-29.
- Hanscom TA, Diddie KR. Early surgical drainage of macular subretinal hemorrhage. *Arch Ophthalmol.* 1987;105:1722-1723.
- Collen D, Lijnen HR. Tissue-type plasminogen activator: mechanisms of action and thrombolytic properties. *Haemostasis.* 1986;16(suppl 3):25-32.
- Kamei M, Misono K, Lewis H. A study of the ability of tissue plasminogen activator to diffuse into the subretinal space after intravitreal injection in rabbits. *Am J Ophthalmol.* 1999;128:739-746.
- Irvine WD, Johnson MW, Hernandez E, Olsen KR. Retinal toxicity of human tissue plasminogen activator in vitrectomized rabbit eyes. *Arch Ophthalmol.* 1991;109:718-722.
- Benner JD, Morse LS, Toth CA, Landers MB III, Hjelmeland LM. Evaluation of a commercial recombinant tissue-type plasminogen activator preparation in the subretinal space of the cat. *Arch Ophthalmol.* 1991;109:1731-1736.
- Hrach CJ, Johnson MW, Hassan AS, Lei B, Sieving PA, Elner VM. Retinal toxicity of commercial intravitreal tissue plasminogen activator solution in cat eyes. *Arch Ophthalmol.* 2000;118:659-663.

19. Chen SN, Yang TC, Ho CL, Kuo YH, Yip Y, Chao AN. Retinal toxicity of intravitreal tissue plasminogen activator: case report and literature review. *Ophthalmology*. 2003;110:704-708.
20. Hesse L, Schmidt J, Kroll P. Management of acute submacular hemorrhage using recombinant tissue plasminogen activator and gas. *Graefes Arch Clin Exp Ophthalmol*. 1999;237:273-277.
21. Davydov L, Cheng JW. Tenecteplase: a review. *Clin Ther*. 2001;23:982-997.
22. Nordt TK, Bode C. Thrombolysis: newer thrombolytic agents and their role in clinical medicine. *Heart*. 2003;89:1358-1362.
23. ASSENT-2 Investigators. Single-bolus tenecteplase compared with front-loaded alteplase in acute myocardial infarction: the ASSENT-2 double-blind randomised trial. *Lancet*. 1999;354:716-722.
24. Sinnaeve P, Alexander J, Belmans A, et al. One-year follow-up of the ASSENT-2 trial: a double-blind, randomized comparison of single-bolus tenecteplase and front-loaded alteplase in 16,949 patients with ST-elevation acute myocardial infarction. *Am Heart J*. 2003;146:27-32.
25. Van de WF, Cannon CP, Luyten A, et al. Safety assessment of single-bolus administration of TNK tissue-plasminogen activator in acute myocardial infarction: the ASSENT-1 trial. The ASSENT-1 Investigators. *Am Heart J*. 1999;137:786-791.
26. Rowley SA, Vijayasekaran S, Yu PK, McAllister IL, Yu DY. Retinal toxicity of intravitreal tenecteplase in the rabbit. *Br J Ophthalmol*. 2004;88:573-578.
27. Johnson MW. Pneumatic displacement of submacular hemorrhage. *Curr Opin Ophthalmol*. 2000;11:201-206.
28. Boone DE, Boldt HC, Ross RD, Folk JC, Kimura AE. The use of intravitreal tissue plasminogen activator in the treatment of experimental subretinal hemorrhage in the pig model. *Retina*. 1996;16:518-524.
29. Smelser GK, Ishikawa T, Pei YF. Electron microscopic studies of intravitreal spaces diffusion of particulate materials. In: Rohen JW, ed. *Structure of the Eye, II. Symposium*. Stuttgart, Germany: Schattauer-Verlag; 1965;109-120.
30. Marmor MF, Negi A, Maurice DM. Kinetics of macromolecules injected into the subretinal space. *Exp Eye Res*. 1985;40:687-696.
31. Pitkanen L, Pelkonen J, Ruponen M, Ronkko S, Urtti A. Neural retina limits the non-viral gene transfer to retinal pigment epithelium in an in vitro bovine eye model. *AAPS J*. 2004;6:Article 25.
32. Hagerman GS, Johnson LV. Chondroitin-6-sulphate glycosaminoglycan is a major constituent of primate cone photoreceptor matrix and sheaths. *Curr Eye Res*. 1987;6:639-646.
33. Russell SR, Shepherd JD, Hageman GS. Distribution of glycoconjugates in the human retinal internal limiting membrane. *Invest Ophthalmol Vis Sci*. 1991;32:1986-1995.
34. Heegaard S, Jensen OA, Prause JU. Structure and composition of the inner limiting membrane of the retina. *Graefes Arch Clin Exp Ophthalmol*. 1986;224:355-360.
35. Chai L, Morris JE. Distribution of heparin sulfate proteoglycan in embryonic chicken neural retina and isolated inner limiting membrane. *Curr Eye Res*. 1994;13:669-677.
36. Takeuchi A, Kricorian G, Yao XY, Kenny JW, Marmor MF. The rate and source of albumin entry into saline-filled experimental retinal detachments. *Invest Ophthalmol Vis Sci*. 1994;35:3792-3798.
37. Lu DW. The changes of vitreous pH values in an acute glaucoma rabbit model. *J Ocul Pharmacol Ther*. 2001;17:343-350.
38. Anderson MV. Changes in the vitreous body pH of pigs after retinal xenon photocoagulation. *Acta Ophthalmol*. 1999;69:2:193-199.
39. Prince JH, McConnell DG. Retina and optic nerve. In: Prince JH, ed. *The Rabbit in Eye Research*. Springfield, IL: CC Thomas; 1964:385-448.
40. Johnson MW, Olsen KR, Hernandez E, Irvine WD, Johnson RN. Retinal toxicity of recombinant tissue plasminogen activator in the rabbit. *Arch Ophthalmol*. 1990;108:259-263.
41. Handwerker BA, Blodi BA, Chandra SR, Olsen TW, Stevens TS. Treatment of submacular hemorrhage with low-dose intravitreal tissue plasminogen activator injection and pneumatic displacement. *Arch Ophthalmol*. 2001;119:28-32.