

# Screening and Diagnosis of Optic Pathway Gliomas in Children with Neurofibromatosis Type 1 by Using Sweep Visual Evoked Potentials

Benjamin C. M. Chang,<sup>1,2</sup> Giuseppe Mirabella,<sup>1</sup> Ronit Yagev,<sup>1,3</sup> Michael Banh,<sup>1</sup> Eedy Mezer,<sup>1</sup> Patricia C. Parkin,<sup>4</sup> Carol A. Westall,<sup>1</sup> and J. Raymond Buncic<sup>1</sup>

**PURPOSE.** Neurofibromatosis type 1 (NF-1) is an autosomal dominant phakomatosis with a prevalence of 1 in 2000 to 1 in 5000. Up to 24% of these patients have optic pathway gliomas (OPGs). In the present study, the use of sweep visual evoked potentials (SVEPs) was investigated as a screening tool for identifying patients with NF-1 who had OPGs by comparing them to those patients with no OPGs and to normally developing children.

**METHODS.** Contrast sensitivity and grating acuity were measured with the SVEP. Sixteen children with OPGs (OPG group), 14 children with NF-1 without OPGs (nOPG), and 16 age-matched control subjects were recruited. All participants had best-corrected visual acuity of 6/9 or better. All were tested monocularly.

**RESULTS.** Comparisons between groups by using the Tukey B test showed a significant reduction of mean log contrast sensitivity in the OPG group (1.55) compared with the nOPG (1.9,  $P = 0.006$ ) and control (2.10,  $P < 0.001$ ) group. There was no significant difference between the nOPG and control groups ( $P = 0.195$ ). Grating acuity was comparable between groups, and no statistically significant differences were found. Log contrast sensitivity was moderately sensitive in identifying patients with OPG and was highly specific in screening out patients with no OPG.

**CONCLUSIONS.** Children with OPGs have reduced contrast sensitivity when assessed using the SVEP. Children with no OPGs display no differences in visual functioning compared with control subjects. The findings suggest that the SVEP can be a useful and noninvasive screening tool for early detection of visual pathway gliomas in children with NF-1 and normal visual acuity. (*Invest Ophthalmol Vis Sci.* 2007;48:2895–2902) DOI: 10.1167/iovs.06-0429

---

From the <sup>1</sup>Department of Ophthalmology and Vision Sciences and the <sup>2</sup>Division of Pediatric Medicine, The Hospital for Sick Children, Toronto, Ontario, Canada; the <sup>3</sup>Department of Ophthalmology and Visual Sciences, Alexandra Hospital, Singapore; and the <sup>4</sup>Department of Ophthalmology, Soroka University Medical Center, Beer-Sheva, Israel.

Supported by the SickKids BrainChild Group.

Submitted for publication April 17, 2006; revised September 8 and November 25, 2006; accepted March 26, 2007.

Disclosure: **B.C.M. Chang**, None; **G. Mirabella**, None; **R. Yagev**, None; **M. Banh**, None; **E. Mezer**, None; **P.C. Parkin**, None; **C.A. Westall**, None; **J.R. Buncic**, None

The publication costs of this article were defrayed in part by page charge payment. This article must therefore be marked "advertisement" in accordance with 18 U.S.C. §1734 solely to indicate this fact.

Corresponding author: Benjamin C. M. Chang, Department of Ophthalmology and Vision Sciences, The Hospital for Sick Children, 555 University Avenue, Toronto, ON M5G 1X8, Canada; benjamin\_chang@alexhosp.com.sg.

Neurofibromatosis type 1 (NF-1) is an autosomal dominant phakomatosis with a prevalence of 1 to 2000 to 1 to 5000.<sup>1</sup> Fifteen percent of these patients (range, 1.5%–24%) develop optic pathway gliomas (OPGs).<sup>2,3</sup> These gliomas, histologically juvenile pilocytic astrocytomas, are slow growing with low potential of malignancy. Nonetheless, they are locally invasive and compressive and can cause the loss of visual function. In their natural history, the median age of clinical presentation is 4.2 years, and 75% present within the first decade of life.<sup>4,5</sup>

Screening for OPGs usually entails assessments of several parameters, such as visual acuity and visual fields, to detect associated visual dysfunction. For young children and uncooperative patients, conducting this lengthy battery of tests can present a significant challenge. The alternative method currently used is screening by routine and periodic neuroimaging with either magnetic resonance imaging (MRI), preferably, or computed tomography (CT). However, these alternatives are expensive and require anesthesia or sedation in young children, with all its attendant risks. CT scans also entail a certain degree of ionizing radiation. In addition, routine imaging gives limited information, in that it cannot assess the functional effects of gliomas.

Conventional pattern visual evoked potentials (VEPs) have been used to evaluate the visual pathway system objectively and to estimate visual acuity as a screening test for OPGs in patients with NF-1.<sup>6</sup> The main drawback of this conventional test in the pediatric population is its long test duration (up to 30 minutes), and demands of prolonged and unpredictable visual attentiveness by the child.

Another alternative electrophysiological method is the sweep visual evoked potential (SVEP), a technique that improves on conventional VEP approaches by rapidly and objectively measuring basic measures of visual function such as contrast sensitivity and grating acuity.<sup>7,8</sup> In children, thresholds can be measured in a few minutes, and thus require minimal behavioral cooperation. SVEP is able to estimate visual thresholds rapidly because, unlike conventional VEPs, evoked potential responses are measured to a changing (or swept) stimulus during a trial. Efficiently obtaining thresholds in this manner may form the basis of a means of screening patients with NF-1 for optic nerve gliomas instead of frequent neuroimaging, which is more cumbersome and costly to administer.

It has been shown that contrast sensitivity is reduced at low spatial frequencies in patients with optic nerve compression.<sup>9,10</sup> This observation served as the impetus for exploring the SVEP as a quick and reliable means of measuring contrast sensitivity in these young children with NF-1. The objective of this study was to determine whether there is a significant difference in contrast sensitivity and grating acuity measured with SVEPs in children with NF-1 and OPGs and good visual acuity. The results from these patients were compared to those from patients with NF-1 with no OPGs and to normal controls. If the SVEP is able to identify contrast sensitivity deficits in

patients with OPGs, it may then form the basis of a noninvasive and effective method of screening for and observation of optic nerve gliomas in children with NF-1, as an alternative to frequent neuroimaging.

## METHODS

### Study Population

Children with NF-1 and OPG were recruited from the Pediatric Neurophthalmology clinic of The Hospital for Sick Children (SickKids), Toronto. Children with NF-1 without OPG were recruited from the Pediatric Neurofibromatosis Clinic of SickKids. The diagnosis of NF-1 was established by one of the authors (PCP), based on NIH diagnostic criteria.<sup>11</sup> Normal control subjects were solicited for participation through recruitment postings within the Ophthalmology Department.

The 16 NF-1 subjects with OPGs (OPG group: nine boys, seven girls; mean age,  $14.0 \pm 2.18$  years) had OPGs diagnosed by neuroimaging (CT and/or MRI) with no other brain tumor. The NF-1 subjects with no OPGs (nOPG group: eight boys, six girls; mean age,  $11.1 \pm 2.14$  years) had had MRIs showing no OPGs within the preceding 18 months. There were no significant differences in mean age between each group, as demonstrated by the confidence intervals. MRIs were performed in each child with gadolinium enhancement. The presence of an optic pathway glioma, identified by the neuroradiologist at SickKids, was defined as a thickening and/or tortuosity of the optic nerve or chiasm on neuroimaging. Inclusion criteria for both groups also were the absence of any other type of brain tumor, no history of brain surgery or chemotherapy, and a best corrected visual acuity of 6/9 or better in the tested eye.

The normal control subjects (control group: 9 boys, 7 girls; mean age =  $11.6 \pm 1.42$  years) included participants with no history of OPG, NF, or brain disease; no family history of NF; and best corrected visual acuity of 6/9 or better. Informed consent was obtained after a full debriefing regarding the procedure was provided to subjects and the parents or caregivers before testing, in accordance with the Declaration of Helsinki. The SickKids Research Ethics Board formally approved all procedures.

Before SVEP testing, all patients underwent a neuro-ophthalmic examination that included visual acuity, visual fields by confrontation, color vision, pupils (including the swinging flashlight test), slit lamp examination of the ocular anterior segment, and funduscopic examination of the optic discs and maculae. The examiners were not blinded to the NF-1 and OPG status of the child.

### Procedure

The visual evoked potential (VEP) technique measures the activity of the visual cortex in response to visual stimuli, processed along the primary visual pathway. An extension of this technique is the SVEP, which is a well-described, rapid method of measurement, based on the steady state evoked potential.<sup>7,12,13</sup> The steady state VEP consists of overlapping visual cortex responses evoked by stimulation at a rapid rate (greater than 4 Hz). The SVEP technique estimates contrast sensitivity and grating acuity by tracking the amplitude of the steady state evoked response to a black-and-white sine wave (striped) grating, which increases in contrast or spatial frequency. Thresholds are determined by performing a linear regression over a range of increasing or decreasing response values to 0 amplitude.

### Stimuli and Apparatus

Vertical black and white sine wave gratings were presented on a 17-in. (43-cm) video monitor (Dynamic Displays, Eau Claire, WI). The grating pattern was phase reversed at 12 reversals per second (6 Hz). A camera/laser-pointer system (LightMouse; United Detector Technology, Santa Monica, CA)<sup>14</sup> was used to calibrate the average luminance of the display, which was set photometrically to  $105 \text{ cd} \cdot \text{m}^{-2}$ . The grating subtended a visual angle of  $14^\circ$ .

The analogue electroencephalograph (EEG) signal was sampled and amplified with a gain of 20,000 (Grass Model 12 Data Acquisition System; Astro-Med, Inc., West Warwick, RI). The EEG was digitized to 16-bit accuracy over a 1- to 100-Hz bandwidth at a sampling rate of 600 Hz. The analog-to-digital signal conversion, data acquisition, stimulus presentation, and extrapolation of threshold estimates were controlled using the PowerDiva system (ver. 1.6), developed by Anthony M. Norcia and his laboratory at the Smith Kettlewell Eye Research Institute (San Francisco, CA).<sup>15</sup>

### VEP Recording

The method used to record SVEPs was that detailed by Norcia et al.<sup>7,8,12,13,16-19</sup> Children were seated 150 cm from the display, with active gold cup electrodes (Grass F-E5GH; Astro-Med, Inc.) attached according to the International 10/20 system.<sup>20</sup> There were three active electrodes ( $O_z$ ,  $O_1$ ,  $O_2$ ) used, which referred to  $C_z$ , with  $P_z$  used as a ground. The examination was performed monocularly while the other eye was patched. In patients with unilateral glioma, only affected eyes were tested. In those with bilateral glioma and in control subjects, the right eye was tested first. Subjects wore their refraction while being tested.

Children who experienced difficulty in maintaining fixation were attracted to the screen by a small toy or bell dangled 1 to 2 cm in front of the display for the duration of each trial. The experimenter determined whether the child was fixating and suspended and rejected trials when necessary. Although the presence of the toy may have occluded some areas of the fovea, it kept the subject's fixation and accommodation on the screen during the length of the trial. Since acuity and contrast thresholds are dependent on the synchronization of the evoked response to the stimulus, the toy would not affect threshold estimation.<sup>15</sup>

### VEP Threshold Estimation

The amplitude and phase of the evoked response was calculated at the pattern reversal response of 12 Hz (the second harmonic of the reversal rate) using the recursive least squares (RLS) method.<sup>21,22</sup> This adaptive filter has a higher detectability rate than does a conventional discrete Fourier transform (DFT), especially for short data records. The RLS was performed over a running 1-second window or "bin" of the EEG. Each trial began with a "prelude" bin, followed by ten 1-second bins, each measuring the amplitude and phase of the evoked response. The evoked response was compared to a noise response measured as the mean of 11- and 13-Hz responses. As these frequencies do not correspond to the pattern reversal rate, they are independent of the evoked signal. A minimum of three valid 10-second trials was recorded for each condition.

Four criteria had to be met for the VEP response signal to be scorable:

1. The peak amplitude of the response had to exceed the average noise by a factor of 3. Norcia et al.<sup>7</sup> showed that this signal-to-noise ratio gives a conservative false signal alarm rate of 0.3% for any one bin of measurement.
2. The phase of the response had to be constant (synchronized) with stimulus onset. Alternatively, the phase could also progressively increase with spatial frequency sweeps or decrease with contrast sweeps, due to latency changes in the visual system.<sup>23-25</sup>
3. Signal peaks produced by broadband artifacts, such as those produced by muscle contractions and eye blinks, were rejected.<sup>24</sup>
4. The peak amplitude of the signal had to be significantly above zero ( $P \leq 0.05$ ) according to the circular  $T^2$  statistic, which tests the consistency of the amplitude and phase (Fourier components) of responses within a bin.<sup>26</sup>

For contrast sweeps, a grating of low spatial frequency, 0.5 cyc/deg, was swept from low to high contrast (range, 0.5%–20%), over a 10-

second period in log steps. For grating acuity sweeps, the stimulus was set at 80% contrast and swept from below the acuity limit, increasing to beyond detection in linear steps (range, 3–23 cyc/deg).

Individual trials were rejected if there were computer data acquisition errors or if there was an experimenter error (e.g., collecting data while the patient was not looking). The signal average of all remaining accepted trials was used to calculate the thresholds. To estimate acuity and contrast thresholds, PowerDiva searches the VEP record for a range of increasing (for log stimulus frequency) or decreasing (for linear spatial frequency) responses in the evoked signal, to perform a linear regression to 0 amplitude. The highest spatial frequency or lowest contrast peak that met all scoring criteria was chosen for extrapolation. A linear regression line was then fit between this peak down to the point of 0 amplitude.<sup>7,8,12</sup> The spatial frequency or contrast at which the regression line crossed 0- $\mu$ V amplitude was taken as the grating or contrast threshold estimate. Examples of contrast and grating acuity SVEPs, along with regression lines, are shown in Figure 1.

### Statistical Analysis

Because we did not have data for both eyes of some of our patients, contrast sensitivity and grating acuity were analyzed by repeated-measures regression. That is, in addition to testing for differences among OPG, nOPG, and control groups, the model incorporated the within-patient correlation of eyes (eye covariate). Thus, all the data we collected could be included in the analysis. Of note, the eye covariate was not significant in the analysis of contrast sensitivity or of grating acuity, suggesting that the effects of OPG and NF-1 in general on visual functioning did not correlate between eyes. To analyze the contrast conditions, we converted the percentage contrast thresholds to contrast sensitivity (inverse of contrast threshold) and then log transformed them. Grating acuity thresholds were not transformed. Pairwise comparisons among means were made for significant group effects by using the Tukey-Kramer (Tukey B) adjustment for multiple comparisons. Degrees of freedom for all F tests were corrected with the Kenward and Roger<sup>27</sup> adjustment for small sample sizes.

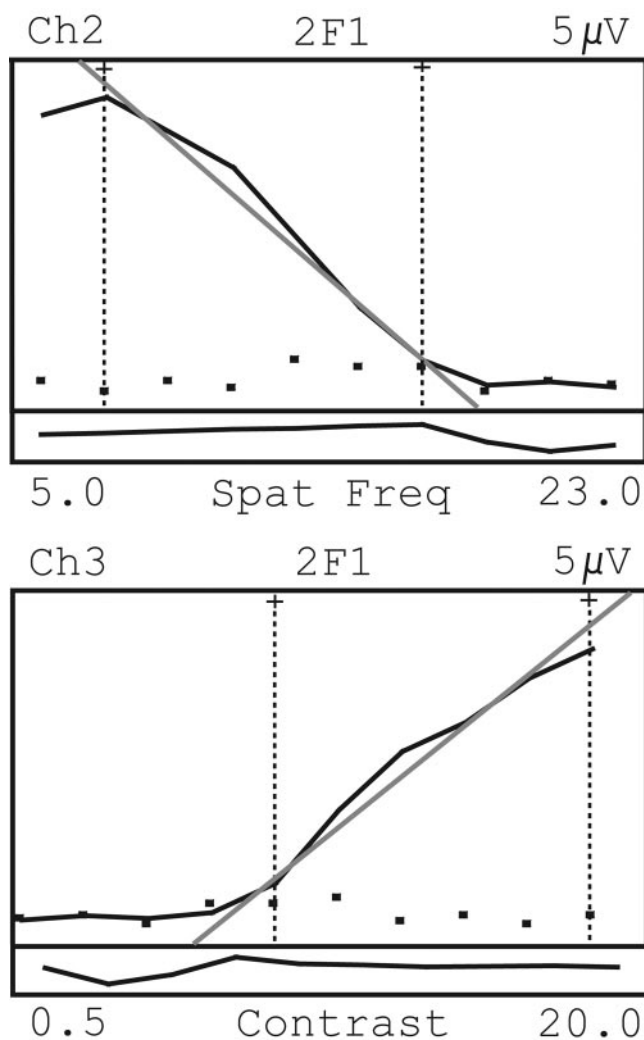
For screening, a scatterplot of individual scores was made for each of the groups. A criterion score for identifying a low vision function suggestive of OPG was established by comparison of scores between the OPG and nOPG groups. Once a criterion score was chosen, sensitivity and specificity were calculated (SPSS 11.0 for Mac OS X; SPSS, Chicago, IL).

### RESULTS

The systemic clinical features for the patients in the OPG and nOPG groups are detailed in Table 1. The ophthalmic findings for these patients are outlined in Tables 2 and 3. All members of the control group had normal results in their ophthalmic examinations.

SVEP data, which satisfied all criteria for scoring, were obtained from most of the eyes tested. Thresholds for the control group were consistent with recently published values for contrast sensitivity and grating acuity.<sup>28</sup> In the OPG group, there was a total of 24 eyes of 32 (75%) analyzed from 16 patients. In the nOPG group, there were 23 eyes of 28 (82.1%) scorable from 14 patients, and in the control group, there were 29 eyes of 32 (90.6%) scorable from 16 patients.

There was a statistically significant difference in contrast sensitivity among groups ( $F = 14.99$ ,  $P < 0.0001$ ). Group comparisons using the Tukey B test showed a significant difference between the OPG group (least-square mean log contrast sensitivity = 1.51) and the nOPG and control groups (1.89 and 2.09,  $P < 0.0001$  and  $P = 0.006$ , respectively). There was no significant difference in contrast sensitivity between the nOPG and control groups ( $P = 0.14$ ). These results are shown in Figure 2 with each group's SE displayed graphically. The eye covariate was not significant ( $F = 3.31$ ,  $P = 0.077$ ).



**FIGURE 1.** Sweep VEP response functions. To estimate thresholds, PowerDiva searches the VEP record for a range of increasing or decreasing responses in the evoked signal (solid line), to perform a linear regression to 0 amplitude. The peak amplitude meeting all scoring criteria is chosen for extrapolation. A linear regression line (straight gray line) is then fitted between this peak down to the point of 0 amplitude (abscissa). (■) The noise response. The bottom rectangular area of each function plots the phase (in radians) of the evoked response. Phase consistency is a component of the scoring criteria. Top: spatial frequency response function used to estimate grating acuity; bottom: a contrast response function used to estimate contrast sensitivity.

Grating acuity was comparable between groups, and no statistically significant differences were found ( $F < 1$ ). The least-squares mean grating acuities for the OPG, nOPG, and control groups were 16.72, 15.64, and 16.54 cyc/deg, respectively, and are displayed in Figure 3. Again, the eye covariate was not significant ( $F < 1$ ).

Log contrast sensitivity among groups was compared by plotting individual scores and determining the optimal cutoff. As shown in Figure 4, there was a significant reduction in log contrast sensitivity for the OPG group only. A comparison of the data between OPG and nOPG was used to establish an optimum criterion log contrast sensitivity cutoff of 1.7 (Fig. 4, gray line). This cutoff, which is equal to a mean contrast threshold of 1.99%, corresponded to a sensitivity of 0.63 and a specificity of 0.87. A scatterplot of grating acuity scores for the three groups is also shown for comparison.

TABLE 1. Systemic Findings in Patients with NF-1: OPG and Non-OPG Groups

No.	Age	Sex	Group	Café au Lait	Neurofibromas/ Plexiform Neurofibroma	Freckling Axilla/ Inguinal	Osseous Lesion	Family History	MRI UBOS	Other
1	8	F	OPG	+	-	+	-	-	+	LD, S
2	11	F	OPG	+	+	+	-	-	+	
3	7	M	OPG	+	-	+	-	-	+	LD, AD
4	16	M	OPG	+	+	+	-	-	+	S
5	17	F	OPG	+	-	+	-	+	+	S
6	17	M	OPG	+	+	-	+	+	-	S, spondylolisthesis, PVS
7	18	M	OPG	+	+	+	-	+	+	
8	17	M	OPG	+	+	+	-	-	+	LD, precocious puberty
9	9	F	OPG	+	+	+	-	-	+	LD, cerebral palsy, prematurity, hearing loss
10	18	M	OPG	+	+	+	+	-	-	LD, S, left carotid aneurysm
11	14	M	OPG	+	+	+	-	-	+	Precocious puberty
12	22	F	OPG	+	-	+	-	-	+	
13	12	M	OPG	+	+	+	+	-	+	S, LD
14	17	F	OPG	+	+	+	+	-	+	Neurogenic sarcoma right popliteal fossa
15	13	F	OPG	+	+	+	-	-	+	
16	8	M	OPG	+	+	+	-	-	+	LD
17	14	M	Non-OPG	+	-	+	-	±	+	Mild ventriculomegaly
18	14	M	Non-OPG	+	+	+	-	-	-	S
19	9	M	Non-OPG	+	-	+	±	-	+	LD
20	11	M	Non-OPG	+	+	+	-	-	+	S, LD, HT, RAS
21	7	F	Non-OPG	+	+	+	-	-	-	PVS
22	19	F	Non-OPG	+	+	+	-	-	-	LD, AD
23	4	M	Non-OPG	+	-	+	-	+	-	Short stature, macrocephaly, LD
24	5	F	Non-OPG	+	+	+	-	-	+	S, mild ventriculomegaly
25	9	F	Non-OPG	+	+	+	-	-	+	LD, L multicystic dysplastic kidney
26	10	F	Non-OPG	+	+	+	+	-	+	Short stature
27	13	M	Non-OPG	+	+	+	-	-	-	S, LD
28	14	M	Non-OPG	+	+	+	-	-	+	PVS, LD
29	13	M	Non-OPG	+	+	+	-	-	+	
30	14	F	Non-OPG	+	-	+	-	-	+	LD, AD

UBO, unidentified bright object; S, scoliosis; LD, learning difficulties; AD, attention difficulties; PVS, pulmonary valve stenosis; HT, hypertension; RAS, renal artery stenosis.

## DISCUSSION

Our study shows that a substantial and significant reduction in contrast sensitivity is detected with the SVEP in children with NF-1 who have OPGs with normal visual acuity, compared with NF-1 children without OPGs and normal control subjects.

The ability of our contrast sensitivity measure to identify patients with NF-1 with OPG was moderate, with sensitivity at 0.67. Conversely, a specificity of 0.87 suggests that the measure was quite good at identifying patients who did not have OPG, because, as can be seen in Figure 4, there was an overlap between the contrast sensitivity distributions of patients with NF-1 with no OPG and those patients with OPG and higher contrast sensitivity. However, there was a clear subgroup of patients with OPG who had markedly reduced sensitivity.

Although the moderate sensitivity in identifying patients with OPG may appear troubling, it is important to remember that this group of patients is almost completely clinically silent (Table 2), meaning that the sensitivity of the eye examination is effectively 0. Conversely, the SVEP was able to identify OPG in approximately two thirds of this sample in the absence of other visual symptoms. Further, SVEP contrast sensitivity appears to be particularly effective for screening out the presence of OPG in our sample, since the contrast sensitivity in patients with NF-1 with no OPG is altogether normal. Taken together, these results suggest that SVEP contrast sensitivity may be an effective functional measure for detecting the presence of optic pathway gliomas in patients with NF-1. Thus, an electrophysiological measure appears to detect functional consequences of OPGs in these patients most readily.

Optic pathway gliomas account for 0.6% to 5.1% of all brain tumors in childhood. Furthermore, up to 70% of OPGs are

associated with NF-1.<sup>29</sup> Although they generally behave in a benign manner, OPGs can lead to vision loss or less commonly, extend to nearby brain regions and cause other signs and symptoms. The period of greatest risk for development of symptomatic OPGs is during the first 6 years of life.<sup>5</sup> Currently, the NF-1 Optic Pathway Glioma Task Force recommends once-yearly complete ophthalmic examinations for screening NF-1 children younger than 7 years of age who are asymptomatic,<sup>30</sup> although it is known that a significant number of OPGs remain clinically silent or undetectable.<sup>5</sup> Longer intervals between examinations are suggested for older children. Neuroimaging as screening examinations in patients with NF-1 without clinical signs or symptoms has not been recommended, apparently because of the risks to young patients associated with anesthesia and CT radiation and the high costs of the neuroimaging examinations. The guidelines do recommend MRI neuroimaging when there are abnormal ophthalmic findings. For children with an established OPG diagnosis, regular ophthalmic examinations with neuroimaging are also suggested.

The ophthalmic examination in uncooperative children can be difficult, and pediatric vision tests (e.g., single-letter matching tests) have been known to overestimate visual acuity. Cognitive impairment can be associated with NF-1<sup>31</sup> and this adds another potential factor that can limit clinical examination techniques that require a subjective response, even in older children. Clinically normal examination findings (e.g., a normal optic nerve head appearance) do not definitively rule out the existence of OPG. A normal pupillary examination result is also not definitive. None of the patients in our OPG group had a relative afferent pupillary defect (RAPD). Symmetrical involvement of the optic nerves or chiasmal gliomas would eliminate

TABLE 2. Ophthalmic Findings in Patients with OPG

No.	Age	Sex	Glioma Location	Visual Acuity	Color Vision (HRR)	Confrontation Visual Fields	Refraction	Pupils	Anterior Segment	Fundi
1	8	F	Optic nerves OU	20/20 OU	N	N	NSRE	N	N	N
2	11	F	Optic nerve OS	20/20 OU	N	N	NSRE	N	N	N
3	7	M	Optic nerve OS	20/30 OU	Missed some plates OU	N	NSRE	N	Mild proptosis OS	N
4	16	M	Optic nerve OD	20/20 OU	Missed one plate	N	NSRE	N	Lisch nodules	N
5	17	F	Optic nerve OS	20/25 OD 20/20 OS	N	N	-1.50 OU	N	N	N
6	17	M	Chiasm+optic nerves OU	20/20 OU	N	N	NSRE	N	L cong ptosis	N
7	18	M	Chiasm+optic nerves OU	20/20 OU	N	N	-2.25D OU	N	Lisch nodules	N
8	17	M	Chiasm	20/20 OU	N	Slight temporal field red desaturation OS	NSRE	N	Lisch nodules	Minimal disc pallor OU
9*	9	F	Chiasm+optic nerves OU	20/20 OU	N	N	+1.0 OU	N	Lisch nodules	N
10	18	M	Chiasm	20/20 OU	N	N	N	N	Lisch nodules	N
11	14	M	Chiasm+optic tract OD	20/20 OU	N	N	-1.50 OD -2.25 OS	N	Lisch nodules	N
12	22	F	Optic nerves OU	20/20 OD 20/30 OS	N	N	-3.0 OD -9.0 OS	N	Lisch nodules	Myopic fundi
13	12	M	Chiasm+optic nerve OD	20/20 OU	N	N	NSRE	N	Lisch nodules	Suspect NFL loss OU
14†	17	F	Optic nerves OU	20/20 OU	N	N	+0.50/+1.25×90 +0.50/+0.50×90	Horner's syndrome OS	N	N
15	13	F	Optic nerve OS	20/20 OU	N	N	-2.50D OU	N	Lisch nodules	N
16	8	M	Chiasm+optic nerve OS	20/20 OD 20/30 OS	N	N	Plano/+0.50 OD Plano/+1.50 OS	N	N	Minimal disc pallor OU

N, normal; color vision - All plates of Hardy-Rand-Rittler test identified; confrontation visual fields, no gross field defect identified; pupils, round, equal and reactive. No relative afferent pupil defect; anterior segment, no Lisch nodules. No anterior segment abnormalities; fundi, healthy optic discs and maculae; NSRE, no significant refractive error (-0.50 to +1.0 DS, <1.50 DCy1, <1.0 D anisometropia); NFL, nerve fiber layer.

\* Patient 9 has a small partial accommodative esotropia. She had patching for mild left amblyopia in the past.

† Patient 14 had left Horner's syndrome (ptosis + miosis) secondary to previous thoracic surgery.

the presence of an RAPD. However, 5 of the 16 patients in the OPG group had a unilateral glioma. In these patients, one explanation of an absent RAPD may be that the relative difference in the afferent defect in these patients was so small that a clinical examination of the pupils did not detect it. Another possibility is that a pupillary examination in certain children may be difficult because of variable fixation activity and an active near response to the examiner.

Conventional pattern VEPs have been proposed as a screening test for children with asymptomatic NF-1, but there are inherent limitations in this method. Although one study demonstrated 100% sensitivity and 60% specificity for the pattern VEP in detecting optic pathway gliomas in children,<sup>6</sup> the authors acknowledged that the test is limited by the age at which the child will cooperate with the long procedure and that reliable results may not be obtained in subjects younger than 5 years. Other studies have not found VEPs to be sensitive tests in detecting OPGs.<sup>32</sup> Another limitation is the question of specificity. Some degree of abnormality can be found in as many as 62.5% of VEPs of children with NF-1 without MRI evidence of OPGs.<sup>33</sup>

It is unknown why there is such a high incidence of conventional VEP abnormalities occurring in patients with NF-1 with no OPG. One speculation is that formation of unidentified bright objects (UBOs) on brain MRI may be linked with VEP

abnormalities.<sup>33</sup> UBOs are hyperintense, T<sub>2</sub>-weighted foci that are commonly found in the MRI scans of patients with NF-1. Their nature is unclear, but they occur in up to 60% of patients.<sup>34</sup> Nine (64.3%) of 14 patients in the nOPG group in our study had UBOs. It may be that the slight reduction in contrast sensitivity in the patients with NF-1 without OPGs in the present study is the result of UBOs. This reduction was not statistically significant, however, compared with normal controls. The effect of NF-1 cerebral abnormalities appears to produce only minimal, if any, disruption in visual functioning, as measured with the SVEP, whereas our results suggest that the presence of OPGs produces a far greater disruption.

There are many advantages to the use of the SVEP in this age group. SVEPs have been used reliably to obtain acuity and contrast estimates in children and infants and so may serve as an ideal measure for assessment of patients with NF-1. Each sweep trial is short, taking only approximately 10 seconds, and places fewer demands on the young patient's attention span compared with the conventional VEP. As with other VEP tests, it does not require a subjective response, and so it can overcome the lack of verbalization and the often limited cooperation in the younger or cognitively impaired patient. The SVEP is also a noninvasive test, as it does not necessitate the use of anesthesia or sedation and avoids any exposure to ionizing irradiation, as occurs in CT neuroimaging.

TABLE 3. Ophthalmic Findings in Patients with NF-1 but No OPG

No.	Age	Sex	Visual Acuity	Color Vision (HRR)	Confrontation Visual Fields	Refraction	Pupils	Anterior Segment	Fundi
1	14	M	20/20 OU	N	N	NSRE	N	Lisch nodules	N
2	14	M	20/20 OU	N	N	NSRE	N	Lisch nodules	N
3	9	M	20/20 OU	N	N	NSRE	N	Lisch nodules	N
4	11	M	20/20 OU	N	N	NSRE	N	N	N
5	7	F	20/25 OD 20/20 OS	N	N	-0.75/+1.0×90 OD Plano OS	N	N	N
6	19	F	20/20 OU	N	N	NSRE	N	N	N
7	4	M	20/25 OU	Missed one plate	N	NSRE	N	N	N
8	5	F	20/20 OU	N	N	NSRE	N	Lisch nodules	N
9	9	F	20/20 OU	N	N	NSRE	N	N	N
10	10	F	20/20-2 OD 20/20 OS	N	N	NSRE	N	N	N
11	13	M	20/20 OD 20/25 OS	N	N	-0.25/+0.75×10 +1.5/+0.5×180	N	Lisch nodules	N
12	14	M	20/20 OU	N	N	NSRE	N	N	N
13	13	M	20/20 OU	N	N	NSRE	N	Lisch nodules	N
14	14	F	20/20 OU	N	N	-2.50 OD -2.25 OS	N	Lisch nodules	N

Abbreviations and data are as described in Table 2.

Finally, why might contrast sensitivity be selectively affected? There is evidence that contrast sensitivity is reduced in other patients who have compressive lesions in the anterior visual pathways.<sup>9</sup> Similar to patients with OPG in the present study, these deficits are even apparent in patients with normal acuity, color vision, visual fields, and pupillary reactions. Because the magnocellular ganglion cells mediate contrast sensitivity at low spatial frequencies and because these cells have large receptive fields and ganglion-cell sizes,<sup>35</sup> it has been proposed that compression of the optic nerve has its earliest effects on these large-caliber axons.<sup>9</sup> With a large-caliber axon, there is less longitudinal resistance to compression, and so they are more susceptible to disruptions from compressive lesions. Another possible explanation is that compressive lesions produce more extensive ischemic pruning of retinal ganglion cells in larger dendritic trees.<sup>9</sup> This pruning may also account for the presence of SVEP abnormalities without an RAPD in our patients with OPG with unilateral glioma. Magnocellular cell involvement may have a greater effect on contrast sensitivity

measurements at low spatial frequencies, than on the clinical observation of an RAPD. There is also evidence that compressive lesions may impair fovea-specific pathways earlier.<sup>36</sup> Because the sweep VEP measures central retinal fields more specifically, it is possible that early OPG lesions would become manifest in sweep VEP abnormalities before an abnormal pupillary reaction. Thus, testing of contrast sensitivity at low spatial frequencies may be a particularly sensitive method for detection of compressive lesions of the anterior visual pathway.

One limitation of our study in the nOPG group is the time gap between neuroimaging and SVEP testing, which may have been as long as 18 months. Although it is still possible that an optic glioma might have arisen during that time frame, since most of our patients were older than the high-risk age of less than 6 years,<sup>5</sup> it is highly unlikely. Another drawback is that, despite the lesser demand on patient attention with the SVEP method compared with conventional VEP, there were still a proportion of recordings that did not fulfill the strict criteria for scoring, possibly because of the patients' inattention and fa-

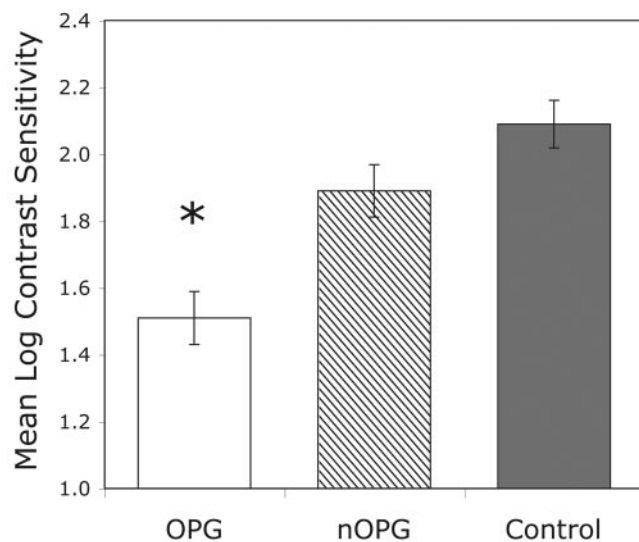


FIGURE 2. Mean log contrast sensitivity for each group. \*Statistically significant difference.

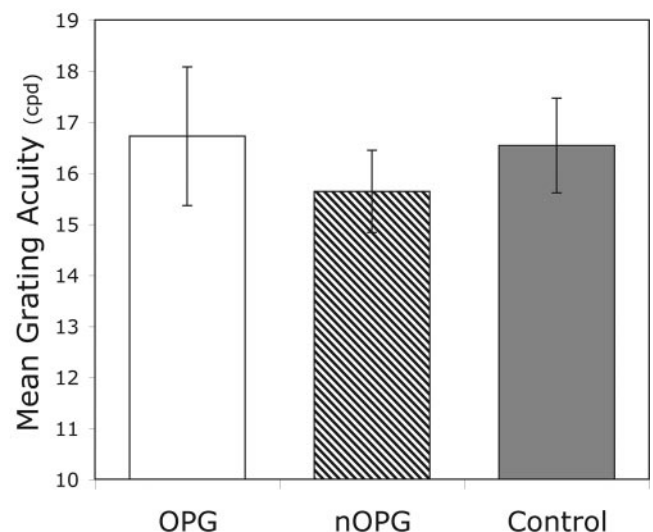
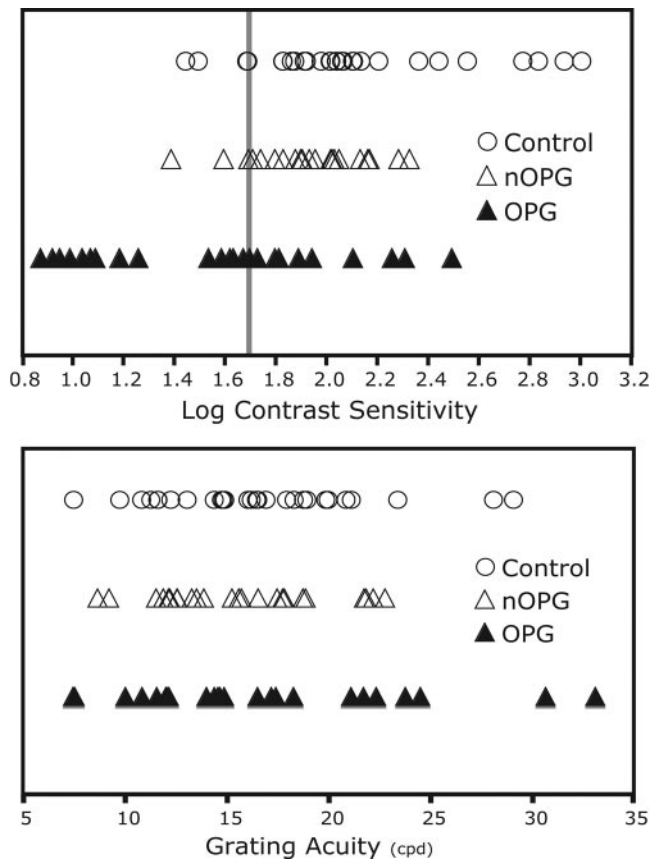


FIGURE 3. Mean grating acuity for each group.



**FIGURE 4.** Scatterplots showing the distribution of log contrast sensitivity (*top*) and grating acuity (*bottom*) for the OPG, nOPG, and control groups. The vertical line in the log contrast sensitivity plot marks the cutoff (1.7) chosen for the sensitivity and specificity analyses. Each point represents the measurement from one eye. Number of eyes per group: OPG, 24; nOPG, 25; control, 29.

figure. For the purposes of this study, most of our subjects came in for one recording session only. If poor recordings were obtained the first time, a repeat visit might have produced better data.

There have been criticisms against the usage of VEPs for routine evaluation of children with NF-1, in part due to the controversy surrounding the management of optic gliomas. The natural history can be quite variable, with most tumors behaving in a benign fashion and a few with rapid progression with vision loss. Rare instances of spontaneous improvement of vision have been reported.<sup>37</sup> Because most decisions to treat are based on clinical or radiologic progression,<sup>29</sup> one could contend that presymptomatic detection with VEPs has no benefit. In contrast, the use of SVEP would be useful as a baseline and in tracking the course of known OPGs in infants who might be receiving chemotherapy but in whom examination of the fundi and optic nerves alone would give an inadequate assessment of clinical response to treatment.

Radiotherapy and chemotherapy has been shown to slow progression of optic gliomas in symptomatic patients and can result in stabilization, although not always improvement in vision. Chemotherapy has, in recent studies, been particularly promising. One- or two-drug chemotherapy regimens have been used, with good progression-free survival rates.<sup>38,39</sup> In younger children with OPGs, radiotherapy is preferably avoided due to its potential neuropsychological and cognitive adverse effects on the developing brain.<sup>40</sup>

Although it has not been established whether very early treatment can prevent the development of symptoms altogether, there has been a suggestion that presymptomatic treatment may be beneficial.<sup>41</sup> Of importance, earlier diagnosis of OPGs would also allow closer monitoring of the patient, and earlier detection of visual loss. Early detection can be especially important in the young patient with rapidly progressive OPG, some of whom may have confusing ocular examination findings with failing visual function, but as yet undetectable optic atrophy. The SVEP contrast sensitivity could also be used as a sensitive outcome measure, to measure improvement, or stability of vision, in future treatment trials.

## CONCLUSION

Children with NF-1 who have OPGs and normal visual acuity have reduced contrast sensitivity when assessed by SVEP. The SVEP can be a useful noninvasive screening test for presymptomatic OPGs in patients with NF-1 and for assessing the clinical course of OPGs over time, whether or not treatment is being administered. From a practical perspective, the use of SVEP monitoring of patients with OPG can be integrated with MRI screening or a follow-up strategy, to provide early detection information and decrease the frequency of MRI neuroimaging, especially in infants and toddlers. Although our results suggest that this technique can provide the basis for a useful screening and monitoring test in this childhood population, further validation studies are needed before the method can be recommended for wide and reliable use.

## Acknowledgments

The authors thank Vivek Patel who initiated an earlier version of this study before the laboratory acquired SVEP technology.

## References

- Rasmussen SA, Friedman JM. NF1 gene and neurofibromatosis 1. *Am J Epidemiol.* 2000;151:33–40.
- Lewis RA, Riccardi VM. von Recklinghausen neurofibromatosis. II. Incidence of optic gliomata. *Ophthalmology.* 1984;91:929–935.
- Stern J, Jakobiec FA, Housepian EM. The architecture of optic nerve gliomas with and without neurofibromatosis. *Arch Ophthalmol.* 1980;98:505–511.
- Listernick R, Charrow J, Greenwald MJ, Esterly NB. Optic gliomas in children with neurofibromatosis type 1. *J Pediatr.* 1989;114:788–792.
- Listernick R, Charrow J, Greenwald M, Mets M. Natural history of optic pathway tumors in children with neurofibromatosis type 1: a longitudinal study. *J Pediatr.* 1994;125:63–66.
- North K, Cochineas C, Tang E, Fagan E. Optic gliomas in neurofibromatosis type 1: role of visual evoked potentials. *Pediatr Neurol.* 1994;10:117–123.
- Norcia AM, Tyler CW. Spatial frequency sweep VEP: visual acuity during the first year of life. *Vision Res.* 1985;25:1399–1408.
- Norcia AM, Tyler CW, Hamer RD, Wesemann W. Measurement of spatial contrast sensitivity with the swept contrast VEP. *Vision Res.* 1989;29:627–37.
- Tytla M, Buncic JR. Optic nerve compression impairs low spatial frequency vision in man. *Clin Vision Sci.* 1988;2:179–186.
- Kupersmith, MJ, Siegel IM, Carr RE. Subtle disturbances of vision with compressive lesions of the anterior visual pathway measured by contrast sensitivity. *Ophthalmology.* 1982;89:68–72.
- Neurofibromatosis.* Conference statement. National Institutes of Health Consensus Development Conference. *Arch Neurol.* 1988;45:575–578.
- Norcia AM, Tyler CW. Infant VEP acuity measurements: analysis of individual differences and measurement error. *Electroencephalogr Clin Neurophysiol.* 1985;61:359–369.

13. Norcia AM, Tyler CW, Allen D. Electrophysiological assessment of contrast sensitivity in human infants. *Am J Optom Physiol Opt.* 1986;63:12-15.
14. Tyler CW, McBride B. The morphonome image psychophysics software and a calibrator for Macintosh systems. *Spat Vis.* 1997; 10:479-484.
15. Norcia AM. *PowerDiva Manual.* San Francisco: Smith-Kettlewell Eye Research Institute; 1999.
16. Norcia AM, Tyler CW, Hamer RD. High visual contrast sensitivity in the young human infant. *Invest Ophthalmol Vis Sci.* 1988;29:44-49.
17. Norcia AM, Tyler CW, Hamer RD. Development of contrast sensitivity in the human infant. *Vision Res.* 1990;30:1475-1486.
18. Norcia AM, Tyler CW, Piecuch R, Clyman R, Grobstein J. Visual acuity development in normal and abnormal preterm human infants. *J Pediatr Ophthalmol Strabismus.* 1987;24:70-74.
19. Skoczenski AM, Norcia AM. Development of VEP vernier acuity and grating acuity in human infants. *Invest Ophthalmol Vis Sci.* 1999;40:2411-2417.
20. Jasper H. Report of the committee on methods of clinical examination in electroencephalography. *Electroencephalogr Clin Neurophysiol.* 1985;10:370-375.
21. Tang Y, Norcia AM. An adaptive filter for steady-state evoked responses. *Electroencephalogr Clin Neurophysiol.* 1995;96:268-277.
22. Tang Y, Norcia AM. Application of adaptive filtering to steady-state evoked response. *Med Biol Eng Comput.* 1995;33:391-395.
23. Vassilev A, Simeonova B. Temporal characteristics of the recognition of short lines orientation. *Acta Physiol Pharmacol Bulg.* 1980;6:13-22.
24. Parker DM, Salzen EA. The spatial selectivity of early and late waves within the human visual evoked response. *Perception.* 1977;6:85-95.
25. Parker DM, Salzen EA. Latency changes in the human visual evoked response to sinusoidal gratings. *Vision Res.* 1977;17:1201-1204.
26. Victor JD, Mast J. A new statistic for steady-state evoked potentials. *Electroencephalogr Clin Neurophysiol.* 1991;78:378-388.
27. Kenward MG, Roger JH. Small sample inference for fixed effects from restricted maximum likelihood. *Biometrics.* 1997;53:983-997.
28. Lauritzen L, Jorgensen MH, Michaelsen KF. Test-retest reliability of swept visual evoked potential measurements of infant visual acuity and contrast sensitivity. *Pediatr Res.* 2004;55:701-708.
29. Dutton JJ. Gliomas of the anterior visual pathway. *Surv Ophthalmol.* 1994;38:427-452.
30. Listernick R, Louis DN, Packer RJ, Gutmann DH. Optic pathway gliomas in children with neurofibromatosis 1: consensus statement from the NF1 Optic Pathway Glioma Task Force. *Ann Neurol.* 1997;41:143-149.
31. Dilts CV, Carey JC, Kircher JC, et al. Children and adolescents with neurofibromatosis 1: a behavioral phenotype. *J Dev Behav Pediatr.* 1996;17:229-239.
32. Rossi LN, Pastorino G, Scotti G, et al. Early diagnosis of optic glioma in children with neurofibromatosis type 1. *Childs Nerv Syst.* 1994;10:426-429.
33. Iannaccone A, McCluney RA, Brewer VR, et al. Visual evoked potentials in children with neurofibromatosis type 1. *Doc Ophthalmol.* 2002;105:63-81.
34. DiMario FJ Jr, Ramsby G, Greenstein R, Langshur S, Dunham B. Neurofibromatosis type 1: magnetic resonance imaging findings. *J Child Neurol.* 1993;8:32-39.
35. Boycott BB, Wassle H. The morphological types of ganglion cells of the domestic cat's retina. *J Physiol.* 1974;240:397-419.
36. Gutowski NJ, Heron JR, Scase MO. Early impairment of foveal magno- and parvocellular pathways in juxta chiasmal tumours. *Vision Res.* 1997;37:1401-1408.
37. Liu GT, Lessell S. Spontaneous visual improvement in chiasmal gliomas. *Am J Ophthalmol.* 1992;114:193-201.
38. Packer RJ, Ater J, Allen, et al. Carboplatin and vincristine chemotherapy for children with newly diagnosed progressive low-grade gliomas. *J Neurosurg.* 1997;86:747-754.
39. Gururangan S, Cavazos CM, Ashley D, et al. Phase II study of carboplatin in children with progressive low-grade gliomas. *J Clin Oncol.* 2002;20:2951-2958.
40. Lacaze E, Kieffer V, Streri A, et al. Neuropsychological outcome in children with optic pathway tumours when first-line treatment is chemotherapy. *Br J Cancer.* 2003;89:2038-2044.
41. Liu GT, Malloy P, Needle M, Phillips P. Optic gliomas in neurofibromatosis type 1: role of visual evoked potentials. *Pediatr Neurol.* 1995;12:89-90.