

Accommodative Lens Refilling in Rhesus Monkeys

Steven A. Koopmans,¹ Thom Terwee,² Adrian Glasser,³ Mark Wendt,³
Abhiram S. Vilipuru,³ Theo G. van Kooten,⁴ Sverker Norrby,²
Henk J. Haitjema,² and Aart C. Kooijman⁵

PURPOSE. Accommodation can be restored to presbyopic human eyes by refilling the capsular bag with a soft polymer. This study was conducted to test whether accommodation, measurable as changes in optical refraction, can be restored with a newly developed refilling polymer in a rhesus monkey model. A specific intra- and postoperative treatment protocol was used to minimize postoperative inflammation and to delay capsular opacification.

METHODS. Nine adolescent rhesus monkeys underwent refilling of the lens capsular bag with a polymer. In the first four monkeys (group A) the surgical procedure was followed by two weekly subconjunctival injections of corticosteroids. In a second group of five monkeys (group B) a treatment intended to delay the development of capsular opacification was applied during the surgery, and, in the postoperative period, eye drops and two subconjunctival injections of corticosteroids were applied. Accommodation was stimulated with carbachol iontophoresis or pilocarpine and was measured with a Hartinger refractometer at regular times during a follow-up period of 37 weeks in five monkeys. In one monkey, lens thickness changes were measured with A-scan ultrasound.

RESULTS. In group A, refraction measurement was possible in one monkey. In the three other animals in group A, postoperative inflammation and capsular opacification prevented refraction measurements. In group B, the maximum accommodative amplitude of the surgically treated eyes was 6.3 D. In three monkeys the accommodative amplitude decreased to almost 0 D after 37 weeks. In the two other monkeys, the accommodative amplitude remained stable at ± 4 D during the follow-up period. In group B, capsular opacification developed in the postoperative period, but refraction measurements could still be performed during the whole follow-up period of 37 weeks.

CONCLUSIONS. A certain level of accommodation can be restored after lens refilling in adolescent rhesus monkeys. During the follow-up period refraction measurements were possible in all five monkeys that underwent the treatment designed to pre-

vent inflammation and capsular opacification. (*Invest Ophthalmol Vis Sci.* 2006;47:2976–2984) DOI:10.1167/iovs.05-1346

Accommodation is the ability to change the optical power of the eye for near vision. This enables dynamic focusing of the image of objects at different distances on the retina. According to the Helmholtz theory,¹ contraction of the ciliary muscle and relaxation of the zonular fibers at the lens equator are associated with an increase in anterior and posterior lens curvature. The elasticity of the lens capsule and the malleability of the lens contents enables the lens curvatures to increase. During relaxation of accommodation, the tension of the zonular fibers, which insert into the ciliary body and choroid, increases, thus pulling the lens back in its unaccommodated, flattened state. At around 45 years of age, the age-related decrease in accommodative amplitude begins to be expressed symptomatically²—an occurrence that is called presbyopia. Factors that may be responsible for presbyopia are lens hardening,^{3–5} aging of the ciliary muscle,⁶ aging of the choroid,^{7,8} loss of elasticity of the lens capsule⁹ or growth of the lens during aging.¹⁰ Lens hardening plays an important role, and so replacing the lens substance with a suitable soft material could restore accommodation.⁵ Lens-refilling surgery involves removal of the lens nucleus and cortex through a small capsular opening, followed by injection of a polymer to refill the capsular bag. This surgery could be performed when the lens has become cataractous and an indication for lens surgery arises. To investigate the accommodative ability of such a refilled lens in an in vivo experiment before human clinical trials, an animal that exhibits accommodation similar to human accommodation has to be used. Among primates, the rhesus monkey eye has been shown to have high accommodative amplitudes and an accommodative anatomy and mechanism similar to that of the human eye.^{11–13} The monkey also develops presbyopia with a relative age course similar to that of humans, culminating in a near complete loss of accommodation by the age of 25 to 30 years.¹⁴ Therefore, rhesus monkeys are a suitable animal model for studies of accommodation, presbyopia, and lens-refilling experiments. Ultimately, the goal of such experiments is to determine whether accommodation can be restored to presbyopic monkeys and then to humans. However, no surgical method exists to remove a hardened presbyopic lens through a small capsular opening. Also, presbyopic monkeys are scarce. Therefore, in an initial effort to establish whether natural accommodation can be restored with polymer refilling of the capsule in normal eyes with normal accommodative amplitudes, adolescent monkeys have been used. To demonstrate normal function of the accommodative apparatus, the preoperative accommodative amplitude of the rhesus monkey should be known. Then surgery could be performed, and postoperative accommodation could be measured as a refractive change of the eye by a refractometer. This type of optical refractive measurement determines the primary outcome variable (i.e., an accommodative optical change in the power of the eye). The optical refractive measurement also provides some indication of the overall optical quality or clarity of the refilled eye by virtue of the ability to measure (or not) the optical refractive change. Other changes in the anterior seg-

From the ¹Department of Ophthalmology and ⁴Institute for Biomedical Engineering, Materials Science, and Application and the ⁵Laboratory of Experimental Ophthalmology, University Medical Center Groningen, University of Groningen, Groningen, The Netherlands; ²Advanced Medical Optics Groningen BV, Groningen, the Netherlands; and the ³College of Optometry, University of Houston, Houston, Texas.

Submitted for publication October 13, 2005; revised January 23, 2006; accepted May 3, 2006.

Disclosure: **S.A. Koopmans**, Advanced Medical Optics Groningen BV (C); **T. Terwee**, Advanced Medical Optics Groningen BV (E); **A. Glasser**, Advanced Medical Optics Groningen BV (C); **M. Wendt**, None; **A.S. Vilipuru**, None; **T.G. van Kooten**, Advanced Medical Optics Groningen BV (C); **S. Norrby**, Advanced Medical Optics Groningen BV (E); **H.J. Haitjema**, Advanced Medical Optics Groningen BV (E); **A.C. Kooijman**, None

The publication costs of this article were defrayed in part by page charge payment. This article must therefore be marked “advertisement” in accordance with 18 U.S.C. §1734 solely to indicate this fact.

Corresponding author: Steven A. Koopmans, Department of Ophthalmology, University, Medical Center Groningen, PO Box 30001, 9700 RB Groningen, The Netherlands; s.a.koopmans@ohk.azg.nl.

ment, such as an accommodative change in anterior chamber depth or lens thickness can support the refraction measurements but give no information on quality nor clarity of the optics of the refilled eye. Because the surgery is intended to restore accommodation permanently, accommodation should be measurable for as long after surgery as possible.

In the past, experiments have been described in monkeys in which the lens nucleus and cortex were removed and the capsular bag was refilled with a silicone material.¹⁵⁻¹⁹ The success of these procedures as determined by the ability to measure refraction in the eyes varied because of inflammation and the development of capsular opacification.

We have developed a capsular bag-refilling polymer that has been used for experiments in ex vivo human eyes.⁵ The refractive index of this material is similar to the equivalent refractive index of the human lens²⁰ and the Young's modulus is similar to that of a 20-year-old human lens.²¹ Accommodative changes could be measured in human lens capsules refilled with this material, whereas similar aged presbyopic natural lenses did not show accommodative changes.⁵ The material has also been implanted in rabbit eyes and was well tolerated (Koopmans SA, unpublished observation, 2003).

In this study, we tested the lens-refilling material in vivo in adolescent rhesus monkeys. After implantation in a first group of four monkeys (group A) anterior chamber inflammation and early capsular opacification prevented refraction measurements in three of four monkeys. Therefore, changes were made to the intraoperative and postoperative treatment protocol to prevent postoperative inflammation and early capsular opacification. With this protocol, five additional lens-refilling experiments were performed in five monkeys (group B) and accommodative changes were measured in the postoperative period.

MATERIALS AND METHODS

Monkeys

The right eyes of four rhesus monkeys (*Macaca mulatta*, identified by numbers 49, 76, 91, and 118), referred to as group A, were used for the first experiments. A second group of four rhesus monkeys (identified by numbers 64, 109, 112, and 114), referred to as group B, was used for a second series of experiments. In group B, the left eye was used. At another institution, a fifth monkey (N33) became available for lens refilling, and this monkey was added to group B. The treatment of this monkey is described separately below, as there were some differences in treatment. The data of all the monkeys are summarized in Table 1. The animals were approximately 5 years old and weighed between 4.8 and 7.5 kg. Seven monkeys were females, two were males. The monkeys were treated according to the ARVO Statement for the Use of Animals in Ophthalmic and Vision Research and in accordance with institutionally approved animal protocols. Six weeks before the lens-refilling surgeries the monkeys had undergone a complete iridectomy to prevent miosis and allow unobstructed refraction measurements during pharmacologically induced accommodation. It has been shown that a total iridectomy does not affect the accommodative response in rhesus monkeys.²² Assessment of maximum pharmacologically stimulated accommodation using carbachol iontophoresis²³ was performed after the iridectomy, 3 weeks before capsular refilling.

Surgical Anesthesia

Monkeys were initially anesthetized with intramuscular ketamine 10 mg/kg (Ketaset; Fort Dodge Animal Health, Fort Dodge, IA) and intramuscular acepromazine 0.5 mg/kg (Vedco, Inc., St. Joseph, MO). The monkeys were maintained at surgical depth anesthesia with constant intravenous perfusion of propofol (Propofol; Abbott Laboratories, North Chicago, IL), with an initial bolus of 1.5 mg/kg, followed by constant infusion at 0.5 mg/kg per minute. After the onset of anesthe-

TABLE 1. Monkey Data and Date of Surgery

Monkey No.	Sex (M/F)	Date of Birth (dd-mm-yy)	Weight (kg)	Date of Surgery (dd-mm-yy)	Animal Institution
Group A					
118	F	03-05-96		29-01-02	1
49	M	20-05-96		29-01-02	1
76	F	29-06-96		30-01-02	1
91	M	19-05-97		30-01-02	1
Group B					
112	F	22-04-99	7.0	08-03-04	1
114	F	19-04-99	5.3	08-03-04	1
64	F	13-06-99	4.9	10-05-04	1
109	F	23-06-99	5.8	11-05-04	1
N33	F	02-07-91	6.0	02-12-03	2

Treatment in group A: removal of lens substance, lens refilling, and two weekly subconjunctival injections of triamcinolon after surgery. Treatment in group B: removal of lens substance, sodium hyaluronate with actinomycin D and cycloheximide in capsular bag, lens refilling, two weekly subconjunctival injections of triamcinolon after surgery, and steroid eye drops 2 weeks after surgery.

sia, the monkey was placed in a head holder that allowed positioning with the face upward under an operating microscope (Opmi; Carl Zeiss Meditec, GmbH, Oberkochen, Germany) for surgical procedures. Additional corneal anesthesia was provided with proparacaine eye drops (0.5%).

Surgical Procedure

Excess eyebrow hair was trimmed with a hair clipper. The periocular region was swabbed with povidone iodine. The body of the monkey was covered with sterile drapes. The eyelids were held open with a wire eyelid speculum. A clear corneal tunnel incision was made using a 3.0-mm disposable keratome. The anterior chamber was filled with sodium hyaluronate (Healon GV; Pharmacia, Uppsala, Sweden). With a 27-gauge needle a small peripheral puncture of the anterior lens capsule was made approximately 2 to 3 mm from the lens equator. With Utrata forceps, an ~1.5 to 2.0 mm diameter circular capsulorrhexis was completed in the lens periphery.²⁴ A clear cornea paracentesis was created using a 15° knife, and an anterior chamber maintainer connected to an infusion bottle was inserted in the incision. Physiologic saline solution (BSS Plus; Alcon Laboratories, Fort Worth, TX) was used in all surgeries. Heparin 5000 IU and vancomycin 10 mg were added to every bottle of saline (500 mL).

The lens substance was removed by manual aspiration, by using a 20-gauge blunt cannula connected to a 10-mL syringe with a piece of polyethylene tubing. After removal of the lens substance, the anterior chamber was filled with sodium hyaluronate. A custom-made silicone membrane (U.S. patent application 2002/0107567) with a diameter of 2.7 mm (a capsular "plug"; Fig. 1) was inserted in the capsular bag through the capsulorrhexis. The empty capsular bag was filled with the polymer through the capsulorrhexis, beneath the plug by inserting a 25-gauge cannula into the bag and injecting the refill polymer until the capsular bag was judged by the surgeon to be completely filled. The cannula was retracted, and the plug was positioned to close the capsulorrhexis. The sodium hyaluronate was flushed out of the anterior chamber with the saline solution via the anterior chamber maintainer through the corneal incision. Finally, both incisions were sutured with a single 10-0 nylon suture, and the anterior chamber was reinflated with injected physiologic saline solution.

At the conclusion of surgery, in addition to intramuscular analgesics, all monkeys received flunixinam 1 mg/kg intramuscularly and a ~0.2 mL subconjunctival injection of triamcinolone 40 mg/mL.

Treatment of Capsular Bag

The monkeys in group B received a treatment of the capsular bag designed to prevent of capsular opacification. After removal of the

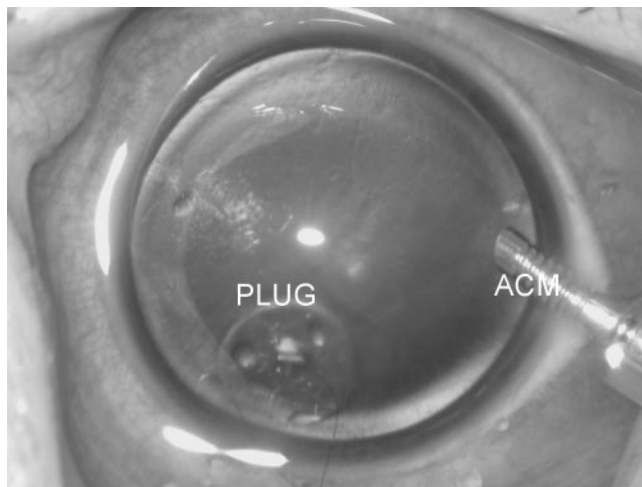


FIGURE 1. Refilled monkey lens just after refilling of the capsular bag. The anterior chamber maintainer (ACM) is visible in the corneal paracentesis. The plug closing the capsulorrhexis is visible at the lens periphery.

natural lens, the anterior chamber maintainer was removed, and the anterior chamber was filled with sodium hyaluronate (Healon 5; Pharmacia). A 1% sodium hyaluronate solution with cycloheximide 25 $\mu\text{g}/\text{mL}$ and actinomycin D 10 $\mu\text{g}/\text{mL}$ in demineralized water had been found effective for delaying the development of capsular opacification (van Kooten TG, personal communication, 2003). This was injected in the monkey capsular bag and left in place for 5 minutes in an effort to lyse or kill the remaining lens epithelial cells and to prevent the early development of postoperative capsular opacification. After this, the anterior chamber maintainer was inserted in the corneal incision again, and the viscoelastic material was aspirated from the eye, starting with the sodium hyaluronate solution in the capsular bag. The inner anterior and posterior central capsular bag surfaces were polished with a Kratz capsule polisher (BD Visitec, Franklin Lakes, NJ) as well as possible without risking capsular rupture.

Postoperative Treatment and Examinations

Postoperative examinations were performed at 1 and 2 weeks and 1, 2, 3, 6, and 9 months after surgery in all monkeys using the same anesthesia protocol as described for the surgery. At the first postoperative examination at 1 week, the corneal sutures were removed, and a second subconjunctival injection of triamcinolone was given. For this procedure the monkeys were anesthetized with ketamine and acepromazine.

During the 14-day postoperative period, the monkeys in group B received dexamethasone 0.1% and gentamicin 0.3% eye drops three times daily. These drops were administered by briefly placing the monkey in a restraint chair and administering the drops manually with the dropper bottles. After the drops were administered, an orange juice and candy reward was given. At the second postoperative examination at 2 weeks and at all subsequent examinations, refraction and the pharmacologically stimulated accommodative response were measured. If refraction measurements were not possible because of media opacities, pharmacological stimulated accommodation measurements were not performed, and follow-up examinations were modified according to clinical judgment. During postoperative slit-lamp examinations measurements were recorded on videotape or photographed through a photographic attachment to the slit lamp and refractometer.

Refraction and Accommodation Measurements

A Hartinger coincidence refractometer (Carl Zeiss Meditec; Fig. 2) was used to measure the refractive state of the eye. This instrument measures the refraction in a small pupillary area (2–3 mm), and it requires manual adjustment of two sets of three vertical vernier lines which are reflected off the retina. The visibility of the vernier lines depends on the optical quality of the eye. The refraction measurements were first recorded without a contact lens on the cornea and then with a rigid, gas-permeable contact lens on the cornea. The contact lens was necessary to maintain corneal hydration and optical clarity over the long duration of the pharmacological stimulation experiments, as the eyelids were retracted with lid specula. Three to five measurements were recorded at each time point along the same horizontal meridian, and the refractometer was repositioned after each measurement. The mean of the three to five measurements at each time point represented the

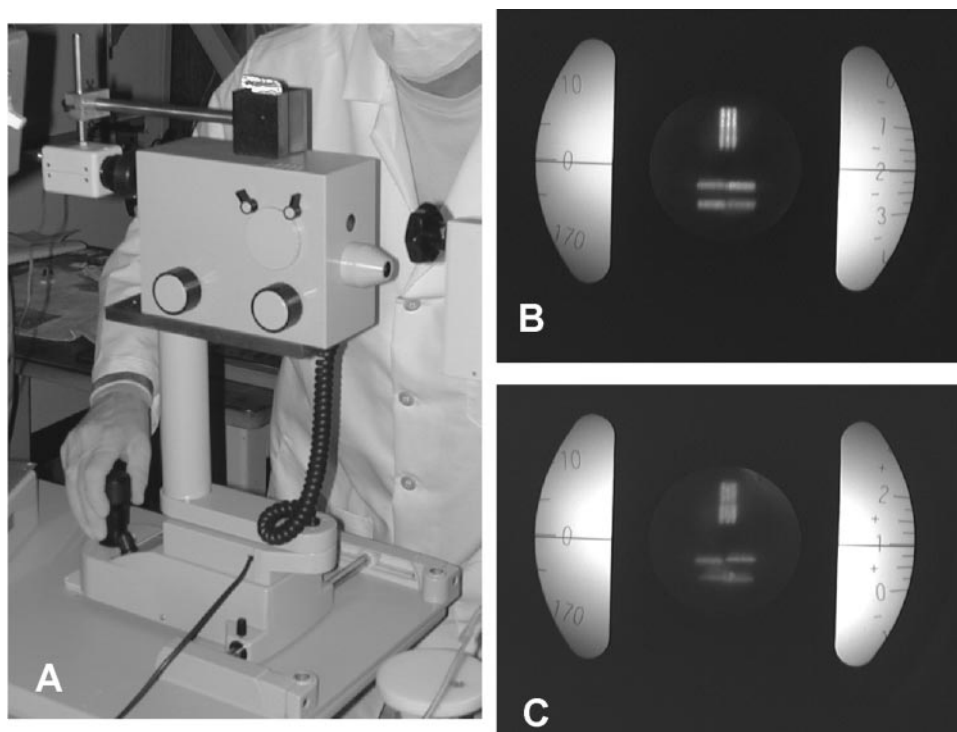


FIGURE 2. (A) Hartinger coincidence refractometer. A charge-coupled device (CCD) camera is mounted in front of the eyepiece. The cone on the right side of the equipment is placed in front of the eye under investigation. (B, C) View through the eyepiece of a Hartinger refractometer. On the *left* a scale is visible that indicates the axis in degrees on which the refraction is being measured. The examiner turns a knob on the outside of the equipment until the two sets of three lines are aligned. Then the refraction can be read from the *right* scale. (B) Image photographed through the eyepiece of the instrument when measuring a nonsurgical eye. (C) A similar image of a surgical eye 4 weeks after surgery. The visibility of the vernier lines depends on the optical quality of the eye.

refraction. At several postoperative examinations, the retinal image of the Hartinger vernier lines were photographed to document the optical quality of the eye's media (Fig. 2). To pharmacologically induce accommodation, carbachol chloride iontophoresis^{23,25} was used. For the carbachol iontophoresis, the monkeys were held in a head holder, prone, with the head upright and facing forward. An agar gel containing 40% carbachol (Sigma-Aldrich) was prepared in a microcentrifuge tube. One end of the microcentrifuge tube was cut and the gel pushed to protrude through the cut end. A 25-gauge needle was pushed through the tube so the needle went through the agar gel. A wire from the iontophoresis box was clipped to this needle to serve as the cathode. The anode was created by pushing a 25-gauge needle attached to another cable from the iontophoresis box through the skin of the animal's forehead. The contact lens was removed and the carbachol containing gel was touched to the cornea nasally and temporally for 4 seconds, each while passing a current of ~80–100 μ A through the gel via a 45-V battery in the iontophoresis box. The cornea was rinsed with sterile saline, the contact lens was replaced, and three refraction measurements were made every 2 minutes until at three consecutive intervals, no further increase in accommodation occurred. To ensure that maximum accommodation was achieved, the contact lens was removed, and the iontophoresis was repeated nasally and temporally. Then, the contact lens was replaced and the refraction measurements started again, until no further increase in accommodation was observed during three consecutive, 2-minute intervals. The accommodative amplitude was the average of the last three refraction results minus the baseline refraction. The standard deviation of the last three refractions was calculated for every postoperative examination per monkey. We assume that the standard deviation of the three final refraction assessments was similar to the standard deviation of the baseline refraction. The SD for the accommodative amplitude was calculated as $\sqrt{2(\sigma)^2}$, since it is the difference between two refraction readings with standard deviation σ .

Refilling Polymer

The refilling silicone polymer consisted of two components that were mixed together and prepared for injection, as was described before.⁵ After 70 minutes of cross-linking at 35°C, the material attains a Young's modulus of 0.8 kPa and remains stable at that value as measured with a rheometer. For comparison, the Young's modulus of a 20-year-old human lens is approximately 1 kPa and that of a 60-year-old lens is 5 to 10 kPa.^{21,26}

Additional Monkey

At a different institution, a lens-refilling experiment was performed on monkey N33, a 12-year-old female monkey weighing 6 kg. This monkey was also treated according to the ARVO Statement for the Use of Animals in Ophthalmic and Vision Research and an institutionally approved protocol. The monkey underwent a treatment similar to that of the other four monkeys in group B. Differences were that no preoperative assessment of the maximally induced pharmacological accommodative amplitude was performed. For surgical anesthesia the monkey was given intramuscular ketamine (10 mg/kg) and intubated. Deep anesthesia was achieved by inhalation of isoflurane (Isoflo; Abbott Laboratories Ltd., Maidenhead, UK). Additional corneal anesthesia was provided with oxybuprocaine 0.4% eye drops. For the postoperative treatment (twice daily) with dexamethasone and gentamicin eye drops, a squeeze cage was used to bring the monkey to the front of the cage and a squirt of 0.1 to 0.2 mL of medicine was delivered to the eye by means of a 2-mL syringe with a 10-cm-long blunt cannula, after which a food reward was given. For pharmacological stimulation of accommodation, pilocarpine 4% eye drops were used (as opposed to the carbachol iontophoresis). Only the left (surgical) eye was measured. The monkey was positioned supine on the operating table during the postoperative measurements. The eyelids were held open with a wire eyelid speculum. Baseline refraction was measured three to five times with a vertically mounted Hartinger refractometer, three

drops of pilocarpine 4% were applied to the cornea, and the eyelids were closed. After 5 minutes, the eyelids were manually opened for a second application of three drops of pilocarpine 4%. The eyelids were closed, and after 30 minutes a second refraction was obtained by measuring three to five times. The difference between the mean refraction before and after pilocarpine 4% represented the accommodative amplitude. In addition, lens thickness was measured with an ophthalmic ultrasound unit (A5500; Sonomed, Lake Success, NY) before and after pharmacological stimulation of accommodation. The ultrasound transducer was manually placed on the cornea after wetting with saline and its position was adjusted until maximum echographic signal peaks of the anterior and posterior lens surface were obtained. The A-scan image was saved. A cursor was positioned in front of the anterior and posterior lens peak and the ultrasound software calculated the lens thickness. For the refilled lenses, a sound velocity of 1066 m/s matching that for the polymer was used.⁵ Six measurements were obtained before and 35 minutes after pilocarpine stimulated accommodation.

RESULTS

During the surgeries, no complications occurred in any of the eyes. In group A, cells and fibrin developed in the anterior chamber of monkeys 49, 91, and 118 as seen by slit lamp examination in the first postoperative week. In an attempt to dissolve the fibrin, 0.25 mL of rtPA (1 mg/mL) was injected in the anterior chamber of these three monkeys by inserting a cannula through the paracentesis. Slit lamp examination at 2 and 4 weeks after surgery revealed that the cells and fibrin had disappeared from the anterior chamber, but opacities of the anterior lens capsule prevented refraction measurements. For this reason no more follow-up refraction measurements could be performed in monkeys 49, 91, and 118. Refraction and accommodation were measured 2 weeks after surgery in monkey 76. The refraction was -10.0 D, and the accommodative amplitude was 4 D. After this 2-week measurement, no further measurements could be performed due to the development of capsular opacification.

In group B no fibrin formation was seen in the anterior chamber. No cornea opacities or other side effects attributable to the cycloheximide and actinomycin D treatment were detected in the postoperative period. Measurements of the postoperative baseline refraction and accommodative amplitude were possible during the whole follow-up period in group B.

Preoperative Carbachol Iontophoresis

The time courses of the pre- and postoperative carbachol-induced accommodative amplitudes of four of the monkeys in group B are plotted in Figure 3. The time course of the response was slow and reached a plateau. In two preoperative carbachol experiments in monkey 109, the maximum induced accommodative amplitude in the left eye was much smaller (6 and 7.5 D) than the maximum induced preoperative amplitude in the other monkeys (12.5–15.8 D) and was smaller than the accommodative amplitude of the right eye (mean amplitude of all follow-up dates, 17 D), and so it is unlikely that maximum stimulation of the ciliary body was achieved in this preoperative test in the left eye of monkey 109.

Postoperative Measurements

The measurements of the postoperative baseline refraction and accommodative amplitude started 2 weeks after the capsule refilling.

Figure 3 shows the time course of the carbachol-induced accommodative amplitude of each refilled monkey eye from group B at the postoperative time when maximum accommodation was achieved. The time course of the postoperative

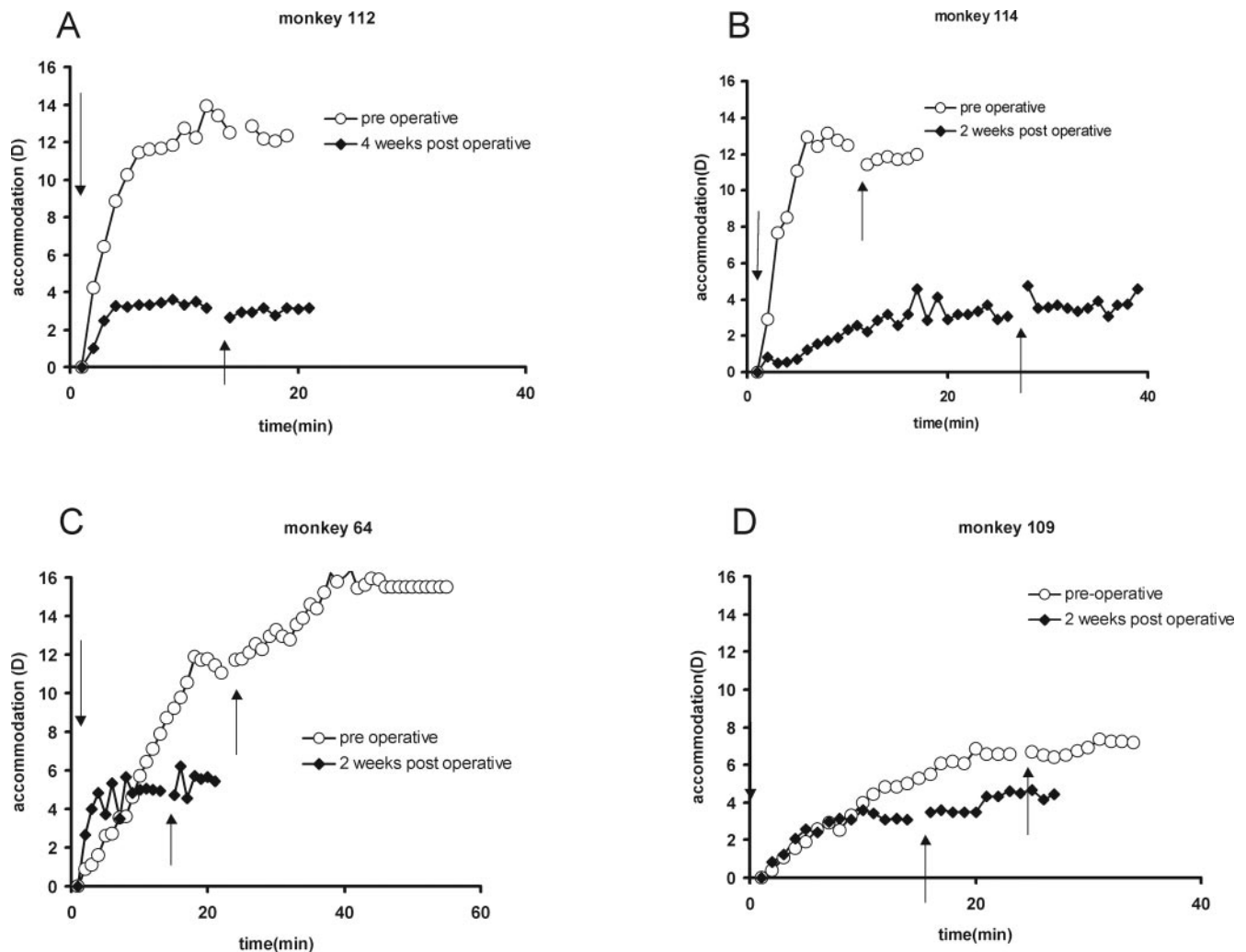


FIGURE 3. Pre- and postoperative carbachol-induced accommodation for four monkeys in group B: (A) 112, (B) 114, (C) 64, and (D) 109. The preoperative accommodative amplitude was measured 3 weeks after the total iridectomy and 3 weeks before surgery. The postoperative measurements shown are those at the follow-up time when the postoperative accommodative amplitude was at its maximum. Carbachol was applied iontophoretically to the temporal and nasal cornea for 4 seconds each (*down arrows*). Refraction was then measured three times at 2-minute intervals with a Hartinger coincidence refractometer. Accommodation is the difference between the present refraction and the refraction at the start of the experiment. Once the accommodation did not increase for three successive 2-minute periods, carbachol was again iontophoretically applied for a further 4 seconds (*up arrows*). Refraction was again measured until no further increase of accommodation occurred at three successive measurements. The preoperative accommodative amplitude in monkey 109 is unlikely to be the maximum accommodative amplitude in this monkey.

response is similar to the preoperative response, but the amplitude was lower in all monkeys. In monkey 114, the plateau was reached after 30 minutes. In the other monkeys it was reached earlier.

Figure 4 shows the maximum pharmacologically induced accommodative amplitude in the refilled eyes and in four of the nonsurgical, iridectomized, normal eyes from group B, as measured at each postoperative examination. The standard deviation of the accommodative amplitude varied between 0.16 and 0.88 D. A decline in the accommodative amplitude with time is seen in the refilled eyes of monkeys 112, 114, and N33. Their accommodative amplitudes were 0.5, 0.75, and 1.25 D respectively at the last follow-up date, whereas the accommodative amplitudes in monkeys 109 and 64 were 3.9 and 4.7 D at the last follow-up date.

The postoperative baseline refraction of the refilled eyes from group B (before stimulation of accommodation with carbachol) compared to its preoperative refraction is shown in Figure 5. The maximum difference between the preoperative

refraction and the mean postoperative refraction of all follow-up dates was 2.5 D. In the refilled eyes, the maximum range of variability of the baseline refraction in the postoperative period was 5.6 D. The maximum range of variability in the nonsurgical, right eyes was 2.6 D.

In monkey N33, lens thickness was measured before and after stimulation with pilocarpine eye drops. The SD of a lens thickness measurement varied between 0.02 and 0.06 mm. The change in lens thickness versus the amount of accommodation at different follow-up dates is plotted in Figure 6. The slope of a fitted linear regression line indicates a lens thickness change of 0.05 mm/D.

Slit lamp inspection revealed a gradual increase in capsular opacification during the follow-up period in group B. It predominantly affected the mid periphery of the anterior lens capsule and would have been covered by the iris in photopic circumstances if no iridectomy had been performed. The opacification was comparable to the fibrous type of opacification of the lens capsule, as seen several months after regular

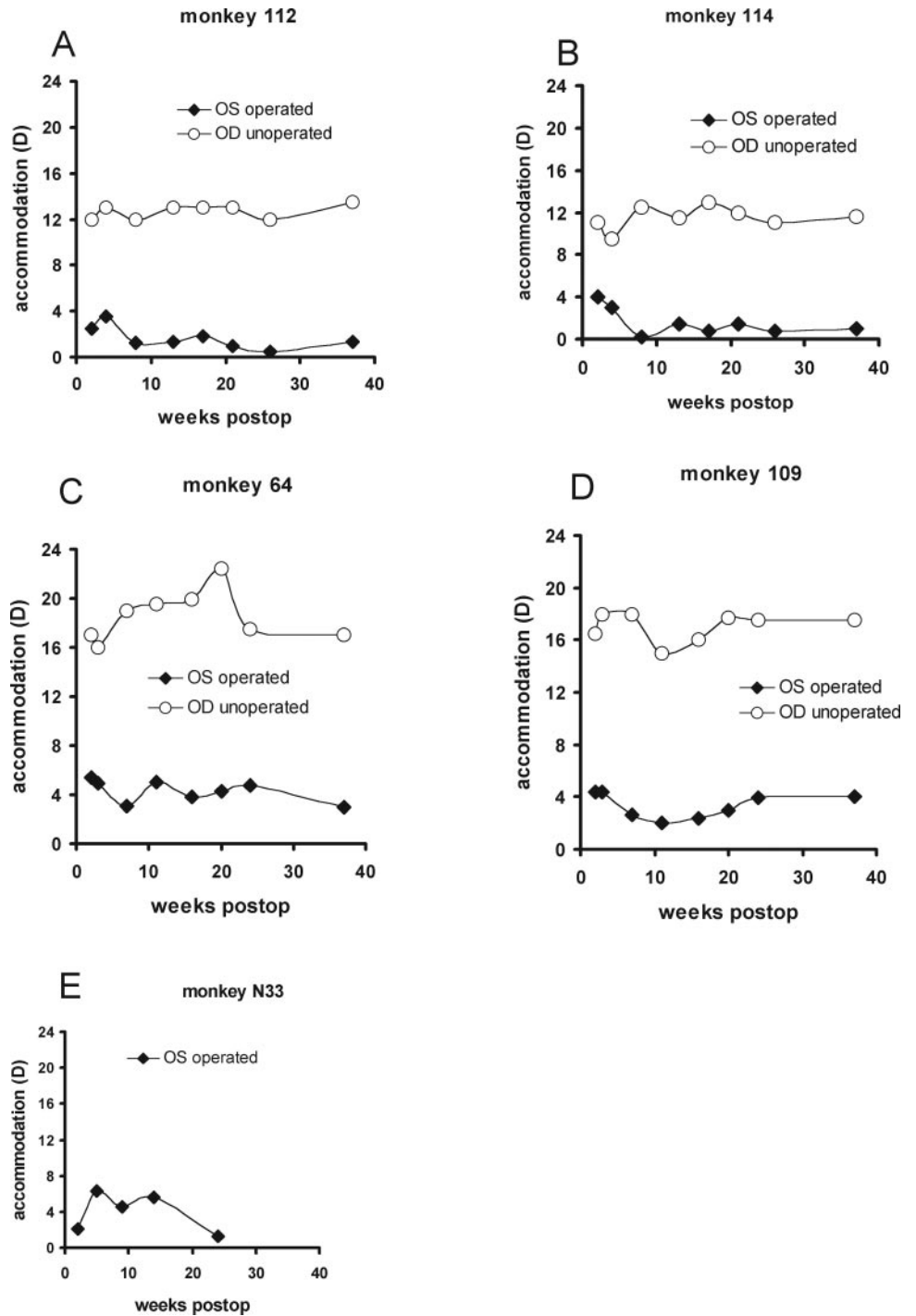


FIGURE 4. Maximum pharmacologically induced accommodative amplitude of the left (surgical) eye and of the right (nonsurgical) eye in the postoperative period in the five monkeys in group B: (A) 112, (B) 114, (C) 64, (D) 109, and (E) N33. Standard deviations of the accommodative amplitude measurements are smaller than the symbol size. In monkey N33 only the left (surgical) eye was measured.

intraocular lens implantation in humans. Capsular opacification was not quantified in a standardized manner. Centrally, changes in clarity of the capsule also occurred, which were associated with a decrease in the quality of the line images as visible in the Hartinger refractometer, indicating a reduction in optical quality of the central part of the lens during the follow-up. Despite this, refraction measurements remained possible during the whole follow-up period.

DISCUSSION

This study primarily shows that, after removal of the lens nucleus and cortex, accommodation can be restored in adoles-

cent rhesus monkeys by refilling the capsular bag with a silicone-based polymer and a plug to close the capsulorrhexis. In all the five monkeys in group B, accommodation could be measured by a refractometer as a refractive change of the eye during the 6-month follow-up period. This indicates sufficient clarity of the eye's media during this period. In one monkey (N33), lens thickness changes were documented together with the refractive changes, demonstrating that the lens power change is associated with an increase in lens thickness, which is in accordance with the Helmholtz theory of accommodation.

In a previous monkey study, Nishi et al.¹⁵ used an endocapsular balloon that was placed in the capsular bag and subsequently filled with silicone oil through a filling tube connected

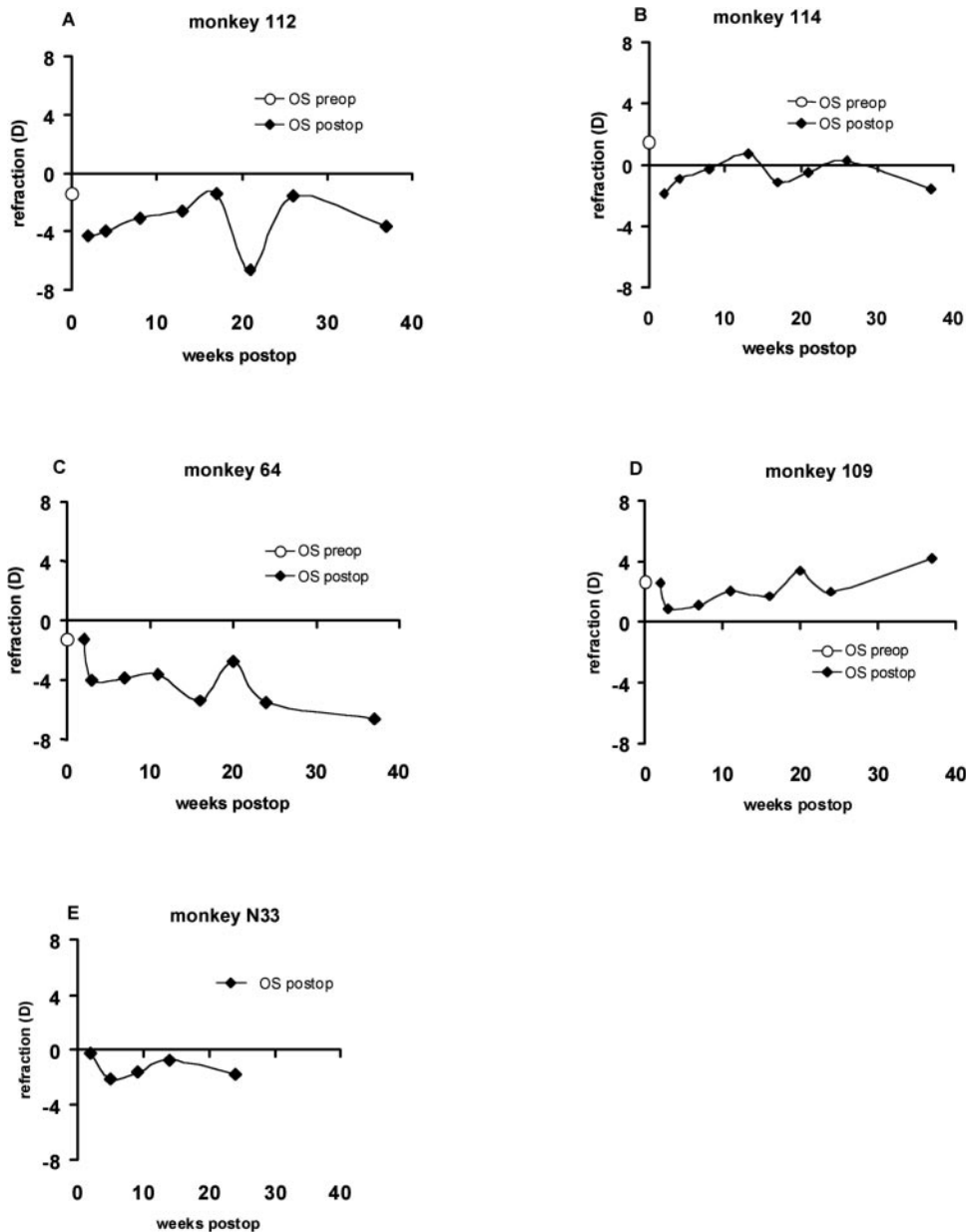


FIGURE 5. (A–E) Pre- and postoperative baseline refraction of the left eyes of monkeys in group B as measured before pharmacological stimulation of accommodation: (A) 112, (B) 114, (C) 64, (D) 109, and (E) N33.

to the balloon. To prevent leaking of the silicone material after refilling, the tube was occluded with a cured silicone polymer and cut. With this technique they also achieved accommodation that was measurable with a refractometer during 6 to 12 months. Because of the technical complexity of the surgical procedure,¹⁸ they abandoned the technique involving an intracapsular balloon. When Nishi and Nishi¹⁸ performed experiments without the use of an endocapsular balloon and closed the capsulorrhexis with a capsular plug, refraction could only be measured 1 week after surgery. After this, refraction measurements were impossible due to capsular opacification. Haefliger et al.¹⁶ also performed lens-refilling experiments in monkeys in which the rhexis in the capsular bag was not plugged but leaking was prevented by the use of a highly viscous, precured silicone that stayed in the bag by cohesion. They were unable to measure refraction due to early postoperative capsular opacification. The accommodative response was measured indirectly in these monkeys by demonstrating a decrease in the anterior chamber depth by optical pachymetry after an intracameral injection of pilocarpine. Beside capsular

opacification, both Haefliger et al.¹⁶ and Nishi and Nishi¹⁸ reported postoperative inflammation in their monkeys that caused media opacities and made refraction measurements impossible in some of them. This is similar to the outcomes of the monkeys in group A. After we used daily local steroid therapy for 2 weeks in group B (as is routinely done in human clinical practice after intraocular surgical procedures) and treatment of the capsular bag with cycloheximide/actinomycin D, refraction measurements were possible for a longer period, and no fibrinous exudates or other inflammatory complications occurred directly after surgery.

The rhesus monkeys used for the lens-refilling experiments were 5 and 12 years old, which is comparable to 17 and 27 human years.¹⁴ Around the age of 20 years, human accommodative amplitude is almost at its maximum. The postoperative accommodative amplitude in the refilled eyes of the adolescent monkeys in this study was a maximum of 40% (~6 D) of the original accommodative amplitude (mean of three monkeys, 16 D).

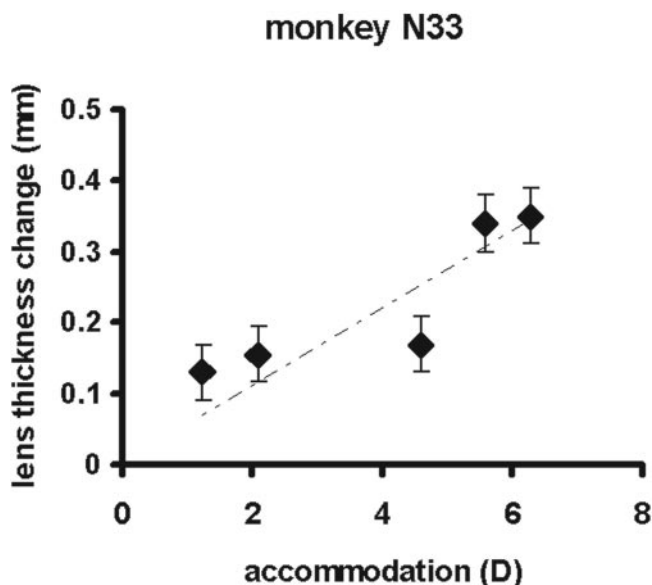


FIGURE 6. Lens thickness change measured with A-scan after pilocarpine stimulated accommodation at several dates during the follow-up period. A linear regression line was fitted through the data points. The slope of the regression line amounts to 0.05 mm/D. Error bars, SD.

This effect could be caused by multiple factors. The adhesion between the lens capsule and the natural lens is lost in the refilled lens. Such a reduced adhesion could result in a less efficient transmission of the capsular forces that mold the lens contents during accommodation. A second cause of the reduction of the accommodative amplitude of a refilled lens is loss of so-called intracapsular accommodation. During accommodation an increase of the equivalent refractive index of the lens occurs,²⁷ which was called intracapsular accommodation by Gullstrand.²⁸ This increase in equivalent refractive index cannot occur in a refilled lens. According to Nishi et al.²⁹ overfilling of the capsular bag also causes a reduction in accommodative amplitude, which could explain the difference in accommodative amplitude between monkeys 112 and 114 and monkeys 64 and 109. The postoperative refraction of monkeys 112 and 114 was more myopic than their preoperative refraction, indicating a higher lens power due to overfilling. Monkeys 64 and 109 showed a more similar pre- and postoperative refraction, indicating a lower degree of filling. More observations relating accommodative amplitude to the amount of filling are necessary to prove such a relationship.

An accommodative amplitude of approximately 3 to 4 D in presbyopic human eyes would be sufficient for reading purposes, and the surgical procedure used in this study could be considered successful in terms of restoring functional accommodative amplitude based on the maximum accommodation as obtained in these monkeys. However, the accommodative amplitudes were obtained in young monkey eyes using a supra-maximum²⁵ pharmacological stimulus (carbachol). It is unknown what accommodative amplitude can be obtained in presbyopic monkey eyes after lens refilling. Haefliger and Parel¹⁹ performed an experiment in monkeys of uncertain ages, but that were at least 17 years old (34 human years¹⁴). The monkeys underwent lens refilling and showed accommodative changes after surgery, but in their study, accommodation was measured indirectly as a decrease in anterior chamber depth. More experiments are needed to confirm this finding and to measure accommodative amplitude in diopters.

In two of the five monkeys in group B the accommodative amplitude remained stable for 6 months, whereas, in the other

three monkeys, the initial accommodative amplitude gradually decreased to close to 0 D. Decreasing elasticity of the lens capsule as a result of capsular opacification could be the cause of the decrease in accommodative amplitude. However, we did not detect significant individual differences in the amount of capsular opacification between the monkeys as judged by slit-lamp examination.

In the five monkeys in group B the capsular bag was treated with a sodium hyaluronate solution containing cycloheximide and actinomycin D to delay the development of capsular opacification. Refraction could be measured in all monkeys in group B, in contrast with three monkeys in group A. Refraction could be measured during a much longer follow-up period than in earlier studies^{16,18} in which a similar lens refilling technique was used. This could be an indication that the perioperative treatment in conjunction with the postoperative treatments delayed the development of capsular opacification.

Carbachol iontophoresis was used to stimulate accommodation in four monkeys. The accommodative response which is obtained with this drug depends on the amount of drug delivered to the ciliary body. We obtained an unexpected low preoperative accommodative amplitude in monkey 109. This was caused by the fact that carbachol was erroneously applied to the bulbar conjunctiva rather than the cornea. After this fact was recognized and corrected, no further unexpected low amplitudes were measured.

Pilocarpine 4% eye drops, which were used in one monkey, resulted in accommodative amplitudes similar to those obtained with carbachol iontophoresis.

During refilling of the monkey lens capsule, no intraoperative measurements were performed to determine the amount of filling of the capsular bag or the refractive power of the lens. As a result, there was approximate emmetropia in one monkey (114), hyperopia in one monkey (109), and myopia in four monkeys (64, 76, 112, and N33). In a clinical situation, this outcome would be unacceptable; thus, there is a need for a method to determine the induced refractive power or the amount of material that has to be injected into the capsular bag. The monkeys operated on by Nishi and Nishi¹⁸ were all hypermetropic (more than +5 D). We used a refill material with a higher refractive index (1.428 in our study; 1.405 in theirs) but we did not inject a fixed amount of refilling material in the capsular bag as they did. The fact that in our study four monkeys were myopic and one was hypermetropic is probably due to both over- and underfilling.

Generally speaking, a stable refractive outcome is mandatory after lens implantation. The refilled eyes in group B showed variations in the baseline refraction during the follow-up period of 37 weeks. Part of the variability is caused by variation in accommodative tone or different levels of anesthetic during the follow-up experiments, because also the nonsurgical right eyes in group B show variability in refraction of maximally 2.6 D. The changes in refraction of the refilled eyes seem to be largest at weeks 2 and 21. However, there was no specific change in experimental procedures on those days. Furthermore, the date of week 2 and 21 was not similar for each monkey. Changes in refraction after regular human cataract surgery are largest in the early postoperative period.³⁰ They are due to changes in the anteroposterior position of the intraocular lens. Similar changes could offer an explanation for the changes in baseline refraction in week 2 in monkeys 64 and 109. Temporary hypotony of the eye due to postoperative inflammation could have caused changes in lens position. Local inhomogeneities in the refilled lens created during injection of the refill material or due to the development of local capsular opacification in the postoperative period could have caused variability in the baseline refraction measurement in monkeys 112 and 64 at week 21.

Linear regression on the lens thickness changes as determined with A-scan ultrasound with the accommodative amplitude as measured at different follow-up dates indicated that lens thickness increased by 0.05 mm/D during accommodation. This is comparable with the value of 0.063 mm/D found by Vilipuru and Glasser³¹ in natural monkey lenses during accommodation stimulated by an electrode in the Edinger-Westphal nucleus. However, we used lower resolution ultrasound equipment compared with their study and the measurements were performed over a follow-up period of 37 weeks using a stimulus (pilocarpine drops) that has not been validated to provide a similar response at each follow-up date.

In summary, we showed that refilling the lens capsular bag with this silicone polymer and with this treatment of the capsular bag a certain level of accommodation was restored in adolescent rhesus monkeys. There were no complications during surgery or in the follow-up period of 37 weeks. Refraction and accommodation were measurable with a refractometer in eyes that underwent the capsular opacification and inflammation prevention protocol, indicating a reasonable optical quality of the refilled lens. Refractometer measurements of accommodation were accompanied by lens thickness changes, as shown in one animal. The treatment of the capsular bag did not induce clinically noticeable side effects and may have contributed to a delay in the occurrence of postoperative capsular opacification.

References

- Von Helmholtz H. Ueber die Akkommodation des Auges. *Albrecht von Graefes Arch Klin Ophthalmol*. 1855;1:1-74.
- Duane A. Studies in monocular and binocular accommodation with their clinical applications. *Am J Ophthalmol*. 1922;5:867-877.
- Glasser A, Campbell MCW. Presbyopia and the optical changes in the human crystalline lens with age. *Vision Res*. 1998;38:209-229.
- Soergel F, Meyer C, Eckert G, et al. Spectral analysis of viscoelasticity of the human lens. *J Refract Surg*. 1999;15:714-716.
- Koopmans SA, Terwee T, Barkhof J, Haitjema H, Kooijman AC. Polymer refilling of presbyopic human lenses in vitro restores the ability to undergo accommodative changes. *Invest Ophthalmol Vis Sci*. 2003;44:250-257.
- Neider MW, Crawford K, Kaufman PL, et al. In vivo videography of the rhesus monkey accommodative apparatus. Age-related loss of ciliary muscle response to central stimulation. *Arch Ophthalmol*. 1990;108:69-74.
- Friberg TR, Lace JW. A comparison of the elastic properties of human choroid and sclera. *Exp Eye Res*. 1988;47:429-436.
- Ramrattan RS, van der Schaft TL, Mooy CM, et al. Morphometric analysis of Bruch's membrane, the choriocapillaris, and the choroid in aging. *Invest Ophthalmol Vis Sci*. 1994;35:2857-2864.
- Fisher RF. Presbyopia and the changes with age in the human crystalline lens. *J Physiol (Lond)*. 1973;228:765-779.
- Bito LZ, Miranda OC. Accommodation and presbyopia. In: Reinicke RD, ed. *Ophthalmology Annual*. New York: Raven Press; 1989:103-128.
- Glasser A, Kaufman PL. The mechanism of accommodation in primates. *Ophthalmology*. 1999;106:863-872.
- Rohen JW. Scanning electron microscopic studies of the zonular apparatus in human and monkey eyes. *Invest Ophthalmol Vis Sci*. 1979;18:133-144.
- Bito LZ, DeRousseau CJ, Kaufmann PL, et al. Age dependent loss of accommodative amplitude in rhesus monkeys: an animal model for presbyopia. *Invest Ophthalmol Vis Sci*. 1982;23:23-31.
- Kaufman PL, Bito LZ, DeRousseau CJ. The development of presbyopia in primates. *Trans Ophthalmol Soc UK*. 1982;102:323-326.
- Nishi O, Nakai Y, Yamada Y, et al. Amplitudes of accommodation of primate lenses refilled with two types of inflatable endocapsular balloons. *Arch Ophthalmol*. 1993;111:1677-1684.
- Haefliger E, Parel JM, Fantes F, et al. Accommodation of an endocapsular silicone lens (phaco-ersatz) in the nonhuman primate. *Ophthalmology*. 1987;94:471-477.
- Sakka Y, Hara T, Yamada Y, et al. Accommodation in primate eyes after implantation of refilled endocapsular balloon. *Am J Ophthalmol*. 1996;121:210-212.
- Nishi O, Nishi K. Accommodation amplitude after lens refilling with injectable silicone by sealing the capsule with a plug in primates. *Arch Ophthalmol*. 1998;116:1358-1361.
- Haefliger E, Parel JM. Accommodation of an endocapsular silicone lens (phaco-ersatz) in the aging rhesus monkey. *J Refract Corneal Surg*. 1994;10:550-555.
- Dubbelman M, van der Heijde GL. The shape of the aging human lens: curvature, equivalent refractive index and the lens paradox. *Vision Res*. 2001;41:1867-1877.
- Weeber HA, Eckert G, Soergel F, et al. Dynamic mechanical properties of human lenses. *Exp Eye Res*. 2005;80:425-434.
- Kaufman PL, Lütjen-Drecoll E. Total iridectomy in the primate in vivo: surgical technique and postoperative anatomy. *Invest Ophthalmol Vis Sci*. 1975;14:766-771.
- Vilipuru AS, Glasser A. Dynamic accommodation in rhesus monkeys. *Vision Res*. 2002;42:125-141.
- Tahi H, Fantes F, Hamoui M, et al. Small peripheral anterior continuous curvilinear capsulorhexis. *J Cataract Refract Surg*. 1999;25:744-747.
- Koretz JF, Bertasso AM, Neider MW, et al. Slit-lamp studies of the rhesus monkey eye II. Changes in crystalline lens shape, thickness and position during accommodation and aging. *Exp Eye Res*. 1987;45:317-326.
- Fisher RF. The elastic constants of the human lens. *J Physiol (Lond)*. 1971;212:147-180.
- Dubbelman M, Van der Heijde GL, Weeber HA. Change in shape of the aging human crystalline lens with accommodation. *Vision Res*. 2005;45:117-132.
- Gullstrand A. How I found the intracapsular mechanism of accommodation. In: Santesson CG, ed. *Les Prix Nobel en 1911*. Stockholm: Nobel Foundation; 1912:414-431.
- Nishi O, Nishi K, Mano C, et al. Controlling the capsular shape in lens refilling. *Arch Ophthalmol*. 1997;115:507-510.
- Petternel V, Menapace R, Findl O, et al. Effect of optic edge design and haptic angulation on postoperative intraocular lens position change. *J Cataract Refract Surg*. 2004;30:52-57.
- Vilipuru AS, Glasser A. The relationship between refractive and biometric changes during Edinger-Westphal stimulated accommodation in rhesus monkeys. *Exp Eye Res*. 2005;80:349-360.