

Optic Disc Measurements in Myopia with Optical Coherence Tomography and Confocal Scanning Laser Ophthalmoscopy

Christopher Kai-shun Leung, Arthur Chak Kwan Cheng, Kelvin Kam Lung Chong, King Sai Leung, Shabeeda Mohamed, Charles Sing Lok Lau, Carol Yim Lui Cheung, Geoffrey Chin-hung Chu, Ricky Yiu Kwong Lai, Calvin Chi Pui Pang, and Dennis Shun Chiu Lam

PURPOSE. To evaluate the relationships between optic disc measurements, obtained by an optical coherence tomograph and a confocal scanning laser ophthalmoscope, and myopia.

METHODS. One hundred thirty-three eyes from 133 healthy subjects with mean spherical equivalent -6.0 ± 4.2 D (range, -13.13 to $+3.25$ D) were analyzed. Optic disc measurements including disc area, rim area, cup area, cup-to-disc area, and vertical and horizontal ratios were obtained with an optical coherence tomograph (StratusOCT; Carl Zeiss Meditec Inc., Dublin, CA) and a confocal scanning laser ophthalmoscope (Heidelberg Retina Tomograph, HRT 3; Heidelberg Engineering, GmbH, Dossenheim, Germany). The modified axial length method derived from prior published work was used to correct the OCT measurements for ocular magnification. Bland-Altman plots were used to evaluate the agreement for each optic disc parameter. Associations between optic disc area and axial length/spherical equivalent were evaluated by linear regression analysis.

RESULTS. Disc area increased with the axial length/negative spherical equivalent in the HRT and the corrected OCT measurements although opposite directions of associations were found when the OCT measurements were not corrected for magnification. The difference of the corrected OCT and HRT disc area (corrected OCT disc area minus HRT disc area) was correlated with the axial length ($r = 0.195$, $P = 0.025$). When the ametropia was limited to -8.0 to $+4.0$ D, the correlations became insignificant in the HRT. Using the corrected OCT measurements, disc area, rim area, and cup area, cup-to-disc area, and cup-to-disc horizontal and vertical ratios were significantly larger than those measured by the HRT, with a span of 95% limits of agreement at 1.99, 1.33, and 1.86 mm² for the areas, 0.34, 0.53, and 0.58 for the ratios, respectively.

CONCLUSIONS. While optic disc area generally increased with the axial length and myopic refraction, the HRT measurements demonstrated that optic disc size was largely independent of

axial length and refractive error between -8 and $+4$ D. OCT may overestimate optic disc size in myopic eyes and results in poor agreement between the two instruments. (*Invest Ophthalmol Vis Sci.* 2007;48:3178–3183) DOI:10.1167/iov.06-1315

Measurement of the optic disc size has an important bearing on the evaluation of optic nerve diseases and anomalies. Accurate assessment of glaucomatous discs is very much dependent on the clinical judgment of the disc size, because the neuroretinal rim area is directly related to the disc area. The size of the disc may also be related to susceptibility to glaucoma. In the Blue Mountains Eye Study, larger optic disc size was found in patients with glaucoma.¹ Similarly, the Reykjavik Eye Study also reported larger disc size in patients with glaucoma.² In contrast, nonarteritic anterior ischemic optic neuropathy³ and optic disc drusen⁴ are more frequently found in small optic discs. In highly myopic eyes (< -8 D), the optic disc was found to be abnormally large whereas in highly hyperopic eyes it was abnormally small.^{5,6} Of note, in eyes with moderate refractive error (between -8 and $+4$ D), it has been suggested that the optic disc size is independent of refractive error.^{6,7} In a hospital-based study by Jonas⁶ on Caucasian eyes, it was concluded that optic disc size depends on refractive error only when it is beyond -8 D in myopic eyes and $+4$ D in hyperopic eyes. A recent population-based study on Chinese eyes, the Beijing Eye Study, confirmed the same conclusion, suggesting that the disc size is independent of refractive error within the range of -8 to $+4$ D.⁷ Nevertheless, there are other studies reporting that the optic disc size increased with myopia.^{8,9} The Rotterdam Study showed that for each diopter of increase toward myopia, the disc area increased by 1.6%.⁸ Measurements of optic disc size in previous studies were based on a fundus photograph. Planimetry, however, is limited by the fact that it is subjective and variable between observers. With the availability of the two modern optic disc imaging devices—the confocal scanning laser ophthalmoscope and the optical coherence tomograph—high reproducibility for optic disc measurements has been demonstrated.^{10–14} In this study, the relationships between the optic disc size and axial length/refractive error were examined with the HRT 3 and the StratusOCT. Optic disc parameters measured by these two instruments were also compared.

METHODS

Subjects

One hundred thirty-three healthy Chinese myopic subjects who met the inclusion criteria were recruited in this study. All subjects were recruited consecutively from October 2005 to June 2006, during routine eye examination at the University Eye Center, The Chinese Uni-

From the Department of Ophthalmology and Visual Sciences, The Chinese University of Hong Kong, Hong Kong, Peoples Republic of China.

Submitted for publication November 1, 2006; revised December 21, 2006, and March 8, 2007; accepted April 23, 2007.

Disclosure: C.K.-s. Leung, Heidelberg Engineering (R); A.C.K. Cheng, None; K.K.L. Chong, None; K.S. Leung, None; S. Mohamed, None; C.S.L. Lau, None; C.Y.L. Cheung, None; G.C.-h. Chu, None; R.Y.K. Lai, None; C.C.P. Pang, None; D.S.C. Lam, None

The publication costs of this article were defrayed in part by page charge payment. This article must therefore be marked "advertisement" in accordance with 18 U.S.C. §1734 solely to indicate this fact.

Corresponding author: Christopher Kai-shun Leung, Department of Ophthalmology and Visual Sciences, The Chinese University of Hong Kong, Hong Kong Eye Hospital, 147K Argyle Street, Kowloon, Hong Kong; tlims00@hotmail.com.

versity of Hong Kong. All subjects underwent a full ophthalmic examination including visual acuity, refraction, intraocular pressure measurement with Goldmann tonometry, dilated fundus examination with stereoscopic biomicroscopy of the optic nerve head under slit lamp, indirect ophthalmoscopy, refraction, and A-scan ultrasound biometry. Other than refractive error, all included eyes had no concurrent disease, and had best corrected visual acuity of at least 20/40. Subjects with clinical evidence of myopic macular degeneration, intraocular pressure higher than 21 mm Hg, visual field defects (described later) or a history of intraocular surgery, neurologic diseases, or diabetes were excluded. Because the HRT produces best image quality when the ametropia is between -12 and $+12$ D, only subjects with spherical error between -12.5 and $+12.5$ D were included. In one randomly selected eye, optical coherence tomography and confocal scanning ophthalmoscopy imaging were performed. The study was conducted in accordance with the ethical standards stated in the Declaration of Helsinki and was approved by the local clinical research ethics committee, with informed consent obtained.

Optical Coherence Tomography Imaging

Optical coherence tomography was performed with OCT version 3 (StratusOCT, Carl Zeiss Meditec Inc). Fast optic nerve head imaging was performed with six radially linear scans, each with 128 scan points, centered at the optic nerve head. The disc margin is automatically identified in the StratusOCT by detecting the top and inner edges of retinal pigment epithelium on each side of the optic disc. A line is then joined and measured as the disc diameter. The reference plane (the cup offset) was then determined by tracing a line parallel to the disc diameter with an anterior offset of $150 \mu\text{m}$. Region above the reference plane is defined as the rim and below as the cup. Data analyzed in each scan are used to compute the composite image measurements. Global measurements including disc area, cup area, rim area (disc area minus cup area), cup-to-disc area ratio, cup-to-disc horizontal ratio, and cup-to-disc vertical ratio were analyzed in this study. All the scans had a signal strength of at least 7.

Although one can input the eye's axial length and refractive correction in the StratusOCT, it has no impact on the analyzed optic disc measurements. The default axial length and refraction in every OCT scan are set to 24.46 mm and 0 D, respectively, for the optic disc measurement. Therefore the actual disc size in an eye with axial length longer than 24.46 mm and/or refraction <0 D would be larger than the printout values and vice versa. The relationship between the measurement of the OCT image and the size of the actual fundus dimension can be expressed as $t = p \cdot q \cdot s$,¹⁵ where t is the actual fundus dimension, s is the measurement on OCT, p is the magnification factor related to the camera of the imaging system, and q is the magnification factor related to the eye. The correction factor q can be determined with the formula $q = 0.01306(x - 1.82)$, where x is the axial length¹⁶; p is a constant in a telecentric system. In OCT, the magnification factor in an eye with axial length 24.46 mm is 1 (i.e., $t = s$). Substituting $t = s$ into the formula $t = p \cdot q \cdot s$, we arrive at $p = 1/q$ and therefore, p can be calculated as $1/[0.01306(24.46 - 1.82)] = 3.382$. Because $t = p \cdot q \cdot s$ refers to linear magnification, the equation should be modified to $t^2 = p^2 \cdot q^2 \cdot s^2$ for area magnification. Therefore, values obtained from the StratusOCT optic nerve head analysis printout should be corrected by the factor $3.382^2 \cdot 0.01306^2 \cdot (x - 1.82)^2$ where x represents the axial length.

Confocal Scanning Laser Ophthalmoscopy Imaging

Confocal scanning laser ophthalmoscopy was performed with the HRT 3 (Heidelberg Retina Tomograph III [HRT 3]; Heidelberg Engineering, GmbH, Dossenheim, Germany). A three-dimensional topographic image consisting of $384 \times 384 \times 16$ up to $384 \times 384 \times 64$ pixels is constructed from multiple focal planes axially along the optic nerve head. An average of three consecutive scans is obtained and aligned to compose a single mean topography for analysis. Images obtained in

this study were reviewed carefully for imaging score and overall quality score. These image-quality checks are generated by the HRT 3 software (Heidelberg Eye Explorer, ver. 1.5.1.0; Heidelberg Engineering, GmbH). Images were selected for analyses only when each of these checks was rated as good or better and with an average pixel height standard deviation of $30 \mu\text{m}$ or less. Once the contour line is drawn, the software automatically calculates all the optic disc measurements. The reference plane is defined at $50 \mu\text{m}$ posterior to the mean retinal height between 350° and 356° along the contour line. Area above the reference is defined as the rim and below as the cup.

Visual Field Testing

Standard visual field testing was performed with the static automated white-on-white threshold perimetry (Humphrey Field Analyzer II, Carl Zeiss Meditec, Inc.). A visual field was defined as reliable when fixation losses and false-positive and -negative rates were $<25\%$. A visual field defect was defined as having three or more significant ($P < 0.05$) nonedge contiguous points with at least one at $P < 0.01$ on the same side of the horizontal meridian in the pattern deviation plot and classified as outside normal limits in the glaucoma hemifield test. Visual field perimetry was performed to ensure that all the eyes included were normal and demonstrated no glaucomatous damage.

Statistical Analysis

Statistical analyses were performed with commercial software (SPSS ver. 11.0; SPSS Inc, Chicago, IL). The associations between the optic disc measurements and the axial length/refractive error were calculated with linear regression analysis. The HRT and OCT measurements were compared with paired t -test. Bland-Altman¹⁷ plots were used to assess the agreements between the HRT and OCT optic disc parameters. $P < 0.05$ was considered statistically significant.

RESULTS

One hundred thirty-three normal eyes (133 subjects) were analyzed in this study. The mean age was 37.9 ± 11 years. The mean \pm SD spherical equivalent and the mean axial length were -6.0 ± 4.2 D (range: -13.13 to 3.25 D) and 25.7 ± 1.8 mm (range: 21.1 to 29.5 mm), respectively. The mean optic disc area measured by OCT was $2.36 \pm 0.51 \text{ mm}^2$. After correction for magnification, it increased to $2.61 \pm 0.61 \text{ mm}^2$, which was significantly different from the uncorrected values ($P < 0.001$). Both corrected and uncorrected disc areas were significantly larger than that measured by the HRT ($2.13 \pm 0.59 \text{ mm}^2$, all with $P < 0.001$). Bland-Altman plots revealed a mean difference of 0.48 mm^2 (95% limits of agreement between 1.50 and -0.54 mm^2) and 0.23 mm^2 (95% limits of agreement between 1.32 and -0.87 mm^2), respectively, between the HRT disc area and the corrected and uncorrected OCT disc areas (Fig. 1). The span of 95% limits of agreement of the HRT and OCT disc areas was smaller when the OCT measurements were corrected for magnification (2.04 mm^2 vs. 2.19 mm^2).

Relationship between Optic Disc Area and Refractive Error

Linear regression analysis showed that the optic disc size measured by the HRT increased with the axial length ($r = 0.193$, $P = 0.026$; Fig. 2a) and negative spherical equivalent ($r = -0.196$, $P = 0.024$; Fig. 3a). In contrast, the uncorrected OCT measurements showed the opposite direction of correlation ($r = -0.314$, $P < 0.001$ and $r = 0.270$, $P = 0.002$ for axial length and spherical equivalent, respectively; Figs. 2b, 3b). After correction for magnification, the OCT measured disc area increased with the axial length ($r = 0.354$, $P < 0.001$) and negative spherical equivalent ($r = -0.309$, $P < 0.001$; Figs. 2c, 3c). For each millimeter increase in axial length, the HRT disc

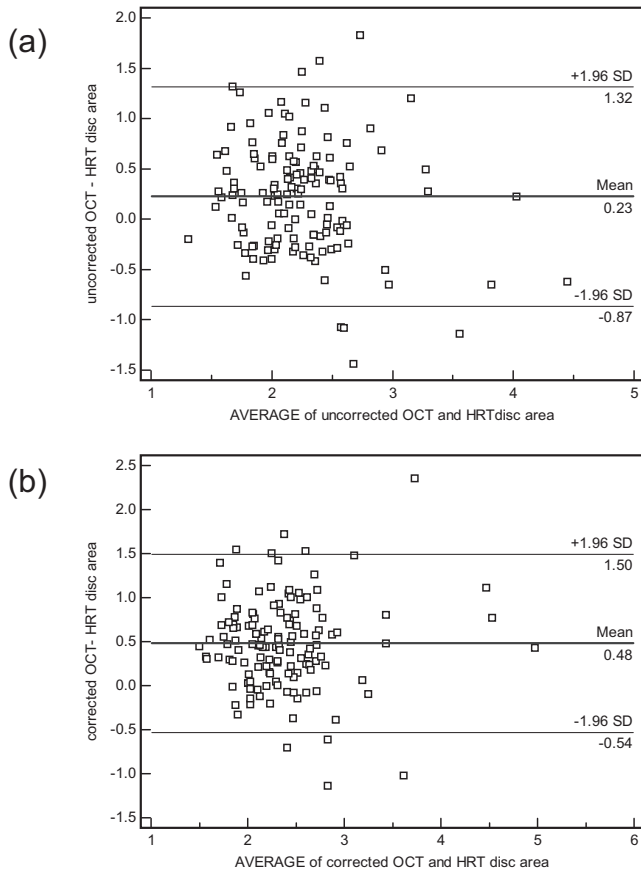


FIGURE 1. Bland-Altman plot of the (a) uncorrected and (b) corrected OCT and HRT optic disc area measurements ($n = 133$).

area increased by 0.065 mm^2 (95% CI $0.008\text{--}0.122 \text{ mm}^2$), whereas for the corrected OCT disc area, it increased by 0.122 mm^2 (95% CI $0.066\text{--}0.178 \text{ mm}^2$). The difference of the corrected OCT and HRT measurements (corrected OCT disc area minus HRT disc area) also demonstrated a positive correlation with the axial length ($r = 0.195, P = 0.025$). An example of the optic disc area measurement difference between HRT and OCT is demonstrated in Figure 4.

The relationships between the optic disc area and spherical equivalent within the range from -8.0 to $+4$ D was analyzed ($n = 81$). While no significant association was found in the HRT measurement, disc area measured by OCT (magnification corrected) correlated significantly with the axial length ($r =$

$0.353, P = 0.001$) and spherical equivalent ($r = -0.344, P = 0.002$). For each millimeter increase in axial length, the optic disc area increased by 0.095 mm^2 (95% CI $0.039\text{--}0.152 \text{ mm}^2$).

Comparison of Optic Disc Parameters between the HRT and OCT

Table 1 compares the disc, cup, and rim areas, and the cup-to-disc area, cup-to-disc vertical, and cup-to-disc horizontal ratios measured by the HRT and OCT (magnification corrected). Fifteen subjects were excluded in this analysis either because the standard $150\text{-}\mu\text{m}$ reference plane in the OCT images was too low to get measurements in shallow optic cups ($n = 7$) or because the presence of posterior vitreous detachment rendered inaccurate the demarcation of the rim area ($n = 8$). Disc, cup, and rim areas and cup-to-disc ratios (area, vertical, and horizontal) measured by OCT were significantly larger than that measured by the HRT (all with $P < 0.001$). The mean difference and the 95% limits of agreement of each of these parameters are shown Table 1. No association was found between age and any of the optic disc measurements.

DISCUSSION

According to the Littmann formula ($t = p \cdot q \cdot s$), determination of true size of the optic disc (t) is related to the camera magnification in the fundus imaging systems (factor p) and the optical dimensions of the given eye (factor q).¹⁵ While factor p is instrument dependent and remains a constant in a telecentric imaging system, various methods have been introduced to estimate factor q based on the ametropia, keratometry, and/or axial length.^{15,16,18,19} With the HRT 3, ametropia and keratometry readings are entered into the operating software (Eye Explorer ver. 1.5.1.0; Heidelberg Engineering, GmbH), and the optic disc measurements are corrected for magnification accordingly. In contrast, entering the axial length and refractive correction in the StratusOCT has no impact on the magnification correction.²⁰ As such, manual correction for optic disc measurements is needed. We selected the modified axial length method derived from Bennet et al.¹⁶ because it is considered more accurate than other methods that use ametropia and keratometry alone.²¹ In this study, the corrected OCT disc area was significantly larger than the uncorrected measurement ($2.61 \pm 0.61 \text{ mm}^2$ versus $2.36 \pm 0.51 \text{ mm}^2, P < 0.001$) with a slightly better agreement (span of 95% limits of agreements, 2.04 vs. 2.19 mm^2) with the HRT measurement. A different conclusion would have been drawn if the OCT measurements were not corrected for ocular magnification (Fig. 2, 3). Correction for magnification in OCT optic disc measure-

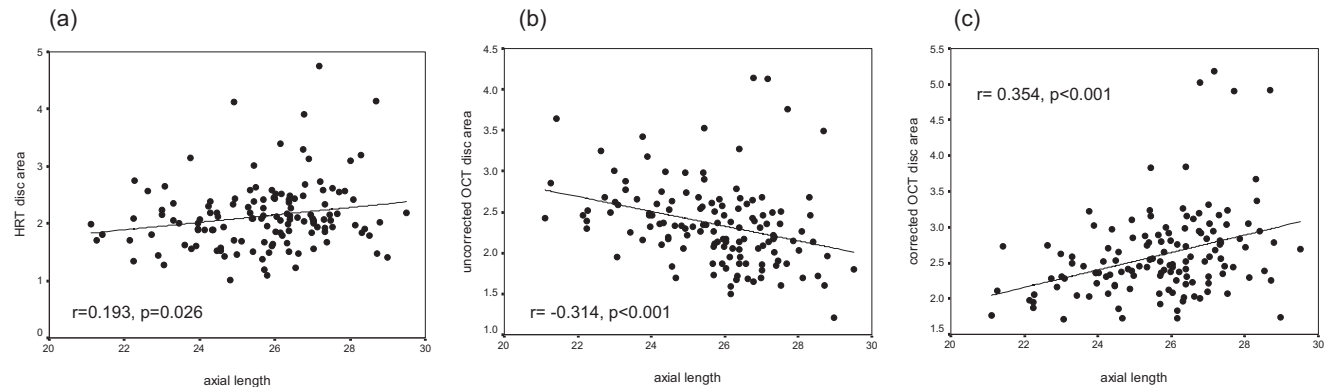


FIGURE 2. Scatterplots of optic disc area from (a) HRT measurements and (b) uncorrected and (c) corrected OCT measurements against the axial length ($n = 133$).

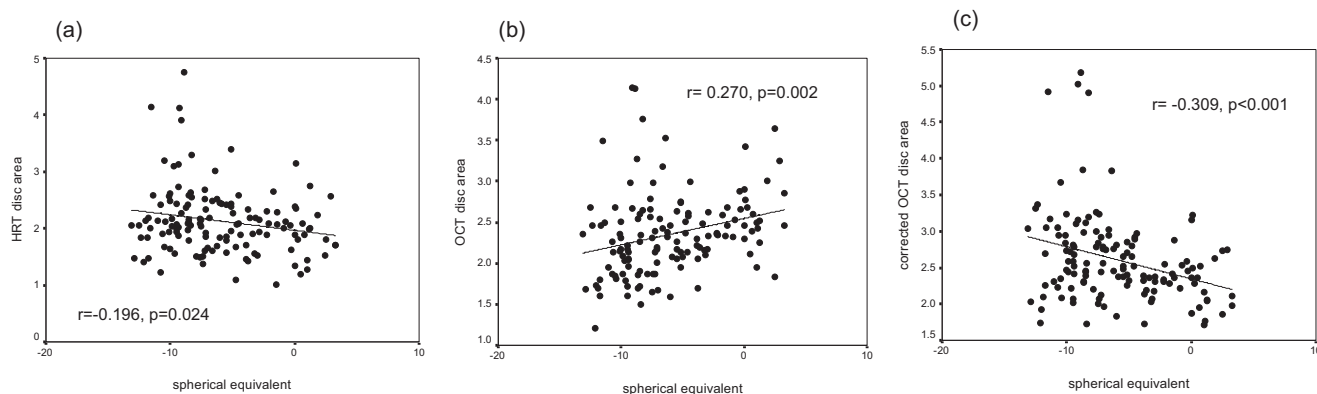


FIGURE 3. Scatterplots of optic disc area from (a) HRT measurements, (b) uncorrected and (c) corrected OCT measurements against the spherical equivalent ($n = 133$).

ments is therefore very important and should not be overlooked.

A few studies have been published comparing the agreement of optic disc size measured with different imaging technologies.²²⁻²⁴ Schuman et al.²² studied 77 eyes of 44 subjects and reported a coefficient of correlation (r) of 0.64 between HRT and StratusOCT. A recent study by Hoffmann et al.²³ showed the span of 95% limits of agreement for the HRT 2 and StratusOCT was 1.15 mm² and $r = 0.73$ ($n = 42$ eyes). In the study by Iliiev et al.,²⁴ the span of 95% limits of agreement was 1.99 mm² and the r was 0.5 ($n = 49$ eyes). It should be noted

that in these studies, the OCT measurements were not corrected for magnification. Different limits of agreement and coefficients of correlations could result if correction for magnification had been taken into consideration. In the present study, the mean difference between the HRT and the magnification-corrected OCT disc area was 0.48 mm² and the span of 95% limits of agreement was 2.04 mm² (1.5 to -0.54 mm²). Consistent with previous studies, the OCT measured a larger disc area compared with the HRT. Rim area, cup-to-disc area ratio, and vertical and horizontal cup-to-disc ratios were also significantly larger than those measured by the HRT, and this

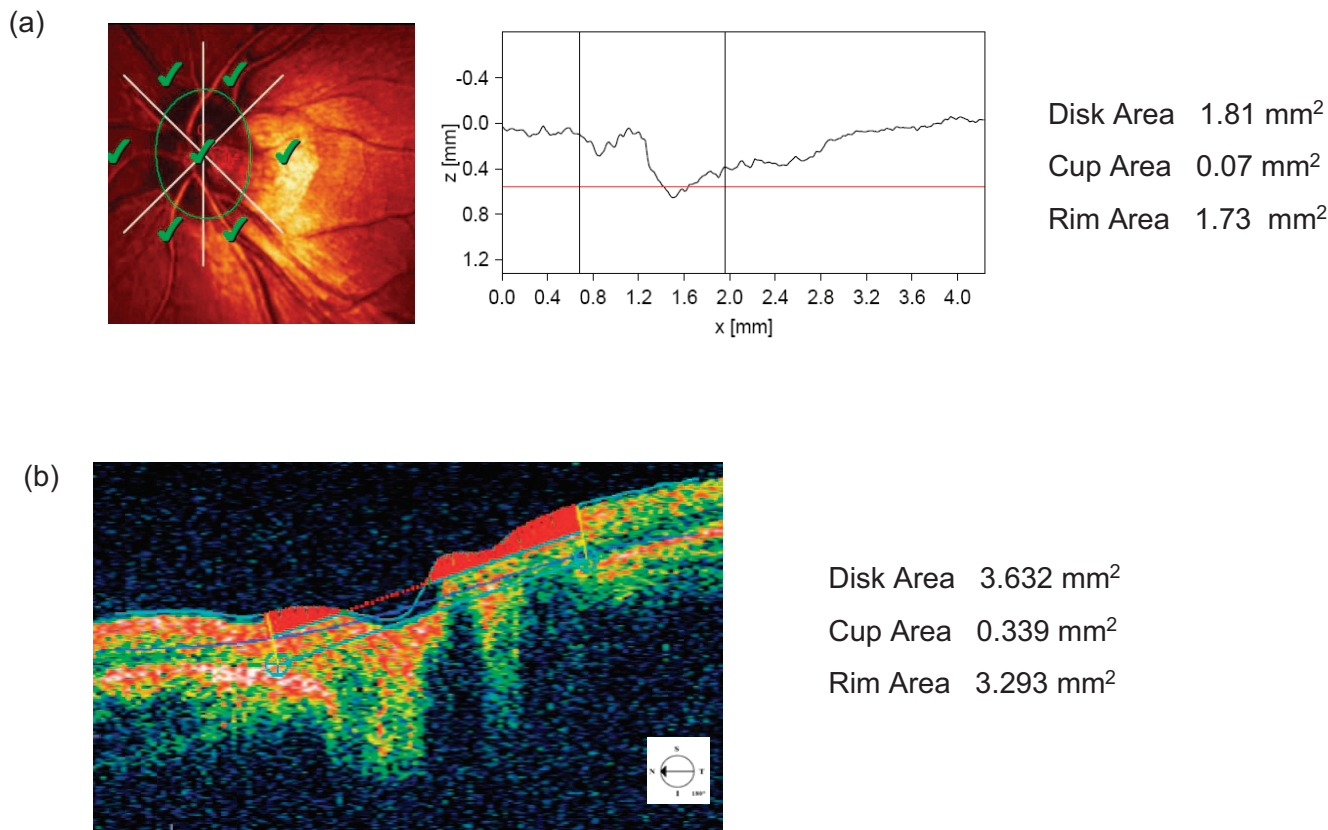


FIGURE 4. An eye with extensive peripapillary atrophy was imaged with HRT 3 and StratusOCT. The HRT 3 reflectance image with the Moorfield regression analysis (a) and the StratusOCT horizontal cross-sectional scan (b) are illustrated. Manual drawing of the optic disc margin was performed with HRT 3. In contrast, the optic disc margin was automatically determined by StratusOCT software. In comparing the horizontal cross-sectional profiles between HRT 3 (a, right) and StratusOCT, it is evident that the temporal disc margin determined by StratusOCT is farther away from the disc, resulting in a larger optic disc area (3.632 vs. 1.81 mm²).

TABLE 1. Comparisons between Disc Parameters Measured by Optical Coherence Tomography (Magnification Corrected) and Confocal Scanning Laser Ophthalmoscope

	Mean \pm SD 95% CI	Mean \pm SD 95% CI	<i>P</i> (Paired <i>t</i> -Test)	Mean Difference OCT – HRT	95% Limits of Agreement
Disc area (mm ²)	2.61 \pm 0.62 2.49–2.72	2.16 \pm 0.61 2.05–2.27	<0.001	0.44	1.44––0.55
Cup area (mm ²)	0.67 \pm 0.52 0.58–0.76	0.46 \pm 0.36 0.39–0.52	<0.001	0.21	0.88––0.45
Rim area (mm ²)	1.93 \pm 0.41 1.86–2.01	1.70 \pm 0.42 1.63–1.78	<0.001	0.23	1.16––0.70
Cup/disc area ratio	0.24 \pm 0.13 0.22–0.27	0.20 \pm 0.12 0.18–0.22	<0.001	0.05	0.22––0.12
Cup/disc vertical ratio	0.45 \pm 0.13 0.42–0.47	0.31 \pm 0.18 0.28–0.35	<0.001	0.13	0.40––0.13
Cup/disc horizontal ratio	0.50 \pm 0.15 0.48–0.53	0.45 \pm 0.19 0.42–0.49	<0.001	0.05	0.34––0.24

n = 118.

difference is probably related to the larger disc area measured by OCT. These suggest that the determination of disc area has significant influence in the evaluation of all the optic disc-related parameters.

Controversies exist regarding the relationship between optic disc size and refractive error. Jonas⁶ and Wang et al.⁷ found that optic disc size was statistically independent, with refractive error within the range of -8 to $+4$ D. In contrast, the Rotterdam study reported that the disc area increased by 0.033 mm² linearly for each diopter increase toward myopia, and these increases were not significantly different in eyes with refractive error between -4 and $+4$ D.⁸ Of note, in this study, the HRT 3 and the StratusOCT also showed different results. Although correlations between the disc area and axial length-refractive error were found in both instruments with ametropia between -14 and $+4$ D, correlations were not evident in the HRT, but were in OCT, when the range of ametropia was limited to -8 to $+4$ D. We believe this discrepancy could be related to the different definitions of disc margin. In the HRT, the disc margin is defined by the outer boundary of Elschnig's ring whereas in OCT, it is the ends of the retinal pigment epithelium (RPE) that are automatically detected. In myopic eyes, peripapillary atrophy is more common.⁸ It is conceivable that optic discs with peripapillary atrophy, which is an area characterized histologically by Bruch's membrane devoid of RPE and photoreceptors,²⁵ could have been measured larger in size in OCT. It is because the borders of the RPE, which are farther away from the outer edge of Elschnig's ring in eyes with peripapillary atrophy, would be detected as the disc margin. Although the location of the disc margin can be adjusted manually in OCT, determining the disc margin in the cross-sectional optic disc image could be highly subjective. So far, no standard approach has been suggested or validated in this regard. It has been shown that the prevalence of peripapillary atrophy increase with 1.3% for each diopter increase in myopia.⁸ It is plausible that OCT overestimates optic disc area in eyes with longer axial length and leads to an apparent correlation within the range between -8.0 and $+4.0$ D. It is supported by the observation that the difference in disc area measured by OCT and HRT was correlated to the axial length ($r = 0.195$, $P = 0.025$; the difference in disc area measured by OCT and HRT may well correspond to the area of peripapillary atrophy). The findings in the HRT agree with the notion that optic disc size is largely independent of axial length/refractive error within the range between -8 and $+4$ D. Caution should be exercised in the interpretation of OCT disc measurements in eyes with peripapillary atrophy.

The HRT and OCT have theoretical advantages over conventional planimetry. However, none has yet to offer perfect

disc measurements. The HRT produces best image quality when the range of ametropia is from -12 to $+12$ D, and this range limited our selection of myopic subjects. (The maximum negative spherical error in our cohort was -12.5 D [spherical equivalent = -13.1 D].) OCT stands out for its automated algorithm for objective detection of disc margin, and yet, this algorithm crumbles in eyes with peripapillary atrophy in which the borders of the RPE may not correspond to the actual disc margin. In addition, much of the disc information could be missed by the extrapolation of disc measurement from the six linear cross-sectional scans. The limitation in disc measurement is also related to the level of reference plane. The default reference plane in the StratusOCT is determined by tracing a line with an anterior offset of 150 μ m parallel to the disc diameter (the line joining the ends of the RPE). Although we found that this reference plane was suitable in detecting glaucomatous change,²⁶ it could be too high in eyes with shallow cups. Although the level of reference plane would not affect the measurement of the disc area, its position has direct impact on the calculation of rim and cup areas. Seven cases were excluded in the analysis of rim area and cup-to-disc ratio for this reason. Finally, we would like to highlight the importance that optic disc measurements should not be directly adopted from the StratusOCT analysis printout. As shown in this study, different conclusions could be drawn if correction for ocular magnification was not taken into consideration.

In summary, optic disc area generally increased with axial length/negative spherical equivalent, although the HRT measurements demonstrated that these associations became insignificant in the range of -8 to $+4$ D. OCT may overestimate optic disc size in myopic eyes. Most of the disagreements between the HRT and OCT optic disc measurements could be related to the different disc margin definitions of the two instruments. The relationships between disc area and axial length/refractive error should always be interpreted with reference to the range of ametropia and the imaging technology used in the optic disc measurements.

References

1. Healey PR, Mitchell P. Optic disk size in open-angle glaucoma: the Blue Mountains Eye Study. *Am J Ophthalmol.* 1999;128:515–517.
2. Wang L, Damji KF, Munger R, et al. Increased disk size in glaucomatous eyes vs normal eyes in the Reykjavik eye study. *Am J Ophthalmol.* 2003;135:226–228.
3. Beck RW, Savino PJ, Repka MX, et al. Optic disc structure in anterior ischemic optic neuropathy. *Ophthalmology.* 1984;91:1334–1337.

4. Jonas JB, Gusek GC, Guggenmoos-Holzmann I, et al. Optic nerve head drusen associated with abnormally small optic discs. *Int Ophthalmol*. 1987;11:79-82.
5. Jonas JB, Gusek GC, Naumann GO. Optic disk morphometry in high myopia. *Graefes Arch Clin Exp Ophthalmol*. 1988;226:587-590.
6. Jonas JB. Optic disk size correlated with refractive error. *Am J Ophthalmol*. 2005;139:346-348.
7. Wang Y, Xu L, Zhang L, et al. Optic disc size in a population based study in northern China: the Beijing Eye Study. *Br J Ophthalmol*. 2006;90:353-356.
8. Ramrattan RS, Wolfs RC, Jonas JB, et al. Determinants of optic disc characteristics in a general population: The Rotterdam Study. *Ophthalmology*. 1999;106:1588-1596.
9. Rudnicka AR, Frost C, Owen CG, et al. Nonlinear behavior of certain optic nerve head parameters and their determinants in normal subjects. *Ophthalmology*. 2001;108:2358-2368.
10. Kampmpeter BA, Schubert KV, Budde WM, et al. Optical coherence tomography of the optic nerve head: interindividual reproducibility. *J Glaucoma*. 2006;15:248-254.
11. Paunescu LA, Schuman JS, Price LL, et al. Reproducibility of nerve fiber thickness, macular thickness, and optic nerve head measurements using StratusOCT. *Invest Ophthalmol Vis Sci*. 2004;45:1716-1724.
12. Sihota R, Gulati V, Agarwal HC, et al. Variables affecting test-retest variability of Heidelberg Retina Tomograph II stereometric parameters. *J Glaucoma*. 2002;11:321-328.
13. Rohrschneider K, Burk RO, Kruse FE, et al. Reproducibility of the optic nerve head topography with a new laser tomographic scanning device. *Ophthalmology*. 1994;101:1044-1049.
14. Kruse FE, Burk RO, Volcker HE, et al. Reproducibility of topographic measurements of the optic nerve head with laser tomographic scanning. *Ophthalmology*. 1989;96:1320-1324.
15. Littmann H. Determination of the real size of an object on the fundus of the living eye (in German). *Klin Monatsbl Augenheilkd*. 1982;180:286-289.
16. Bennett AG, Rudnicka AR, Edgar DF. Improvements on Littmann's method of determining the size of retinal features by fundus photography. *Graefes Arch Clin Exp Ophthalmol*. 1994;232:361-367.
17. Bland JM, Altman DG. Statistical methods for assessing agreement between two methods of clinical measurement. *Lancet*. 1986;1:307-310.
18. Bengtsson B, Krakau CE. Correction of optic disc measurements on fundus photographs. *Graefes Arch Clin Exp Ophthalmol*. 1992;230:24-28.
19. Littmann H. Determining the true size of an object on the fundus of the living eye (in German). *Klin Monatsbl Augenheilkd*. 1988;192:66-67.
20. *StratusOCT User's Manual*. Jena, Germany: Carl Zeiss Meditec, GmbH; 2004.
21. Garway-Heath DF, Rudnicka AR, Lowe T, et al. Measurement of optic disc size: equivalence of methods to correct for ocular magnification. *Br J Ophthalmol*. 1998;82:643-649.
22. Schuman JS, Wollstein G, Farra T, et al. Comparison of optic nerve head measurements obtained by optical coherence tomography and confocal scanning laser ophthalmoscopy. *Am J Ophthalmol*. 2003;135:504-512.
23. Hoffmann EM, Bowd C, Medeiros FA, et al. Agreement among 3 optical imaging methods for the assessment of optic disc topography. *Ophthalmology*. 2005;112:2149-156.
24. Iliev ME, Meyenberg A, Garweg JG. Morphometric assessment of normal, suspect and glaucomatous optic discs with StratusOCT and HRT II. *Eye*. 2006;20:1288-1289.
25. Dichtl A, Jonas JB, Naumann GO. Histomorphometry of the optic disc in highly myopic eyes with absolute secondary angle closure glaucoma. *Br J Ophthalmol*. 1998;82:286-289.
26. Leung CK, Chan WM, Hui YL, et al. Analysis of retinal nerve fiber layer and optic nerve head in glaucoma with different reference plane offsets, using optical coherence tomography. *Invest Ophthalmol Vis Sci*. 2005;46:891-899.