

Selective Loss of Inner Retinal Layer Thickness in Type 1 Diabetic Patients with Minimal Diabetic Retinopathy

Hille W. van Dijk,¹ Pauline H. B. Kok,¹ Mona Garvin,² Milan Sonka,^{2,3} J. Hans DeVries,⁴ Robert P. J. Michels,⁴ Mirjam E. J. van Velthoven,¹ Reinier O. Schlingemann,¹ Frank D. Verbraak,^{1,5} and Michael D. Abramoff^{2,3,6}

PURPOSE. To determine whether type 1 diabetes preferentially affects the inner retinal layers by comparing the thickness of six retinal layers in type 1 diabetic patients who have no or minimal diabetic retinopathy (DR) with those of age- and sex-matched healthy controls.

METHODS. Fifty-seven patients with type 1 diabetes with no ($n = 32$) or minimal ($n = 25$) DR underwent full ophthalmic examination, stereoscopic fundus photography, and optical coherence tomography (OCT). After automated segmentation of intraretinal layers of the OCT images, mean thickness was calculated for six layers of the retina in the fovea, the pericentral area, and the peripheral area of the central macula and were compared with those of an age- and sex-matched control group.

RESULTS. In patients with minimal DR, the mean ganglion cell/inner plexiform layer was $2.7 \mu\text{m}$ thinner (95% confidence interval [CI], $2.1\text{--}4.3 \mu\text{m}$) and the mean inner nuclear layer was $1.1 \mu\text{m}$ thinner (95% CI, $0.1\text{--}2.1 \mu\text{m}$) in the pericentral area of the central macula compared to those of age-matched controls. In the peripheral area, the mean ganglion cell/inner plexiform layer remained significantly thinner. No other layers showed a significant difference.

CONCLUSIONS. Thinning of the total retina in type 1 diabetic patients with minimal retinopathy compared with healthy controls is attributed to a selective thinning of inner retinal layers and supports the concept that early DR includes a neurodegenerative component. (*Invest Ophthalmol Vis Sci.* 2009;50:3404–3409) DOI:10.1167/iovs.08-3143

From the Departments of ¹Ophthalmology, ⁴Internal Medicine, and ²Biomedical Engineering and Physics, Academic Medical Center, Amsterdam, the Netherlands; the ²Department of Electrical and Computer Engineering, The University of Iowa, Iowa City, Iowa; the ³Department of Ophthalmology and Visual Sciences, The University of Iowa Hospital and Clinics, Iowa City, Iowa; and ⁶Veterans Administration Medical Center, Iowa City, Iowa.

Supported by the Edward en Marianne Blaauwfonds, Netherlands Organization for Health Research and Development, National Institutes of Health/National Eye Institute Grant R01-EY017066, and Research to Prevent Blindness.

Submitted for publication November 12, 2008; revised December 23, 2008; accepted April 16, 2009.

Disclosure: H.W. van Dijk, None; P.H.B. Kok, None; M. Garvin, P; M. Sonka, P; J.H. DeVries, None; R.P.J. Michels, None; M.E.J. van Velthoven, None; R.O. Schlingemann, None; F.D. Verbraak, None; M.D. Abramoff, P

The publication costs of this article were defrayed in part by page charge payment. This article must therefore be marked "advertisement" in accordance with 18 U.S.C. §1734 solely to indicate this fact.

Corresponding author: Hille W. van Dijk, Department of Ophthalmology, Academic Medical Center, PO Box 22660, 1100 DD, Amsterdam, the Netherlands; h.w.vandijk@amc.nl.

Diabetic retinopathy (DR) is one of the leading causes of blindness in developed countries. DR is primarily considered a form of vasculopathy and classically manifests with microaneurysms, small hemorrhages, or lipoprotein exudates. The precise pathophysiological mechanism leading to the onset and progression of DR is still unclear, though vascular damage through hyperglycemia is considered to play a pivotal role.¹ Several studies have indicated that neural loss may occur in DR even before any visible signs of vascular damage can be observed. Human and animal studies have shown neural apoptosis, loss of ganglion cell bodies, and glial reactivity in the retina in the earliest stages of retinopathy.^{2–15} Previous studies showed that the inner retinal layers in Ins2Akita diabetic mice and streptozotocin diabetic rats are thinner than controls, which indicates neurodegeneration of the inner retina.^{11,16} With optical coherence tomography (OCT), it became possible to image the human retina longitudinally in vivo and to measure the retinal thickness (RT) with high accuracy. Several groups have shown that total RT is decreased in patients with no or minimal DR compared with healthy controls.^{17–20}

Given that the inner retinal layers are affected differentially by diabetes, it is desirable to have the ability to quantify the thickness of each layer within the retina separately. The Stratus OCT (model 3000, software version 4.0.1; Carl Zeiss Meditec, Dublin, CA) provides B-scan images of the retina with an axial resolution of 8 to 10 μm . Even though multiple layers of the retina are distinguishable in these OCT images, the installed software only provided thickness measurements for the total retina and retinal nerve fiber layer. Recently, fully automated algorithms have been published for the segmentation of retinal time-domain and spectral-domain OCT scans that are capable of detecting seven to nine surface boundaries in the retina, based on differences in refractive index resulting in differences in the scattering of laser light.^{21–26} The accuracy and reproducibility of the algorithm developed by Garvin et al.²² used in this study is comparable to or better than that of human experts segmenting the same layer surfaces and detects six retinal layers in Stratus OCT images.

The purpose of this study was to determine whether type 1 diabetes preferentially affects the inner retinal layers by comparing the thickness of six retinal layers in type 1 diabetic patients who had no or minimal DR with the thickness in age- and sex-matched healthy controls.

PATIENTS, MATERIALS, AND METHODS

Patients

Consecutive patients, recruited from the outpatient clinic of the department of Internal Medicine at the Academic Medical Centre (University Hospital, Amsterdam, Netherlands) between July 2004 and June 2005 and participating in an ongoing longitudinal observational study, were asked to participate in this observational cross-sectional study. In total, 57 patients were included, of whom 53 have already been described in a previous study by Bialosterski et al.¹⁷ The study adhered

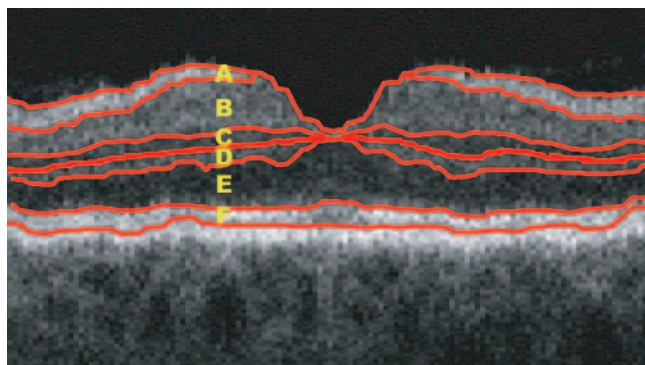


FIGURE 1. Macular B-scan with intraretinal surfaces as indicated by the red lines and corresponding retinal layers. A, retinal nerve fiber layer; B, ganglion cell layer plus inner plexiform layer; C, inner nuclear layer; D, outer plexiform layer; E, outer nuclear layer plus inner segments (photoreceptors); F, outer segments (photoreceptors).

to the tenets of the Declaration of Helsinki. Investigative review board approval was obtained at both the Academic Medical Centre and the University of Iowa, and all participants gave written informed consent.

Visual acuity was measured with the use of an Early Treatment Diabetic Retinopathy Study chart at 4 m. Best-corrected visual acuity was recorded as Snellen equivalent. After pupil dilation with 0.5% phenylephrine hydrochloride and 0.1% tropicamide, both eyes were examined with a stereoscopic slit lamp biomicroscope and a handheld lens (SuperField; Volk Optical, Inc., Mentor, OH), and OCT images were obtained. In addition, stereoscopic fundus photographs were taken (TRC-50IX; Topcon Corporation, Tokyo, Japan). Age, sex, duration and type of diabetes, and recent HbA1c level (within 3 months) were recorded.

Inclusion criteria were diagnosis of type 1 diabetes mellitus (DM) and no or minimal DR, as determined by a retinal specialist through indirect funduscopy and slit lamp stereo biomicroscopy and stereoscopic fundus photography. Minimal DR was defined as the presence of at least one microaneurysm or hemorrhage in the central retina but no other diabetic lesions (second stage of the International Clinical Diabetic Retinopathy Disease Severity Scale).²⁷ Exclusion criteria were refractive errors over S +5 or under S -8 D, visual acuity less than

20/25, significant media opacities, and previous diagnosis of glaucoma, uveitis, or retinal disease. Healthy control subjects were age and sex matched with patients and did not have any diagnosed ocular disease, diabetes, or other systemic disease.

Optical Coherence Tomography Imaging

All subjects were examined with the Stratus OCT (model 3000, software version 4.0.1; Carl Zeiss Meditec). The fast macular thickness OCT protocol was performed. This scan protocol obtains six cross-sectional B-scans, 6 mm in length, at equally spaced angular orientations (30°) in a radial spoke pattern centered on the fovea. A previous study by Biallostowski et al.¹⁷ showed a significant correlation ($R = 0.93$; $P < 0.0001$) between the mean RT of the left and right eyes of the same subject. Therefore, in this study only the right eyes of patients and controls were used for further analysis. For analysis of the retina, three retinal areas were defined. They were: (1) the fovea, the central circle with a diameter of 1 mm; (2) the pericentral area, a donut-shaped ring centered on the fovea that had an inner diameter of 1 mm and an outer diameter of 3 mm; and (3) the peripheral area, with an inner diameter of 3 mm and an outer diameter of 6 mm.

Automated Segmentation of Retinal Surfaces

Segmentation was performed in two stages. First, a three-dimensional (3D) macular volume from the raw data of the 6 radial OCT scans was created. Second, the seven surfaces within this 3D macular image were determined. Briefly, the seven surfaces defining the six layers were found in each 3D volume by transforming the segmentation task into that of finding a minimum-cost closed set in a geometric graph constructed from edge/regional information and a priori determined surface smoothness and interaction constraints. Correspondence with human expert segmentation has been studied and published.²⁵ The six layers that could be identified were interpreted as follows (from the inner to the outer surface): A, retinal nerve fiber layer; B, ganglion cell layer plus inner plexiform layer; C, inner nuclear layer; D, outer plexiform layer; E, outer nuclear layer plus inner segments (photoreceptors); F, outer segments (photoreceptors) (Fig. 1).

Thickness Measurement of the Separate Layers

Each of the six B-scans was divided into two half-sections, from the foveal center to the most peripheral measured A-scan (Fig. 2). Each of

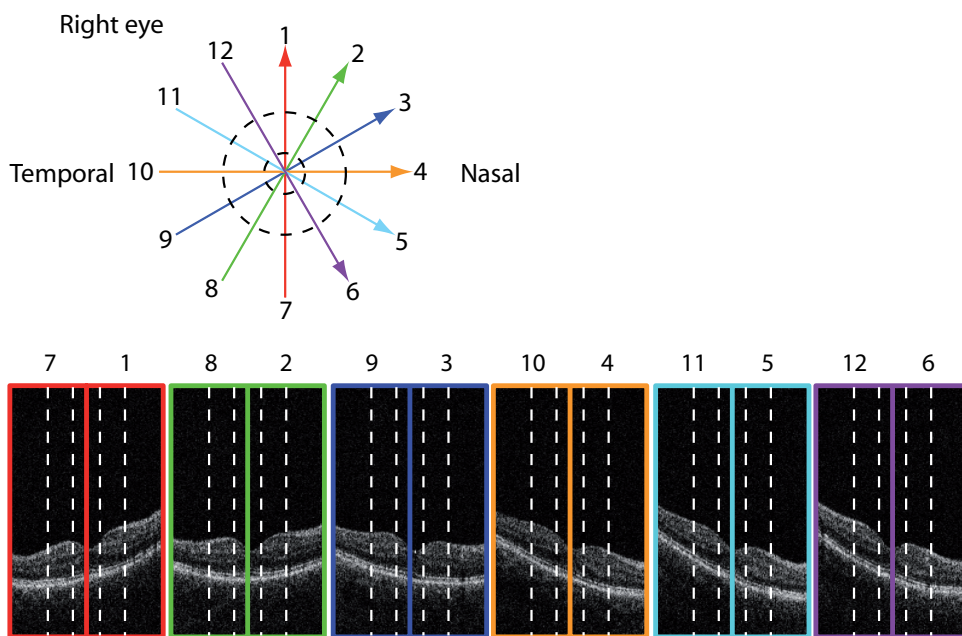


FIGURE 2. Twelve half-sections of the six B-scans of the fast macular thickness OCT scan protocol. The dotted lines indicate the transition between the foveal area, pericentral area, and peripheral area.

TABLE 1. Characteristics of Patients with Type 1 Diabetes with and without Minimal DR and Controls

Parameters	Patients with and without Minimal DR (n = 57)	Patients without DR (n = 32)	Patients with Minimal DR (n = 25)	Controls (n = 5)
Age (years)	33 ± 11	30 ± 11*	37 ± 10*	33 ± 11
Sex (M:F)	21:36	11:21	10:15	25:34
Duration of DM (years)	17.6 ± 9.2	14 ± 8*	22 ± 9*	NA
HbA1C (%)	8.1 ± 1.1	8.0 ± 1.2	8.1 ± 0.9	—

Values are mean ± SD for all subjects in each group. HbA1C, glycosylated hemoglobin; NA, not applicable; —, not performed.

* Significant difference between patients with DM type 1 with minimal DR and patients with DM type 1 without DR.

the 12 half sections consisted of 64 A-scans. An A-scan is an axial depth scan at a given lateral point in the retina. A cross-sectional scan (B-scan) may be achieved by laterally combining 128 of these A-scans. The central A-scans from 1 to 11 defined the foveal area; the pericentral area was defined by A-scans 12 to 32, and the peripheral area was defined by A-scans 33 to 64. Within each A-scan, the thickness of the six different layers as detected by the segmentation algorithm was defined. Mean layer thickness (LT) in all three areas—foveal, pericentral, peripheral—for all layers was compared among patients without DR, patients with minimal DR, and healthy controls.

Statistical Analysis

Statistical analyses were performed (SPSS 16.0.2 for Windows; SPSS, Chicago, IL). Analysis of variance (ANOVA) was used to assess differences in mean age between patients and controls. Mean HbA1c and duration of diabetes in patients with no or minimal DR were compared using the unpaired *t*-test.

Mean RT and mean LT of diabetic patients with DR, diabetic patients without DR, and controls were compared using ANOVA, followed by Bonferroni post hoc analysis to correct for multiple comparisons. Confidence intervals were computed at the *P* = 0.05 level.

RESULTS

In total, 57 consecutive patients with type 1 diabetes were included in the study, of whom 32 had no DR and 25 had minimal DR. There were significant differences in age and mean duration of diabetes between the diabetic patients with

minimal DR and those without DR (Table 1). There was no significant difference in age between patients and controls. Most patients had reasonable glycemic control (mean HbA1c, 8.1%; SD, 1.1).

Mean total RT in all patients with DM compared with healthy controls is shown in Table 2. The pericentral area was significantly thinner in patients than in controls. Division of the patient group into diabetic patients with minimal DR and patients with no DR showed that thinning of the retina was more pronounced in the patient group with minimal DR (Table 3). Total RT in diabetic patients with minimal DR was significantly thinner in the pericentral area than it was in healthy controls.

Mean LT of the six intraretinal layers in the foveal, the pericentral, and the peripheral areas of patients with type 1 DM, with or without minimal DR, compared with healthy controls is shown, respectively, in Tables 4, 5 and 6. Mean LT differences (μm) between patients with type 1 DM with or without minimal DR and age-matched healthy controls in the pericentral area of the macula are depicted in Figures 3 and 4. In the pericentral area, the ganglion cell plus inner plexiform layer and the inner nuclear layer of diabetic patients with minimal DR were significantly thinner than in healthy controls. In the peripheral area, the ganglion cell plus inner plexiform layer remained significantly thinner. In contrast all outer retinal layers did not show a significant difference in layer thickness. Patients with diabetes and no DR showed no significant differences in any LT compared with healthy controls.

TABLE 2. Mean RT Measurements (μm) in Patients with Type 1 Diabetes with and without Minimal DR Compared with Controls

Parameters	Patients with and without Minimal DR (n = 57)	Mean Difference	95% CI		Controls (n = 59)
			Lower Bound	Upper Bound	
Fovea	207.46	-0.68	-9.78	8.41	208.14
PCR	273.98	-6.23	-12.27	-0.18	280.21
PR	240.00	-3.04	-8.16	2.10	243.04

CI, confidence interval; PCR, pericentral ring; PR, peripheral ring. The bold values indicate a statistically significant difference between patients and controls (*P* < 0.05).

TABLE 3. Mean RT Measurements (μm) in Patients with Type 1 Diabetes with and without Minimal DR Compared with Controls

Parameters	Patients without DR (n = 32)	Mean Difference	95% CI		Patients with Minimal DR (n = 25)	Mean Difference	95% CI		Controls (n = 59)
			Lower Bound	Upper Bound			Lower Bound	Upper Bound	
Fovea	211.72	3.58	-9.53	16.69	202.00	-6.14	-20.40	8.12	208.14
PCR	277.84	-2.38	-11.02	6.27	269.05	-11.16	-20.56	-1.77	280.21
PR	241.03	-2.01	-9.47	5.46	238.69	-4.35	-12.46	3.76	243.04

Abbreviations as in Table 2. The bold values indicate a statistically significant difference between patients and controls (*P* < 0.05).

TABLE 4. Mean LT Measurements (μm) of the Individual Intraretinal Layers in the Foveal Area in Patients with Type 1 Diabetes with and without Minimal DR Compared with Controls

Parameters	Patients without DR (<i>n</i> = 32)	Mean Difference	95% CI		Patients with Minimal DR (<i>n</i> = 25)	Mean Difference	95% CI		Controls (<i>n</i> = 59)
			Lower Bound	Upper Bound			Lower Bound	Upper Bound	
RNFL	0.88	0.16	-0.1	0.44	0.66	-0.06	-0.36	0.24	0.72
GCL + IPL	43.76	3.62	-2.58	9.84	40.60	0.46	-6.26	7.2	40.14
INL	29.42	0.58	-1.9	3.06	29.1	0.26	-2.44	2.96	28.84
OPL	16.54	2.30	-0.12	4.70	14.86	0.62	-2.02	3.22	14.24
ONL + IS	115.64	-1.2	-8.04	5.64	113.02	-3.82	-11.26	3.62	116.84
OS	38.36	0.32	-1.28	1.92	39	0.96	-0.78	2.7	38.04

RNFL, retinal nerve fiber layer; GCL, ganglion cell layer; IPL, inner plexiform layer; INL, inner nuclear layer; OPL, outer plexiform layer; ONL, outer nuclear layer; IS, inner segments; OS, outer segments.

DISCUSSION

With the use of an algorithm that detects six retinal layers in Stratus OCT images and through comparison of patients and age- and sex-matched healthy controls, this study showed that type 1 diabetes preferentially affects the inner retinal layers. In patients with minimal DR, significant thinning was found in the pericentral area of the macula in the ganglion cell plus inner plexiform layer ($5.42 \mu\text{m}$) and the inner nuclear layer ($2.16 \mu\text{m}$). In the peripheral area, only the ganglion cell plus inner plexiform layer was thinner ($2.14 \mu\text{m}$) in these patients. In contrast, in the outer retinal layers, no significant difference in thickness measurements between the patients with minimal DR and healthy controls could be detected. The mean difference of total RT ($11.6 \mu\text{m}$) in the pericentral ring between type 1 diabetic patients with minimal DR and controls was attrib-

uted primarily to a selective thinning of inner retinal layers ($9.08 \mu\text{m}$). In patients without DR, no statistically significant difference in any LT could be found.

Based on these results, we conclude that the inner retina becomes thinner in patients with type 1 diabetes and minimal DR. Previous studies have shown a decrease in total retinal thickness,¹⁷⁻²⁰ and this study confirms and expands these results. The loss of neural tissue agrees with previous studies showing neuroretinal functional deficits in patients with diabetes, even before the onset of vascular lesions, such as an abnormal electroretinogram, loss of dark adaptation and contrast sensitivity, color vision disturbances, and abnormal microperimetry.²⁸⁻³⁵

Our results indicate diabetes has an early neurodegenerative effect on the retina that occurs even though the vascular

TABLE 5. Mean LT Measurements (μm) of the Individual Intraretinal Layers in the Pericentral Area of the Macula in Patients with Type 1 Diabetes with and without Minimal DR Compared with Controls

Parameters	Patients without DR (<i>n</i> = 32)	Mean Difference	95% CI		Patients with Minimal DR (<i>n</i> = 25)	Mean Difference	95% CI		Controls (<i>n</i> = 59)
			Lower Bound	Upper Bound			Lower Bound	Upper Bound	
RNFL	16.6	-0.1	-1.34	1.54	15.2	-1.5	-3.06	0.06	16.7
GCL + IPL	105.86	-0.2	-3.1	2.7	100.64	-5.42	-8.56	-2.26	106.06
INL	36.26	-0.04	-1.88	1.82	34.14	-2.16	-4.18	-0.16	36.3
OPL	39.38	-1.4	-0.98	3.78	38.58	-0.6	-1.98	3.2	37.98
ONL + IS	88.68	-1.62	-5.5	2.26	87.32	-2.98	-7.2	1.24	90.3
OS	34.46	0.42	-1.62	2.44	35.54	-1.5	-0.72	3.72	34.04

RNFL, retinal nerve fiber layer; GCL, ganglion cell layer; IPL, inner plexiform layer; INL, inner nuclear layer; OPL, outer plexiform layer; ONL, outer nuclear layer; IS, inner segments; OS, outer segments. The bold values indicate a statistically significant difference between patients and controls ($P < 0.05$).

TABLE 6. Mean LT Measurements (μm) of the Individual Intraretinal Layers in the Peripheral Area of the Macula in Patients with Type 1 Diabetes with and without Minimal DR Compared with Controls

Parameters	Patients without DR (<i>n</i> = 32)	Mean Difference	95% CI		Patients with Minimal DR (<i>n</i> = 25)	Mean Difference	95% CI		Controls (<i>n</i> = 59)
			Lower Bound	Upper Bound			Lower Bound	Upper Bound	
RNFL	32.68	-0.88	-2.76	1.02	32.26	-1.3	-3.34	0.76	33.56
GCL + IPL	74.14	-0.36	-2.1	1.38	72.36	-2.14	-4.02	-0.24	74.5
INL	33.52	0.06	-1.58	1.7	32.44	-1.02	-2.82	0.76	33.46
OPL	27	0.2	-1.48	1.86	26.64	-0.16	-1.98	1.66	26.8
ONL + IS	78.52	-0.72	-4	2.58	78.32	-0.92	-4.48	2.66	79.24
OS	36.5	0.68	-0.84	2.18	36.32	0.5	-1.16	2.12	35.82

Abbreviations as in Table 5. The bold values indicate a statistically significant difference between patients and controls ($P < 0.05$).

component of DR remains minimal. The mechanisms behind this neurodegeneration are not clear. The inner retina, supplied by the retinal circulation, is relatively hypoxic compared with the outer retina, which is primarily supplied by the choroidal circulatory. In combination with the high metabolic demands of the retina, this makes the inner retina more vulnerable to metabolic stress induced by diabetes.³⁶ Another potential mechanism is the decreased availability of insulin, a survival factor for retinal neurons,^{37,38} counteracting apoptosis of neuroglial cells in the inner retina induced by hyperglycemia and advanced glycation end products.^{4,39}

In this study, the mean duration of DM in patients with minimal DR was 8 years longer than in patients without DR (Table 1), which indicates that both processes slowly develop over time and are late complications of DM. Although both processes are linked, the nature of their interdependence is unknown. Each process, once established, probably contributes to the progression of the other.³⁶ Therefore, neuronal apoptosis may be an important target for new therapeutic interventions.

The high interindividual variability in RT prevents the definition of a clear threshold between normal and abnormal RT. Consequently, RT measurements based on Stratus OCT are not suitable for detecting early neurodegeneration and thus are not applicable for the decision to treat. Future studies must address whether the increased resolution of spectral domain OCT or a combination of neuroretinal functional tests and RT measurements can be useful to detect early neural cell defects and to start possible neuroprotection.

The present study had several limitations. First, the grading of no or minimal background retinopathy was made by a single reader from a single set of stereoscopic central retinal photographs combined with clinical evaluation instead of the gold standard—seven-field stereo fundus photography read by independent, trained graders.⁴⁰ However, no patients had advanced retinopathy, indicating that the results do apply to the earliest stage of DR.

Secondly, the HbA1C of the healthy subjects was unknown. Type 2 diabetes is often subclinical; therefore, it cannot be excluded that some healthy subjects actually had diabetes and

Layer thickness difference in the peripheral area of the macula

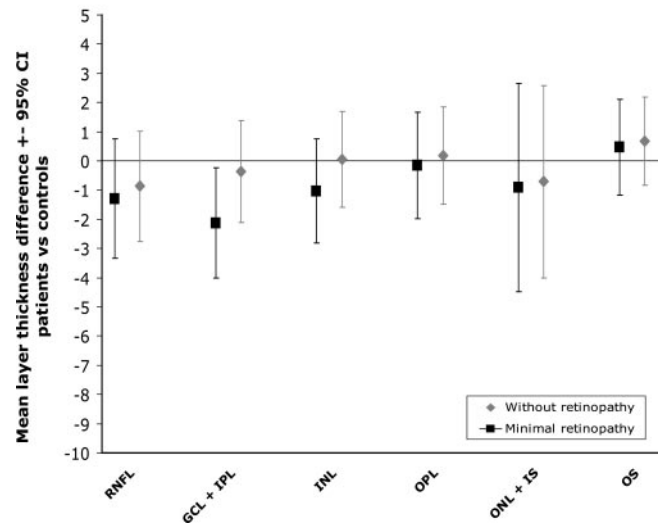


FIGURE 4. Mean LT differences (μm) and 95% CI between patients with type 1 diabetes with and without minimal DR and age-matched controls in the peripheral area of the macula.

elevated blood sugar levels, though the prevalence of diabetes at this age is low. In addition, the presence of undiagnosed diabetes would most likely have led to underestimation, not overestimation, of the difference in inner retinal thickness between patients and controls.

Stratus OCT is limited because only six scans are obtained that have to be interpolated over relatively large areas. With the advent of spectral domain OCT, regional differences in layer thickness can be determined more reliably. Although the faster scanning time and increased depth resolution of the spectral domain OCT allow for substantial improvement of retinal thickness mapping resolution, with fewer movement artifacts, there is no reason to believe that the outcome of this study would have been different if spectral domain OCT was used. It is, however, the next step to apply the segmentation algorithm to spectral-domain OCT volume scans of type 1 diabetic patients with no or minimal DR.

Although no direct relationship has been described, a layered structure of the retina, visible in histologic examination, is also present in OCT images by spatially separated intensity differences. Automated segmentation offers an objective, efficient method to quantify thickness of these individual retinal layers. As this study revealed, identification of separate retina layers and measurement of their thickness demonstrates that individual layers of the retina can be affected differently in certain diseases.

In summary, the decreased total RT most pronounced in the pericentral area in type 1 diabetic patients with minimal DR, compared to total RT in healthy controls, is attributed to a selective loss of thickness in the inner retinal layers and supports the concept that early DR includes a neurodegenerative component.

References

1. Brownlee M. Biochemistry and molecular cell biology of diabetic complications. *Nature*. 2001;414:813–820.
2. Abu-El-Asrar AM, Dralands L, Missotten L, et al. Expression of apoptosis markers in the retinas of human subjects with diabetes. *Invest Ophthalmol Vis Sci*. 2004;45:2760–2766.

Layer thickness difference in the pericentral area of the macula

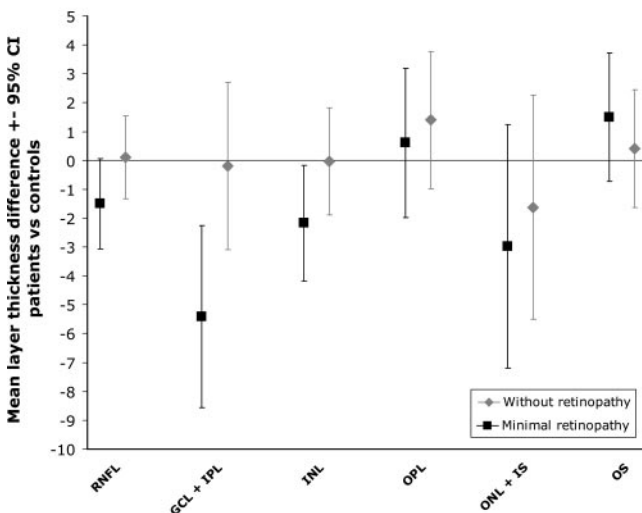


FIGURE 3. Mean LT differences (μm) and 95% CI between patients with type 1 diabetes with and without minimal DR and age-matched controls in the pericentral area of the macula.

3. Barber AJ, Lieth E, Khin SA, et al. Neural apoptosis in the retina during experimental and human diabetes: early onset and effect of insulin. *J Clin Invest.* 1998;102:783-791.
4. Barber AJ. A new view of diabetic retinopathy: a neurodegenerative disease of the eye. *Prog Neuropsychopharmacol Biol Psychiatry.* 2003;27:283-290.
5. Bloodworth JM Jr. Diabetic retinopathy. *Diabetes.* 1962;11:1-22.
6. Gastinger MJ, Singh RS, Barber AJ. Loss of cholinergic and dopaminergic amacrine cells in streptozotocin-diabetic rat and Ins2Akita-diabetic mouse retinas. *Invest Ophthalmol Vis Sci.* 2006;47:3143-3150.
7. Gastinger MJ, Kunselman AR, Conboy EE, et al. Dendrite remodeling and other abnormalities in the retinal ganglion cells of Ins2 Akita diabetic mice. *Invest Ophthalmol Vis Sci.* 2008;49:2635-2642.
8. Li Q, Puro DG. Diabetes-induced dysfunction of the glutamate transporter in retinal Muller cells. *Invest Ophthalmol Vis Sci.* 2002;43:3109-3116.
9. Lieth E, Barber AJ, Xu B, et al. Glial reactivity and impaired glutamate metabolism in short-term experimental diabetic retinopathy: Penn State Retina Research Group. *Diabetes.* 1998;47:815-820.
10. Lieth E, Gardner TW, Barber AJ, et al. Retinal neurodegeneration: early pathology in diabetes. *Clin Exp Ophthalmol.* 2000;28:3-8.
11. Martin PM, Roon P, Van Ells TK, et al. Death of retinal neurons in streptozotocin-induced diabetic mice. *Invest Ophthalmol Vis Sci.* 2004;45:3330-3336.
12. Mizutani M, Gerhardinger C, Lorenzi M. Muller cell changes in human diabetic retinopathy. *Diabetes.* 1998;47:445-449.
13. Park SH, Park JW, Park SJ, et al. Apoptotic death of photoreceptors in the streptozotocin-induced diabetic rat retina. *Diabetologia.* 2003;46:1260-1268.
14. Rungger-Brandle E, Dosso AA, Leuenberger PM. Glial reactivity, an early feature of diabetic retinopathy. *Invest Ophthalmol Vis Sci.* 2000;41:1971-1980.
15. Zeng XX, Ng YK, Ling EA. Neuronal and microglial response in the retina of streptozotocin-induced diabetic rats. *Vis Neurosci.* 2000;17:463-471.
16. Barber AJ, Antonetti DA, Kern TS, et al. The Ins2Akita mouse as a model of early retinal complications in diabetes. *Invest Ophthalmol Vis Sci.* 2005;46:2210-2218.
17. Bialosterski C, van Velthoven ME, Michels RP, et al. Decreased optical coherence tomography-measured pericentral retinal thickness in patients with diabetes mellitus type 1 with minimal diabetic retinopathy. *Br J Ophthalmol.* 2007;91:1135-1138.
18. Browning DJ, Fraser CM, Clark S. The relationship of macular thickness to clinically graded diabetic retinopathy severity in eyes without clinically detected diabetic macular edema. *Ophthalmology.* 2008;115:533-539.
19. Nilsson M, von Wendt G, Wanger P, Martin L. Early detection of macular changes in patients with diabetes using Rarebit Fovea Test and optical coherence tomography. *Br J Ophthalmol.* 2007;91:1596-1598.
20. Oshitari T, Hanawa K, Adachi-Usami E. Changes of macular and RNFL thicknesses measured by Stratus OCT in patients with early stage diabetes. *Eye.* 2009;23(4):884-889.
21. Fernandez DC, Salinas M, Puliafito A. Automated detection of retinal layer structures on optical coherence tomography images. *Opt Expr.* 2008;13:10200-10216.
22. Garvin MK, Abramoff MD, Kardon R, et al. Intraretinal layer segmentation of macular optical coherence tomography images using optimal 3D graph search. *IEEE Trans Med Imaging.* 2008;27:1495-1505.
23. Haeker M, Wu X, Abramoff M, et al. Incorporation of regional information in optimal 3D graph search with application for intraretinal layer segmentation of optical coherence tomography images. *Inf Process Med Imaging.* 2007;20:607-618.
24. Haeker M, Abramoff MD, Wu X, et al. Use of varying constraints in optimal 3D graph search for segmentation of macular optical coherence tomography images. *Med Image Comput Comput Assist Interv Int Conf.* 2007;10:244-251.
25. Haeker M, Sonka M, Kardon R, et al. Automated segmentation of intraretinal layers from macular optical coherence tomography images. *Proc SPIE Med Imag.* 2007;6512.
26. Ishikawa H, Stein DM, Wollstein G, et al. Macular segmentation with optical coherence tomography. *Invest Ophthalmol Vis Sci.* 2005;46:2012-2017.
27. Wilkinson CP, Ferris FL III, Klein RE, et al. Proposed international clinical diabetic retinopathy and diabetic macular edema disease severity scales. *Ophthalmology.* 2003;110:1677-1682.
28. Bearse MA Jr, Han Y, Schneck ME, et al. Local multifocal oscillatory potential abnormalities in diabetes and early diabetic retinopathy. *Invest Ophthalmol Vis Sci.* 2004;45:3259-3265.
29. Fortune B, Schneck ME, Adams AJ. Multifocal electroretinogram delays reveal local retinal dysfunction in early diabetic retinopathy. *Invest Ophthalmol Vis Sci.* 1999;40:2638-2651.
30. Greenstein VC, Shapiro A, Zaidi Q, et al. Psychophysical evidence for post-receptor sensitivity loss in diabetics. *Invest Ophthalmol Vis Sci.* 1992;33:2781-2790.
31. Han Y, Adams AJ, Bearse MA Jr, et al. Multifocal electroretinogram and short-wavelength automated perimetry measures in diabetic eyes with little or no retinopathy. *Arch Ophthalmol.* 2004;122:1809-1815.
32. Hardy KJ, Lipton J, Scase MO, et al. Detection of colour vision abnormalities in uncomplicated type 1 diabetic patients with angiographically normal retinas. *Br J Ophthalmol.* 1992;76:461-464.
33. Kurtenbach A, Fogel W, Erb C. Anomaloscope matches in patients with diabetes mellitus. *Graefes Arch Clin Exp Ophthalmol.* 2002;240:79-84.
34. Realini T, Lai MQ, Barber L. Impact of diabetes on glaucoma screening using frequency-doubling perimetry. *Ophthalmology.* 2004;111:2133-2136.
35. Shimada Y, Li Y, Bearse MA Jr, et al. Assessment of early retinal changes in diabetes using a new multifocal ERG protocol. *Br J Ophthalmol.* 2001;85:414-419.
36. Antonetti DA, Barber AJ, Bronson SK, et al. Diabetic retinopathy: seeing beyond glucose-induced microvascular disease. *Diabetes.* 2006;55:2401-2411.
37. Barber AJ, Nakamura M, Wolpert EB, et al. Insulin rescues retinal neurons from apoptosis by a phosphatidylinositol 3-kinase/Akt-mediated mechanism that reduces the activation of caspase-3. *J Biol Chem.* 2001;276:32814-32821.
38. Nakamura M, Barber AJ, Antonetti DA, et al. Excessive hexosamines block the neuroprotective effect of insulin and induce apoptosis in retinal neurons. *J Biol Chem.* 2001;276:43748-43755.
39. King GL, Brownlee M. The cellular and molecular mechanisms of diabetic complications. *Endocrinol Metab Clin North Am.* 1996;25:255-270.
40. Grading diabetic retinopathy from stereoscopic color fundus photographs—an extension of the modified Airlie House classification: ETDRS report number 10. Early Treatment Diabetic Retinopathy Study Research Group. *Ophthalmology.* 1991;98:786-806.