

Experimental Model to Evaluate Mechanical Closure Resistance of Sutureless Vitrectomy Sclerotomies Using Pig Eyes

Lorenzo Lopez-Guajardo,¹ Javier Benitez-Herreros,¹ and Agustin Silva-Mato²

PURPOSE. The purpose of this study was to report a novel model for comparing mechanical resistance to intraocular pressure (IOP) increases with 23-gauge (23G) and 25G transconjunctival sutureless vitrectomy (TSV) sclerotomies in the immediate postoperative period using an experimental model of a vitrectomized eye.

METHODS. This was a prospective, experimental, randomized, and observer-masked experimental study in which TSV 23G and 25G oblique sclerotomies, performed in same cadaveric pig eye, were subject to an increase in IOP. Mechanical resistance was determined by the resistance to intraocular fluid leak through the sclerotomy. The simultaneous use of the different sclerotomy diameters in the same eye avoided interindividual scleral resistance differences.

RESULTS. This animal model allowed comparison of the effect of different sclerotomy diameters (23G and 25G) on incisional mechanical resistance. One hundred twenty eyes were included. In 60.7% of cases, the 23G sclerotomy first allowed intraocular fluid escape (leaked; $P = 0.02$). When comparing opening pressure values, 23G sclerotomies leaked at significantly lower pressure levels than 25G sclerotomies ($P < 0.0001$); 53% of the 25G incisions but only 16% of 23G incisions opened at pressure levels greater than 120 mm Hg.

CONCLUSIONS. Oblique 23G sutureless sclerotomies offer less mechanical resistance to increases in IOP than do 25G sclerotomies. This animal model may become the basis for future studies to evaluate the advantages of using other types of incision or other surgical tools on sclerotomy closure capacity. (*Invest Ophthalmol Vis Sci.* 2011;52:4080–4084) DOI:10.1167/iov.10.6812

Transconjunctival sutureless vitrectomy (TSV) has progressively been adopted as the first-choice vitrectomy technique for an increasing number of vitreoretinal surgeons because of a series of advantages such as increased patient comfort with less postoperative inflammation, decreased operative times, and reduction in surgery-induced astigmatism. By comparison with traditional 20-gauge (20G) vitrectomy, wounds are self-sealing without the need for suturing because of the small-diameter sclerotomy created.

The initial report of TSV by Fujii et al.¹ used 25G caliber instruments introduced using a perpendicular (direct) sclerotomy. This incisional construction, when left with no sutures at the end of surgery, resulted in a number of incompetent closures. This could manifest as a progressively growing subconjunctival balanced salt solution (BSS; Alcon Laboratories, Inc. Fort Worth, TX) bleb formation if it occurred preoperatively (which would require suturing) or as postoperative hypotony (<5 mm Hg) in the following days.

In an attempt to improve the sclerotomy closure rate, a series of approaches were suggested. Air or gas filling of the vitreous cavity at the end of the procedure was used in an attempt to ameliorate superior sclerotomy closure.² In 2006, 25G oblique sclerotomy construction was introduced³ and seems to have been the most accepted solution. When we reviewed series using 25G oblique sclerotomies, we found that the percentage of patients requiring intraoperative suturing was very low: 0% in Hsu's series⁴ and 1% in Shimada's series.⁵

The 23G TSV was described by Eckardt⁶ in 2005. The initial description included oblique sclerotomy construction with a two-step technique. The increased diameter of the instrument allowed the resolution of some problems inherent in the 25G instrument, such as reduced flexibility, which allowed for better access to the peripheral vitreous, and better fluidics, with aspiration-infusion rates near those for the 20G instrument. These advantages, however, were obtained with an increase in the sclerotomy diameter from 0.61 mm to 0.74 mm,^{7,8} which seemed to result in higher rates of incompetent postoperative closure. This fact implied that a higher percentage of patients would require suturing of the sclerotomy at the end of surgery than after 25G oblique sclerotomy TSV. A review of the published 23G oblique sclerotomy series, in which suturing percentages range from 4%⁹ to 38%,¹⁰ supports this idea.

In the early postoperative period, nonsutured sclerotomies are subject to pressure stress, derived from blinking (10 mm Hg increase) and rubbing (up to 90 mm Hg increase).^{11,12} Studying the resistance of both diameters of TSV sclerotomy to increased IOP increase could aid in determining the safety profile of both types of sclerotomies before healing.¹³

We thus decided to compare the mechanical resistance of both 25G and 23G oblique sclerotomies. Given the lack of experimental studies that have analyzed the closure capacity of sclerotomies subjected to increased IOP, we developed an experimental method using a cadaveric animal model that would allow us to consider the scleral wall as a purely mechanical element without the contribution of the healing mechanisms of a live organism. This situation is similar to that encountered in patients during the first postoperative days, when the reparative mechanisms have not had time to act. Experimental studies with TSV place the appearance of healing tissue in the sclerotomy tract between the second and fifth postoperative days.¹²

From the ¹Ophthalmology Department, Hospital Universitario Príncipe de Asturias, Alcalá de Henares, Madrid, Spain; and the ²Department of Health and Sociomedical Sciences, Biostatistics Unit, Faculty of Medicine, Alcalá University, Madrid, Spain.

Submitted for publication October 31, 2010; revised February 18, 2011; accepted March 10, 2011.

Disclosure: **L. Lopez-Guajardo**, None; **J. Benitez-Herreros**, None; **A. Silva-Mato**, None

Corresponding author: Lorenzo López-Guajardo, Hospital Virgen de la Paloma, C/ Loma, 1, Madrid 28003, Spain; llguajardo@icam.es.

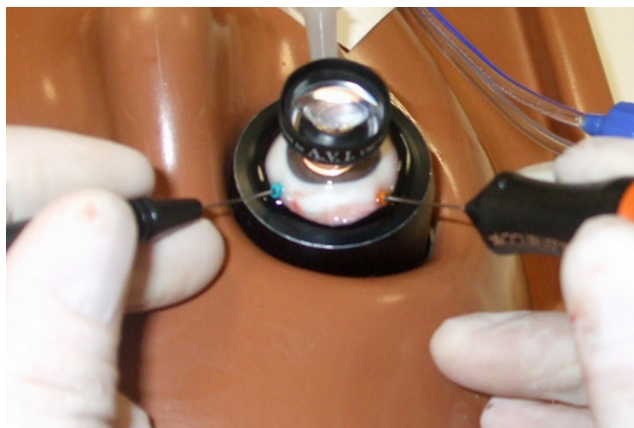


FIGURE 1. 23G and 25G cannulas in same pig eye, with the 23G vitrectomy probe in the dominant hand and the 25G light pipe in the nondominant hand. The shaft of the 21G locked needle is seen at 6 o'clock.

MATERIALS AND METHODS

Our prospective, experimental, randomized, and observer-masked study was performed between June and December 2009. We used 131 pig eyes; 11 had to be discarded because of several reasons (intraoperative retinal detachment, crystalline lens dislocation in vitreous cavity, obvious scleromalacia, leakage of the fourth sclerotomy); hence, 120 eyes were finally included in the study. The pig species was *Sus scrofa domesticus* (weight range, 65–80 kg), whose eyes are similar to human eyes in scleral thickness.¹⁴ Histology confirmed the similarity between human and porcine scleras, although more disorganized collagen bundles have been found in porcine sclera.¹⁵

All globes were obtained 3 hours after pig kill and were kept in cold storage at 4°C before use. Given that the eyes were obtained from pigs killed for human consumption from a regulated slaughterhouse, no statements for the use of animals in ophthalmic research are applicable.

In each eye, superior sclerotomies were performed using the 23G and 25G TSV systems (Alcon Laboratories, Fort Worth, TX) alternately so that 60 eyes underwent vitrectomy performed with a 25G probe and 60 with a 23G probe (Fig. 1). Both superior sclerotomies were performed with an oblique technique 4 mm from the limbus in a manner similar to that previously described by one of the authors.³ The trocar used is a one-face beveled trocar that creates a V-shaped incision. With the aim of equalizing the fluidics of all eyes at the moment in which we evaluated the mechanical resistance of the sclerotomies at different IOPs, infusion was always introduced through a 23G cannula. A 21G locked needle was introduced through the pars plana in the 6 o'clock meridian (fourth sclerotomy) to allow clear BSS to be exchanged with a 1% methylene blue solution after vitrectomy. A three-way stopcock was placed in the infusion line to allow the infusion to be switched from the BSS bottle to the syringe containing the 1% methylene blue solution (Fig. 2).

Vitrectomy (performed by L.L.G.) performed with a vitrectome (Accurus; Alcon Laboratories) was considered complete when the vitreous cavity was judged optically empty by the surgeon and BSS flowed freely through both the superior cannulas and the inferior 21G needle (see Supplementary Movie, <http://www.iovs.org/lookup/suppl/doi:10.1167/iovs.10-6812/-/DCSupplemental>). Then the superior cannulas was extracted, and BSS-methylene blue-dyed solution was introduced into the eye through the infusion cannula, evacuating clear BSS through the 21G needle (fourth sclerotomy), taking care to increase IOP minimally (Fig. 3). In this way, no blue dye escaped through the recently closed superior sclerotomies. Once the exchange was complete, (blue dye came out of the 21G needle; see Supplementary Movie), the 21G needle was locked again with a plastic cap, thus obtaining a closed eye with an infusion line.

The infusion line was connected again to the BSS bottle, and pressure was gradually increased in 5-mm Hg steps using vented gas forced infusion (VGFI; Accurus; Alcon Laboratories) until one of the sclerotomies opened, allowing internal ocular blue-dyed solution to escape (Fig. 4). This was readily detected by the appearance of a blue bleb at the level of the sclerotomy (Fig. 5) or directly by a blue fluid escape flow (see Supplementary Movie, <http://www.iovs.org/lookup/suppl/doi:10.1167/iovs.10-6812/-/DCSupplemental>). In some cases when 120 mm Hg was reached, no sclerotomy had yet opened, so pressure was increased by direct contact with a pressure source until one of the sclerotomies opened. This maneuver implied that values greater than 120 mm Hg could not be precisely quantified, and, as we will see later, an arbitrary value was given for statistical purposes (Fig. 6).

The second author determined the moment of leakage and included all results in a database (e.g., which sclerotomy was the first to leak intraocular fluid [23G or 25G] and IOP leakage level).

Statistical Analysis

For all statistical tests, 5% was considered the significance level ($P < 0.05$). Eyes in which the 23G sclerotomy leaked first (compared with 25G) were studied using the one-sample proportion test. Confidence interval was estimated at 95% (95% CI).

To compare the differences in IOP values at which each diameter (23G vs. 25G) of sclerotomy leaked, we used the nonparametric Mann-Whitney *U* test; pressures higher than 120 mm Hg could not be quantified consistently, and, thus, a *t*-test was not possible.

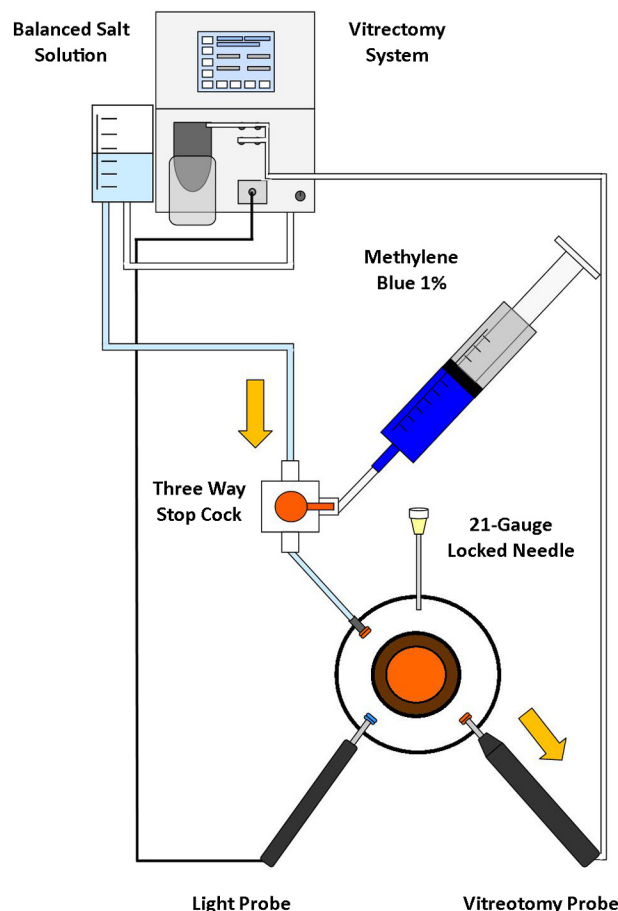


FIGURE 2. Schematic figure of the circuit during the vitrectomy phase. *Arrows:* direction of the fluid at different points.

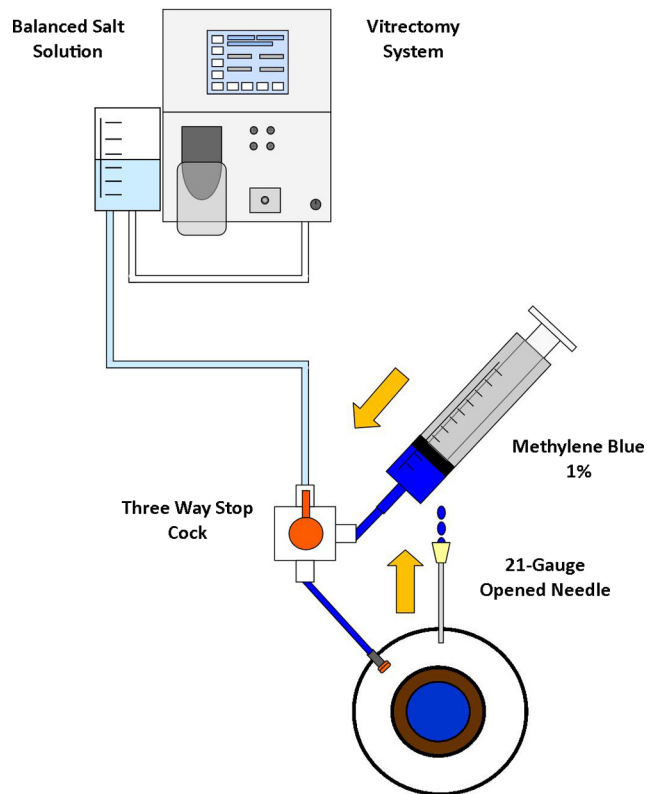


FIGURE 3. Schematic figure of the circuit during the exchange of BSS with 1% methylene blue solution. *Arrows*: direction of the fluid at different points.

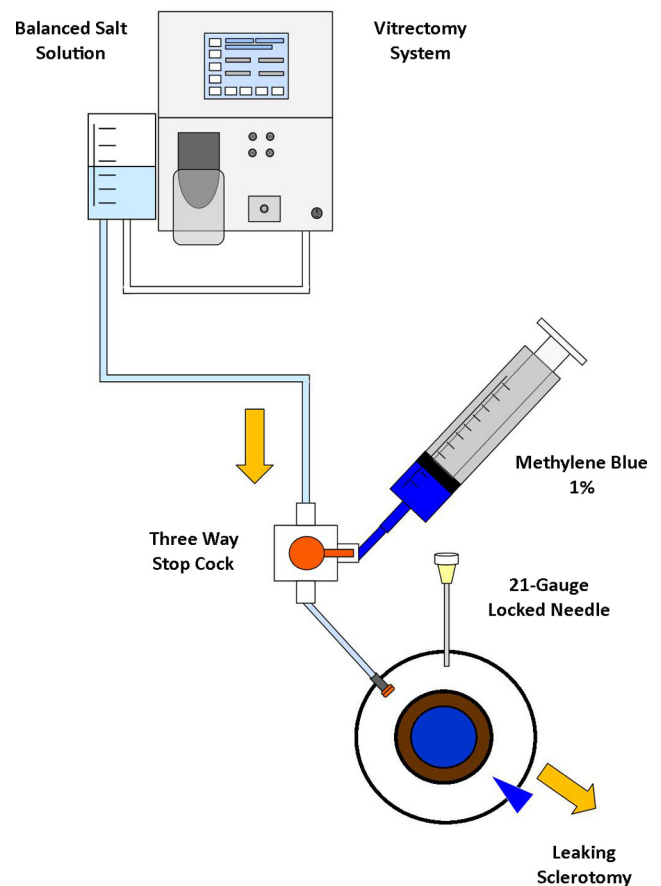


FIGURE 4. Schematic figure of the circuit during the IOP increase using the VGFI system. *Arrows*: direction of the fluid at different points.

RESULTS

This animal model has allowed us to compare the effect of different sclerotomy diameters (23G and 25G) on the incisional mechanical resistance.

In 73 of 120 eyes (60.1%; 95% CI, 51.7%–70.0%), the 23G sclerotomy opened first, when IOP was increased ($P = 0.02$; one-sample proportion test) (Fig. 6).

When we studied IOP values, 23G sclerotomies opened at a significantly lower level than 25G sclerotomies ($P < 0.0001$, Mann-Whitney U test) (Fig. 6). The percentage of sclerotomies opening at pressure levels greater than 120 mm Hg was 53% (25 of 47) in the 25G incision group and only 16% (12 of 73) in the 23G group (Fig. 6).

DISCUSSION

Our experimental model allowed us to compare the effect of different sclerotomy diameters (23G and 25G) on incisional mechanical resistance. This model has shown us some positive points. First, the use of the same tools and surgical procedures that are used in humans helped us simulate the real conditions we find in our usual surgical practice. Second, the use of pig eyes, which are very similar to human eyes and are easy to obtain, allowed us to include a great number of vitrectomized eyes. Third, the use of the VGFI of the vitrectomy system is an objective and quantitative method for the control of IOP included in the vitrectomy unit, so no new material was needed. Therefore, we can assume that this animal model, as well as allowing us to evaluate the effect of the different gauges on sclerotomy competency, may become the basis for future studies to evaluate the effect of other types of incisions or other surgical instruments on sclerotomy closure capability.

Despite the morphologic similarities between human eyes and pig eyes (as can be seen in Fig. 7), the absolute IOP values at which sclerotomies showed leakage should not be considered the main conclusion of our study. Our clinical experience has shown us that in human eyes, the IOP level at which sutureless sclerotomy leaks is lower. The important outcome is the relative difference between the 23G and the 25G sclerotomy leakage values.

The conclusion of this study is that there is a significant difference in IOP level at which the different gauges first open.

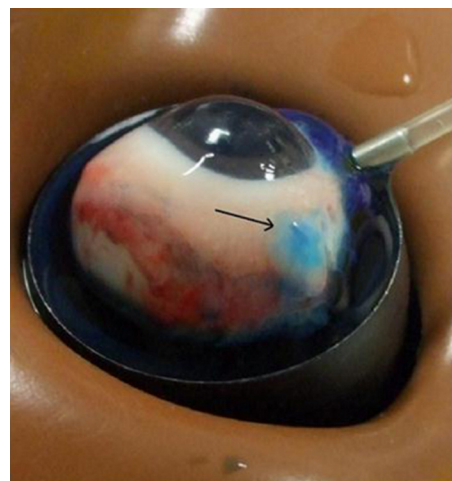


FIGURE 5. Blue subconjunctival bleb (*arrow*).

Thus, when changing from 25G to 23G vitrectomy, the surgeon has to assume an increase in the incidence of sclerotomy leakage. To obtain similar closure standards between both gauges, the surgeon should probably be prepared to perform more sclerotomy suturing with 23G vitrectomy.

The period during which the results of our study were valid in real clinical practice was limited to the time frame between the retrieval of the cannula and the development of the healing mechanisms because we only study mechanical resistance to increased IOP. No reparative mechanisms occurred in our experimental model because we used cadaveric eyes. This period has been established between the second and fifth days after sclerotomy¹² in experimental models of TSV vitrectomy. Other experimental models of scleral incisions offer similar results.¹⁶ In humans, healing chronology in TSV has been established primarily through indirect imaging methods; ultrasound biomicroscopy and anterior segment optical coherence tomography (Visante; Carl Zeiss, Oberkochen, Germany) are the most frequently used methods. In these imaging studies, the moment healing began could not be well established; what could be established was when the process was completed, manifested by the disappearance of the incisional gap. In this sense, studies by Rizzo¹⁷ established the healing period of oblique sclerotomies around 7 days. Other studies place this time frame between 7 and 15 days.¹⁸

The fact that our study was applicable only during the few first preoperative days was no less important because studies related to post-TSV endophthalmitis place the mean postoperative day for infection appearance around the third day.^{19,20} Thus, bacteria ingress can only have occurred during surgery or in the early postoperative days, when incision closure was primarily dependent on mechanical factors. India ink particles studies (whose size is similar to that of bacteria) have demonstrated postoperative ingress into the eye after straight sutureless sclerotomies in microincisional vitrectomy both in experimental²¹ and in human cadaveric eyes.²²

The trocar used, as we have mentioned earlier, creates a V-shaped incision. We have not used new trocar designs for TSV (beveled at both sides) or two-step TSV systems (knife used for sclerotomy), each of which creates a slit-shaped sclerotomy. Series published using slit-shaped sclerotomies reveal

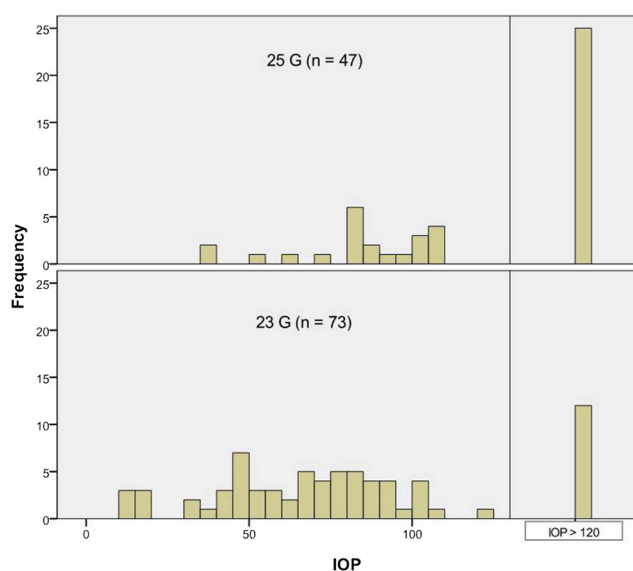


FIGURE 6. Leaking IOP values for 23G and 25G sclerotomies. *Top:* eyes in which 25G sclerotomy opened first; *bottom:* eyes in which 23G sclerotomy opened first. Number of eyes are shown on the y-axis, and pressure values (5-mm Hg steps) are shown on the x-axis.

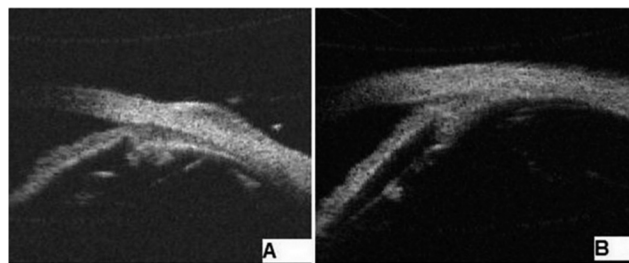


FIGURE 7. Two ultrasound biomicroscopy images in which structural similarities can be appreciated. (A) Pig eye. (B) Human eye.

better closure properties for both 25G²³ and 23G.²⁴ We do not know whether this change in incisional shape could make 23G sclerotomies as mechanically resistant as 25G sclerotomies to IOP increases.

Our study reports the development of an animal model that can be used to study sclerotomy closure properties. Based on this animal model, we have concluded that an increase in the sclerotomy diameter from 25G to 23G is related to less mechanical resistance when IOP is increased. These results may well be translated to human eye surgery. To achieve a similar closure rate between 25G and 23G TSV vitrectomy, surgeons should be prepared to perform a higher number of sutures on 23G oblique TSV sclerotomies.

References

- Fujii GY, de Juan E, Humayun MS, et al. A new 25-gauge instrument system for transconjunctival sutureless vitrectomy surgery. *Ophthalmology*. 2002;109:1807-1812.
- Charles S. Wound construction issues for microincisional vitrectomy surgery. Available at: www.opthalmic.hyperguides.com. Accessed April 25, 2009.
- Lopez-Guajardo L, Pareja-Esteban J, Teus-Guezala MA. Oblique sclerotomy technique for prevention of incompetent wound closure in transconjunctival 25-gauge vitrectomy. *Am J Ophthalmol*. 2006;141:1154-1156.
- Hsu J, Chen E, Gupta O, Fineman MS, Garg SJ, Regillo CD. Hypotony after 25-gauge vitrectomy using oblique versus direct cannula insertions in fluid-filled eyes. *Retina*. 2008;28:937-940.
- Shimada H, Nakashizuka H, Mori R, Mizutani Y, Hattori T. 25-gauge scleral tunnel transconjunctival vitrectomy. *Am J Ophthalmol*. 2006;142:871-873.
- Eckardt K. Transconjunctival sutureless 23-gauge vitrectomy. *Retina*. 2005;25:208-211.
- Singh RP, Bando H, Brasil OF, Williams DR, Kaiser PK. Evaluation of wound closure using different incision techniques with 23-gauge and 25-gauge microincision vitrectomy systems. *Retina*. 2008;28:242-248.
- Micro-incision vitrectomy surgery: a paradigm shift in modern vitreoretinal surgery: EuroTimes Satellite Educational Symposium. *EuroTimes Supplement*. 2007:1-10.
- Parolini B, Prigione G, Romanelli F, Cereda MG, Sartore M, Pertile G. Postoperative complications and intraocular pressure in 943 consecutive cases of 23-gauge transconjunctival pars plana vitrectomy with 1-year follow-up. *Retina*. 2010;30:107-111.
- Chieh JJ, Rogers AH, Wiegand TW, Baumall CR, Reichel E, Duker JS. Short-term safety of 23-gauge single-step transconjunctival vitrectomy surgery. *Retina*. 2009;29:1486-1490.
- Miller D. Pressure of the lid on the eye. *Arch Ophthalmol*. 1967;78:328-330.
- Coleman DJ, Trokel S. Direct-recorded intraocular pressure variations in a human subject. *Arch Ophthalmol*. 1969;82:637-640.
- Zhengyu S, Fang W, Ying F, Qinghua Q. The experimental research of rabbit's sclerotomy sites undergoing transconjunctival sutureless vitrectomy. *Curr Eye Res*. 2007;32:647-652.
- Olsen TW, Sanderson S, Feng X, Hubbard WC. Porcine sclera: thickness and surface area. *Invest Ophthalmol Vis Sci*. 2002;43:2529-2532.

15. Nicoli S, Ferrari G, Quarta M, et al. Porcine sclera as a model of human sclera for in vitro transport experiments: histology, SEM, and comparative permeability. *Mol Vis*. 2009;15:259-66.
16. Hikichi T, Yoshida A, Hasegawa T, Ohnishi M, Sato T, Muraoka S. Wound healing of scleral self-sealing incision: a comparison of ultrasound biomicroscopy and histology findings. *Graefes Arch Clin Exp Ophthalmol*. 1998;236:775-778.
17. Rizzo S, Genovesi-Ebert F, Vento A, Miniaci S, Cresti F, Palla M. Modified incision in 25-gauge vitrectomy in the creation of a tunneled airtight sclerotomy: an ultrabiomicroscopic study. *Graefes Arch Clin Exp Ophthalmol*. 2007;245:1281-1288.
18. López-Guajardo L, Vleming-Pinilla E, Pareja-Esteban J, Teus-Guezala MA. Ultrasound biomicroscopy study of direct and oblique 25-gauge vitrectomy sclerotomies. *Am J Ophthalmol*. 2007;143:881-883.
19. Kunitomo DY, Kaiser RS. Incidence of endophthalmitis after 20- and 25-gauge vitrectomy. *Ophthalmology*. 2007;114:2133-2137.
20. Scott IU, Flynn HW Jr, Dev S, et al. Endophthalmitis after 25-gauge and 20-gauge pars plana vitrectomy: incidence and outcomes. *Retina*. 2008;28:138-142.
21. Taban M, Ventura AA, Sharma S, Kaiser PK. Dynamic evaluation of sutureless vitrectomy wounds: an optical coherence tomography and histopathology study. *Ophthalmology*. 2008;115:2221-2228.
22. Gupta OP, Maguire JI, Eagle RC Jr, Garg SJ, Gonye GE. The competency of pars plana vitrectomy incisions: a comparative histologic and spectrophotometric analysis. *Am J Ophthalmol*. 2009;147:243-250.
23. Inoue M, Shinoda K, Shinoda H, Suzuki K, Kawamura R, Ishida S. 25-gauge cannula system with microvitorectinal blade trocar. *Am J Ophthalmol*. 2007;144:302-304.
24. Inoue M, Shinoda K, Hirakata A. Twenty-three gauge cannula system with microvitorectinal blade trocar. *Br J Ophthalmol*. 2010;94:498-502.