

The Anti-inflammatory Effects of *Curcuma longa* and *Berberis aristata* in Endotoxin-Induced Uveitis in Rabbits

Suresh Kumar Gupta,¹ Renu Agarwal,¹ Sushma Srivastava,¹ Puneet Agarwal,¹ Shyam Sunder Agrawal,¹ Robit Saxena,² and Niranjana Galpalli¹

PURPOSE. To investigate the anti-inflammatory effect of topical application of *Curcuma longa* (*C. longa*) and *Berberis aristata* (*B. aristata*) aqueous extracts on experimental uveitis in the rabbit.

METHODS. Anterior uveitis was induced in rabbits by intravitreal injection of lipopolysaccharide from *Escherichia coli* after pre-treatment with *C. longa* and *B. aristata* aqueous extracts. Subsequently, the anti-inflammatory activity of *C. longa* and *B. aristata* was evaluated by grading the clinical signs and histopathologic changes and estimating the inflammatory cell count, protein, and TNF- α levels in the aqueous humor.

RESULTS. The anterior segment inflammation in the control group was significantly higher than in both the extract-treated groups, as observed by clinical and histopathologic grading. The inflammatory cell count in the control group was $30.75 \pm 7.33 \times 10^5$ cells/mL, whereas it was $2.39 \pm 0.59 \times 10^5$ ($P < 0.001$ vs. control) and $11.56 \pm 2.44 \times 10^5$ ($P = 0.001$ vs. control) cells/mL in the *C. longa*- and *B. aristata*-treated groups, respectively. The protein content of the aqueous humor was 18.14 ± 4.98 , 3.16 ± 0.55 ($P < 0.001$ vs. control), and 8.24 ± 1.42 ($P < 0.01$ vs. control) mg/mL in the control, *C. longa*-, and *B. aristata*-treated groups, respectively. The aqueous TNF- α level in the control group was 976.29 ± 66.38 pg/mL and was 311.96 ± 28.50 ($P < 0.0001$ vs. control) and 654.09 ± 47.66 ($P < 0.001$ vs. control) pg/mL in the *C. longa*- and *B. aristata*-treated groups, respectively.

CONCLUSIONS. Topical instillation of aqueous extracts of *C. longa* and *B. aristata* showed potent anti-inflammatory activity against endotoxin-induced uveitis in rabbits. (*Invest Ophthalmol Vis Sci.* 2008;49:4036–4040) DOI:10.1167/iovs.07-1186

The animal model of endotoxin-induced uveitis has often been used to represent acute anterior uveitis in humans. Lipopolysaccharide (LPS), a glycolipid from the outer cell membranes of Gram-negative bacteria is a proinflammatory component and is used to induce uveitis in animals by a systemic or ocular route.^{1,2} Exposure to LPS induces expres-

sion of various mediators of inflammation such as tumor necrosis factor (TNF)- α and other cytokines.^{3–5} Increased expression of inflammatory mediators contributes to the development of anterior uveitis, with the breakdown of the blood-ocular barrier leading to infiltration of the aqueous humor with inflammatory cells and the leakage of protein.⁶ Experimental uveitis peaks at 24 hours after LPS injection and gradually subsides over the next 24 hours.

Curcuma longa (*C. longa*) and *Berberis aristata* (*B. aristata*) are two among the many herbs that have been widely used in traditional medicine for centuries. Turmeric, the powdered form of the rhizome of *C. longa* is rich in curcuminoids. Among the curcuminoids, curcumin is the major phenolic component in the rhizomes of *C. longa*. The roots of *B. aristata* contain significant amounts of the isoquinoline alkaloid berberine. Both the herbs are well known for their anti-inflammatory activity. The aqueous extract of the roots of *B. aristata* (500–1000 mg/kg) was found to have a significant anti-inflammatory effect in rats with carrageenan-induced paw edema; the effect was comparable to that of 10 mg diclofenac sodium.⁷ The alkaloid berberine from *B. aristata* has antibacterial effects and has been found to be useful in cases of trachoma.⁸ Berberine has also been found to be effective in experimental herpetic uveitis.⁹ Berberine was also shown to abolish acetaldehyde-induced NF- κ B activity and cytokine production in HepG2 cells in a dose-dependent manner.¹⁰ Extracts of *C. longa* have also exhibited anti-inflammatory effects in standard animal models used for testing anti-inflammatory activity.^{11–13} Curcumin, a major chemical constituent of *C. longa* was found to inhibit leukotriene formation in rat peritoneal polymorphonuclear neutrophils.¹⁴ Possible benefits of oral curcumin supplementation have been observed in cases of chronic anterior uveitis.¹⁵ As in the case of berberine, curcumin exhibits an ability to suppress NF- κ B activity and cytokine production in experimental acute liver injury.¹⁶ In view of the potent anti-inflammatory activity of *C. longa* and *B. aristata*, the present study was designed to investigate the effect of topical application of their aqueous extracts in endotoxin-induced uveitis.

From the ¹Department of Pharmacology, Delhi Institute of Pharmaceutical Sciences and Research, New Delhi, India; and the ²Dr. R. P. Center for Ophthalmic Sciences, All India Institute of Medical Sciences, New Delhi, India.

Supported by Grant VII-PRDSF/15/04–05/TT from the Department of Science and Technology, Government of India.

Submitted for publication September 11, 2007; revised February 26, 2008; accepted July 1, 2008.

Disclosure: S. Gupta, None; R. Agarwal, None; S. Srivastava, None; P. Agarwal, None; S. Agrawal, None; S. Rohit, None; N. Galpalli, None

The publication costs of this article were defrayed in part by page charge payment. This article must therefore be marked “advertisement” in accordance with 18 U.S.C. §1734 solely to indicate this fact.

Corresponding author: Suresh Gupta, Department of Pharmacology, Delhi Institute of Pharmaceutical Sciences and Research, Pushp Vihar Sector-3, M B Road, New Delhi 110017, India; skgupta@icriindia.com.

MATERIALS AND METHODS

All procedures were conducted according to the ARVO Statement for the Use of Animals in Ophthalmic and Vision Research. New Zealand White rabbits weighing 2.5 to 3 kg were obtained from the animal house facility at Delhi Institute of Pharmaceutical Sciences and Research. The aqueous extracts of *C. longa* (rhizome) and *B. aristata* (roots) were provided by Promed Exports Pvt Ltd. (New Delhi, India) and were authenticated by high-performance thin-layer chromatography (HPTLC) fingerprinting. The powdered extracts were dissolved in 0.25% hydroxy propyl methylcellulose and filtered with 0.22- μ m filters (Millipore, Billerica, MA). The filtrate was stored at -4°C in sterile sealed vials until further use.

Study Design

The rabbits were divided into three groups of four rabbits each (eight eyes). The rabbits in groups 1 and 2 were topically instilled with 0.1% *C. longa* and 2% *B. aristata* aqueous extract, respectively, while group 3 (control group) received the vehicle. All instillations were performed three times a day for 3 days before induction of experimental uveitis and continued for 3 days after induction. Twenty-four hours after the induction of experimental uveitis, aqueous humor sampling was performed for cell count, protein, and TNF- α estimation. The rabbits were reexamined 72 hours after the endotoxin injection for clinical signs of uveitis and then were killed and the eyes enucleated for histopathologic examination.

Rabbit Model of Experimental Uveitis

The endotoxin used to induce uveitis was lipopolysaccharide (LPS) from *Escherichia coli* (Sigma-Aldrich, St. Louis, MO). The endotoxin was injected intravitreally in both eyes. One drop of proparacaine HCl (0.5%) solution was used for topical anesthesia. After the upper lid was retracted, 20 μ L (100 ng) of the endotoxin solution was injected intravitreally at the 12 o'clock position, 3 to 4 mm posterior to the limbus with a 30-gauge needle. Preliminary dose-response studies were undertaken, and 100 ng was found to be the optimal dose for induction of uveitis in rabbits. Subsequently, the eyes were examined for clinical grading, and aqueous humor was tapped for inflammatory cell count, protein, and TNF- α estimation. The person performing aqueous humor sampling, cell count, protein, and TNF- α estimation was masked to the treatment given. The rabbits were killed after clinical assessment for signs of uveitis, 72 hours after experimental induction of uveitis.

Clinical Grading of Ocular Inflammation

The clinical signs of ocular inflammation were graded on a scale of 0 to 4 according to the scoring system described by Ruiz-Moreno et al.¹⁷ The grading scale was as follows: no inflammatory reaction, 0; discrete inflammatory reaction, 1; moderate dilation of the iris and conjunctival vessels, 2; intense iridal hyperemia, with flare in the anterior chamber, 3; and the

same clinical signs as grade 3 plus the presence of fibrinoid exudation in the pupillary area, with intense flare in the anterior chamber, 4.

The grading of clinical signs of uveitis was performed at 24 and 72 hours after intravitreal injection of endotoxin.

Aqueous Humor Sampling

The animals were anesthetized with ketamine (20–40 mg/kg) and xylazine (1–2 mg/kg) by intramuscular injection in the hind limb. Proparacaine HCl (0.5%) solution was used topically to supplement the general anesthesia. During preliminary studies, attempts at aqueous humor (AH) sampling under topical anesthesia were found to be very painful and therefore further AH sampling was performed under general anesthesia. AH (150–200 μ L) was aspirated from the anterior chamber with a 30-gauge disposable insulin syringe, and care was taken not to injure the iris or lens during the procedure. Each aqueous humor sample was diluted 50-fold with PBS.

Total Cell Count

The AH sample was suspended in an equal volume of Turk's stain solution and cell counting was performed on a hemocytometer under light microscope. The cell count per field (each field considered equal to 0.1 mL) was estimated as an average of counts in four fields per sample. Subsequently, the number of cells per milliliter of AH was calculated.

Total Protein Estimation

Protein estimation in AH samples was performed according to the method described by Lowry et al.¹⁸ Briefly, 10 μ L of AH sample was diluted with 990 μ L of 1 N NaOH and reacted with 5 mL of copper reagent. After 10 minutes, 0.5 mL of Folin's reagent was added and vortexed, and the samples were kept in the dark for 30 minutes. Absorbance was recorded with a spectrophotometer at 620 nm. Bovine serum albumin (BSA) was taken as a protein standard to calculate the protein content of the sample. All estimations were performed in duplicate.

The cell count and protein estimation were performed on the day of AH sampling.

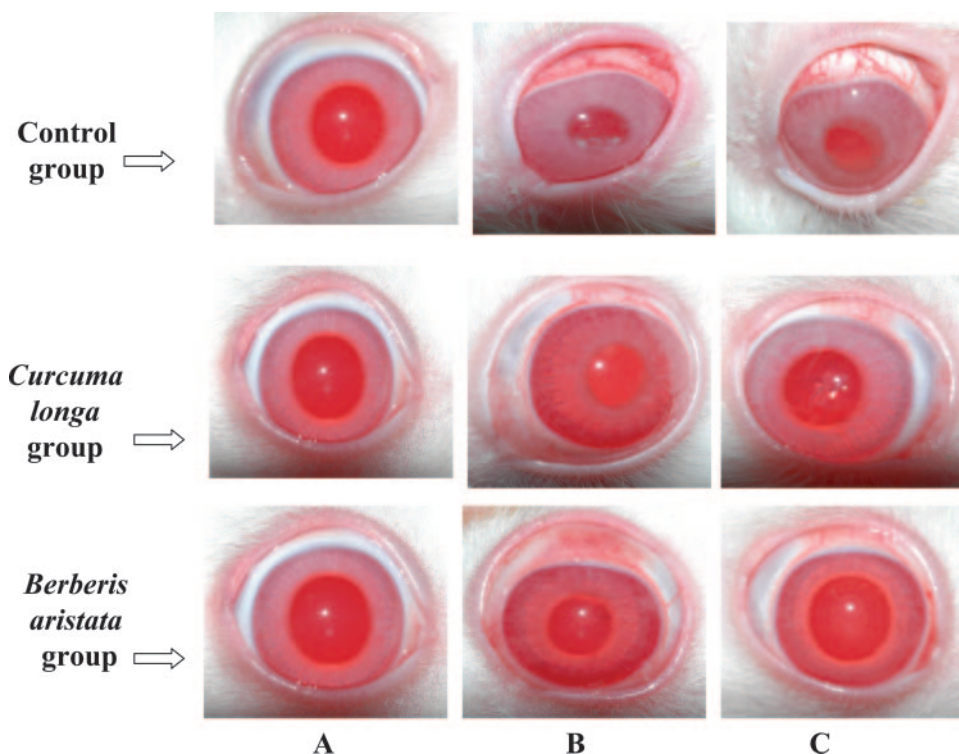


FIGURE 1. Clinical signs of anterior uveitis in control and treated groups. (A) Just before intravitreal endotoxin injection. (B) Twenty-four and (C) 72 hours after intravitreal endotoxin injection.

TNF- α Estimation

TNF- α levels in AH were estimated by using a commercially available enzyme-linked immunosorbent assay (ELISA) kit from Diaclone (Besançon, France), per the manufacturer's instructions. All estimations were performed in duplicate.

Histopathologic Examination

The rabbits' eyes were enucleated 72 hours after intravitreal injection of endotoxin and fixed in 10% formaldehyde. The sections (6–8 μ m thick) were stained with hematoxylin and eosin, and the structures in the immediate vicinity of endotoxin injection (i.e., anterior chamber, posterior chamber, and ciliary body) were evaluated for severity of vasodilatation, edema, and inflammatory cell infiltration. The inflammatory changes were graded on a scale of 0 to 5: none, 0; minimum, 1; discrete, 2; moderate, 3; severe, 4; and intense, 5.

RESULTS

Clinical Signs of Uveitis

The rabbits in the control group showed significantly higher grades of ocular inflammation than did the *C. longa*- and *B. aristata*-treated groups (Fig. 1). At 24 hours after intravitreal injection of endotoxin, the vehicle-treated control group had a mean score of 2.75 ± 0.56 (range, 2–4), whereas the *C. longa*- and *B. aristata*-treated groups showed a mean score of 1.13 ± 0.48 (range, 0–2) and 2.00 ± 0.41 (range, 1–3), respectively, at the same time point (Fig. 2). Clinical signs of uveitis observed at 72 hours after endotoxin injection are shown in Table 1.

Total Cell Count

C. longa- and *B. aristata*-treated groups showed a 92.24% and 62.40% inhibition of inflammatory cell infiltration, respectively, compared with that in the control group. In the control group, the total inflammatory cell count in the aqueous humor 24 hours after intravitreal injection of endotoxin was $30.75 \pm 7.33 \times 10^5$ cells/mL (mean \pm SD, $n = 8$). The rabbits pretreated with *C. longa* and *B. aristata* showed significantly lower inflammatory cell counts ($2.39 \pm 0.59 \times 10^5$ cells/mL, $P < 0.001$ vs. control; and $11.56 \pm 2.44 \times 10^5$ cells/mL, $P = 0.001$ vs. control) in the aqueous humor obtained at the same time point. In addition, a significantly lower inflammatory cell infiltration was observed in the *C. longa*-treated group than in the *B. aristata*-treated group ($P < 0.001$; Fig. 3).

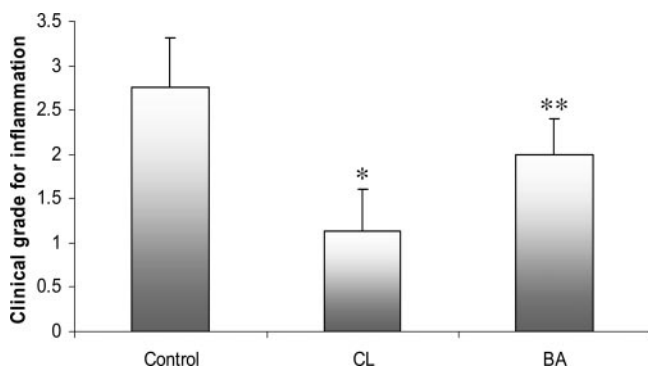


FIGURE 2. The effect of topical instillation of aqueous extract of *C. longa* (CL; 0.1%) and *B. aristata* (BA; 2%) on the development of inflammatory signs in rabbits with experimental uveitis. The grading of clinical signs of uveitis was done 24 hours after intravitreal injection. All data are expressed as the mean \pm SD. * $P < 0.01$ vs. control; ** $P < 0.05$ vs. control ($n = 8$).

TABLE 1. The Histopathologic and Clinical Score of Rabbit Eyes 72 Hours after Intravitreal Injection of Endotoxin

Groups	Histopathologic Score	Clinical Score
Control	4.38 ± 0.41	2.75 ± 0.56
<i>C. longa</i>	$1.13 \pm 0.54^{*\dagger}$	$0.75 \pm 0.25^{*\dagger}$
<i>B. aristata</i>	$2.13 \pm 0.41^*$	$1.63 \pm 0.41^{\ddagger}$

All values are group mean \pm SD.

* $P < 0.001$ vs. control.

$\dagger P < 0.05$ vs. *B. aristata* group.

$\ddagger P < 0.01$ vs. control.

Total Protein

Total proteins as estimated 24 hours after intravitreal injection of endotoxin showed significantly lower values in the extract-treated groups. In the *C. longa*-treated group the protein concentration was 3.16 ± 0.55 mg/mL compared with 8.24 ± 1.42 and 18.14 ± 4.98 mg/mL in the *B. aristata*-treated and control groups, respectively. The protein concentration in the *C. longa*-treated group was significantly lower than in the *B. aristata*-treated group ($P < 0.001$) and control group ($P < 0.001$). The aqueous humor protein concentration in the *B. aristata*-treated group was also significantly lower than in the control group ($P < 0.01$; Fig. 4).

Tumor Necrosis Factor- α

Aqueous humor TNF- α levels in *C. longa*- and *B. aristata*-treated rabbits showed 68.05% and 33% lower values, respectively, compared with the control. The aqueous humor TNF- α level in the control group was 976.29 ± 66.38 pg/mL, whereas it was 311.96 ± 28.50 ($P < 0.0001$ vs. control) and 654.09 ± 47.66 ($P < 0.001$ vs. control) pg/mL in the *C. longa*- and *B. aristata*-treated groups, respectively. The TNF- α level in the *C. longa*-treated group was significantly lower than in the *B. aristata*-treated group ($P < 0.0001$; Fig. 5).

Histopathologic Evaluation

The histopathologic examination of all eight rabbit eyes in the control group showed severe inflammatory changes with interstitial edema, vasodilatation, and extensive inflammatory cell infiltration of the anterior chamber, posterior chamber, and ciliary body. The mean histopathologic grade in the control group was found to be 4.38 ± 0.41 (range, 3–5). In the *C.*

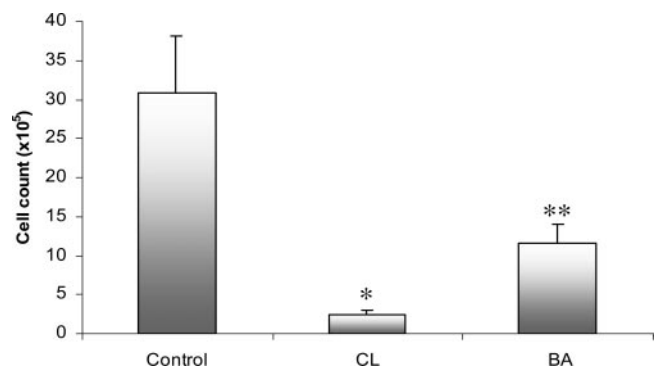


FIGURE 3. The effect of topical instillation of aqueous extract of *C. longa* (CL; 0.1%) and *B. aristata* (BA; 2%) on inflammatory cell infiltration in rabbits with experimental uveitis. The aqueous humor was collected 24 hours after intravitreal injection of endotoxin. All values are expressed as the mean \pm SD. * $P < 0.001$ vs. control and BA, ** $P < 0.05$ versus control ($n = 8$).

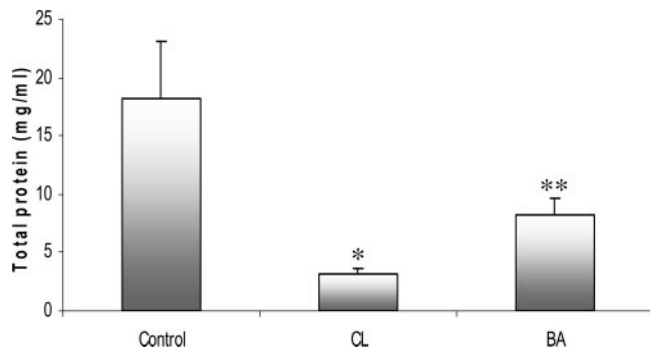


FIGURE 4. The effect of topical instillation of aqueous extract of *C. longa* (CL; 0.1%) and *B. aristata* (BA; 2%) on protein concentration in aqueous humor in rabbits with experimental uveitis. All values are expressed as the mean \pm SD. * $P < 0.001$ vs. control and BA; ** $P < 0.05$ vs. control ($n = 8$).

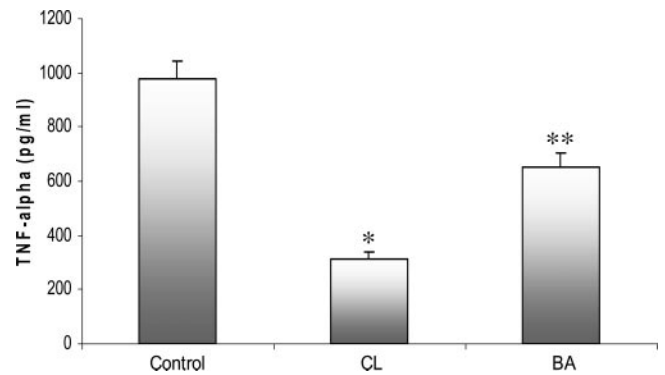


FIGURE 5. The effect of topical instillation of aqueous extract of *C. longa* (CL; 0.1%) and *B. aristata* (BA; 2%) on TNF- α in aqueous humor in rabbits with experimental uveitis. All values are expressed as the mean \pm SD. * $P < 0.001$ vs. control and BA; ** $P < 0.05$ vs. control ($n = 8$).

longa-treated group, only one eye was completely free of inflammation, whereas others showed mild edema, vasodilatation, and inflammatory cell infiltration, mainly in the posterior chamber. The mean histopathologic score in the *C. longa*-treated group was 1.13 ± 0.54 (range, 0-2). In *B. aristata*, seven eyes showed mild-to-moderate inflammatory changes, one eye showed very minimal inflammatory changes, and none was found to be completely free of inflammatory changes. The mean histopathologic grade in *B. aristata*-treated group was 2.13 ± 0.41 (range, 1-3). The statistical analysis of the histopathologic score showed a significantly higher degree of inflammation in the control group than in the *C. longa*- and *B. aristata*-treated groups ($P < 0.001$). A significantly higher degree of inflammation was observed in the *B. aristata*-treated group than in the *C. longa*-treated group ($P < 0.05$; Table 1, Fig. 6).

DISCUSSION

The results of the present study clearly demonstrated the protective effects of the topical application of two herbs in

endotoxin-induced uveitis. The animals in the treated groups showed not only significantly reduced severity of clinical signs and histopathologic changes of uveitis but also significant reduction in aqueous humor levels of inflammatory cells, protein contents, and TNF- α compared with the control group.

The endotoxin-induced model used in this study is not an exact representation of clinical uveitis, but the inflammatory response and cytokine production in response to endotoxin closely resembles the acute phase of clinical uveitis. The endotoxin-induced inflammation can be observed during antibiotic therapy for ocular infections. The antibiotics, while destroying the bacteria, also release the LPS from their cell walls, thereby leading to an inflammatory response. The drugs found effective in endotoxin-induced uveitis may be effective in the treatment of ocular and systemic Gram-negative bacterial infections.

After intravitreal injection, the strong biological activity of the endotoxin initiates the inflammatory vascular and cellular responses. Increased production and release of monocytes, macrophages, and other inflammatory cells is associated with the release of potent inflammatory mediators in the aqueous

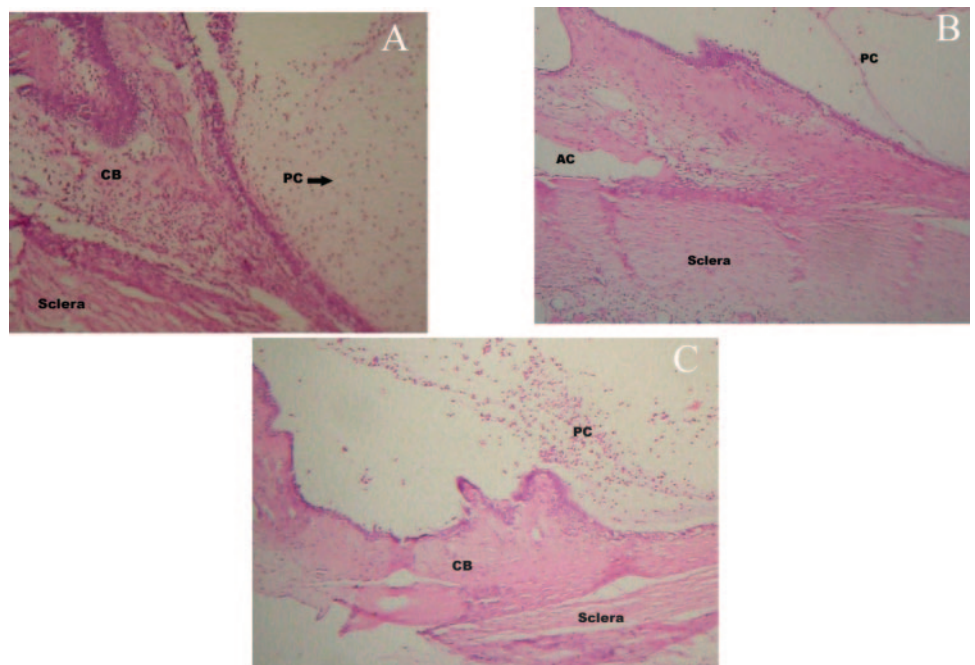


FIGURE 6. Micrographs of hematoxylin and eosin-stained sections of rabbit eyes 72 hours after intravitreal endotoxin injection. (A) Control group. Extensive inflammatory cell infiltration was seen in the posterior chamber (PC; arrow), the anterior chamber (AC), and the ciliary body (CB). (B) *C. longa*-treated group. Very few inflammatory cells were seen in the PC and CB. (C) *B. aristata*-treated group, with moderate inflammatory cell infiltration in the PC and mild infiltration in the CB and AC.

humor. One of these is TNF- α , which appears to be essential in the development of endotoxin-induced inflammation.^{19,20} Besides the chemical mediators of inflammation, cell adhesion molecules play a vital role in leukocyte adherence to vascular endothelial cells during the early acute phase of inflammation and contribute to the leakage of protein.

The drugs used in our study have demonstrated a significant anti-inflammatory effect in other studies,^{7-9,11-13} including improvement of chronic uveitis by oral supplementation.¹⁵ The therapeutic response to topical application of aqueous extracts of *C. longa* and *B. aristata* has demonstrated for the first time the possible utility of these drugs as a topical application for the treatment of anterior uveitis. The reduced severity of inflammatory changes observed in histopathologic examination and clinical manifestations in the inflamed eye was the result of significant inhibition of vascular and cellular inflammatory responses. The release of chemical mediators of inflammation is also suppressed secondary to inhibition of the cellular response. The suppression of vascular and cellular inflammatory responses by herbal extracts was evidenced by significantly low levels of inflammatory cells, proteins, and TNF- α levels in aqueous humor of treated animals. Significantly reduced protein levels in aqueous humor also indicates a possible inhibitory role of extract constituents on leukocyte adherence to the vascular endothelium. Direct binding to LPS of some of the extract constituents may be another mechanism of suppression of endotoxin-triggered uveitis. Inhibition of cyclooxygenase (COX)-2 may also contribute to the anti-inflammatory effect in anterior uveitis, as studies have shown selective COX 2 inhibitory activity of curcumin and berberine.^{21,22} Further studies of the isolated active principle components of these herbal extracts are warranted, to explore fully the mechanisms of anti-inflammatory activity in endotoxin-induced uveitis.

References

- Rosenbaum, JT, McDevitt, HO, Guss, RB, Egbert, PR. Endotoxin-induced uveitis in rats as a model for human disease. *Nature*. 1980;286:611-613.
- Li, Q, Peng, B, Whitcup, SM, Jang, SU, Chan, CC. Endotoxin induced uveitis in the mouse: susceptibility and genetic control. *Exp Eye Res*. 1995;61:629-632.
- Beutler, B, Milsark, IW, Cerami, AC. Passive immunization against cachectin/tumor necrosis factor protects mice from lethal effect of endotoxin. *Science*. 1985;229:869-871.
- Lehmann, V, Freudenberg, MA, Galanos, C. Lethal toxicity of lipopolysaccharide and tumor necrosis factor in normal and D-galactosamine-treated mice. *J Exp Med*. 1987;165:657-663.
- Cerami, A, Beutler, B. The role of cachectin/TNF in endotoxic shock and cachexia. *Immunol Today*. 1988;9:28-31.
- Li, Q, Peng, B, Whitcup, SM, Jang, SU, Chan, CC. Endotoxin induced uveitis in the mouse: susceptibility and genetic control. *Exp Eye Res*. 1995;61:629-632.
- Rajput N, Nigam JM, Srivastava DN, Sahni YP. Anti-inflammatory activity of *Adhatoda vasica* and *Berberis aristata* on carrageenin induced paw oedema in rats. *J Nat Remedies*. 2004;4:97-102.
- Khosla PK, Neeraj VI, Gupta SK, Satpathy G. Berberine, a potential drug for trachoma. *Rev Int Trach Pathol Ocul Trop Subtrop Sante Publique*. 1992;69:147-165.
- Mohan M, Sekhar GC, Mahajan VM. Berberine: an indigenous drug in experimental herpetic uveitis. *Indian J Ophthalmol*. 1983; 31(2):65-68.
- Hsiang CY, Wu SL, Cheng SE, Ho TY. Acetaldehyde-induced interleukin-1beta and tumor necrosis factor-alpha production is inhibited by berberine through nuclear factor-kappaB signaling pathway in HepG2 cells. *J Biomed Sci*. 2005;12(5):791-801.
- Ghatak N, Basu N. Sodium curcumin as an effective anti-inflammatory agent. *Indian J Exp Biol*. 1972;10:235-236.
- Srimal RC, Dhawan BN. Pharmacology of diferuloyl methane (curcumin), a non-steroidal anti-inflammatory agent. *J Pharm Pharmacol*. 1973;25:447-452.
- Mukophadhyay A, Basu N, Ghatak N, Gujral PK. Anti-inflammatory and irritant activities of curcumin analogues in rats. *Agents Actions*. 1982;12:508-515.
- Ammon HPT, Anazodo MI, Safayhi H, Dhawan BN, Srimal RC. Curcumin: a potent inhibitor of Leukotriene B₄ formation in rat peritoneal polymorphonuclear neutrophils (PMNL). *Planta Medica*. 1992;58:26-28.
- Lal B, Kapoor AK, Asthana OP, et al. Efficacy of curcumin in the management of chronic anterior uveitis. *Phytotherapy Res*. 1999; 13:318-322.
- Reyes-Gordillo K, Segovia J, Shibayama M, Vergara P, Moreno MG, Muriel P. Curcumin protects against acute liver damage in the rat by inhibiting NF-kappaB, proinflammatory cytokines production and oxidative stress. *Biochim Biophys Acta*. 2007;1770(6):989-996.
- Ruiz-Moreno JM, Thillaye B, de Zokak Y. Retino-choroidal changes in endotoxin-induced uveitis in the rat. *Ophthalmic Res*. 1992;24: 162-168.
- Lowry OH, Rosenbrough NJ, Farr AL, Randall RJ. Protein measurement with the Folin-phenol reagent. *J Biol Chem*. 1951;193:265-275.
- Tuailion N, Shen de F, Berger RB, Lu B, Rollins BJ, Chan CC. MCP-1 expression in endotoxin-induced uveitis. *Invest Ophthalmol Vis Sci*. 2002;43:1493-1498.
- Avunduk, AM, Avunduk, MC, Oztekin, E, Baltaci, AK. Characterization of T lymphocyte subtypes in endotoxin-induced uveitis and effect of pentoxifylline treatment. *Curr Eye Res*. 2002; 24:92-98.
- Zhang F. Curcumin inhibits cyclooxygenase-2 transcription in bile acid- and phorbol ester-treated human gastrointestinal epithelial cells. *Carcinogenesis*. 1999;20(3):445-451.
- Fukuda K, Hibiya Y, Mutoh M, et al. Inhibition by berberine of cyclooxygenase-2 transcriptional activity in human colon cancer cells. *J Ethnopharmacology*. 1999;66(2):227-233.