

# Plasmin Treatment Accelerates Vascular Endothelial Growth Factor Clearance from Rabbit Eyes

Wei-Chi Wu,<sup>1,2</sup> Chib-Chun Chen,<sup>3</sup> Chi-Hsien Liu,<sup>4</sup> Nan-Kai Wang,<sup>1,2</sup> Kuan-Jen Chen,<sup>1,2</sup> Tun-Lu Chen,<sup>1,2</sup> Yib-Shiou Hwang,<sup>1,2</sup> Lien-Min Li,<sup>1</sup> and Chi-Chun Lai<sup>1,2</sup>

**PURPOSE.** To investigate the clearance of vascular endothelial growth factor (VEGF) after the induction of posterior vitreous detachment by plasmin and/or SF<sub>6</sub>.

**METHODS.** The study design included four groups of rabbits: group 1 received an intravitreal injection of plasmin and SF<sub>6</sub> in the right eye, group 2 received an intravitreal injection of plasmin in the right eye, group 3 received an intravitreal injection of SF<sub>6</sub> in the right eye, and group 4 received an intravitreal injection of balanced salt solution in the right eye. Intravitreal injection of human VEGF (50 μL, 10 ng/μL) was performed in study eyes and control eyes 1 month after plasmin and/or SF<sub>6</sub> injection. Serum and vitreous samples were collected on days 1, 3, and 7 after VEGF injection to determine the serum and vitreous concentrations of VEGF.

**RESULTS.** One day after VEGF injection, residual human VEGF concentration in the vitreous cavity was significantly lower in the plasmin- and SF<sub>6</sub>-treated eyes (group 1) and the plasmin-treated eyes (group 2) when compared with the control eyes (group 4) ( $P = 0.047$  and  $0.027$ , respectively). Three days after VEGF injection, the residual VEGF concentration in the vitreous cavity was still significantly lower in the plasmin- and SF<sub>6</sub>-treated eyes (group 1) when compared with the control eyes (group 4) ( $P = 0.025$ ).

**CONCLUSIONS.** Eyes treated with plasmin exhibit a more rapid clearance of exogenous VEGF than control eyes. This finding suggests a novel treatment for retinopathies associated with vitreous traction and VEGF elevation. (*Invest Ophthalmol Vis Sci.* 2011;52:6162–6167) DOI:10.1167/iops.10-6396

Vascular endothelial growth factor (VEGF) is a critical factor in the tissue growth and organ repair processes of angiogenesis and vasculogenesis.<sup>1</sup> VEGF is also a survival factor for endothelial cells, controls glomerular capillary function, and works as a neurotrophic and neurogenic agent.<sup>2–4</sup> Pathologically, VEGF is the principal growth factor in the neovascularization in the eye and serves as a potent vessel permeability

growth factor.<sup>2</sup> The production of VEGF is mainly driven by retinal ischemia.<sup>5</sup> When neovascularization develops in the retina, leakage, retinal edema, and even retinal detachment in the eye may result, thus compromising vision.<sup>6</sup> The role of VEGF is recognized in a number of vitreoretinal diseases, including retinopathy of prematurity (ROP),<sup>7,8</sup> diabetic retinopathy,<sup>9,10</sup> age-related macular degeneration (ARMD),<sup>11</sup> and retinal vessel occlusion.<sup>10,12,13</sup> Therapy aimed at VEGF has been found to be effective in the retinopathies associated with VEGF elevation.<sup>14–17</sup>

Plasmin is a serine protease that mediates the fibrinolytic process and modulates the extracellular matrix.<sup>18</sup> It hydrolyzes a variety of glycoproteins, including laminin and fibronectin, both of which are present at the vitreoretinal interface and are thought to play a key role in vitreoretinal attachment.<sup>19,20</sup> Plasmin has been proven to cause vitreous liquefaction and posterior vitreous detachment (PVD).<sup>21–27</sup> Pharmacologic vitreolysis with microplasmin (ThromboGenics Ltd, Dublin, Ireland), which is a truncated form of plasmin, increases vitreous diffusion coefficients<sup>28</sup> and oxygen levels in the vitreous.<sup>29</sup> Therefore, plasmin might be useful in treating a variety of retinopathies by serving to reduce vitreous traction and retinal ischemia.

It has been suggested that whether there is a PVD may influence the bio-distribution or flux of molecules that cross the vitreoretinal junction<sup>30</sup> (Goldenberg DT, et al. *IOVS* 2008; 49:ARVO E-Abstract 5616). However, direct evidence of VEGF clearance from PVD eyes is still lacking. Because VEGF is an important target of treatment in a variety of retinopathies, we aimed to investigate the role of PVD and vitreous liquefaction on the clearance of VEGF from rabbit eyes. We hypothesized that the eyes with PVD will have different pharmacokinetics in the clearance of VEGF. PVD and vitreous liquefaction were induced by the injection of plasmin and/or sulfur hexafluoride (SF<sub>6</sub>) into the rabbit eye. Residual VEGF levels were then determined and compared between study eyes and control eyes after the administration of exogenous human VEGF into the vitreous.

## MATERIALS AND METHODS

### Grouping of Animals

Japanese white rabbits (1.5–1.7 kg) were used in this study. The handling of animals was performed in accordance with the Chang Gung Memorial Hospital regulations that govern the use of experimental animals and the ARVO Statement for the Use of Animals in Ophthalmic and Vision Research. Because the vitreoretinal adhesion is tighter in rabbits than in humans, plasmin injection alone or the long-acting gas SF<sub>6</sub> alone did not produce complete PVD.<sup>31</sup> Plasmin enzyme combined with the long-acting SF<sub>6</sub> produced complete PVD and vitreous liquefaction.<sup>31</sup> Therefore, animals in group 1 received plasmin and SF<sub>6</sub> injection, which represented the complete PVD group. Animals in group 2 and group 3 received plasmin or SF<sub>6</sub>

From the <sup>1</sup>Department of Ophthalmology and <sup>3</sup>Microscopy Core Laboratory, Chang Gung Memorial Hospital, Taoyuan, Taiwan; <sup>2</sup>Chang Gung University, College of Medicine, Taoyuan, Taiwan; and <sup>4</sup>Graduate Institute of Biochemical and Biomedical Engineering, Chang Gung University, Taoyuan, Taiwan.

Supported by the National Science Council, Taipei, Taiwan; NSC98-2311-B-182A-001-MY2; and Chang Gung Memorial Hospital Research Grant CMRPG 370751, Taoyuan, Taiwan.

Submitted for publication August 12, 2010; revised December 1, 2010; accepted December 10, 2010.

Disclosure: **W.-C. Wu**, None; **C.-C. Chen**, None; **C.-H. Liu**, None; **N.-K. Wang**, None; **K.-J. Chen**, None; **T.-L. Chen**, None; **Y.-S. Hwang**, None; **L.-M. Li**, None; **C.-C. Lai**, None

Corresponding author: Chi-Chun Lai, Department of Ophthalmology, Chang Gung Memorial Hospital, 5 Fu-Hsin Rd., Kweishan 333, Taoyuan, Taiwan; chichun.lai@gmail.com.

injection, which represented the incomplete PVD groups. The right eye of each rabbit in group 1 received an intravitreal injection of 1 unit of human plasmin (0.1 mL reconstituted in sterile balanced salt solution [BSS; CalBiochem, La Jolla, CA]) and 0.5 mL of SF<sub>6</sub>. The right eye of each rabbit in group 2 received an intravitreal injection of 1 unit of human plasmin (0.1 mL) only. The right eye of each rabbit in group 3 received an intravitreal injection of 0.5 mL of SF<sub>6</sub> only. The left eye of each animal in these three groups received a 0.1 mL balanced salt solution injection. Animals in group 4 received balanced salt solution injections into the right eye and no injection into the left eye. Each group consisted of four animals, and the grouping details are shown in Table 1.

The intravitreal injections were performed 2 mm posterior to the limbus while the eye was observed under a surgical microscope (M691; Wild Heerbrugg, Heerbrugg, Switzerland). Care was taken to avoid damage to the lens and the retina during the injection.

### Clinical Observations and Electrophysiological Examination

Slit-lamp (SL-15; Kowa, Tokyo, Japan) examinations and indirect ophthalmoscopy (Omega 500; Heine, Herrsching, Germany) were performed. External photos and color fundus photos were obtained to document the status of the cornea, conjunctiva, lens, vitreous, and retina after plasmin and/or SF<sub>6</sub> injection. For electroretinogram (ERG) recordings, the rabbits were anesthetized, their pupils were dilated, and a topical anesthetic was applied to the cornea. After 1 hour of dark adaptation, ERGs were recorded with an ERG recording system (RETIport ERG; Roland Consult, Brandenburg, Germany) at baseline and at 1, 3, 7, 14, and 28 days after the intravitreal injections. ERGs were recorded with a contact lens electrode that contained light-emitting diodes as a stimulator and was connected to an electrode on the forehead. The ground electrode was attached to the ear. Amplitudes and implicit times of a- and b-waves were evaluated.

### Intravitreal Injection of VEGF

Intravitreal injection of human VEGF (recombinant human VEGF<sub>165</sub>; R&D Systems, Minneapolis, MN) was performed in the plasmin-treated eyes and control eyes to determine whether plasmin-treated eyes displayed more rapid VEGF diffusion. One month after plasmin and/or SF<sub>6</sub> injection, injection of VEGF (50 μL, 10 ng/μL) was performed in the right eyes in each group of rabbits. To determine the residual vitreous concentration of VEGF, intravitreal samples were obtained via the pars plana using a 27-gauge needle at the following time intervals: 1, 3, and 7 days after the injection of VEGF. Serum VEGF samples were measured at the same time.

### VEGF ELISA after Vitreous VEGF Injection

The amount of human VEGF injected was measured using a commercially available VEGF sandwich enzyme-linked immunosorbent assay (ELISA) kit (DuoSet, R&D Systems). The optical density of each well was measured by a plate reader that subtracted readings at 540 nm from the readings at 450 nm. The VEGF content was estimated from the standard curve. The range of detection of this ELISA kit was 20–2500 pg/mL. Vitreous samples were centrifuged at 5000g at 4°C to remove cells, and the supernatant was frozen at –70°C. The ELISA procedure was performed according to the manufacturer's instructions.

TABLE 1. Grouping and Treatment of the Animals

	Group 1	Group 2	Group 3	Group 4
Intravitreal injection	OD: plasmin and SF <sub>6</sub> OS: Balanced salt solution	OD: plasmin OS: Balanced salt solution	OD: SF <sub>6</sub> OS: Balanced salt solution	OD: Balanced salt solution OS: No treatment
Condition in the right eye	Complete PVD	Incomplete PVD	Incomplete PVD	Control group

OD, right eye; OS, left eye; PVD, posterior vitreous detachment.

### Histologic Examination

After enucleation, the eyes were opened with a razor blade that penetrated the vitreous adjacent to the pars plana to ensure rapid penetration of fixative. Care was taken to avoid damage to the adjacent retina and lens. The eye section used for light microscopy was immersed in 4% paraformaldehyde for 30 minutes.

For transmission electron microscopy (TEM), after fixation with a mixture of 3% glutaraldehyde and 2% paraformaldehyde, the tissue was dehydrated in an ethanol series, postfixed in 1% osmium tetroxide, and embedded in epoxy resin (Epok 812; Oken, Tokyo, Japan). Semithin sections were stained with 0.5% toluidine blue. Ultrathin sections were stained for contrast with 8% uranyl acetate and lead citrate and then analyzed using an electron microscope (H7500; Hitachi, Tokyo, Japan).

For scanning electron microscopy (SEM), after fixation in a mixture of 3% glutaraldehyde and 2% paraformaldehyde in 0.1 M cacodylate buffer, a posterior calotte that included part of each quadrant of the eye was removed, dehydrated through a graded ethanol series, dried in carbon dioxide liquid to the critical point, sputter-coated in platinum, and then photographed using an electron microscope (S-5000; Hitachi, Tokyo, Japan). Electron photomicrographs were evaluated for the degree of vitreoretinal separation based on the presence of the three following features: a continuous or a discontinuous network of collagen fibrils that covered the internal limiting membrane (ILM); single, sparse collagen fibrils present on the ILM; or no collagen fibrils on the ILM. Consistent with a previous study,<sup>32</sup> grading was classified as follows: 3, dense deposition of collagen on the ILM; 2, moderate deposition of collagen on the ILM; 1, mild deposition of collagen on the ILM; and 0, no deposition of collagen on the ILM. The observers were blinded to the group classifications when they interpreted the morphology data.

### Statistical Evaluation

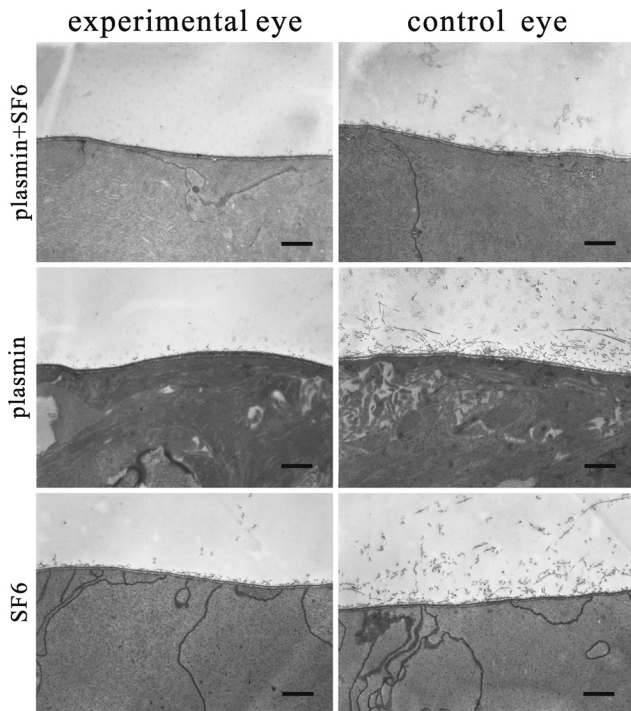
We compared ERG results between study eyes and control eyes, between eyes before and after intravitreal injection, and among different treatment groups. Amplitudes and implicit times of the a- and b-waves were analyzed by group mean comparisons. We also compared the ELISA results among the different treatment groups using the analysis of variance (ANOVA) and the Dunnett post hoc test. The Wilcoxon signed-rank test was used to compare ERG results at baseline and after treatment as well as to compare the results between study eyes and control eyes. The tests were performed using statistical software (SPSS v. 13.0; SPSS Inc., Chicago, IL), and data were expressed as the mean ± the SD with *P* < 0.05 considered to be significant.

## RESULTS

### Clinical Observations and Electrophysiological Examination

After surgeries, moderate to severe conjunctival congestion persisted for approximately 2 weeks in the study eyes. After that, redness gradually decreased. Up to 30 days after surgery, there was no significant difference among the four treatment groups in terms of the degree of conjunctival redness as assessed by the CCLRU grading scale.<sup>33</sup> None of the eyes developed corneal or conjunctival infections by the end of the





**FIGURE 1.** TEM results after plasmin and/or SF<sub>6</sub> treatment. Selected sections showed that collagen fibrils were still densely attached to the ILM in the left eyes of the animal. In contrast, eyes treated with plasmin and/or SF<sub>6</sub> showed a clean ILM with much less collagen fibril adhesion, which is consistent with the findings related to PVD. Scale bar, 1  $\mu$ m.

experiment. The lens remained clear for up to 30 days after the intravitreal injection of plasmin and/or SF<sub>6</sub>. Dilated fundus examinations revealed no signs of vitreous opacity, retinal detachment, vessel occlusion, or retinal necrosis in any group of animals. ERG data showed a transient decrease in a- and b-wave amplitude within 1 week after the injections in groups 1, 2, and 3. At 1 week after the injections, the amplitude returned to baseline (data not shown).

### Histology and EM Results

There were no apparent differences in the retinal histology among the four treatment groups as determined by light microscopy. The morphology of the retinas from the plasmin- and/or SF<sub>6</sub>-treated eyes was similar to that observed in the control eyes.

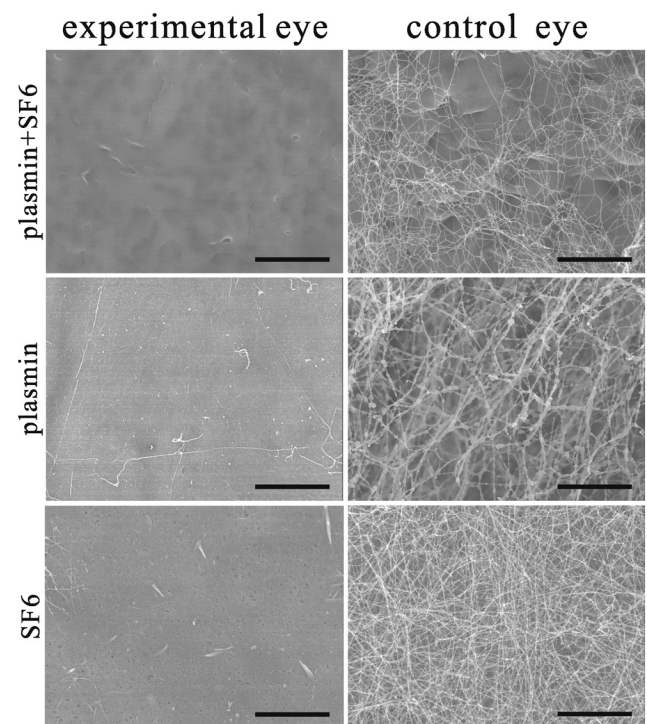
TEM was used to investigate the presence of vitreoretinal adhesion and to characterize the ultra-morphology in different retinal layers after plasmin and/or SF<sub>6</sub> treatment. Dense collagen fibrils were still attached to the ILM in the control eyes. In contrast, eyes treated with plasmin and/or SF<sub>6</sub> showed a cleaner ILM with very limited adhesion of collagen fibrils (Fig. 1). The ultra-structure in the retinal pigment epithelium, outer segments of photoreceptors, inner segments of photoreceptors, mitochondria in the inner segments, and cells in the outer nuclear layer showed normal morphology in all four treated groups.

SEM showed that collagen fibrils were sparsely present or could not be found in the plasmin- and SF<sub>6</sub>-treated (group 1) eyes, which was consistent with the findings of complete PVD. In plasmin- or SF<sub>6</sub>-treated eyes (group 2 or 3), mild to moderate collagen deposition on the ILM was observed, which was consistent with the findings of incomplete PVD. In contrast, the balanced salt solution-treated eyes showed dense and

continuous networks of collagen fibrils covering the ILM, which indicated no signs of PVD (Fig. 2 and Table 2).

### VEGF Concentration as Determined by ELISA

One day after VEGF injection, residual VEGF concentrations in the vitreous cavity were significantly lower in the plasmin- and SF<sub>6</sub>-treated eyes (group 1;  $74,876 \pm 52,027$  pg/mL) and in the plasmin-treated eyes (group 2;  $52,299 \pm 38,279$  pg/mL) when compared to the control eyes (group 4;  $170,333 \pm 33,322$  pg/mL;  $P = 0.047$  and  $0.024$ , respectively). Three days after VEGF injection, residual VEGF concentrations in the vitreous cavity were still significantly lower in the plasmin- and SF<sub>6</sub>-treated eyes (group 1;  $886 \pm 605$  pg/mL) when compared to the control eyes (group 4;  $7809 \pm 4296$  pg/mL). Seven days after VEGF injection, the residual VEGF concentrations were very low ( $421 \pm 320$  pg/mL,  $333 \pm 211$  pg/mL,  $386 \pm 118$  pg/mL, and  $453 \pm 186$  pg/mL from groups 1, 2, 3, and 4, respectively). No significant differences were noted among the treatment groups. Although the mean VEGF levels on day 1 were the lowest in the group treated with plasmin alone (group 2), there was no statistically significant difference between the VEGF levels in the group treated with plasmin and SF<sub>6</sub> (group 1) and the group treated with plasmin alone (group 2) ( $P = 0.838$ ). The VEGF levels on day 3 were lower in the group treated with plasmin and SF<sub>6</sub> (group 1) compared to the group treated with plasmin alone (group 2). However, the difference was also not statistically significant ( $P = 0.940$ ). Therefore, the eyes treated with plasmin alone or plasmin plus SF<sub>6</sub> showed much faster clearance of VEGF compared with the control eyes. However, we did not find a significant difference between these two groups of eyes (group 1 and 2). The results are shown in Figure 3.



**FIGURE 2.** SEM showed that collagen fibrils were sparsely present or could not be found in plasmin- and/or SF<sub>6</sub>-treated eyes. On the contrary, the fellow balanced salt solution-treated eyes showed dense and continuous networks of collagen fibrils covering the ILM, with no sign of PVD. Scale bar, 6  $\mu$ m.

TABLE 2. Grading and Results of Vitreo-Retinal Separation in Various Treatment Groups

Group	Group 1: Plasmin and SF <sub>6</sub> injection in OD				Group 2: Plasmin injection in OD				Group 3: SF <sub>6</sub> injection in OD				Group 4: Balanced salt solution injection in OD			
	1	2	3	4	5	6	7	8	9	10	11	12	13	14	15	16
Animal number																
OD	0-1	0-1	0-1	0-1	1-2	1-2	1-2	1-2	1-2	1-2	1-2	1-2	3	3	2	2
OS	3	2	3	3	3	2	2	3	3	3	3	3	3	3	3	3

Grading: 0, no deposition of collagen on internal limiting membrane (ILM); 1, mild deposition of collagen on ILM; 2, moderate deposition of collagen on ILM; 3, dense deposition of collagen on ILM. OD, right eye; OS, left eye.

The serum VEGF levels were below the level that could be detected by this ELISA kit in all the groups of animals at all the examined time points.

## DISCUSSION

Our study results show that plasmin and/or SF<sub>6</sub> injection is well tolerated in rabbit eyes. Complete PVD could be consistently created through treatment with plasmin and SF<sub>6</sub>. Partial PVD was found after the injection of plasmin or SF<sub>6</sub>. VEGF clearance from the rabbit vitreous was much faster in the plasmin-treated eyes than in the control eyes. Such findings could have important clinical implications in the future.

The causes of the faster clearance of VEGF from the plasmin-treated eyes require further investigation. A colloidal vitreous and intact vitreoretinal junction represent physical barriers that could limit the movement of molecules.<sup>30</sup> Therefore, enzyme-mediated detachment of the vitreous from the retina has been found to increase the molecular penetration in the retina (Goldenberg DT, et al. *IOVS* 2008;49:ARVO E-Abstract 5616). In addition to PVD, plasmin enzyme causes vitreous liquefaction by the activation of collagenase,<sup>34</sup> which could lead to the degradation of collagen in the vitreous. A colloidal vitreous could act as a reservoir for the VEGF and entrap more VEGF than a liquefied vitreous. Additionally, plasmin could facilitate the degradation of the extracellular matrix that surrounds the endothelial cells, which increases the flux of metabolites.<sup>35</sup> Plasmin could also act directly on the endothelial cells and increase their permeability.<sup>36</sup> These effects could account for the increased clearance of VEGF after the administration of plasmin. However, serum VEGF could not be shown to differ among the treatment groups because the concentration of VEGF was too low to be detected by ELISA.

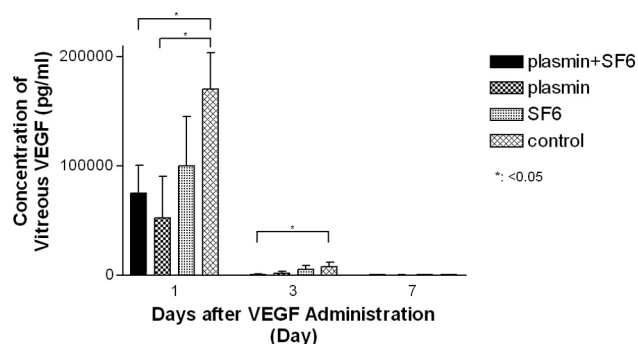


FIGURE 3. VEGF clearance in the eyes treated with plasmin and/or SF<sub>6</sub> as well as control eyes. Eyes treated with plasmin enzyme were found to have a significantly lower concentration of VEGF in the vitreous than the control eyes 1 and 3 days after the injection of human VEGF. VEGF levels were very low and showed no difference among treatment groups 7 days after the injection of human VEGF.

These findings show significant potential for the clinical application of plasmin enzyme in the future. VEGF plays an important role in the pathogenesis of a variety of retinopathies, including ARMD,<sup>11</sup> diabetic retinopathy,<sup>9,10</sup> ROP,<sup>7,8</sup> and retinal vessel occlusion<sup>10,12,13</sup> and has shown promising results as a major target in the treatment of these diseases. Methods of blocking VEGF, including VEGF antibodies,<sup>14,15</sup> VEGF trap,<sup>16</sup> and VEGF RNA interference<sup>17</sup> have been attempted with promising results. Faster clearance of VEGF from eyes treated with plasmin is also likely to be beneficial in these retinopathies. In addition, vitreous traction has been recognized as a significant pathogenic factor in the retinopathies mentioned above.<sup>37-43</sup> Studies have shown that patients with PVD had a better visual prognosis in certain retinopathies, such as retinal vessel occlusion and ARMD.<sup>37,40</sup> The complete relief of vitreous traction by the induction of PVD is theoretically helpful in these retinopathies. With the administration of plasmin enzyme in the eye, dual beneficial effects could be achieved for the retina.

Another potential benefit of plasmin is the long-acting nature of its effect. This VEGF-lowering effect is desirable for chronic retinal disorders, such as ARMD, which is a major cause of blindness in developed countries. Intravitreal injection of VEGF antibodies, bevacizumab (Avastin; Genentech Inc., South San Francisco, CA) or ranibizumab (Lucentis; Genentech Inc.), is the current treatment of choice. Although effective, monthly injection of these drugs is usually required due to the chronic character of the disease and the short half-lives of the drugs.<sup>14,44,45</sup> These factors burden both patients and their treating doctors. Plasmin enzyme treatment is found to speed VEGF clearance from the vitreous. It is likely that such an effect could persist longer than the half-lives of VEGF antibodies, VEGF trap, or RNA interference because plasmin enzyme permanently hydrolyzes the collagen structure in the vitreous.

Plasmin enzyme was clinically used mainly as an adjuvant to reduce vitreoretinal adhesion during vitrectomy surgery.<sup>24-27,38,46-50</sup> With the application of plasmin enzyme, PVD was less traumatic than that achieved by the mechanical method alone.<sup>51</sup> This less traumatic treatment would be especially useful in pediatric eyes, in which vitreoretinal adhesion is so tight that the induction of PVD by mechanical methods seldom succeeds. Plasmin enzyme could also be used in combination with long-acting gas to treat macular holes.<sup>22</sup> In addition to the use of plasmin as an adjuvant for vitrectomy or long-acting SF<sub>6</sub> gas, the enzyme could also be used as a single agent to treat retinopathies associated with retinal ischemia, VEGF elevation, or vitreous traction. Of note, the effect of PVD produced by plasmin is dose and time dependent.<sup>52</sup> Therefore, sufficient doses of plasmin and time for action are required to produce the complete effect of vitreoretinal separation, and insufficient doses or time for action will produce partial vitreoretinal separation or no separation at all. Currently, clinical trials that involve microplasmin, which is a truncated form of plasmin, are currently ongoing,<sup>48,53</sup> and some of the prelimi-



nary results are encouraging. The long-term efficacy and safety of this enzyme will be proven only with further research.

The diffusion coefficient for the VEGF in the vitreous could be estimated by using the following approach. He and Niemeier<sup>54</sup> modified Stokes-Einstein equation and found that the diffusion coefficient is proportional to molecular weight<sup>-1/6</sup> and radius<sup>-1/2</sup>. The diffusion coefficient of fluorescein (a dye, MW 376, radius 0.45 nm) in the vitreous has been estimated to be approximately  $4.8 \times 10^{-6}$  cm<sup>2</sup>/s.<sup>55,56</sup> VEGF has a molecular weight of 45,000 daltons and a radius of 3 nm.<sup>57</sup> Its diffusion coefficient is calculated at  $8.4 \times 10^{-7}$  cm<sup>2</sup>/s in the vitreous when compared with fluorescein. When injected into the vitreous using 20 nm beads and dynamic light scattering technology, microplasmin has been reported to reduce the viscosity and produce a two- to fivefold enhancement in the diffusion coefficient.<sup>28</sup> Therefore, the diffusion coefficient of VEGF in the plasmin-treated vitreous could be calculated at approximately  $1.7\text{--}4.2 \times 10^{-6}$  cm<sup>2</sup>/s, which is larger than the diffusion coefficient ( $8.4 \times 10^{-7}$  cm<sup>2</sup>/s) in the nontreated vitreous.

The strength of vitreoretinal adhesion varies based on the location within the eye. Vitreoretinal adhesions are particularly strong in the vitreous base, at the equator, over the retinal vessels, at the optic disc, and at the macula.<sup>58</sup> Vitreoretinal separation or PVD could be created by administering plasmin or microplasmin<sup>59,60</sup> but at most up to the region that is immediately posterior to the equator. In the vitreous base, direct insertions of vitreous fibrils into Müller cells and/or into the crypts between adjacent Müller cells have been found.<sup>61–63</sup> In addition, attachment plaques (i.e., hemidesmosomes) are present in the equator and are absent from the posterior pole, with the exception of the fovea.<sup>61</sup> Therefore, complete vitreoretinal separation in the ora serrata could not be achieved by plasmin or other enzymes in those areas because of very strong vitreoretinal adhesions.

Although plasmin has been safely used in clinical settings, some potential complications could arise with its use. Transient decreases in ERG<sup>59,64</sup> and mild intraocular inflammation<sup>60,66</sup> after intravitreal injection of plasmin have been reported. Posterior subcapsular cataracts have been noted in some patients with pediatric traumatic macular holes after plasmin-mediated vitrectomy.<sup>27,66</sup> Other potential complications associated with intravitreal injection include retinal tears, retinal detachments,<sup>27</sup> and endophthalmitis.

In conclusion, plasmin enzyme could produce PVD and relieve vitreous traction in the retina. The enzyme also has a good safety profile. In addition, VEGF clearance was much faster from the plasmin enzyme-treated eyes than from the control eyes. These results imply a potential application in retinopathies that are associated with VEGF elevation and vitreous traction in the near future.

## References

1. Wirostko B, Wong TY, Simo R. Vascular endothelial growth factor and diabetic complications. *Prog Retin Eye Res.* 2008;27:608–621.
2. Alon T, Hemo I, Itin A, et al. Vascular endothelial growth factor acts as a survival factor for newly formed retinal vessels and has implications for retinopathy of prematurity. *Nat Med.* 1995;1:1024–1028.
3. Eremina V, Sood M, Haigh J, et al. Glomerular-specific alterations of VEGF-A expression lead to distinct congenital and acquired renal diseases. *J Clin Invest.* 2003;111:707–716.
4. Raab S, Plate KH. Different networks, common growth factors: shared growth factors and receptors of the vascular and the nervous system. *Acta Neuropathol.* 2007;113:607–626.
5. Aiello LP, Northrup JM, Keyt BA, et al. Hypoxic regulation of vascular endothelial growth factor in retinal cells. *Arch Ophthalmol.* 1995;113:1538–1544.
6. Antcliff RJ, Marshall J. The pathogenesis of edema in diabetic maculopathy. *Semin Ophthalmol.* 1999;14:223–232.
7. Sato T, Kusaka S, Shimojo H, Fujikado T. Simultaneous analyses of vitreous levels of 27 cytokines in eyes with retinopathy of prematurity. *Ophthalmology.* 2009;116:2165–2169.
8. Sato T, Kusaka S, Shimojo H, Fujikado T. Vitreous levels of erythropoietin and vascular endothelial growth factor in eyes with retinopathy of prematurity. *Ophthalmology.* 2009;116:1599–1603.
9. Pe'er J, Folberg R, Itin A, et al. Upregulated expression of vascular endothelial growth factor in proliferative diabetic retinopathy. *Br J Ophthalmol.* 1996;80:241–245.
10. Aiello LP, Avery RL, Arrigg PG, et al. Vascular endothelial growth factor in ocular fluid of patients with diabetic retinopathy and other retinal disorders. *N Engl J Med.* 1994;331:1480–1487.
11. Witmer AN, Vrensen GF, Van Noorden CJ, Schlingemann RO. Vascular endothelial growth factors and angiogenesis in eye disease. *Prog Retin Eye Res.* 2003;22:1–29.
12. Boyd SR, Zachary I, Chakravarthy U, et al. Correlation of increased vascular endothelial growth factor with neovascularization and permeability in ischemic central vein occlusion. *Arch Ophthalmol.* 2002;120:1644–1650.
13. Noma H, Funatsu H, Yamasaki M, et al. Pathogenesis of macular edema with branch retinal vein occlusion and intraocular levels of vascular endothelial growth factor and interleukin-6. *Am J Ophthalmol.* 2005;140:256–261.
14. Rosenfeld PJ, Brown DM, Heier JS, et al. Ranibizumab for neovascular age-related macular degeneration. *N Engl J Med.* 2006;355:1419–1431.
15. Avery RL, Pearlman J, Pieramici DJ, et al. Intravitreal bevacizumab (Avastin) in the treatment of proliferative diabetic retinopathy. *Ophthalmology.* 2006;113:1695–1705.
16. Cao J, Zhao L, Li Y, et al. A subretinal matrigel rat choroidal neovascularization (CNV) model and inhibition of CNV and associated inflammation and fibrosis by VEGF trap. *Invest Ophthalmol Vis Sci.* 2010;51:6009–6017.
17. Greenberger S, Boscolo E, Adini I, et al. Corticosteroid suppression of VEGF-A in infantile hemangioma-derived stem cells. *N Engl J Med.* 2010;362:1005–1013.
18. Liotta LA, Goldfarb RH, Brundage R, et al. Effect of plasminogen activator (urokinase), plasmin, and thrombin on glycoprotein and collagenous components of basement membrane. *Cancer Res.* 1981;41:4629–4636.
19. Russell SR, Shepherd JD, Hageman GS. Distribution of glycoconjugates in the human retinal internal limiting membrane. *Invest Ophthalmol Vis Sci.* 1991;32:1986–1995.
20. Kohno T, Sorgente N, Ishibashi T, et al. Immunofluorescent studies of fibronectin and laminin in the human eye. *Invest Ophthalmol Vis Sci.* 1987;28:506–514.
21. Diaz-Llopis M, Udaondo P, Arevalo F, et al. Intravitreal plasmin without associated vitrectomy as a treatment for refractory diabetic macular edema. *J Ocul Pharmacol Ther.* 2009;25:379–384.
22. Trese MT, Williams GA, Hartzler MK. A new approach to stage 3 macular holes. *Ophthalmology.* 2000;107:1607–1611.
23. Tsukahara Y, Honda S, Imai H, et al. Autologous plasmin-assisted vitrectomy for stage 5 retinopathy of prematurity: a preliminary trial. *Am J Ophthalmol.* 2007;144:139–141.
24. Williams JG, Trese MT, Williams GA, Hartzler MK. Autologous plasmin enzyme in the surgical management of diabetic retinopathy. *Ophthalmology.* 2001;108:1902–1905.
25. Wu WC, Dresner KA, Lai M, et al. Plasmin enzyme-assisted vitrectomy for primary and reoperated eyes with stage 5 retinopathy of prematurity. *Retina.* 2008;28:S75–S80.
26. Wu WC, Dresner KA, Capone A, et al. Plasmin enzyme-assisted vitreoretinal surgery in congenital X-linked retinoschisis: surgical techniques based on a new classification system. *Retina.* 2007;27:1079–1085.
27. Wu WC, Dresner KA, Trese MT, et al. Pediatric traumatic macular hole: results of autologous plasmin enzyme-assisted vitrectomy. *Am J Ophthalmol.* 2007;144:668–672.
28. Sebag J, Ansari RR, Suh KI. Pharmacologic vitreolysis with microplasmin increases vitreous diffusion coefficients. *Graefes Arch Clin Exp Ophthalmol.* 2007;245:576–580.

29. Quiram PA, Leverenz VR, Baker RM, et al. Microplasmin-induced posterior vitreous detachment affects vitreous oxygen levels. *Retina*. 2007;27:1090-1096.
30. Goldenberg DT, Trese MT. Pharmacologic vitreodynamics and molecular flux. *Dev Ophthalmol*. 2009;44:31-36.
31. Hikichi T, Yanagiya N, Kado M, et al. Posterior vitreous detachment induced by injection of plasmin and sulfur hexafluoride in the rabbit vitreous. *Retina*. 1999;19:55-58.
32. Gandorfer A, Rohleder M, Sethi C, et al. Posterior vitreous detachment induced by microplasmin. *Invest Ophthalmol Vis Sci*. 2004;45:641-647.
33. Cornea and Contact Lenses Research Unit. CCLRU grading scales. Sydney, Australia: University of New South Wales; 1996.
34. Dano K, Andreasen PA, Grondahl-Hansen J, et al. Plasminogen activators, tissue degradation, and cancer. *Adv Cancer Res*. 1985;44:139-266.
35. Ghajar CM, Kachgal S, Kniazeva E, et al. Mesenchymal cells stimulate capillary morphogenesis via distinct proteolytic mechanisms. *Exp Cell Res*. 2010;316:813-825.
36. Okajima K, Abe H, Binder BR. Endothelial cell injury induced by plasmin in vitro. *J Lab Clin Med*. 1995;126:377-384.
37. Hikichi T, Konno S, Trempe CL. Role of the vitreous in central retinal vein occlusion. *Retina*. 1995;15:29-33.
38. Joshi MM, Ciaccia S, Trese MT, Capone A Jr. Posterior hyaloid contracture in pediatric vitreoretinopathies. *Retina*. 2006;26:S38-S41.
39. Nasrallah FP, Jalkh AE, Van Coppenolle F, et al. The role of the vitreous in diabetic macular edema. *Ophthalmology*. 1988;95:1335-1339.
40. Robison CD, Krebs I, Binder S, et al. Vitreomacular adhesion in active and end-stage age-related macular degeneration. *Am J Ophthalmol*. 2009;148:79-82.
41. Tagawa H, McMeel JW, Furukawa H, et al. Role of the vitreous in diabetic retinopathy. I. Vitreous changes in diabetic retinopathy and in physiologic aging. *Ophthalmology*. 1986;93:596-601.
42. Machemer R. Description and pathogenesis of late stages of retinopathy of prematurity. *Ophthalmology*. 1985;92:1000-1004.
43. Schepens CL, Avila MP, Jalkh AE, Trempe CL. Role of the vitreous in cystoid macular edema. *Surv Ophthalmol*. 1984;28 Suppl:499-504.
44. Brown DM, Kaiser PK, Michels M, et al. Ranibizumab versus verteporfin for neovascular age-related macular degeneration. *N Engl J Med*. 2006;355:1432-1444.
45. Wu L, Martinez-Castellanos MA, Quiroz-Mercado H, et al. Twelve-month safety of intravitreal injections of bevacizumab (Avastin): results of the Pan-American Collaborative Retina Study Group (PACORES). *Graefes Arch Clin Exp Ophthalmol*. 2008;246:81-87.
46. Hirata A, Takano A, Inomata Y, et al. Plasmin-assisted vitrectomy for management of proliferative membrane in proliferative diabetic retinopathy: a pilot study. *Retina*. 2007;27:1074-1078.
47. Rizzo S, Pellegrini G, Benocci F, et al. Autologous plasmin for pharmacologic vitreolysis prepared 1 hour before surgery. *Retina*. 2006;26:792-796.
48. de Smet MD, Gandorfer A, Stalmans P, et al. Microplasmin intravitreal administration in patients with vitreomacular traction scheduled for vitrectomy: the MIVI I trial. *Ophthalmology*. 2009;116:1349-1355.
49. Azzolini C, D'Angelo A, Maestranzi G, et al. Intravitreal plasmin enzyme in diabetic macular edema. *Am J Ophthalmol*. 2004;138:560-566.
50. Asami T, Terasaki H, Kachi S, et al. Ultrastructure of internal limiting membrane removed during plasmin-assisted vitrectomy from eyes with diabetic macular edema. *Ophthalmology*. 2004;111:231-237.
51. Russell SR, Hageman GS. Optic disc, foveal, and extrafoveal damage due to surgical separation of the vitreous. *Arch Ophthalmol*. 2001;119:1653-1658.
52. Gandorfer A, Putz E, Welge-Lüssen U, et al. Ultrastructure of the vitreoretinal interface following plasmin assisted vitrectomy. *Br J Ophthalmol*. 2001;85:6-10.
53. Benz MS, Packo KH, Gonzalez V, et al. A placebo-controlled trial of microplasmin intravitreal injection to facilitate posterior vitreous detachment before vitrectomy. *Ophthalmology*. 2010;117:791-797.
54. He L, Niemeyer B. A novel correlation for protein diffusion coefficients based on molecular weight and radius of gyration. *Biotechnol Prog*. 2003;19:544-548.
55. Nishimura Y, Hayashi H, Oshima K, Iwata S. [Alteration of diffusion velocity of fluorescein-Na in dependence on vitreous liquefaction]. *Nippon Ganka Gakkai Zasshi*. 1986;90:1313-1316.
56. Xu J, Heys JJ, Barocas VH, Randolph TW. Permeability and diffusion in vitreous humor: implications for drug delivery. *Pharm Res*. 2000;17:664-669.
57. Stefanini MO, Wu FT, Mac GF, Popel AS. A compartment model of VEGF distribution in blood, healthy and diseased tissues. *BMC Syst Biol*. 2008;2:77.
58. Ponsioen TL, van Luyn MJ, van der Worp RJ, et al. Collagen distribution in the human vitreoretinal interface. *Invest Ophthalmol Vis Sci*. 2008;49:4089-4095.
59. Verstraeten TC, Chapman C, Hartzler M, et al. Pharmacologic induction of posterior vitreous detachment in the rabbit. *Arch Ophthalmol*. 1993;111:849-854.
60. de Smet MD, Valmaggia C, Zarranz-Ventura J, Willekens B. Microplasmin: ex vivo characterization of its activity in porcine vitreous. *Invest Ophthalmol Vis Sci*. 2009;50:814-819.
61. Foos RY. Vitreoretinal juncture: topographical variations. *Invest Ophthalmol*. 1972;11:801-808.
62. Gloor BP, Daicker BC. Pathology of the vitreo-retinal border structures. *Trans Ophthalmol Soc U K*. 1975;95:387-390.
63. Malecaze F, Caratero C, Caratero A, et al. Some ultrastructural aspects of the vitreoretinal juncture. *Ophthalmologica*. 1985;191:22-28.
64. Kim NJ, Yu HG, Yu YS, Chung H. Long-term effect of plasmin on the vitreolysis in rabbit eyes. *Korean J Ophthalmol*. 2004;18:35-40.
65. Wang F, Wang Z, Sun X, et al. Safety and efficacy of dispase and plasmin in pharmacologic vitreolysis. *Invest Ophthalmol Vis Sci*. 2004;45:3286-3290.
66. Margherio AR, Margherio RR, Hartzler M, et al. Plasmin enzyme-assisted vitrectomy in traumatic pediatric macular holes. *Ophthalmology*. 1998;105:1617-1620.