

# The Effect of Intravitreal Injection of Bevacizumab on Retinal Circulation in Patients with Neovascular Macular Degeneration

Olivier Fontaine,<sup>1,2,3</sup> Sébastien Olivier,<sup>1</sup> Denise Descovich,<sup>1</sup> Ghassan Cordahi,<sup>1</sup> Elvire Vaucher,<sup>2</sup> and Mark R. Lesk<sup>1,3</sup>

**PURPOSE.** Intravitreal (ITV) injection of anti-VEGFs like bevacizumab are widely used to treat neovascular AMD. However, VEGF is essential for biologic functions such as blood pressure regulation. Indeed, anti-VEGF intravenous administration is associated with hypertension. Therefore, the effect of ITV bevacizumab on retinal circulation was examined.

**METHODS.** Twenty-three patients with neovascular AMD treated with three repeat ITV injections of bevacizumab were recruited. Blood arteriolar diameter and flow measurements were performed with a bidirectional laser Doppler flowmeter at baseline, 1 week after the first injection, just before the second injection, and 5 weeks after the third injection. Scanning laser Doppler flowmetry was used to assess the effect of bevacizumab on tissue perfusion at the first and fourth visits.

**RESULTS.** Arteriolar diameter significantly decreased from  $122.5 \pm 14.5 \mu\text{m}$  to  $118.9 \pm 14.0 \mu\text{m}$  ( $P = 0.03$ ) during the first week to reach a mean value of  $117.2 \pm 13.7 \mu\text{m}$  at the end of the study ( $P < 0.01$ ). Arterial blood flow did not change significantly. Neuroretinal rim perfusion decreased from  $181.1 \pm 84.1$  arbitrary flow units to  $167.7 \pm 76.5$  arbitrary flow units, which was borderline significant ( $P = 0.06$ ). No significant change was observed in the peripapillary retina.

**CONCLUSIONS.** Arteriolar diameter decreased significantly after the first injection and persisted until the end of the study suggesting a long-term effect of bevacizumab on vascular tone. However, the blood flow change is not significant. A borderline significant decrease in neuroretinal rim perfusion was observed and suggests that the neuroretinal rim may be more sensitive than the peripapillary retina to the effects of bevacizumab. (*Invest Ophthalmol Vis Sci.* 2011;52:7400-7405) DOI:10.1167/iovs.10-6646

From the <sup>1</sup>Department of Ophthalmology, Faculty of Medicine, and the <sup>2</sup>School of Optometry, University of Montréal, Montréal, Québec, Canada; and the <sup>3</sup>Maisonneuve-Rosemont Hospital Research Centre, Montréal, Québec, Canada.

Presented at the annual meeting of the Association for Research in Vision and Ophthalmology, Fort Lauderdale, Florida, May 2009.

Supported by the Fonds de Recherche en Ophthalmologie de l'Université de Montréal (MRL, SO), Fonds de la Recherche en Santé du Québec (FRSQ) Vision Research Network (MRL, EV), and the Canada Foundation for Innovation (MRL, EV).

Submitted for publication September 30, 2010; revised March 6, 2011; accepted May 1, 2011.

Disclosure: **O. Fontaine**, None; **S. Olivier**, None; **D. Descovich**, None; **G. Cordahi**, None; **E. Vaucher**, None; **M.R. Lesk**, None

Corresponding author: Mark R. Lesk, Ophthalmology Research Unit (room F117), Maisonneuve-Rosemont Hospital Research Centre, 5415 L'Assomption Boulevard, Montreal, QC, Canada H1T 2M4; lesk@videotron.ca.

Ocular diseases involving angiogenesis are particularly destructive to central visual acuity. Among those, AMD is a leading cause of severe visual loss in industrialized countries.<sup>1</sup> Many studies bring to light the essential role of VEGF in choroidal neovascularization (CNV) through its effect on proliferation, migration, and cell differentiation.<sup>2</sup> In humans, VEGF levels seem to be correlated to the degree of the activation of neovascularization and vascular permeability.<sup>3</sup> VEGF therefore appears to be the most prominent molecule inducing neovascularization, and consequently, treatments inhibiting VEGF bioactivity have been widely used as the new paradigm to treat neovascular AMD.

Bevacizumab, a full-length anti-VEGF antibody approved for systemic use in some solid tumors, is the prime molecule used to treat CNV by intravitreal injection (ITV). Its efficacy is related to its property to inhibit all VEGF-A isoforms.<sup>4</sup> This off-label use was first reported by Rosenfeld et al.<sup>5</sup> and has led to many subsequent studies on the innocuity and the effectiveness of this anti-VEGF molecule.<sup>6</sup> Even if the use of bevacizumab can be theoretically associated with serious ocular adverse side effects, many clinical studies have shown that ITV injections of bevacizumab are well tolerated.<sup>7-9</sup> However, intravenous injections of bevacizumab have been associated with an increase in systemic arterial blood pressure in patients with neovascular AMD.<sup>5</sup> This effect could be explained by the role of VEGF in the vasomotor tone regulation by activation of endothelial nitric oxide synthase (eNOS) and subsequent production of nitric oxide (NO), a potent vasodilator.<sup>10</sup> The common use of intravitreal bevacizumab limits systemic exposure to the anti-VEGF drug but directly exposes the retina. VEGF is present in the retina under physiological conditions and can regulate the vasomotor tone in ocular tissues.<sup>11</sup> The goal of this prospective study was to assess the long-term effect of ITV of bevacizumab on vascular tone and on retinal blood flow including the neuroretinal rim (RIM) in AMD patients.

## METHODS

### Prospective Study

The research protocol was approved by the ethics committee of Maisonneuve-Rosemont Hospital, Montréal, Québec, and adhered to the tenets of the Declaration of Helsinki. Twenty-three patients with neovascular AMD were recruited after standard ophthalmologic examination. The diagnosis of neovascular macular degeneration was based on the presence of angiographic subtypes of choroidal neovascularization secondary to AMD. When a patient was considered to have a clinical indication for ITV bevacizumab treatment, they were assessed for eligibility for this prospective study. Patients with uncontrolled hypertension, a history of myocardial infarction or cerebral vascular accident, media opacities or insufficient pupillary dilatation preventing arteriolar laser Doppler blood flow measurement, or abnormal ocular

findings other than AMD or pseudophakia were excluded from the study. One eye per patient was included. If both eyes were eligible, the eye with the clearest media was chosen. Informed consent was obtained for all participants after explanation of the nature and possible consequences of the study.

Systemic arterial blood pressure and an ophthalmologic examination were performed at each of the four visits required for the study. This examination included medical and ocular histories, visual acuity with a pinhole using an Early Treatment of Diabetic Retinopathy Study chart, biomicroscopy, IOP measurement using Goldman applanation tonometry, and fundus examination. Central retinal thickness (CRT) using the 1-mm center of the macular retinal map obtained by optical coherence tomography (Stratus OCT; Carl Zeiss, Dublin, CA) was also measured for all studied eyes at the first and the fourth visits.

### Intravitreal Injection of Bevacizumab

The preparation of bevacizumab (Genentech, San Francisco, CA) was performed using a standard aseptic technique under a laminar flow hood to divide the commercially available solution (100 mg/4 mL) into 1-mL tuberculin syringes containing 0.05 mL of bevacizumab. The injections of bevacizumab were performed using a standard aseptic protocol, including the use of a topical anesthetic, povidone-iodine scrubbing of the ocular surface, and a sterile speculum. Gatifloxacin or moxifloxacin was applied three times daily 1 day before the injection and 5 days after the injection. A subconjunctival injection of lidocaine 2% was performed in the inferotemporal quadrant where the ITV injection was to be given. Bevacizumab was injected into the vitreous cavity through the pars plana 3.5 to 4 mm posterior to the limbus using a sterile 30-gauge needle. Three injections of bevacizumab (1.25 mg/0.05 mL) were performed at 5- to 7-week intervals.

### Arteriolar Diameter and Blood Flow Measurements

A Canon Laser Blood Flowmeter (CLBF100; Canon, Tokyo, Japan) was used at each visit, namely before the first injection, 1 week after the first injection, 5 weeks after the first injection, and 5 weeks after the third injection to assess the possible change of diameter and blood flow on the same major retinal arteriole related to the presence of ITV bevacizumab. CLBF is a noninvasive bidirectional laser Doppler velocimeter that directly measures the Doppler shift of the backscattered light from the red blood cells with a red diode laser (675 nm). This device has an eye movement detector to allow for the adequate position of the laser beam on the centerline of the vessel during the time measurement of the velocity. It is also equipped with a green vessel tracking HeNe laser that measures vessel diameter. With the obtained blood velocity and vessel diameter values, the machine provides retinal blood flow in microliters per minute. A minimum of five measurements were taken in a major retinal arteriole after the first bifurcation, if possible, and all good quality measurements were used for analysis. Good quality of measurement was defined according to the CLBF analysis software by a Q index between three to five relative units, considering both incident path beams. Previous studies describe the device and procedure in detail.<sup>12,13</sup> The segment of the target vessel was marked on fundus photographs for subsequent measurements.

To assess the effect of an eventual arteriolar diameter change on tissue perfusion, RIM and peripapillary retinal blood flow were measured using scanning laser Doppler flowmetry (SLDF; Heidelberg Retina Flowmeter; Heidelberg Engineering, Germany, and SLDF software v 3.3<sup>14,15</sup>) at the first and the fourth visits. We used mean values from the three to five highest quality SLDF images in terms of focusing, centering, brightness, and absence of movement as previously described elsewhere.<sup>16,17</sup> The SLDF parameter flow in all valid pixels overlying the RIM and the peripapillary retina was used to determine RIM and peripapillary blood flow in arbitrary flow units (AU). This technique measures blood flow in perfused tissue between the visible blood vessels.

### Statistical Analysis

Values are presented as mean  $\pm$  SD. Sample size calculation considering the mean variable, retinal arteriolar diameter, indicated that a sample size of 15 subjects achieves 81% power to detect a difference of 5% between visits with a significance level (alpha) of 0.008 using a two-sided one-sample *t*-test. Previous coefficient of variation for this device obtained on healthy subjects in our laboratory was used to perform the sample size calculation. This sample size was calculated with Bonferroni correction to counteract the six implicit paired comparisons by time. Therefore, an alpha level of 0.008 was used to take the effect of the multiplicity of statistic tests into account and to finally conserve a global alpha level of 0.05. Statistical analysis was performed using statistical software (SPSS software, v 17.0; SPSS Inc., Chicago, IL). Repeated measures analysis of variance and the post-hoc test if necessary were used for all continuous variables except for variables concerning SLDF data and optical coherence tomography data where paired Student's *t*-tests were performed.  $P \geq 0.05$  was considered statistically significant.

## RESULTS

### Subject Population

Four subjects were not present at one of the four visits and were therefore excluded from the study. One patient interrupted his antihypertensive medication during the study and was also excluded. Proper CLBF measurement data were obtained on 18 subjects (9 men and 9 women) and were included in the analysis. SLDF measurement data were obtained on 16 subjects among all included subjects. The mean age ( $\pm$  SD) was  $71.8 \pm 7.9$  years (range, 56–84 years). Fourteen patients (77.8%) had systemic hypertension and received systemic therapy. These treatments did not change during the study. Three patients (16.7%) had diabetes mellitus. These patients were well controlled and had no signs of diabetic retinopathy.

### Visual Acuity and CRT

One week after the first injection, the mean visual acuity (VA) changed from logMAR  $0.79 \pm 0.74$  to  $0.66 \pm 0.60$  ( $P = 0.09$ ), but this improvement reached significance only 5 weeks after the first injection (logMAR  $0.54 \pm 0.39$ ;  $P = 0.02$ ). Five weeks after the third injection, VA was still significantly improved (logMAR  $0.55 \pm 0.60$ ;  $P = 0.01$ ). The significant overall mean gain of lines was 2.4 from baseline to 5 weeks after the third injection. Two patients had counting finger acuity in the study eye at the beginning of the study. According to convention, counting fingers at a distance of 1 foot was converted to logMar 2.6 for VA calculation.

A significant decrease from  $305 \pm 99 \mu\text{m}$  to  $238 \pm 87 \mu\text{m}$  in CRT was observed at 5 weeks after the third injection. This change represents a significant overall decrease of 22.0% ( $P < 0.01$ ). Measurement data are summarized in Table 1.

### CLBF Measurement of Vessel Diameter and Retinal Thickness

The arteriolar diameter in the 18 patients decreased significantly from  $122.5 \pm 14.5 \mu\text{m}$  to  $118.9 \pm 14.0 \mu\text{m}$  ( $P = 0.03$ ) 1 week after the first injection. This decrease remained stable 5 weeks after the first injection. At 5 weeks after the third injection, which was a mean time of 16.5 weeks after the baseline examination, the arterial diameter significantly decreased to  $117.2 \pm 13.7 \mu\text{m}$  compared to baseline, which represents an overall significant decrease of 4.3% ( $P < 0.01$ ; Fig. 1). No significant velocity change was observed during any visit ( $P = 0.27$ ). The arteriolar blood flow was not changed 1 week after the first injection ( $11.0 \pm 3.5 \mu\text{L}/\text{min}$  to  $10.9 \pm 2.5 \mu\text{L}/\text{min}$ ;  $P = 0.15$ ). A slight continuous decrease (9.8%) was

TABLE 1. Measurements of Clinical Parameters at the Four Visits

	Visit No.				P
	1	2	3	4	
Mean VA, logMAR	0.79 ± 0.74	0.66 ± 0.60	0.54 ± 0.39	0.55 ± 0.60	0.01*
CRT, $\mu\text{m}$	305 ± 99	—	—	238 ± 87	<0.01*
Calculated OPP, mm Hg	49.3 ± 5.5	47.5 ± 7.0	48.5 ± 7.1	45.6 ± 5.1	0.07

OPP was calculated according to the following formula:  $\text{OPP} = 2/3 [\text{diastolic blood pressure} + 1/3 (\text{systolic blood pressure} - \text{diastolic blood pressure})] - \text{IOP}$ . Values are presented as mean  $\pm$  SD. CRT, central retinal thickness; VA, visual acuity; OPP, ocular perfusion pressure.

\*  $P < 0.05$  obtained using repeated measures analysis of variance for mean VA and using the paired Student's *t*-test for CRT.

observed until 5 weeks after the third injection, where a mean arteriolar blood flow value of  $10.0 \pm 2.7 \mu\text{L}/\text{min}$  was recorded. However, this did not reach statistical significance ( $P = 0.08$ ). CLBF measurement data were summarized in Table 2.

### Ocular Blood Circulation Measured Using SLDF

Among the 16 subjects that had SLDF imaging, one presented with large areas of peripapillary atrophy. Consequently, the results for this subject were computed only for the RIM analysis because of the absence of neuroretinal tissue adjacent to the optic disc border. The RIM blood flow decreased from  $181.1 \pm 84.1 \text{ AU}$  to  $167.7 \pm 76.5 \text{ AU}$ . This decrease of 7.4% was of borderline significance ( $P = 0.06$ ). For the temporal and nasal peripapillary retina, the observed changes respectively from  $236.9 \pm 89.2 \text{ AU}$  to  $230.0 \pm 72.8 \text{ AU}$  and from  $264.5 \pm 74.8 \text{ AU}$  to  $253.4 \pm 85.7 \text{ AU}$  were not significant ( $P = 0.48$  and  $P = 0.38$  respectively). SLDF measurement data are summarized in Table 2. No statistical difference was observed in the mean of calculated ocular perfusion pressure during any visit. Measurements of these parameters are summarized in Table 1.

### DISCUSSION

The effect of bevacizumab treatment for preservation of vision and blood flow was investigated in neovascular AMD patients. Our results showed an improvement in visual acuity and CRT after the ITV injection of bevacizumab. The diameter of arteries was significantly decreased, but the changes on the ocular

blood flow did not reach statistical significance. It is not clear whether the measurement of a nonsignificant change in blood flow despite a significant effect on the vessel diameter is related to technical limitations of the CLBF and SLDF. It cannot be concluded that repeat ITV injections of bevacizumab are completely safe for ocular blood perfusion.

The experimental design of this study did not include a control group receiving ITV injections of buffered saline solution or human IgG because of ethical reasons. Even if it is unlikely that the ITV injection itself has any intrinsic influence on retinal circulation at mid-term or long-term, this possibility cannot be entirely excluded.

### Effects of ITV Bevacizumab on Retinal Arteriolar Blood Diameter and Flow

This study shows that retinal arteriolar diameter decreases significantly in patients with neovascular macular degeneration after the ITV injection of bevacizumab. In addition, the decrease in the arteriolar diameter was observed 1 week after the first injection, and this decrease continued until the end of the study, suggesting a long-term effect of bevacizumab on vascular tone.

Bonnin et al.<sup>18</sup> has recently shown a 10% decrease of time-averaged mean blood flow velocity in the central retinal artery 4 weeks after a single ITV injection of bevacizumab using ultrasound imaging. Arterial blood flow velocity assessed upstream of an organ provides an indirect estimate of the downstream vascular resistance.<sup>19</sup> Therefore, the arterial blood flow velocity recorded upstream of the retina can reflect its vascular resistance. If the central retinal artery diameter did not change during their study, the 10% decrease of the blood flow velocity in central retinal artery was in accordance with the 9.1% decrease of retinal blood flow observed in our study. A prospective study of Soliman et al.<sup>20</sup> on 10 eyes has also shown a decrease in retinal arterial and vein diameter of 0.2% and 1.9%, respectively, after three bevacizumab injections. However, these vessel diameter decreases did not reach statistical significance. The retinal vessel diameter was assessed at baseline and 1 month after the third injection using early phase fluorescein angiograms coupled with customized software. The modest and nonsignificant decrease observed by Soliman et al.<sup>20</sup> differs from our results that revealed a significant vasoconstrictive effect of bevacizumab. Another researcher revealed significant retinal arteriolar vasoconstriction in patients with neovascular AMD after three ITV injections of ranibizumab, an anti-VEGF molecule that is similar to bevacizumab.<sup>21</sup> Indeed, ranibizumab, like bevacizumab, neutralizes all isoforms of VEGF<sup>2</sup> and may potentially have similar ocular adverse effects. These researchers found a significant mean decrease of 8.1% and 17.6%, respectively, 4 weeks after the first injection and 4 weeks after the third injection. These changes, observed with the retinal

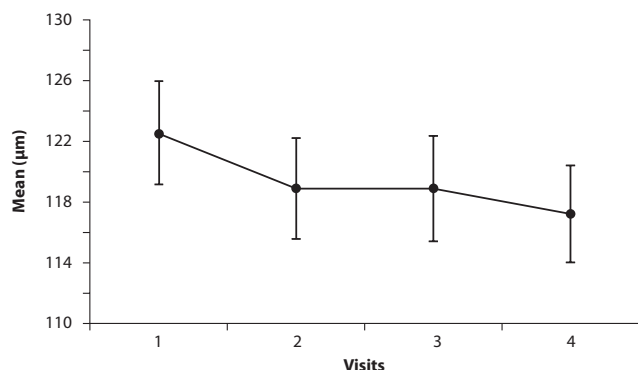


FIGURE 1. Laser Doppler arteriolar diameter. A significant decrease in arteriolar diameter was observed at first week after ITV injection. This decrease remained stable at 5 weeks after the first injection. At visit four (mean, 16.5 weeks after baseline examination), the decrease in arteriolar diameter was more pronounced. This strongly suggests a retinal vasoconstrictive effect of bevacizumab when injected in the vitreous body. Error bars represent the SEM.

TABLE 2. CLBF and SLDF Measurements

	Visit No.				P
	1	2	3	4	
CLBF ( <i>n</i> = 18)					
Diameter, $\mu\text{m}$	122.5 $\pm$ 14.5	118.9 $\pm$ 14.0	118.9 $\pm$ 14.6	117.2 $\pm$ 13.7	<0.01*
Velocity, mm/min	30.6 $\pm$ 6.6	32.4 $\pm$ 4.6	31.0 $\pm$ 6.4	30.5 $\pm$ 5.3	0.27
Flow, $\mu\text{L}/\text{min}$	11.0 $\pm$ 3.5	10.9 $\pm$ 2.5	10.3 $\pm$ 2.9	10.0 $\pm$ 2.7	0.08
SLDF ( <i>n</i> = 16)					
Nasal retinal flow, AU	264.5 $\pm$ 74.8	—	—	253.4 $\pm$ 85.7	0.38
RIM flow, AU	181.1 $\pm$ 84.1	—	—	167.7 $\pm$ 76.5	0.06
Temporal retinal flow, AU†	236.9 $\pm$ 89.2	—	—	230.0 $\pm$ 72.8	0.48

Values are presented as mean  $\pm$  SD.

\*  $P < 0.05$  using repeated measures analysis of variance.

†  $n = 15$  for the peripapillary retinal flow.

vessel analyzer (Zeiss FF, Jena, Germany), were highly significant and represent an overall decrease that is more pronounced than the decreased observed in our study. These results taken as a whole might suggest a more pronounced effect of ranibizumab than bevacizumab on vascular tone. Prospective studies comparing both anti-VEGF molecules are needed to assess this hypothesis.

While the arteriolar diameter decreased significantly by a mean 4.3% during our study, the mean flow decreased by 9.1% over the same period but did not reach statistical significance, probably because of high variability. Blood flow is calculated according to Poiseuille's law, and because it depends directly on the square of the diameter (and on the velocity, which was virtually unchanged), we expected to observe a significant change in arteriolar blood flow. The absence of statistically significant changes in blood flow could be related to diverse limitations of the velocimetry technique; therefore, the most important and reliable result would be the decrease in arterial diameter.<sup>13,22</sup> The coefficient of variation for diameter (2.0%) is smaller than for velocity and flow (19.9% and 19.3%, respectively).<sup>22</sup> The variability in velocity would therefore be the primary source of the variability of flow, and is induced by the patient's eye motion and centerline displacement of the laser beam.<sup>22</sup> Because of parabolic blood flow—with faster blood flow in the center of the vessel—a small displacement of the laser beam will bias the velocity measurement, thereby decreasing the measured velocity and increasing measurement variability. Moreover, the accuracy of the eye movement detector that maintains the laser beam at the centerline of the vessel depends on the contrast of the retinal vessel against the local fundus background and also on the noise source picked up by the detector.<sup>23</sup> Imperfect media in our neovascular AMD patients could have decreased the accuracy of the eye movement detector and increased measurement variability in our study. Another source of measurement variability in our study relates to the ocular surface. Symptoms and signs of dry eyes, especially for the tear film break-up time,<sup>24</sup> increase significantly with aging.<sup>24,25</sup> A break-up of the tear film during the measurement can disrupt the anterior cornea power and cause a drift of the laser beam away from the center of the vessel. The decrease in fixation, media clearness, and tear break up time can contribute to an increase in the coefficients of variability, especially for velocity and flow, thereby contributing to a statistical assessment of the blood flow decrease as not significant. The vessel diameter is assessed by a separate laser segment integrated into the CLBF and placed perpendicularly to the target vessel. This technology is less sensitive to the above factors. These discrepancies could have been counteracted by increasing the sample size. A post-hoc sample size calculation for the variable retinal arteriolar blood flow indicated that 66 subjects

would have been necessary to achieve adequate power. This sample size was calculated with a two-sided one-sample *t*-test considering the Bonferroni correction to conserve a global alpha level of 0.05.

### Effects of ITV Bevacizumab on Retinal Tissue Perfusion

No significant change was observed in the perfusion of the peripapillary retina. However, the mean 7.4% decrease in RIM area perfusion was of borderline significance. Because the blood supply is provided by an arterial terminal system without anastomoses, a decrease in arteriolar blood supply should theoretically lead to a decrease in tissue perfusion. In this study, the decrease in arteriolar diameter seems to be sufficient to generate a decrease in tissue perfusion in the RIM area but not in the peripapillary retina. It can therefore be hypothesized that the RIM area could be more sensitive than the peripapillary retina to an overall decrease in retinal arteriolar diameter. This higher sensitivity of the RIM area compared to peripapillary retina when a change in blood supply occurs might be physiologically plausible. Indeed, these differences between tissue area perfusion after change in blood supply have been previously observed in other contexts.<sup>16</sup> An alternate explanation for the decrease in rim perfusion in the absence of change of perfusion in the peripapillary retina is that the SLDF detected a small portion of perfusion from the deeper circulation dependent on the short posterior ciliary arteries, and that there was a decrease in this circulation in response to bevacizumab.

The SLDF full-field perfusion analysis software that we used has been shown to improve the reproducibility of the device for tissue perfusion measurements.<sup>14</sup> However, a study previously published by our laboratory<sup>17</sup> showed coefficients of variation for nasal, rim, and temporal blood flow of 28.6%, 34.2%, and 27.8%, respectively, in healthy patients with a mean age of 63.6  $\pm$  9.8 years. Therefore, reliability can be qualified as intermediate and can partially explain the borderline significance of the change in RIM blood flow when a highly significant arteriolar retinal vasoconstriction was observed. Indeed, the SLDF technique suffers from several limitations. Many researchers have found that flow values can vary widely depending on the brightness of the image during acquisition.<sup>26–28</sup> Media opacities and short tear break-up time can strongly influence the brightness of the image, increasing the variability of the tissue perfusion. Even if the media opacities are clinically insignificant, their presence degrades the quality of the images and increases the underlying noise, thereby generating an increase in perfusion values.<sup>29</sup> Regional variation in media opacities can also artifactually change the perfusion measurements with eye movements and with change in the body

position of the subjects during the test. All of these discrepancies can contribute to difficulties in obtaining a significant decrease in RIM perfusion despite a significant vasoconstrictive effect on retinal arterioles.

### Effects of ITV Bevacizumab on Retinal Circulation

The blockade of VEGF by the anti-VEGF bevacizumab increased retinal vascular tone, which could result in altered regulation of the NO pathway.<sup>10</sup> NO is synthesized by eNOS, which is mainly expressed by vascular endothelial cells in the choroidal vessels,<sup>11,30</sup> retinal vessels<sup>30,31</sup> and pericytes<sup>32</sup> of the retinal capillaries. Therefore, the presence of an anti-VEGF antibody like bevacizumab could interfere with the NO pathway in the retinal vasculature and could counteract the normal blood flow autoregulation.

There is growing evidence that VEGF is not specific to endothelial cells and that it interacts with many other cell types.<sup>33</sup> Numerous nonvascular cells express VEGFR2, the major VEGF receptor.<sup>33,34</sup> Its association with the ligand VEGF can promote proliferation, differentiation, or survival on these cells.<sup>34</sup> Recent studies have revealed that VEGF has a neuroprotective effect for retinal ganglion cells,<sup>35</sup> Müller cells, and photoreceptors<sup>34</sup> under normal conditions. Therefore, a decrease in VEGF below the physiological level caused by bevacizumab in patients with AMD could theoretically increase the structural impairment observed in the natural history of the disease.<sup>36</sup>

### CONCLUSION

Our study suggests that the therapeutic use of ITV bevacizumab affects retinal arteriolar vascular tone and, potentially, retinal blood flow. Moreover, our findings suggest that the RIM tissue perfusion may be more sensitive to an overall decrease of arteriolar vascular tone, although rim perfusion changes did not reach statistical significance in this study. The overall decrease in retinal blood flow could potentially lead to numerous harmful effects on structure and function of the retina and the optic nerve head. Because some patients with neovascular AMD may potentially require ITV injections of bevacizumab on a regular basis to control choroidal neovascularization, these effects could have long-term consequences. The wide expression of VEGF and VEGFR2 in numerous cell types strongly suggests a role for VEGF signaling in retinal homeostasis, not only on endothelial cells and vascular tone. Additional studies are required to confirm the effect of ITV bevacizumab on retinal blood flow and to assess its effect on retinal function.

### References

- Kulkarni AD, Kuppermann BD. Wet age-related macular degeneration. *Adv Drug Deliv Rev.* 2005;57:1994-2009.
- Shams N, Ianchulev T. Role of vascular endothelial growth factor in ocular angiogenesis. *Ophthalmol Clin North Am.* 2006;19:335-344.
- Aiello LP, Avery RL, Arrigg PG, et al. Vascular endothelial growth factor in ocular fluid of patients with diabetic retinopathy and other retinal disorders. *N Engl J Med.* 1994;331:1480-1487.
- Moshfeghi AA, Rosenfeld PJ, Puliafito CA, et al. Systemic bevacizumab (Avastin) therapy for neovascular age-related macular degeneration: twenty-four-week results of an uncontrolled open-label clinical study. *Ophthalmology.* 2006;113:2002.e1-2002.e12.
- Michels S, Rosenfeld PJ, Puliafito CA, Marcus EN, Venkatraman AS. Systemic bevacizumab (Avastin) therapy for neovascular age-related macular degeneration twelve-week results of an uncontrolled open-label clinical study. *Ophthalmology.* 2005;112:1035-1047.
- Schouten JS, La Heij EC, Webers CA, Lundqvist IJ, Hendrikse F. A systematic review on the effect of bevacizumab in exudative age-

related macular degeneration. *Graefes Arch Clin Exp Ophthalmol.* 2009;247:1-11.

- Avery RL, Pearlman J, Pieramici DJ, et al. Intravitreal bevacizumab (Avastin) in the treatment of proliferative diabetic retinopathy. *Ophthalmology.* 2006;113:1695.e1-1695.e15.
- Fung AE, Rosenfeld PJ, Reichel E. The International Intravitreal Bevacizumab Safety Survey: using the internet to assess drug safety worldwide. *Br J Ophthalmol.* 2006;90:1344-1349.
- Rich RM, Rosenfeld PJ, Puliafito CA, et al. Short-term safety and efficacy of intravitreal bevacizumab (Avastin) for neovascular age-related macular degeneration. *Retina.* 2006;26:495-511.
- Michel JB. Role of endothelial nitric oxide in the regulation of the vasomotor system [in French]. *Pathol Biol (Paris).* 1998;46:181-189.
- Brylla E, Tschedschilsuren G, Santos AN, Nieber K, Spänel-Borowski K, Aust G. Differences between retinal and choroidal microvascular endothelial cells (MVECs) under normal and hypoxic conditions. *Exp Eye Res.* 2003;77:527-535.
- Garcia Jr JP, Garcia PT, Rosen RB. Retinal blood flow in the normal human eye using the canon laser blood flowmeter. *Ophthalmic Res.* 2002;34:295-299.
- Yoshida A, Feke GT, Mori F, et al. Reproducibility and clinical application of a newly developed stabilized retinal laser Doppler instrument. *Am J Ophthalmol.* 2003;135:356-361.
- Michelson G, Welzenbach J, Pal I, Harazny J. Automatic full field analysis of perfusion images gained by scanning laser Doppler flowmetry. *Br J Ophthalmol.* 1998;82:1294-1300.
- Michelson G, Welzenbach J, Pal I, Harazny J. Functional imaging of the retinal microvasculature by scanning laser Doppler flowmetry. *Int Ophthalmol.* 2001;23:327-335.
- Hafez AS, Bizzarro RL, Rivard M, Lesk MR. Changes in optic nerve head blood flow after therapeutic intraocular pressure reduction in glaucoma patients and ocular hypertensives. *Ophthalmology.* 2003;110:201-210.
- Hafez AS, Bizzarro RL, Rivard M, et al. Reproducibility of retinal and optic nerve head perfusion measurements using scanning laser Doppler flowmetry. *Ophthalmic Surg Lasers Imaging.* 2003;34:422-432.
- Bonnin P, Pournaras JA, Lazrak Z, et al. Ultrasound assessment of short-term ocular vascular effects of intravitreal injection of bevacizumab (Avastin®) in neovascular age-related macular degeneration. *Acta Ophthalmol.* 2010;88:641-645.
- Sugimoto H, Kaneko T, Hirota M, Inoue S, Takeda S, Nakao A. Physical hemodynamic interaction between portal venous and hepatic arterial blood flow in humans. *Liver Int.* 2005;25:282-287.
- Soliman W, Vinten M, Sander B, et al. Optical coherence tomography and vessel diameter changes after intravitreal bevacizumab in diabetic macular oedema. *Acta Ophthalmol.* 2008;86:365-371.
- Papadopoulou DN, Mendrinou E, Mangioris G, Donati G, Pournaras CJ. Intravitreal ranibizumab may induce retinal arteriolar vasoconstriction in patients with neovascular age-related macular degeneration. *Ophthalmology.* 2009;116:1755-1761.
- Guan K, Hudson C, Flanagan JG. Variability and repeatability of retinal blood flow measurements using the Canon Laser Blood Flowmeter. *Microvasc Res.* 2003;65:145-151.
- Milbocker MT, Feke GT, Goger DG. Laser Doppler velocimetry stabilized in one dimension. *IEEE Trans Biomed Eng.* 1991;38:928-930.
- Ozdemir M, Temizdemir H. Age- and gender-related tear function changes in normal population. *Eye (Lond).* 2010;24:79-83.
- Viso E, Rodriguez-Ares MT, Gude F. Prevalence of and associated factors for dry eye in a Spanish adult population (the Salnes Eye Study). *Ophthalmic Epidemiol.* 2009;16:15-21.
- Hosking SL, Embleton S, Kagemann L, Chabra A, Jonescu-Cuypers C, Harris A. Detector sensitivity influences blood flow sampling in scanning laser Doppler flowmetry. *Graefes Arch Clin Exp Ophthalmol.* 2001;239:407-410.
- Kagemann L, Harris A, Chung HS, Evans D, Buck S, Martin B. Heidelberg retinal flowmetry: factors affecting blood flow measurement. *Br J Ophthalmol.* 1998;82:131-136.
- Tsang AC, Harris A, Kagemann L, Chung HS, Snook BM, Garzoni HJ. Brightness alters Heidelberg retinal flowmeter measurements in an in vitro model. *Invest Ophthalmol Vis Sci.* 1999;40:795-799.

29. Hayreh SS. Evaluation of optic nerve head circulation: review of the methods used. *J Glaucoma*. 1997;6:319-330.
30. Meyer P, Champion C, Schlotzer-Schrehardt U, Flammer J, Haefliger IO. Localization of nitric oxide synthase isoforms in porcine ocular tissues. *Curr Eye Res*. 1999;18:375-380.
31. Knowles RG, Moncada S. Nitric oxide synthases in mammals. *Biochem J*. 1994;298(part 2):249-258.
32. Chakravarthy U, Stitt AW, McNally J, Bailie JR, Hoey EM, Duprex P. Nitric oxide synthase activity and expression in retinal capillary endothelial cells and pericytes. *Curr Eye Res*. 1995;14:285-294.
33. D'Amore PA. Vascular endothelial cell growth factor-a: not just for endothelial cells anymore. *Am J Pathol*. 2007;171:14-18.
34. Saint-Geniez M, Maharaj AS, Walshe TE, et al. Endogenous VEGF is required for visual function: evidence for a survival role on muller cells and photoreceptors. *PLoS One*. 2008;3:e3554.
35. Kilic U, Kilic E, Jarve A, et al. Human vascular endothelial growth factor protects axotomized retinal ganglion cells in vivo by activating ERK-1/2 and Akt pathways. *J Neurosci*. 2006;26:12439-12446.
36. Medeiros NE, Curcio CA. Preservation of ganglion cell layer neurons in age-related macular degeneration. *Invest Ophthalmol Vis Sci*. 2001;42:795-803.