

Software for Reading and Grading Diabetic Retinopathy

Aravind Diabetic Retinopathy Screening 3.0

NAMPERUMALSAMY PERUMALSAMY, MD¹
NOELA M. PRASAD, MSc¹

SHANKAR SATHYA, BE²
KIM RAMASAMY, MD¹

OBJECTIVE — To evaluate the validity and reproducibility of software for reading digital images and grading diabetic retinopathy.

RESEARCH DESIGN AND METHODS — A prospective, comparative observational study was conducted on a series of patients with type 2 diabetes who presented at the retina clinic of a tertiary care center in India. A total of 210 eyes of 105 patients were allocated to one of three ophthalmologists, who performed dilated indirect and direct ophthalmoscopy and subsequently assessed the digital images of the same group of patients who were masked to the patient's identity. The interobserver and intertest agreement between clinical assessments and grading of diabetic retinopathy using the software was estimated.

RESULTS — Moderate nonproliferative diabetic retinopathy (NPDR) was most frequently diagnosed, both clinically and on evaluating digital images. The overall agreement between the clinical grading of diabetic retinopathy and the grading of images was 81.3% ($\kappa = 0.69$, SE 0.04, $P < 0.0001$); there was good agreement (81.3%) for NPDR ($\kappa = 0.61$, SE 0.05, $P < 0.0001$), but agreement was not as good (54.6%) for proliferative diabetic retinopathy ($\kappa = 0.29$, SE 0.11, $P = 0.005$). Clinically significant macular edema was diagnosed in 33.3% (70 of 210) of eyes clinically and in 40.2% (84 of 209) of eyes by grading images, and there was good agreement (89.5%) between the two ($\kappa = 0.77$, SE 0.07, $P < 0.0001$).

CONCLUSIONS — Aravind Diabetic Retinopathy Screening 3.0 is a simple and valid tool to assist in the detection of sight-threatening retinopathy and could supplement dilated fundus examinations by ophthalmologists on patients to detect diabetic retinopathy.

Diabetes Care 30:2302–2306, 2007

Diabetic retinopathy resulting from microvascular end-organ damage to the retina is found in 60% (1) of people 20 years after onset of type 2 diabetes; sight-threatening retinopathy is found in 2.0% of people who have had diabetes for <5 years and in 15.5% of people who have had diabetes for ≥ 15 years. Identifying these patients occurs primarily through opportunistic case detection (2) in a country like India (prevalence of retinopathy is 17.6% among urban diabetic subjects aged >20 years), since a routine screening program for

people known to have diabetes is not a feasible option considering the poor attendance; 11% of new diabetic subjects and 55% of known diabetic subjects attend these camps (3).

The current gold standard for diagnosing diabetic retinopathy is through fundus photography (comparing the fundus pathology with that seen on stereoscopic viewing of seven standard photographs for grading retinopathy or through fluorescein angiographic diagnosis). However, even in countries in which facilities for close monitoring of diabetes

are available, there is no consensus on cost-effective, valid methods to screen for diabetic retinopathy (4). Telemedicine has resulted in new possibilities, such as capturing images at a remote location and transmitting them to a skilled grader at a specialist center. Though reducing costs while maintaining good quality care, the deployment of telemedicine intensifies the need to validate using digital images as a tool for diagnosing diabetic retinopathy and following its progression (5,6). This study compares the Aravind Diabetic Retinopathy Screening (ADRES) 3.0 reading and grading system with clinical assessments as the current practice gold standard with regard to its validity and reproducibility in the assessment of diabetic retinopathy.

RESEARCH DESIGN AND METHODS

A prospective, comparative observational study was conducted on a series of patients with type 2 diabetes who presented for the first time at the retina clinic of a tertiary care center in India. The patients who consented to participate were enrolled by the clinic coordinator during May and June 2006 and assigned to the grader (one of three trained retina specialists) who was attending to outpatients on that day.

Each patient underwent a routine detailed comprehensive ophthalmic examination by any single grader, and digital fundus photographs were taken by a technician through the dilated pupil. The same three clinicians subsequently graded the digital images using the manual software ADRES 3.0 reading and grading system while being masked to the clinical grading assigned to individual patients. For the sake of comparability, all three graders were assigned five consecutive patients on the last day of enrollment, which they assessed independently in the same manner.

The eye examination included measurement of Snellen's visual acuity, slit-lamp biomicroscopy aided with the three-mirror contact lens when required, dilated funduscopy using a 60- or 90-dioptre lens, and indirect ophthalmos-

From the ¹Aravind Eye Care System, Madurai, India; and ²Eagle Software, Santa Ana, California.

Address correspondence and reprint requests to Noela M. Prasad, Aravind Eye Care System, 1, Annanagar, Madurai 625 020, India. E-mail: noelaprasad@yahoo.co.in.

Received for publication 3 February 2007 and accepted in revised form 7 May 2007.

Published ahead of print at <http://care.diabetesjournals.org> on 16 May 2007. DOI: 10.2337/dc07-0225.

Abbreviations: ADRES, Aravind Diabetic Retinopathy Screening; CSME, clinically significant macular edema; NPDR, nonproliferative diabetic retinopathy; PDR, proliferative diabetic retinopathy.

A table elsewhere in this issue shows conventional and Système International (SI) units and conversion factors for many substances.

© 2007 by the American Diabetes Association.

The costs of publication of this article were defrayed in part by the payment of page charges. This article must therefore be hereby marked "advertisement" in accordance with 18 U.S.C. Section 1734 solely to indicate this fact.

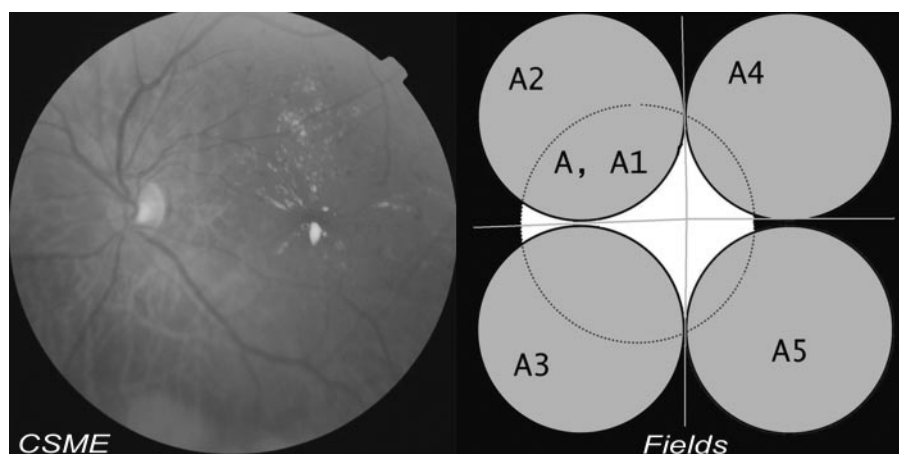


Figure 1—Stereo-photograph pair and four peripheral fields of ADRES 3.0 five 45° field protocol with a sample image.

copy. Findings from a single visit are used; progressive evaluation of retinopathy in the same patient was not conducted for this study. Clinical grading of diabetic retinopathy and of clinically significant macular edema (CSME) was based on the extension of the Airlie House classification.

The single nonsimultaneous stereoscopic pair of central images were acquired manually by horizontal translation of the fundus camera and labeled as A and A1. Four equidistant images covering the peripheral areas of the retina were also taken (Fig. 1) and were labeled A2, A3, A4, and A5, respectively. A and A1 are 45° fields, focused centrally between the temporal margin of the optic disc and the center of the macula, with the horizontal central line of the image passing through the center of the disc. Stereoscopic images are obtained by shifting the camera laterally; a slight delay between the first and the second image may be necessary to allow for adequate pupil mydriasis. A2 is a 45° field superotemporal to the optic disc so that the lower edge of the field is at a tangent to the horizontal line passing through the center of the optic disc and the nasal edge of the field is at a tangent to the vertical line passing through the center of the disc. Similar fields in the inferotemporal (A3), superonasal (A4), and inferonasal (A5) quadrants were imaged.

Grading protocol for diabetic retinopathy

Two sets of images representing each eye were verified for quality (gradability) before commencing grading. The graders entered clinical findings, which were converted to results according to a lesion

grading matrix (Table 1), based on established standard practice guidelines such as those of the Early Treatment Diabetic Retinopathy Study (7) and the American Academy of Ophthalmology's document on the International Clinical Diabetic Retinopathy Disease Severity Scale (published October 2002) (8).

ADRES system

A commercially available nonmydriatic retinal fundus camera optimized for low-light-level imaging of the retina (TOPCON, TRC-NW100) with the capability to provide up to 2.3 million-pixel, high-quality spatial, contrast and color resolu-

tion images (Fig. 1) was used. This fundus camera is lightweight and energy efficient and was optimized for acquiring high-quality retinal images in low-light-level conditions with the lowest available flash intensities. It was interfaced with ADRES 3.0, the image capture and telemedicine software developed in house to acquire standard single-frame digital color images of the retina.

At the acquisition unit, a standard Windows-Intel-compatible desktop running the Windows XP operating system was used to capture relevant structured and unstructured clinical data, which was transmitted after being decomposed to form XML (eXtensible Mark-Up Language) structures. Images captured using a USB interface through TWAIN protocol at maximum resolution were compressed and stored in a DICOM (Digital Imaging and Communications in Medicine) 3 file format along with the other information, enabling each image to be uniquely associated with a patient before transmission. Images transmitted to the remote grading center using a 384-Kbps very small aperture terminal connection were filtered, indexed, and filed in a robust and reliable RAID (redundant array of independent drives)-3 network attached storage unit with a tape backup system.

At the grading station, Windows-Intel-compatible professional desktops were deployed with a high-end graphics card (3Dlabs oxygen GVXI), 21-inch 100-

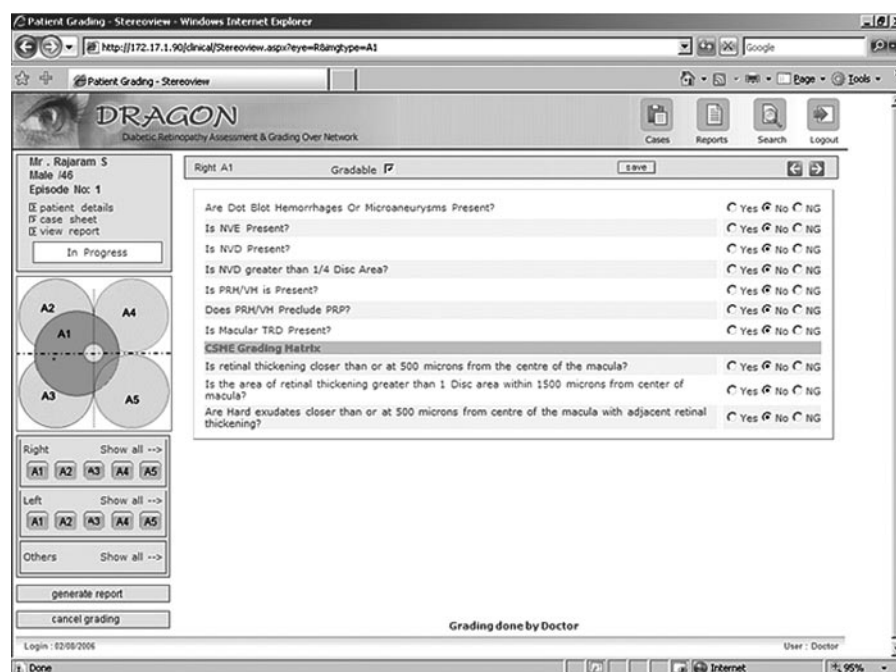

Figure 2—The ADRES 3.0 data input screen.

Table 1—Diabetic retinopathy lesion grading matrix for ADRES 3.0

Lesions	Images to be assessed	Grading inputs
Field not readable	A, A1, A2, A3, A4, A5	
Microaneurysms	A, A1, A2, A3, A4, A5	Present/absent
Hemorrhages	A, A1, A2, A3, A4, A5	Hemorrhages present; compare with standard photograph 2A, noting whether they are less than in the standard photograph or more than/equal to that seen in the standard photograph.
Hard exudates	A, A1, A2, A3, A4, A5	Present/absent
Cotton wool spots	A, A1, A2, A3, A4, A5	Number of lesions
Retinal thickening	A, A1	Number of areas present of size less than one disc area and number more than/equal to one disc area in size; distance of the retinal thickening from center of macula in microns (<500, 500–1,500, >1,500 microns).
Venous beading	A, A1	Number present that are larger than that seen in standard photograph 6A; number of size less than one-fourth of the disc area and number equal to/more than one-fourth of the disc area in size.
Intraretinal microangiopathy	A2, A3, A4, A5	Number present that are larger than that seen in standard photograph 8A; number of size less than half the disc area and number equal/more than half the disc area in size.
Neovascularization disc	A, A1	Present/absent
Neovascularization elsewhere	A2, A3, A4, A5	Present/absent
Disc oedema	A, A1	Present/absent
Preretinal hemorrhage	A, A1, A2, A3, A4, A5	Present/absent
Vitreous hemorrhage	A, A1, A2, A3, A4, A5	Present/absent
Fibrovascular proliferation disc	A, A1	Present/absent
Fibrovascular proliferation elsewhere	A2, A3, A4, A5	Present/absent
Tractional retinal detachment	A, A1, A2, A3, A4, A5	Present/absent
Occluded vessels	A, A1, A2, A3, A4, A5	Present/absent

MHz refresh-rate true-color monitors, and three-dimensional revelator infrared version goggles for stereo viewing. The software enabled the simultaneous reading of patient and standard images in dual monitors, along with the patient demographics and clinical information, and flexible integrated templates enabled objective online grading of images (Fig. 2).

Ethical issues

Patients were counseled about the disease, and their informed consent for participation in the validation study was obtained before allocation. The study had been presented to and approved by the research committee of Aravind Eye Care System.

RESULTS— One hundred and five patients were enrolled. The population averaged 53.5 years of age (95% CI 52.46–54.51), and the duration of diabetes ($n = 104$) averaged 9.3 years (8.2–10.3). Overall, 13.3% of eyes (28 of 210) had mild nonproliferative diabetic retinopathy (NPDR), 57.1% (120 of 210) had moderate NPDR, 13.8% (29 of 210) had severe NPDR, and 15.7% (33 of 210) had

proliferative diabetic retinopathy (PDR) on clinical grading. While grading the images, one image was ungradable and one had no diabetic retinopathy. Of the remaining 208 images, 13.8% had mild NPDR, 59.3% had moderate NPDR, 11% had severe NPDR, and 15.3% had PDR. The overall agreement between the clinical grading of diabetic retinopathy and the grading of images was good (Table 2). There was very good agreement (81.3%) for NPDR, but agreement was not as good (54.6%) for PDR.

CSME was diagnosed on 32.1% (25 of 78) of eyes by grader 1, on 64.8% (95 of 142) of eyes by grader 2, and on half of the 10 eyes that grader 3 assessed clinically. The corresponding proportions for grading using ADRES for the three graders were 34.5% (49 of 142), 27.3% (21 of 77), and 36.4% (76 of 209), respectively. Overall, CSME was diagnosed in 33.3% (70 of 210) of eyes clinically and in 40.2% (84 of 209) of eyes by grading images, and there was good agreement between the two assessments.

Compared with the grading on clinical assessment, 3.6% of mild NPDRs were graded as less advanced disease on assess-

ment of the images, and 21.4% were graded as more advanced disease on the images. For clinically moderate NPDR, there were 6.7% graded lower on imaging and 5.1% graded higher, and for severe NPDR these proportions were 34.5 and 6.9, respectively. For clinical PDR, 18.2% were graded as having less severe disease on imaging.

The interobserver agreement between the diagnoses made by the three graders on clinical examination of the fundus and that made on manual grading of the fundus images was assessed (Table 2). Agreement between graders 1 and 2 was good for clinical assessment of diabetic retinopathy and CSME and for their assessment of images. Agreement of graders 2 and 3 was poorer for both the clinical assessment and the assessment of images. Graders 1 and 3 had good agreement for their clinical assessments and for their grading of retinopathy or CSME on the images.

The current standard practice is to perform indirect ophthalmoscopy to detect and grade diabetic retinopathy and stereoscopic slit-lamp biomicroscopic examination with a magnifying lens to detect CSME; therefore, we measured the

Table 2—Interobserver and intertest agreement

Interobserver	Agreement (%)	κ (P value)	r^2 (n)
Grader 1 and grader 2			
Clinical diabetic retinopathy	70	0.57 (0.0002)	0.76 (10)
Clinical CSME	90	0.80 (0.005)	0.67 (10)
Images diabetic retinopathy	60	0.33 (0.04)	0.55 (10)
Images CSME	90	0.78 (0.006)	0.64 (10)
Grader 2 and grader 3			
Clinical diabetic retinopathy	70	0.50 (0.003)	0.79 (10)
Clinical CSME	60	0.20 (0.3)	0.04 (10)
Images diabetic retinopathy	85.7	0.73 (<0.00001)	0.74 (77)
Images CSME	79.2	0.49 (0.09)	0.24 (77)
Grader 1 and grader 3			
Clinical diabetic retinopathy	60	0.42 (0.006)	0.63 (10)
Clinical CSME	70	0.40 (0.09)	0.16 (10)
Images diabetic retinopathy	73.2	0.59 (<0.00001)	0.73 (142)
Images CSME	86.6	0.7 (<0.00001)	0.53 (142)
Intertest			
Overall	81.3	0.69 (<0.0001)	0.69 (209)
NPDR	81.3	0.62 (<0.0001)	0.47 (176)
PDR	56.4	0.29 (0.005)	0.29 (33)
CSME	89.5	0.77 (<0.0001)	0.61 (209)

sensitivity and specificity of the manual grading system to detect diabetic retinopathy and CSME compared with current practices (Table 3).

CONCLUSIONS— ADRES 3.0 is an example of an indigenously developed, user-friendly reading and grading system for diabetic retinopathy. The technology (hardware, software, and systems) utilized is simple and relatively inexpensive, though not available yet as a commercial package.

The sample population used to validate this software was comparable across graders with regard to the distribution of the severity of diabetic retinopathy. The proportion of patients with moderate to severe NPDR was higher than that of mild diabetic retinopathy in this sample, as opposed to the findings of a recent preva-

lence study (7) that used clinical examination to grade diabetic retinopathy, which found mild NPDR to be the most prevalent form of retinopathy. This could be due to sampling bias (people with more severe forms of retinopathy presenting to hospital, the differences in the definitions used, or overdiagnosis of more severe forms of retinopathy based on the criteria used for grading).

Of 97 eyes that subsequently underwent laser treatment, half had focal laser (53.6%), 39.2% had panretinal photocoagulation, and 7.2% had both treatments. ADRES 3.0 may have to be validated further against Early Treatment Diabetic Retinopathy Study standard photographs in order to determine the extent to which it can serve as a substitute or a replacement for grading diabetic retinopathy in the field of telemedicine.

Fundus photography and using ADRES 3.0 for reading and grading images proves to be a good screening test for detecting all grades of diabetic retinopathy. The high negative predictive value of this tool in ruling out the presence of sight-threatening retinopathy establishes its usefulness in the field situation, where a decision on whether to refer to the base hospital can be made by the technician in the mobile van. However, it should be noted that in this study, agreement between clinical and digital imaging assessments was lower for the more advanced levels of retinopathy.

The findings of this report suggest that ADRES 3.0 can be used to assist the detection of diabetic retinopathy, supplementing clinical examination by an ophthalmologist. Its diagnostic value in the hands of a trained technician (nonophthalmologist) grader needs to be assessed so as to make its deployment more cost-effective, and its sensitivity to detecting change will have to be studied in order to establish its usefulness in detecting progression over a long patient follow-up period. The data suggest that ADRES 3.0 has good sensitivity across the various stages of diabetic retinopathy but that specificity seems to increase in more advanced disease.

The images captured at the hospital setting were of good quality, and only one (0.5%) patient had images that were not gradable due to media opacities. The proportion of ungradable images may be higher when these images are captured from the mobile van and transmitted to a remote grader. This is another area that needs further investigation. Though a nonmydriatic camera is used, the image quality is optimal only if the pupil is at least 4 mm in diameter. The benefit of dilated fundus photography over photography through an undilated pupil also has to be assessed, especially in a country like

Table 3—Diagnostic value of image grading compared with clinical grading by ophthalmologists

Condition	Background/mild diabetic retinopathy	Moderate/severe NPDR	PDR	CSME
Proportion	23/28	135/149	27/33	68/73
Sensitivity (%) (95% CI)	82.1 (63.1–93.9)	90.6 (84.7–94.8)	81.8 (64.5–93)	93.2 (84.7–97.7)
Proportion	154/182	49/61	172/177	119/136
Specificity (%) (95% CI)	84.6 (78.5–89.5)	80.3 (68.2–89.4)	97.2 (93.5–99.1)	87.5 (80.7–92.5)
Likelihood ratio for a positive test (95% CI)	5.34 (3.64–7.82)	4.6 (2.77–7.67)	28.96 (12.03–69.75)	7.45 (4.76–11.68)
Positive predictive value (%) (95% CI)	45.1 (31.1–59.7)	91.8 (86.2–95.7)	84.4 (67.2–94.7)	80 (69.9–87.9)
Negative predictive value (95% CI)	96.9 (92.8–99)	77.8 (65.5–87.3)	96.6 (92.8–98.8)	96 (90.8–98.7)
ROC area (95% CI)	0.83 (0.76–0.91)	0.85 (0.80–0.91)	0.89 (0.83–0.96)	0.90 (0.86–0.94)

India where dark irides are predominant and are associated with smaller pupillary apertures. Pupil size is more of an issue in the mobile van setting, where ambulatory background light levels are relatively high. ADRES 3.0 is a simple and valid tool to assist the detection of both diabetic retinopathy and CSME.

Acknowledgments—This study was supported by TIFAC-CORE in Diabetic Retinopathy, a project of the Department of Science and Technology, the Government of India through its Industry Partner Topcon Singapore PTE, Ltd., Singapore.

We are grateful to K. Sooriya, the clinic coordinator; Drs. Chandramohan, Naresh, and R. Anand, who examined the eyes of patients for this study and graded images; P. John, the photographer; and R. Mahalakshmi, who revised the statistical analysis.

References

1. Klein R, Klein BE, Moss SE, Davis MD, DeMets DL: The Wisconsin Epidemiologic Study of Diabetic Retinopathy. III. Prevalence and risk of diabetic retinopathy when age at diagnosis is 30 or more years. *Arch Ophthalmol* 102:527–532, 1984
2. Thomas R, Parikh R, Paul P, Muliyl J: Population-based screening versus case detection. *Indian J Ophthalmol* 50:233–237, 2002
3. Agarwal S, Mahajan S, Padmaja KR: How high is the non-response rate of patients referred for eye examination from diabetic screening camps? *Ophthalmic Epidemiology* 12:393–394, 2005
4. Bachmann MO, Nelson SJ: Impact of diabetic retinopathy screening on a British district population: case detection and blindness prevention in an evidence-based model. *J Epidemiol Community Health* 52:45–52, 1998
5. Johnston K, Kennedy C, Murdoch I, Taylor P, Cook C: The cost-effectiveness of technology transfer using telemedicine. *Health Policy Plan* 19:302–309, 2004
6. Bursell SE, Cavallerano JD, Cavallerano AA, Clermont AC, Birkmire-Peters D, Aiello LP, Aiello LM, the Joslin Vision Network Research Team: Stereo nonmydriatic digital-video color retinal imaging compared with Early Treatment Diabetic Retinopathy Study seven standard field 35-mm stereo color photos for determining level of diabetic retinopathy. *Ophthalmology* 108:572–585, 2001
7. Wilkinson CP, Ferris FL III, Klein RE, Lee PP, Agardh CD, Davis M, Dills D, Kampik A, Pararajasegaram R, Verdaguer JT, the Global Diabetic Retinopathy Project Group: Proposed international clinical diabetic retinopathy and diabetic macular edema disease severity scales. *Ophthalmology* 110:1677–1682, 2003
8. Early Treatment Diabetic Retinopathy Study Research Group: Fundus photographic risk factors for progression of diabetic retinopathy: ETDRS report number 12. *Ophthalmology* 98:823–833, 1991
9. Rema M, Premkumar S, Anitha B, Deepa R, Pradeepa R, Mohan V: Prevalence of diabetic retinopathy in urban India: the Chennai Urban Rural Epidemiology Study (CURES) Eye Study, I. *Invest Ophthalmol Vis Sci* 46:2328–2333, 2005