

Botulinum Toxin Treatment for Oropharyngeal Dysphagia Associated With Diabetic Neuropathy

DOMENICO A. RESTIVO, MD, PHD¹
ROSARIO MARCHESI-RAGONA, MD²
GIUSEPPE LAURIA, MD³

SEBASTIANO SQUATRITO, MD⁴
DAMIANO GULLO, MD⁴
RICCARDO VIGNERI, MD⁴

OBJECTIVE — No specific treatment for oropharyngeal dysphagia related to diabetic neuropathy has been described to date. Chemical myotomy of the cricopharyngeus (CP) muscle by botulinum neurotoxin type A (BoNT/A) has been effective in reducing or abolishing dysphagia associated with upper esophageal sphincter (UES) hyperactivity of different etiologies. In the present study, we evaluated the efficacy of BoNT/A injections into the CP muscle in diabetic patients with severe oropharyngeal dysphagia associated with diabetic autonomic and/or somatic peripheral neuropathy.

RESEARCH DESIGN AND METHODS — Twelve type 2 diabetic patients with severe dysphagia for both solid and liquid foods associated with autonomic and/or peripheral somatic neuropathy were investigated. Swallowing function was evaluated by clinical examination, videofluoroscopy, and simultaneous needle electromyography (EMG) of the CP and pharyngeal inferior constrictor (IC) muscles. Clinical evaluation using a four-level dysphagia severity score was performed every other day for the 1st week and thereafter every other week until week 24. Videofluoroscopy and EMG follow-up were carried out at week 1, 4, 12, 16, 18, and 24 after BoNT/A injection. BoNT/A was injected percutaneously into the CP muscle under EMG control.

RESULTS — BoNT/A induced the complete recovery of dysphagia in 10 patients and had a significant ($P = 0.0001$, ANOVA) improvement in 2 patients within 4 ± 1.1 days (range 3–7). Clinical improvement was confirmed by videofluoroscopy and EMG.

CONCLUSIONS — Our findings suggest a potential benefit from BoNT/A treatment in dysphagia associated with diabetic neuropathy. Randomized controlled trials are needed to confirm this observation.

Diabetes Care 29:2650–2653, 2006

Swallowing permits the ingestion of fluids and food without aspiration. A number of processes are required for normal swallowing, including voluntary and reflexive motor control, as well as integrity of several cranial nerves and muscles. Disruption of normal swallowing, dysphagia, is a frequent sequela of many neurological and neuromuscular disorders (1–4).

Autonomic and/or peripheral neuropathy is a common complication of diabetes and is due to chronic hyperglycemia and diabetic microvascular disease involving vasa nervorum (5). Dysphagia has been observed in diabetic patients, but its prevalence has never been assessed. Moreover, whether dysphagia in diabetic patients is caused by diabetic neuropathy and whether the pathophysi-

ological features of nerve involvement are the same in all diabetic patients with dysphagia is not known (3,4,6). Although all phases of swallowing can be involved, oropharyngeal dysphagia due to hyperactivity of the cricopharyngeus (CP) muscle of the upper esophageal sphincter (UES) is the prevalent abnormality (3,4,6). A prospective study in 33 diabetic patients evaluated by esophageal manometry showed isolated or combined involvement of the upper and lower esophageal sphincter in ~60% of patients (6).

No medical treatment for oropharyngeal dysphagia in patients with diabetic neuropathy has been described thus far. Surgical myotomy of the CP muscle has been considered the treatment of choice for dysphagia caused by UES hyperactivity in patients with neurological and/or neuromuscular diseases. However, this treatment requires general anesthesia and is not always effective (7–9).

In the last few years, chemical myotomy of the CP muscle by botulinum neurotoxin type A (BoNT/A) has proved to be effective in reducing and even abolishing dysphagia due to UES hyperactivity of different neurological or non-neurological etiologies (10–14). This treatment is safe and can successfully be performed in patients with oropharyngeal dysphagia either as an alternative to more invasive procedures or to identify subjects who may benefit from surgical myotomy (11,13). The effects of the percutaneous injection of botulinum neurotoxin are due to the block of presynaptic release of acetylcholine and last several weeks. After this period, it is necessary to repeat the treatment to maintain the clinical benefit.

In the present study, we assessed the safety and efficacy of BoNT/A injections into the CP muscle in diabetic patients with severe oropharyngeal dysphagia associated with diabetic autonomic and/or somatic peripheral neuropathy and found this treatment to be efficacious and safe.

RESEARCH DESIGN AND METHODS

Sixty-eight type 2 diabetic patients (43 insulin dependent and 25 non-insulin dependent) with diabetes-associated peripheral somatic and/or

From the ¹Division of Neurology, Garibaldi Hospital, Catania, Italy; the ²Otolaryngology Department, University of Padua, Padua, Italy; the ³Neuromuscular Diseases Unit, National Neurological Institute “Carlo Besta,” Milan, Italy; and the ⁴Division of Endocrinology, Department of Internal and Specialistic Medicine, University of Catania, Garibaldi Hospital, Catania, Italy.

Address correspondence and reprint requests to Damiano Gullo, Division of Endocrinology, Garibaldi Hospital, via Palermo 636, Catania I-95121, Catania, Italy. E-mail: damiano.gullo@poste.it.

Received for publication 17 December 2005 and accepted in revised form 18 September 2006.

Abbreviations: BoNT/A, botulinum neurotoxin type A; CP, cricopharyngeus; EMG, electromyography; IC, inferior constrictor; UES, upper esophageal sphincter.

A table elsewhere in this issue shows conventional and Système International (SI) units and conversion factors for many substances.

DOI: 10.2337/dc05-2486

© 2006 by the American Diabetes Association.

The costs of publication of this article were defrayed in part by the payment of page charges. This article must therefore be hereby marked “advertisement” in accordance with 18 U.S.C. Section 1734 solely to indicate this fact.

Table 1—Clinical data of diabetic patients with dysphagia

Age (years)	Sex	Duration of diabetes (years)	Peripheral neuropathy	Autonomic neuropathy	NDS	Dysphagia duration (years)
59	M	12.3	N	Y	1	6.2
59	M	10.7	N	Y	1	5.4
65	F	13.1	N	Y	2	4.0
63	M	16.6	Y	Y	9	3.8
66	M	17.1	Y	Y	9	5.8
68	M	18.9	Y	Y	9	6.0
67	F	23.1	Y	Y	10	6.1
65	F	15.1	Y	Y	10	3.6
68	M	21.0	Y	Y	10	4.5
68	F	17.3	Y	Y	4	4.4
64	M	15.6	Y	Y	8	3.9
66	M	18.1	Y	Y	6	4.0

F, female; M, male; N, no; NDS, neuropathy disability score; Y, yes.

autonomic neuropathy underwent neurological examination for the presence of neurogenic dysphagia. Fourteen of 68 (20.5%) patients complained of dysphagia for both solid and liquid foods. Twelve of them (8 men, 4 women, age range 59–68 years, 9 insulin dependent and 3 non-insulin dependent) with severe dysphagia (mean duration 4.8 ± 1.0 years) for both solid and liquid foods agreed to undergo treatment with BoNT/A. The mean duration of diabetes was 8.3 ± 5.8 years (range 10.7–23.10). All patients were examined by the same neurologist (D.A.R.) and underwent brain magnetic resonance to exclude brain or brainstem involvement. Clinical data are reported in Table 1. The diagnosis of diabetic neuropathy was based on clinical and neurophysiological criteria. Somatic neuropathy was ascertained by either the modified neuropathy disability score (0–2, no neuropathy; 3–5, mild neuropathy; 6–8, moderate neuropathy; and 9–10, severe neuropathy) (15) or by the vibration perception threshold, which was assessed by a neurotensimeter at the great toe of the dominant foot. Autonomic neuropathy was diagnosed by calculation of the mean expiratory/inspiratory heart rate ratio during deep breathing. All patients gave their written informed consent to the treatment. The study was conducted in accordance with Declaration of Helsinki and approved by the local ethics committee.

Swallowing function was evaluated clinically and by both videofluoroscopy and simultaneous needle electromyography (EMG) of the CP and pharyngeal inferior constrictor (IC) muscles. Clinical evaluation was carried out every other day for the 1st week and every other week

thereafter until week 24. Videofluoroscopic and electromyographic examinations were performed before and at week 1, 4, 12, 16, 18, and 24 after BoNT/A injection.

Based on clinical evaluation, four levels of dysphagia were considered: mild dysphagia (dysphagia for liquids), discrete dysphagia (dysphagia for solids or for liquids and solids), severe dysphagia (frequent tracheal aspiration and choking), and very severe dysphagia (patient fed by nasogastric tube or percutaneous endoscopic gastrostomy. Level zero indicated the absence of dysphagia.

Videofluoroscopy with modified barium swallowing was performed. Three different food consistencies of standardized bolus size were used: thin liquid (equivalent to milk), semisolid (equivalent to jelly), and solid (dry toast coated in barium).

Simultaneous EMG of the CP and IC muscles was performed using concentric needle electrodes according to the protocol proposed by Elidan et al. (16). Briefly, for CP recording, the needle was inserted 1.5 cm lateral to the palpable border of the cricoid cartilage in a postero-medial direction. In normal subjects, a high-frequency tonic electromyographic activity is observed as the needle penetrates the muscle and a 300- to 600-ms pause is seen during voluntary swallowing. For IC muscle recordings, the needle is inserted ~3 cm above the point of insertion for the CP muscle, lateral to the lateral border of the thyroid cartilage. In normal subjects, no EMG activity is present at rest; whereas a tonic EMG activity is observed during voluntary swallowing (Fig. 1). Therefore, voluntary swallowing is electromyographically characterized by a burst of activation in the IC muscle and a synchronous EMG pause in the CP muscle, corresponding to UES relaxation.

BoNT/A (Dysport, Speywood, Portons Downs, U.K.) was percutaneously injected into the CP muscle under EMG control using a teflon-coated needle. For each patient, 30 units of botulinum toxin (2 ml dilution, 0.9% saline) were injected in each side of the CP muscle.

Statistical analysis

Data were evaluated by ANOVA. The level of significance was set at $P < 0.05$. Likert's transformation was applied to change the qualitative results of the dysphagia severity score into a score ranging from zero (no dysphagia) to four (very severe dysphagia).

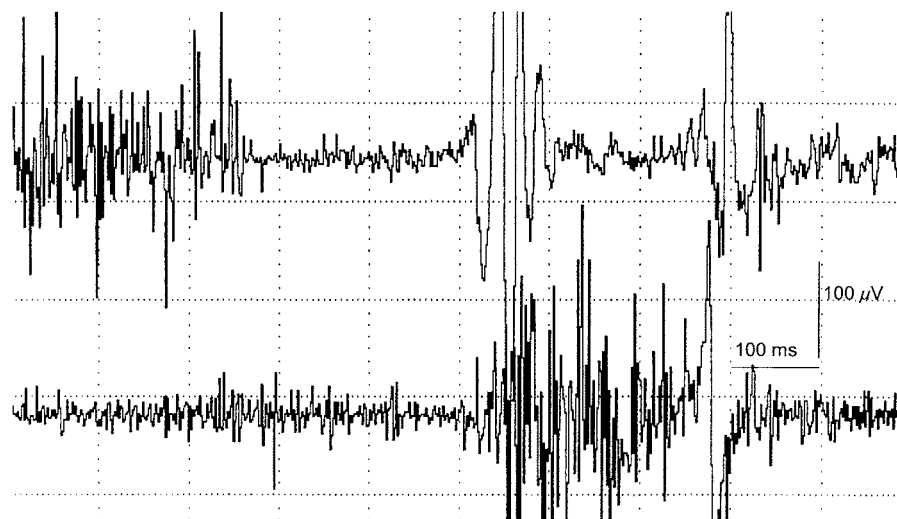


Figure 1—EMG trace showing the normal coordination between cricopharyngeal (upper trace) and inferior pharyngeal constrictor (lower trace) muscle. Sweep, 100 ms/D; amplitude, 100 μ V/D.

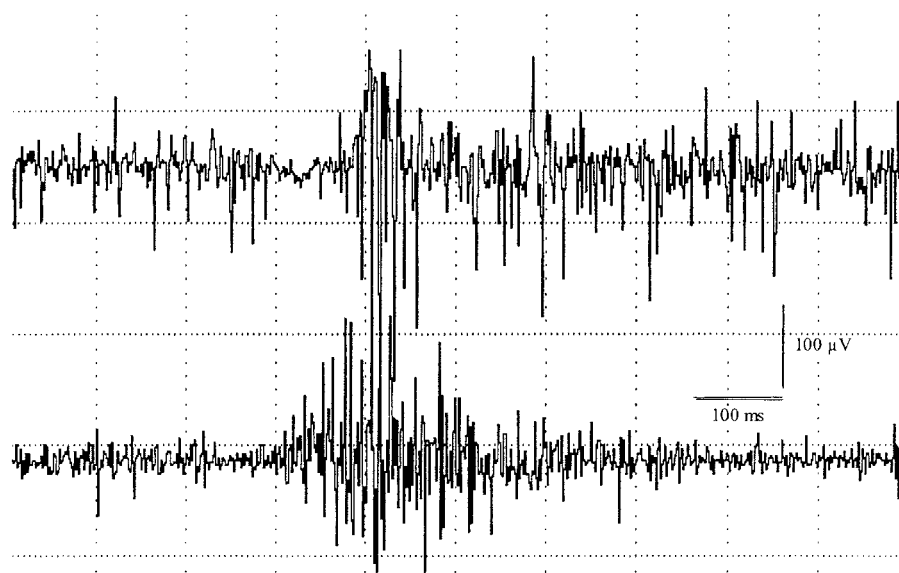


Figure 2—EMG trace of a patient with oropharyngeal dysphagia showing no relaxation of the cricopharyngeal muscle (lower trace) during voluntary swallowing.

RESULTS — In all patients, brain magnetic resonance ruled out brain and brainstem ischemic lesions. Electrophysiologic and clinical data revealed the presence of autonomic neuropathy in all patients (heart rate ratio 1.1 ± 0.1 , range 0.9–1.1, normal values >1.20), whereas somatic peripheral neuropathy was detected in nine patients (Table 1). Mean neuropathy disability score was 6.6 ± 3.6 , range 1–10 (mild neuropathy in one patient, moderate neuropathy in two patients, and severe neuropathy in six patients). Mean vibratory perception threshold was 30.5 ± 4.8 V (range 24–39, normal values <25 V) (Table 1). Before BoNT/A treatment, one patient had very severe dysphagia and all the others had severe dysphagia.

In all patients, videofluoroscopy showed the reduction of pharyngeal clearance and the incomplete CP opening. EMG showed a remarkable decrease of the maximal IC muscle activation with an increased discharge frequency and an excessive CP tonic hyperactivity leading to reduced or no relaxation (Fig. 2). Moreover, EMG of the IC muscle disclosed fibrillation potentials and/or motor unit action potential abnormalities in all subjects, reflecting active and chronic denervation.

After a single BoNT/A injection in each side of the CP muscle, dysphagia completely disappeared in 10 patients (severity score zero) and significantly improved in the remaining 2 patients (severity score “mild dysphagia”). Mean dysphagia severity score significantly

ameliorated compared with the pretreatment value (score before BoNT/A, 3.1 ± 0.2 ; week 1, 0.2 ± 0.3 ; $P = 0.0001$) and all patients were able to voluntarily swallow. Figure 3 shows the mean and SD changes in dysphagia severity score before and at 1, 4, 12, 16, 18, and 24 weeks after botulinum toxin injection. Videofluoroscopic and electromyographic studies confirmed normal swallowing and correct IC/CP muscle coordination. The beneficial effect of BoNT/A was evident after 4 ± 1.1 days (range 3–7). At week 1, the improvement was evident in all patients and remained unchanged up to week 12. It then decreased but remained significant ($P = 0.04$) at weeks 16 and 18. The mean effect duration was 14.6 ± 2.1 weeks (range 12–18). At week 24, all patients complained of the recurrence of dysphagia, the severity of which did not differ from the pretreatment value (mean dysphagia severity score 2.9 ± 0.5 , $P = 0.18$). All patients underwent a further BoNT/A treatment at week 24 and experienced the same improvement observed at the first injection. Therefore, treatment was repeated every 3–4 months according to the response of each patient. Overall, all patients remained able to voluntarily swallow for the whole period of treatment. Treatment with BoNT/A was well tolerated, and no relevant local or systemic side effects were reported. Only four patients complained of slight pain in the injection site. No adverse side effects were observed during and after the further follow-up treatments.

CONCLUSIONS — In diabetic patients, oropharyngeal dysphagia associated with autonomic and/or somatic peripheral neuropathy is likely more frequent than previously presumed, and its pathophysiology has not been completely elucidated (3,4,6). Although all phases of swallowing can be involved, the oropharyngeal phase is the most frequently impaired phase in diabetic patients (1,3,4,6). Control of oropharyngeal swallowing is mediated by voluntary and involuntary (reflexive) mechanisms. Although voluntary swallowing is not an autonomic function, it is allowed by the coordination of two muscles: the IC muscle, which controls the voluntary component, and the CP muscle of the UES, which controls the involuntary (reflexive) component. During voluntary swallowing, the activation of the IC muscle is synchronous with the relaxation of CP muscle, thus allowing the bolus to transit into the upper esophageal tract. In patients with dysphagia due to diabetic neuropathy, the coordination between the two muscular components (CP and IC) is impaired. This can be assessed by dynamic EMG analysis. In all our diabetic patients, the IC muscle showed neuropathic changes and reduced activity during swallowing. The denervation of the IC muscle induces the reduction of its voluntary activation with consequent impairment to the physiological balance between these two components. In fact, the reduction of the voluntary activation (contraction) may lead to a tonic hyperactivation of the CP muscle that cannot be inhibited and causes a defective control of voluntary and reflexive mechanisms during voluntary swallowing. A long-lasting block of the parasympathetic fibers innervating the CP muscle might be useful for treating UES hyperactivity.

Percutaneous injection of BoNT/A has been already used to successfully treat CP muscle hyperactivity associated with various neurological diseases (10–14). Our study demonstrated that BoNT/A is a safe and very effective treatment also for dysphagia associated with diabetic neuropathy.

The advantage of BoNT/A treatment is that it can be performed in an outpatient clinic, needing neither hospitalization nor anesthesia. It can be repeated when the symptoms reappear, retains the same efficacy, and requires no specific follow-up. However, this treatment may have potential risks. The diffusion of BoNT/A into the nearby laryngeal muscles might lead to laryngeal spasm or to

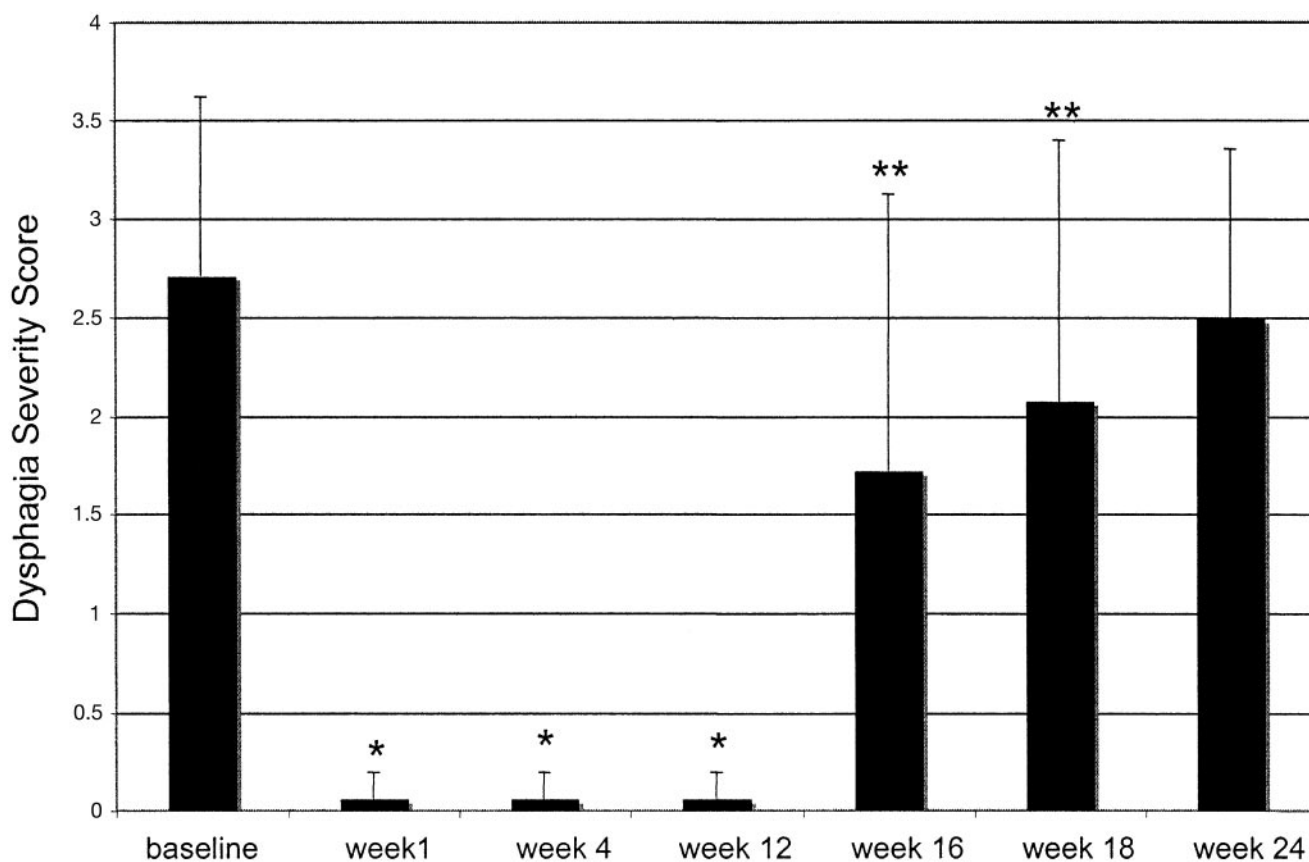


Figure 3—Mean dysphagia severity score and response to BoNT/A treatment in cricopharyngeal muscle. Data reported in the figure were collected at baseline and 1, 4, 12, 16, 18, and 24 weeks after botulinum toxin injection. Error bars indicate SD. * $P = 0.0001$; ** $P = 0.04$.

worsening of the preexisting dysphagia. For this reason, the treatment must be carried out under electromyographic guidance by an expert operator in order to identify the target muscle and to rule out the possible diffusion of the botulinum toxin into the nearby laryngeal muscles.

References

- Borgstrom PS, Olsson R, Sundkvist G, Ekberg O: Pharyngeal and oesophageal function in patients with diabetes mellitus and swallowing complaints. *Br J Radiol* 61: 817–821, 1988
- Sundkvist G, Hillarp B, Lilja B, Ekberg O: Esophageal motor function evaluated by scintigraphy, video-radiography and manometry in diabetic patients. *Acta Radiol* 30:17–19, 1989
- Annese V, Bassotti G, Caruso N, De Cosmo S, Gabrielli A, Modoni S, Frusciantè V, Andriulli A: Gastrointestinal motor dysfunction, symptoms, and neuropathy in noninsulin-dependent (type 2) diabetes mellitus. *J Clin Gastroenterol* 29: 171–177, 1999
- Rosztoczy A, Roka R, Varkonyi TT, Lengyel C, Izbeki F, Lonovics J, Wittmann T: Regional differences in the manifestation of gastrointestinal motor disorders in type 1 diabetic patients with autonomic neuropathy. *Z Gastroenterol* 42:1295–1300, 2004
- Feldman EL, Stevens MJ, Greene DA: Pathogenesis of diabetic neuropathy. *Clin Neurosci* 4:365–370, 1997
- Huppe D, Tegenthoff M, Brunke F, Depka S, Stuhldreier M, Micklefield G, Gillissen A, May B: Esophageal dysfunction in diabetes mellitus: is there a relation to clinical manifestation of neuropathy? *Clin Investig* 70:740–747, 1992
- McKenna JA, Dedo HH: Cricopharyngeal myotomy: indications and technique. *Ann Otol Rhinol Laryngol* 101:216–221, 1992
- Duranceau A: Cricopharyngeal myotomy in the management of neurogenic and muscular dysphagia. *Neuromusc Dis* 7: S85–S89, 1997
- Fradet G, Pouliot D, Robichaud R, St-Pierre S, Bouchard JP: Upper esophageal sphincter myotomy in oculopharyngeal muscular dystrophy: long-term clinical results. *Neuromusc Disord* 7:S90–S95, 1997
- Schneider I, Thumfart W, Pototschnig C, Eckel HE: Treatment of dysfunction of the cricopharyngeal muscle with botulinum toxin: introduction of a new, noninvasive method. *Ann Otol Rhinol Laryngol* 108:31–35, 1994
- Restivo DA, Marchese-Ragona R, Staffieri A, De Grandis D: Successful botulinum toxin treatment of dysphagia in oculopharyngeal muscular dystrophy. *Gastroenterology* 119:1416, 2000
- Restivo DA, Giuffrida S, Marchese-Ragona R, Falsaperla R: Successful botulinum toxin treatment of dysphagia in a young child with nemaline myopathy. *Dysphagia* 16: 228–229, 2001
- Restivo DA, Palmeri A, Marchese-Ragona R: Botulinum toxin for cricopharyngeal dysfunction in Parkinson's disease. *N Engl J Med* 346:1174–1175, 2002
- Marchese-Ragona R, De Grandis D, Restivo DA, Staffieri A, Marioni G, Pastore A: Recovery of swallowing disorders in patients undergoing supracricoid laryngectomy with botulinum toxin therapy. *Ann Otol Rhinol Laryngol* 112:258–263, 2003
- Paisley AN, Abbott CA, van Schie CH, Boulton AJ: A comparison of the Neuropen against standard quantitative sensory-threshold measures for assessing peripheral nerve function. *Diabet Med* 19: 400–405, 2002
- Elidan J, Shochina M, Gonen B, Gay I: Manometry and electromyography of the pharyngeal muscles in patients with dysphagia. *Arch Otolaryngol Head Neck Surg* 116:910–913, 1990