

Neurologic complications associated with intrathecal liposomal cytarabine given prophylactically in combination with high-dose methotrexate and cytarabine to patients with acute lymphocytic leukemia

Elias Jabbour,¹ Susan O'Brien,¹ Hagop Kantarjian,¹ Guillermo Garcia-Manero,¹ Alessandra Ferrajoli,¹ Farhad Ravandi,¹ Maria Cabanillas,¹ and Deborah A. Thomas¹

¹Department of Leukemia, University of Texas M. D. Anderson Cancer Center, Houston, TX

Central nervous system (CNS) prophylaxis has led to a significant improvement in the outcome of patients with acute lymphocytic leukemia (ALL). Liposomal cytarabine (Enzon Pharmaceuticals, Piscataway, NJ; Skye Pharma, San Diego, CA), an intrathecal (IT) preparation of cytarabine with a prolonged half-life, has been shown to be safe and effective in the treatment of neoplastic meningitis. Liposomal cytarabine was given for CNS prophylaxis to 31 patients with newly diagnosed ALL. All patients were treated concurrently with hyper-CVAD chemo-

therapy (fractionated cyclophosphamide, vincristine, doxorubicin, and dexamethasone) including high-dose methotrexate (MTX) and cytarabine on alternating courses. Liposomal cytarabine 50 mg was given intrathecally on days 2 and 15 of hyper-CVAD and day 10 of high-dose MTX and cytarabine courses until completion of either 3, 6, or 10 IT treatments, depending on risk for CNS disease. Five patients (16%) experienced serious unexpected neurotoxicity, including seizures, papilledema, cauda equina syndrome (n = 2), and encephalitis after a median of 4 IT

administrations of liposomal cytarabine. Toxicities usually manifested after the MTX and cytarabine courses. One patient died with progressive encephalitis. After a median follow-up of 7 months, no isolated CNS relapses have been observed. Liposomal cytarabine given via intrathecal route concomitantly with systemic chemotherapy that crosses the blood-brain barrier such as high-dose MTX and cytarabine can result in significant neurotoxicity. (Blood. 2007;109:3214-3218)

© 2007 by The American Society of Hematology

Introduction

Acute lymphocytic leukemia (ALL) is magnified by a monoclonal proliferation and expansion of immature lymphoid cells in the marrow, blood, and other organs. The use of intensive multi-agent systemic chemotherapy and central nervous system (CNS) prophylaxis has led to long-term survival rates of over 80% in children with ALL.¹ Despite similar advances in therapy outcomes, adults with ALL fare less well; the 5-year survival rates range from 30% to 60% depending on risk features at presentation.

CNS involvement is present at diagnosis in less than 5% of children with ALL; however, 50% to 75% will develop CNS disease in the absence of adequate CNS prophylaxis.² The routine use of CNS prophylaxis incorporating intrathecal (IT) chemotherapy and/or cranial irradiation has reduced this incidence to less than 10%.³ Similar results have also been observed in the adult population.⁴

An analysis of risk factors for development of CNS disease in patients treated with conventional adult ALL regimens at the M. D. Anderson Cancer Center (MDACC), prior to the routine use of CNS prophylaxis, showed that high levels of lactate dehydrogenase (LDH \geq 1400 IU/L) and an increased proliferative index (S + G₂M phases \geq 14%) were predictive for an adverse outcome.⁵ The incidence of CNS leukemia at 1 year was 4% if neither of these features was present at diagnosis, 13% to 29% if 1 feature was present, and 56% if both were elevated.

The hyper-CVAD regimen (fractionated cyclophosphamide, vincristine, doxorubicin, and dexamethasone alternating with high-

dose methotrexate [MTX] and cytarabine approximately every 21 days) has been established as an effective frontline therapy for adults with de novo ALL.⁶ IT chemotherapy was given with MTX on day 2 and cytarabine on day 7 of each cycle. The total number of IT treatments was based on risk stratification guided by the LDH level and the proliferative index at diagnosis. Low-risk patients received 4 IT treatments, and those with elevations in either parameter or Burkitt-type ALL received 16 treatments. Patients with low levels of LDH but an unknown proliferative index were classified as indeterminate risk and received 8 IT treatments. Application of this CNS risk stratification schema resulted in a 3-year overall CNS event-free survival rate of 92%.⁷ With longer follow-up (median 5 years), only 10 (4%) of 269 patients developed CNS disease.⁸ However, the majority of the CNS relapses were in the low-risk group, resulting in further modifications in IT chemotherapy. Currently, the total number of IT treatments in the low-risk group has been increased to 6, whereas the total number of IT treatments was reduced to 8 in the high-risk group (except for Burkitt-type ALL) owing to similar outcomes in the high- and indeterminate-risk groups.

Liposomal cytarabine (Depocyt; Enzon Pharmaceuticals, Piscataway, NJ; Skye Pharma, San Diego, CA) is a slow-release formulation of cytarabine produced by encapsulating the aqueous drug solution in spherical multivesicular particles known as DepoFoam (Skye Pharma). Cytarabine is gradually released from

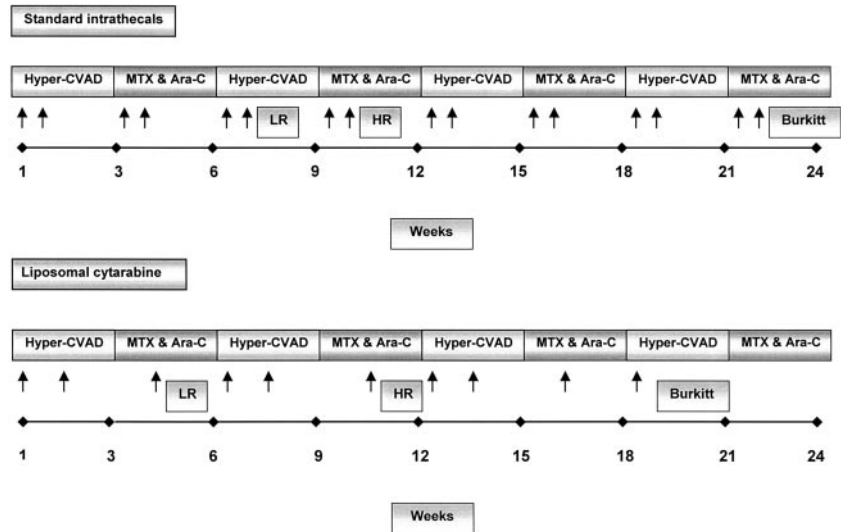
Submitted August 29, 2006; accepted November 27, 2006. Prepublished online as *Blood* First Edition Paper, January 5, 2007; DOI 10.1182/blood-2006-08-043646.

The publication costs of this article were defrayed in part by page charge

payment. Therefore, and solely to indicate this fact, this article is hereby marked "advertisement" in accordance with 18 USC section 1734.

© 2007 by The American Society of Hematology

Figure 1. Schema of intrathecal (IT) chemotherapy for the hyper-CVAD regimen with standard IT compared with IT liposomal cytarabine. Standard IT therapy consisted of methotrexate (MTX) 12 mg on day 2 and cytarabine 100 mg on day 7 of each course of therapy until completion based on risk group (6 for low-risk [LR], 8 for indeterminate- or high-risk [HR], 16 for Burkitt-type). Liposomal cytarabine 50 mg was given on days 1 and 15 of each course of hyper-CVAD and on day 10 of each course of high-dose MTX-cytarabine until completion (3 for low-risk, 6 for indeterminate- or high-risk, 10 for Burkitt-type). Arrows indicate IT treatments.



the DepoFoam into the cerebrospinal fluid (CSF), resulting in prolonged drug exposure approximately 40 times longer than standard cytarabine. This liposomal formulation has shown a pharmacokinetic advantage over the standard preparation in adult and pediatric phase 1 studies, with an acceptable safety profile as long as administered concurrently with corticosteroids to reduce the incidence of arachnoiditis.^{9,10} Based on its significant efficacy, the drug was approved by the Food and Drug Administration for the treatment of adults with lymphomatous meningitis.¹¹

Given the frequency of IT injections required for CNS prophylaxis (via lumbar punctures based on our departmental preference to avoid indwelling ventricular access devices such as Ommaya reservoirs), liposomal cytarabine was an attractive alternative, given the ability to reduce the frequency and total number of IT treatments and the potential to further improve on the efficacy of the current CNS prophylaxis regimen. In this regard, we designed a phase 2 trial of IT liposomal cytarabine for CNS prophylaxis concurrently with the hyper-CVAD regimen for adults with de novo ALL, lymphoblastic lymphoma (LL), or Burkitt-type leukemia/lymphoma. The trial was terminated early owing to the observation of several unexpected neurologic events, particularly severe in a small subset of the patients treated. To our knowledge, this is the first report of neurologic events of such severity after liposomal cytarabine IT therapy.

Patients, materials, and methods

Patients

Between January 2005 and December 2005, 33 patients with previously untreated ALL, LL, Burkitt, or Burkitt-like leukemia or lymphoma receiving frontline therapy with the modified hyper-CVAD regimen or its variants were enrolled prospectively in this phase 2 trial. Eligibility criteria included age 15 years or older, Zubrod performance status 3 or better, adequate hepatorenal function (bilirubin level $\leq 51.3 \mu\text{M}$ [3 mg/dL] and creatinine level $\leq 265.2 \mu\text{M}$ [3 mg/dL]), and the absence of known CNS leukemia or active meningeal infection. The protocol was approved by the Institutional Review Board (IRB) at the MDACC. Informed consent was obtained from patients in accordance with institutional guidelines and the Declaration of Helsinki.

Therapy

The dosing schema was chosen based on the pharmacokinetic studies of liposomal cytarabine in carcinomatous meningitis.⁹ Free and encapsulated

CSF cytarabine levels peak rapidly (within 5 hours), then declined rapidly until 24 hours, when levels declined at a slower rate.¹² Very low levels of encapsulated and free cytarabine were detectable up to 14 days, usually below the in vitro minimum cytotoxicity potential of cytarabine (determined to be least $0.1 \mu\text{g/mL}$). Systemic levels of liposomal cytarabine were only sporadically detectable at minimal concentrations. Thus, in order to minimize overlapping toxicity, the IT liposomal cytarabine treatments were separated by at least 12 days and were not given until 7 days after the last dose of systemic cytarabine. The dose of 50 mg liposomal cytarabine was chosen based on review of prior phase 1 and 2 studies in adults (including patients aged 19 and older) and children.^{9,12,13} The total number of IT treatments was chosen based on the fact that single-agent liposomal cytarabine would replace IT MTX (now eliminated) and standard cytarabine 100 mg (Figure 1).

Liposomal cytarabine 50 mg was given via lumbar puncture (none of the patients had indwelling ventricular access devices) on days 2 and 15 of the first, third, fifth, and seventh (hyper-CVAD) courses, and on day 10 of the second, fourth, and sixth (high-dose MTX and cytarabine) courses until completion of the total number of IT treatments per assigned risk group (Figure 1).

Low-risk patients received 3 IT treatments (completed after cycle 2), indeterminate- or high-risk patients received a total of 6 IT treatments (completed after cycle 4), and patients with Burkitt or Burkitt-like leukemia/lymphoma received a total of 10 IT treatments (completed after cycle 7). Dose reductions to 25 mg were mandated for patients who developed grade 2-3 therapy-related neurotoxicity that had resolved prior to the next dose. All patients received dexamethasone 4 mg twice daily either orally or intravenously for 5 days beginning on the day of liposomal cytarabine administration, then 2 mg twice a day on day 6, and 1 mg twice a day on day 7. High-dose dexamethasone (40 mg \times 4 days) given as part of the systemic chemotherapy (during the hyper-CVAD cycles) was substituted for this regimen if the liposomal cytarabine was administered concurrently.

The hyper-CVAD regimen was administered as previously described.^{6,8,14,15} Briefly, it consisted of 8 alternating courses of systemic chemotherapy administered approximately every 21 days or upon recovery from myelosuppression. Odd courses (1, 3, 5, 7) were hyper-CVAD: hyper-fractionated cyclophosphamide 300 mg/m² intravenously every 12 hours for 6 doses days 1 to 3; vincristine 2 mg intravenously days 4 and 11; doxorubicin 50 mg/m² intravenously over 24 hours day 4; dexamethasone 40 mg daily days 1 to 4 and 11 to 14. A 2-day window was allowed for the dexamethasone planned for days 11 to 14 in order to coincide with liposomal cytarabine if needed (eg, shifted to days 13-16). Even courses (2, 4, 6, 8) were MTX and cytarabine as follows: MTX 1 g/m² intravenously over 24 hours day 1, cytarabine 3 g/m² intravenously every 12 hours for 4 doses days 2 and 3, and methylprednisolone 50 mg intravenously every 12 hours for 6 doses days 1 to 3. Rituximab was given 375 mg/m²

Table 1. Characteristics of patients experiencing a severe neurologic event after IT liposomal cytarabine and hyper-CVAD

Parameter	Patient no.				
	1	2	3	4	5
Age, y	22	19	42	65	54
Sex	M	F	F	M	M
CNS risk*	Indeterminate	High	High	High	High
No. of courses before toxicity	2	4	4	2	2
Total IT treatments before toxicity	3	6	6	3	3
Time from IT to toxicity, d	10	14	1	10	5
Toxicity	Seizure	Pseudotumor cerebri	Cauda equina syndrome	Cauda equina syndrome	Encephalitis
Evaluation	Negative	Increased CSF pressure	Sacral multi-root thickening	Negative	Scattered infarcts or necrosis
Toxicity outcome	Resolved	Decreased visual acuity	Persistent fecal incontinence	Persistent fecal and urinary incontinence	Death
Last follow-up status	CR	CR	CR	CR	Died in CR
Time of follow-up, mo, diagnosis/toxicity	11/9	13/9	8/5	14/11	3/1

The diagnosis, induction response, and last chemotherapy for all 5 patients was pre-B ALL, CR, and MTX + ara-C (methotrexate, cytarabine), respectively. IT indicates intrathecal; M, male; F, female; CSF, cerebrospinal fluid; and CR, complete remission.

*Total planned IT chemotherapy treatments by risk: low 3, indeterminate/high 6, Burkitt 10.

intravenously on days 1 and 11 of hyper-CVAD courses and on days 1 and 8 of MTX and cytarabine courses for a total of 8 doses in patients with CD20⁺ ALL or Burkitt-type leukemia/lymphoma.¹⁵ All patients received granulocyte colony-stimulating factor, prophylactic antibiotics, and transfusion support. Maintenance chemotherapy consisted of 6-mercaptopurine, MTX, vincristine, and prednisone (POMP) for 30 months, interrupted by early and late intensifications with hyper-CVAD ± rituximab and MTX with L-asparaginase. No maintenance therapy was given to patients with Burkitt-type leukemia/lymphoma.

Assessments

CSF analysis was performed concurrently with dose no. 1 of liposomal cytarabine and included cell count with differential, total protein, glucose, cytology, and microbial assessments. CSF was monitored with cell count and cytology with each IT treatment. Neurologic examinations were performed prior to each dose of liposomal cytarabine. Imaging studies such as magnetic resonance imaging (MRI) scan of the brain or computed tomography (CT) scan of the head were not required in the absence of symptoms. Toxicities were evaluated using version 2 of the National Cancer Institute Common Toxicity Criteria.

Statistical considerations

The primary end point was the CNS relapse rate. A secondary end point was CNS disease-free survival. The study was designed to achieve equivalence to the historic CNS relapse rate of 6%; stopping rules were applied if the CNS relapse rate approached 15%. No formal stopping rules were applied for toxicity, as inpatient dose reductions were allowed as detailed previously. However, the study was terminated early prior to projected accrual after a grade 4 encephalitis attributed to liposomal cytarabine was observed. The request for termination was granted by the IRB after review of summary toxicity data.

Results

Study group

Thirty-three patients were enrolled: 51% were male; 21% were age 21 years or younger, and 25% were age 60 years or older (range, 16-78 years). CNS risk groups included 7 (21%) with low-risk, 24 (73%) with indeterminate- or high-risk, and 2 (6%) with Burkitt-type-leukemia/lymphoma. The 2 patients in the latter group were removed from study after identification of occult CNS disease: 1 with an MRI scan of the lumbosacral spine identifying leptomeningeal

infiltration, and 1 owing to positive CSF cytology after dose no. 1 of liposomal cytarabine. Thus, 31 patients were treated.

Toxicity

Nineteen (61%) of 31 patients completed the IT liposomal cytarabine as planned. Two patients died during induction chemotherapy due to development of multi-organ failure related to sepsis and received only 1 dose of liposomal cytarabine. Overall, 12 patients (38%) discontinued IT therapy early (prior to assigned number of IT treatments) owing to death (n = 3), toxicity (n = 2), change in systemic chemotherapy (n = 2), systemic disease recurrence (n = 2), closure of the protocol (n = 2), or noncompliance (n = 1).

Headache was the most commonly reported adverse event, occurring in 39% of patients. In less severe cases, these were attributed to the lumbar puncture itself and were responsive to supportive care measures. Neurotoxicity attributed to liposomal cytarabine also included grade 4 papilledema with blindness (n = 1), grade 3 increased intracranial pressure (n = 2), grade 3 cauda equina syndrome (n = 2), and grade 2 seizure (n = 1). One episode of grade 3 meningitis was not attributed to therapy. Other grade 3-4 toxicities were attributed to the systemic chemotherapy, including myelosuppression-related events, and to comorbid conditions.

The 5 patients (16%) who developed serious neurotoxicity attributed to liposomal cytarabine had indeterminate/high CNS risk: 2 had discontinued therapy for these toxicities, whereas 3 had late manifestations after completion of IT therapy. The clinical features of these 5 patients are presented in detail (Table 1).

Patient 1

A 22-year-old male diagnosed with indeterminate CNS risk (no proliferative index owing to inadequate sample for DNA analysis), CD20⁺ pre-B-cell ALL achieved a complete remission (CR) after induction chemotherapy with hyper-CVAD. Ten days after receiving dose no. 3 of IT liposomal cytarabine (cycle 2, day 10 of MTX and cytarabine chemotherapy), the patient developed complex partial seizures with occasional generalization. Complete neurologic evaluation including lumbar puncture, MRI of the brain, and electroencephalogram (EEG) was negative. The patient was treated with valproic acid and no further IT liposomal cytarabine or other IT chemotherapy was administered. The patient completed all 8

courses of intensive chemotherapy followed by initiation of POMP maintenance therapy without subsequent episodes.

Patient 2

A 19-year-old female with high CNS risk, CD20⁻ pre-B ALL achieved a CR after induction chemotherapy with hyper-CVAD. After receiving cycle 4 of high-dose MTX and cytarabine with administration of the sixth and final IT liposomal cytarabine on day 10, the patient developed headaches of increasing severity, relieved only partially with analgesics. Two weeks later she developed blurred vision. MRI of the brain was negative without evidence of hydrocephalus. Ophthalmologic examination revealed bilateral papilledema. Lumbar puncture showed an opening pressure of 550 mm of water, which decreased to 170 mm of water after withdrawal of 40 mL of CSF. There was no evidence of leukemia or infection on CSF analysis. A diagnosis of pseudotumor cerebri was rendered. A ventriculoperitoneal shunt was placed owing to progressive visual loss. The patient recovered but with decreased visual acuity. After completion of 5 courses of systemic chemotherapy, the patient proceeded to POMP maintenance therapy.

Patient 3

A 42-year-old female with high CNS risk, CD20⁻ pre-B-cell ALL with translocation (4;11) karyotype achieved CR after induction chemotherapy with hyper-CVAD, completing all 6 doses of liposomal cytarabine via lumbar puncture uneventfully. The patient then developed slow onset of fecal incontinence, urinary hesitancy, and perineal numbness, progressing after cycle 4 of MTX and cytarabine. Complete neurologic evaluation including lumbar puncture and MRI of the brain and lumbosacral spine were negative. The patient was treated empirically with corticosteroids without improvement in symptomatology. Due to the persistence of the neurologic symptoms, the lumbosacral MRI was repeated approximately 2 months later and showed a subtle focal sacral multi-root thickening consistent with chemical arachnoiditis/radiculitis, likely related to local effects of the administration of liposomal cytarabine. The patient was managed symptomatically with only mild improvement in symptoms, completing 8 courses of systemic chemotherapy followed by allogeneic stem cell transplantation.

Patient 4

A 65-year-old male with high CNS risk, CD20⁺ pre-B-cell ALL achieved CR after hyper-CVAD and rituximab induction. The patient received liposomal cytarabine cycle 2, day 10 of MTX and cytarabine and subsequently developed slow onset of urinary and fecal incontinence. MRI scan of the lumbosacral spine was negative for arachnoiditis. The patient had a posttreatment course complicated by cytomegalovirus pneumonia, deep venous thrombosis, and sacral decubitus; intensive chemotherapy with the hyper-CVAD regimen was discontinued. The patient completed the CNS prophylaxis with 4 standard IT chemotherapy (alternating MTX and cytarabine) treatments concurrently with POMP and rituximab maintenance therapy without incident. The patient has had mild improvement in fecal incontinence but persistent urinary dysfunction requiring self-catheterizations.

Patient 5

A 54-year-old male with high CNS risk, CD20⁺ pre-B-cell ALL achieved a CR after induction chemotherapy with hyper-CVAD and rituximab. The patient underwent cycle 2, day 10 IT administra-

tion of liposomal cytarabine. Five days subsequent to the IT treatment, the patient presented with a 36-hour history of lower-extremity discomfort progressing to bilateral lower-extremity weakness associated with back pain, with subsequent development of unresponsiveness, lethargy, and then coma. Flaccid paralysis with doll's eyes was noted on physical examination, and mechanical ventilation was provided for airway protection. Lumbar puncture was negative for signs of infection or leptomeningeal disease (LMD). EEG showed diffuse generalized cortical dysfunction. MRI of the brain showed scattered punctate infarcts or necrosis in the periventricular white matter and white matter of the centrum semiovale and elsewhere through the brain, suggesting posterior vessel encephalopathy. The patient was treated with broad-spectrum antibacterial, antifungal, and antiviral antibiotics and high-dose corticosteroids empirically with multiple culture specimens negative for infection. Despite aggressive supportive care measures, the patient failed to show any neurologic recovery and was transferred to hospice care. The patient died 3 weeks following this episode (no autopsy was performed).

Outcome

No instances of isolated CNS relapse have been identified. Systemic recurrence was observed in 3 patients, 2 without evidence of CNS involvement and 1 with concomitant CNS disease.

Discussion

This is the first report of the use of intrathecal liposomal cytarabine for CNS prophylaxis in adults with de novo ALL treated concomitantly with systemic hyper-CVAD alternating with high-dose MTX and cytarabine chemotherapy. Five (16%) of 31 patients developed severe unexpected neurologic events attributed to the liposomal cytarabine. These events, including cauda equina syndrome, encephalitis, pseudotumor cerebri-like syndrome, and seizures, are not typically seen with the standard IT chemotherapy used for CNS prophylaxis with the hyper-CVAD regimen. No obvious alternative explanations (such as infection or LMD) could be elucidated to explain the neurologic findings.

In randomized studies comparing single-agent liposomal cytarabine with standard IT chemotherapy treatment for neoplastic meningitis, clinical benefit was observed with use of the liposomal preparation. Liposomal cytarabine produced higher response rates and significantly better quality of life compared with free cytarabine when given as a single agent on an every-2-week schedule for patients with lymphomatous meningitis.¹¹ The major adverse events observed included headache and chemical arachnoiditis; the incidence of the latter toxicity could be reduced with concurrent use of corticosteroids. In patients with solid tumor neoplastic meningitis, liposomal cytarabine produced a response rate comparable to that of IT MTX but with significantly increased time to neurologic progression.¹⁶ The frequency and severity of adverse events were comparable between treatment arms.

When standard IT chemotherapy for CNS prophylaxis (MTX alternating with standard cytarabine) is given concurrently with the hyper-CVAD regimen, the incidence of significant grade 3-4 neurotoxicity (eg, papilledema, pseudotumor cerebri syndrome, cauda equina syndrome, and encephalitis as observed in the current study) is less than 1%.^{6,8,14,15} Neurotoxicity is also minimal when standard IT chemotherapy is intensified for CNS disease at presentation (twice weekly until clear for 2 assessments, then weekly for 4, then twice with each remaining course of systemic

chemotherapy, often approaching a total 20-25 IT treatments). Headaches related to the spinal taps (not the IT chemotherapy) and peripheral neuropathy related to vincristine are not uncommon.

However, concomitant administration of liposomal cytarabine and systemic chemotherapy agents that penetrate the blood-brain barrier, such as high-dose MTX and cytarabine, may increase the potential for neurotoxicity. The serious neurologic events generally were manifested during the courses of high-dose MTX and cytarabine, although cumulative effects of the prior liposomal cytarabine doses and the preceding courses of systemic chemotherapy cannot be excluded. McClune et al¹⁷ reported mostly minor neurologic side effects (eg, headaches) in 15 patients with ALL and high-grade lymphoma who received the hyper-CVAD regimen concurrently with 1 dose of prophylactic IT liposomal cytarabine 50 mg (25 mg if via Ommaya reservoir) on day 8 (range, day -4 to day 13) of each cycle. Two patients (13%) had more serious neurotoxicity. One patient experienced severe but transient headache requiring intravenous narcotics subsequent to cycle 4 of MTX and cytarabine. The other patient received liposomal cytarabine 4 days prior to the MTX and cytarabine course and developed hyponatremia and somnolence. These neurologic events resolved after several days of supportive care.

Radiation therapy may also potentiate the neurotoxicity associated with liposomal cytarabine. In a phase 1 clinical trial, severe encephalopathy was reported in 1 patient who received whole-brain radiation simultaneously with IT administration of liposomal

cytarabine 125 mg, a dose higher than the recommended dose of 50 mg.¹⁰ In conclusion, severe neurotoxicity may occur after concurrent administration of IT liposomal cytarabine and systemic chemotherapy agents that penetrate the blood-brain barrier.

Acknowledgments

This work was funded in part by research grants from Enzon Pharmaceuticals and Skye Pharma.

Authorship

Contribution: E.J. analyzed data and wrote the paper; S.O. performed research and revised the paper; H.K. contributed patients to the study and revised the paper; G.G.-M. contributed patients to the study; A.F. contributed patients to the study; F.R. contributed patients to the study; M.C. performed research; and D.A.T. designed the research, performed research, analyzed the data, and revised the paper.

Conflict-of-interest disclosure: The authors declare no competing financial interests.

Correspondence: Deborah A. Thomas, Department of Leukemia, Unit 428, The University of Texas M. D. Anderson Cancer Center, 1515 Holcombe Blvd, Unit 428, Houston, TX 77030; e-mail: debthomas@mdanderson.org.

References

- Jabbour EJ, Faderl S, Kantarjian HM. Adult acute lymphoblastic leukemia. *Mayo Clin Proc.* 2005; 80:1517-1527.
- Bleyer WA, Poplack DG. Prophylaxis and treatment of leukemia in the central nervous system and other sanctuaries. *Semin Oncol.* 1985;12: 131-148.
- Bleyer WA, Coccia PF, Sather HN, et al. Reduction in central nervous system leukemia with a pharmacokinetically derived intrathecal methotrexate dosage regimen. *J Clin Oncol.* 1983;1: 317-325.
- Omura GA, Moffitt S, Vogler WR, Salter MM. Combination chemotherapy of adult acute lymphoblastic leukemia with randomized central nervous system prophylaxis. *Blood.* 1980;55:199-204.
- Kantarjian HM, Walters RS, Smith TL, et al. Identification of risk groups for development of central nervous system leukemia in adults with acute lymphocytic leukemia. *Blood.* 1988;72:1784-1789.
- Kantarjian HM, O'Brien S, Smith TL, et al. Results of treatment with hyper-CVAD, a dose-intensive regimen, in adult acute lymphocytic leukemia. *J Clin Oncol.* 2000;18:547-561.
- Cortes J, O'Brien SM, Pierce S, Keating MJ, Freireich EJ, Kantarjian HM. The value of high-dose systemic chemotherapy and intrathecal therapy for central nervous system prophylaxis in different risk groups of adult acute lymphoblastic leukemia. *Blood.* 1995;86:2091-2097.
- Kantarjian H, Thomas D, O'Brien S, et al. Long-term follow-up results of hyperfractionated cyclophosphamide, vincristine, doxorubicin, and dexamethasone (Hyper-CVAD), a dose-intensive regimen, in adult acute lymphocytic leukemia. *Cancer.* 2004;101:2788-2801.
- Chamberlain MC, Kormanik P, Howell SB, Kim S. Pharmacokinetics of intralumbar DTC-101 for the treatment of leptomeningeal metastases. *Arch Neurol.* 1995;52:912-917.
- Kim S, Chatelut E, Kim JC, et al. Extended CSF cytarabine exposure following intrathecal administration of DTC 101. *J Clin Oncol.* 1993;11:2186-2193.
- Glantz MJ, LaFollette S, Jaeckle KA, et al. Randomized trial of a slow-release versus a standard formulation of cytarabine for the intrathecal treatment of lymphomatous meningitis. *J Clin Oncol.* 1999;17:3110-3116.
- Phuphanich S, Maria B, Braeckman R, Chamberlain M. A pharmacokinetic study of intra-CSF administered encapsulated cytarabine (DepoCyt®) for the treatment of neoplastic meningitis in patients with leukemia, lymphoma, or solid tumors as part of a phase III study. *J Neurooncol.* 2007; 81:201-208.
- Bomgaars L, Geyer JR, Franklin J, et al. Phase I trial of intrathecal liposomal cytarabine in children with neoplastic meningitis. *J Clin Oncol.* 2004;22: 3916-3921.
- Thomas DA, O'Brien S, Cortes J, et al. Outcome with the hyper-CVAD regimens in lymphoblastic lymphoma. *Blood.* 2004;104:1624-1630.
- Thomas DA, Faderl S, O'Brien S, et al. Chemoimmunotherapy with hyper-CVAD plus rituximab for the treatment of adult Burkitt and Burkitt-type lymphoma or acute lymphoblastic leukemia. *Cancer.* 2006;106:1569-1580.
- Glantz MJ, Jaeckle KA, Chamberlain MC, et al. A randomized controlled trial comparing intrathecal sustained-release cytarabine (DepoCyt) to intrathecal methotrexate in patients with neoplastic meningitis from solid tumors. *Clin Cancer Res.* 1999;5:3394-3402.
- McClune B, Buadi F, Aslam N, Przepiorka D. Intrathecal liposomal cytarabine (DepoCyt) is safe and effective for prevention of meningeal disease in patients with acute lymphoblastic leukemia and high-grade lymphoma treated with the hyper-CVAD regimen [abstract]. *Blood.* 2005;116:227b.