

resistant *NOTCH1*-mutated clone is at risk of acquiring further progression-associated hits. Besides the known t(14;19)(q32;q13)/*IGH-BCL3*,⁸⁻¹⁰ we also identified dic(9;14)(q34;q32)/*IGH-NOTCH1*, which so far has not been reported in B-cell leukemia/lymphoma, as a novel genomic aberration capable of triggering RS.

Kim De Keersmaecker

Center for Human Genetics, KU Leuven,
Center for the Biology of Disease, Vlaams Instituut voor Biotechnologie,
Leuven, Belgium

Lucienne Michaux

Center for Human Genetics, KU Leuven,
Leuven, Belgium

André Bosly

Mont-Godinne University Hospital,
Yvoir, Belgium

Carlos Graux

Mont-Godinne University Hospital,
Yvoir, Belgium

Julio Finalet Ferreira

Center for Human Genetics, KU Leuven,
Leuven, Belgium

Peter Vandenberghe

Center for Human Genetics, KU Leuven,
Leuven, Belgium

Jan Cools

Center for Human Genetics, KU Leuven,
Center for the Biology of Disease, Vlaams Instituut voor Biotechnologie,
Leuven, Belgium

Iwona Wlodarska

Center for Human Genetics, KU Leuven,
Leuven, Belgium

The online version of this article contains a data supplement.

Acknowledgments: This work was supported by the European Research Council (ERC-starting grant to J.C.), KU Leuven (concerted action grant to J.C., P.V., I.W.), and the Stichting Tegen Kanker (grant to P.V.). K.D.K. is a

postdoctoral researcher of the Research Foundation-Flanders (FWO) and P.V. is a senior clinical investigator of FWO. The authors thank Ursula Pluys for technical assistance and Rita Logist for editorial help.

Contribution: K.D.K. and I.W. designed and performed the research, analyzed data, and wrote and approved the manuscript; L.M. analyzed data and wrote and approved the manuscript; A.B. and C.G. treated the patient, contributed vital patient information, and approved the manuscript; J.F.F. performed array CGH, analyzed data, and approved the manuscript; P.V. analyzed data and wrote and approved the manuscript; and J.C. designed the research, analyzed data, and wrote and approved the manuscript.

Conflict-of-interest disclosure: The authors declare no competing financial interests.

Correspondence: Iwona Wlodarska, Center for Human Genetics, KU Leuven, Gasthuisberg, Herestraat 49, Box 602, B-3000 Leuven, Belgium; e-mail: iwona.wlodarska@uzleuven.be.

References

- Fabbri G, Rasi S, Rossi D et al. Analysis of the chronic lymphocytic leukemia coding genome: role of NOTCH1 mutational activation. *J Exp Med*. 2011; 208(7):1389-1401.
- Puente XS, Pinyol M, Quesada V et al. Whole-genome sequencing identifies recurrent mutations in chronic lymphocytic leukaemia. *Nature*. 2011;475(7354): 101-105.
- Rossi D, Rasi S, Fabbri G et al. Mutations of NOTCH1 are an independent predictor of survival in chronic lymphocytic leukemia. *Blood*. 2012;119(2):521-529.
- Weng AP, Ferrando AA, Lee W et al. Activating mutations of NOTCH1 in human T cell acute lymphoblastic leukemia. *Science*. 2004;306(5694):269-271.
- Sportoletti P, Baldoni S, Cavalli L et al. NOTCH1 PEST domain mutation is an adverse prognostic factor in B-CLL. *Br J Haematol*. 2010;151(4):404-406.
- Rossi D, Spina V, Deambrogi C et al. The genetics of Richter syndrome reveals disease heterogeneity and predicts survival after transformation. *Blood*. 2011; 117(12):3391-3401.
- Martinez A, Pittaluga S, Villamor N et al. Clonal T-cell populations and increased risk for cytotoxic T-cell lymphomas in B-CLL patients: clinicopathologic observations and molecular analysis. *Am J Surg Pathol*. 2004;28(7):849-858.
- Michaux L, Dierlamm J, Wlodarska I et al. t(14;19)/BCL3 rearrangements in lymphoproliferative disorders: a review of 23 cases. *Cancer Genet Cytogenet*. 1997;94(1):36-43.
- Soma LA, Gollin SM, Remstein ED et al. Splenic small B-cell lymphoma with IGH/BCL3 translocation. *Hum Pathol*. 2006;37(2):218-230.
- Huh YO, Abruzzo LV, Rassidakis GZ et al. The t(14;19)(q32;q13)-positive small B-cell leukaemia: a clinicopathologic and cytogenetic study of seven cases. *Br J Haematol*. 2007;136(2):220-228.

To the editor:

Persistently high quality of life conferred by coexisting congenital deficiency of terminal complement C9 in a paroxysmal nocturnal hemoglobinuria patient

Paroxysmal nocturnal hemoglobinuria (PNH) clone bears a *PIGA* mutation and fails to express glycosylphosphatidylinositol-linked membrane proteins such as complement-regulatory CD55 and CD59, leading to complement-mediated intravascular hemolysis and thrombosis. The advent of eculizumab, an inhibitor of terminal complement C5, provides good quality of life (QOL) by preventing hemolysis and thrombosis,^{1,2} and may improve prognosis of PNH patients.³ However, the safety of its long-term use for more than 10 years^{1,2} and the pathogenesis of eculizumab-associated extravascular hemolysis have not been established.⁴ For the hemolysis, steroid, splenectomy,⁵ and C3-targeted therapy⁶ have been proposed, despite their individual risks.⁷ In 1980, we found a PNH patient with a coexisting congenital deficiency of C9, still the only case globally.⁸ Presently, the patient is 78 years old and has kept a high QOL (no experience of massive hemolysis, thrombotic events, critical infection, or malignant diseases) for more than 31 years

after the PNH diagnosis. Of note, the patient manifests very low levels of PNH hemolysis (Figure 1A-B) and marrow failure (Figure 1A). The high QOL may reflect that the C9-deficiency prevents membrane attack complex (C5b-9) formation but allows immune reactions by generation of C5a and C5b-8.⁷ Currently, virtually all erythrocytes (and granulocytes) of the patient showed the PNH phenotype (Figure 1A-C). Whole blood cells had the same *PIGA* mutation in 1998 and 2011 (Figure 1D), indicating that the cells are of a single PNH clone. Marrow cells showed a normal karyotype. These findings support the concept that clonal hematopoiesis in PNH is a benign process. The clinical features suggest the safety and efficacy of long-term inhibition of terminal complement including C9 for even elderly PNH patients. Thus, we propose that C9 targeting is another option for PNH therapy.²

Hemosiderinuria (Figure 1E) is an indicator of intravascular hemolysis, probably induced by C5b-8 in the C9-deficient patient.⁷

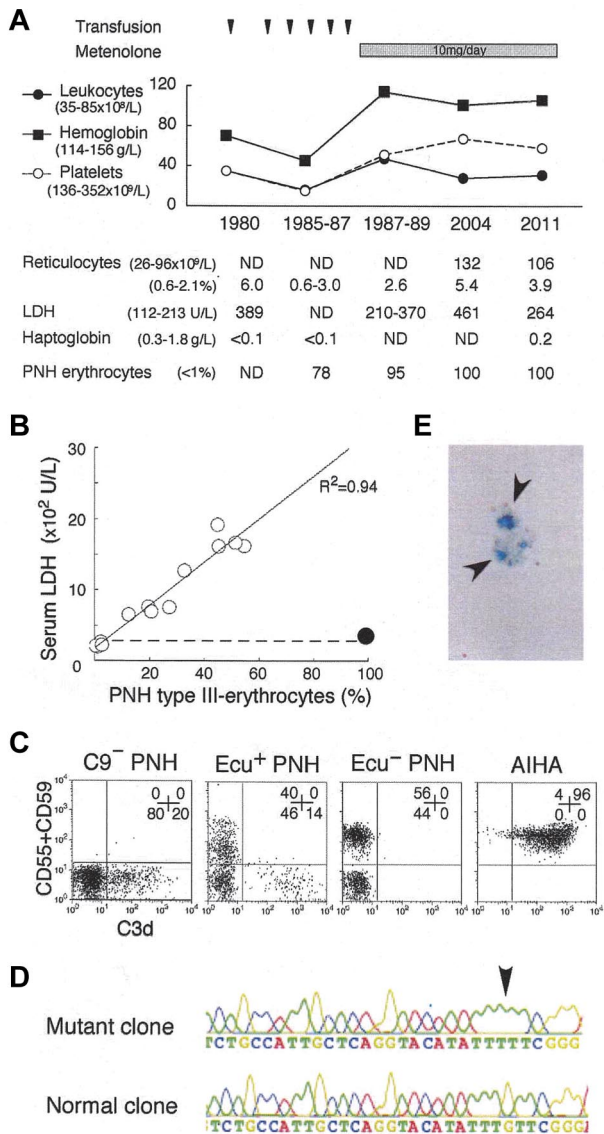


Figure 1. Analysis of the C9-deficient patient with PNH. (A) Clinical profile of the C9-deficient patient with PNH. ND indicates not determined; and PNH erythrocytes, negative for both CD55 and CD59. (B) Correlation between LDH levels and PNH type III erythrocytes (%). ○, 14 patients with PNH; ●, C9-deficient patient with PNH; dashed line, upper limit of normal LDH range. (C) C3d expression on erythrocytes of PNH patients with C9 deficiency (C9⁻ PNH), with eculizumab (Ecu⁺ PNH), without eculizumab (Ecu⁻ PNH), and of a patient with autoimmune hemolytic anemia (AIHA). Numbers indicate the population (%) of cells in each quadrant. (D) Arrow indicates a *PIGA* mutation, deletion of G (352), in the granulocyte genome exon 2 of C9⁻ PNH. (E) Arrows indicate urine hemosiderin stained with Prussian blue of C9⁻ PNH.

Surprisingly, the patient had C3d-bound erythrocytes (Figure 1C) that often appear in PNH patients on eculizumab^{4,5} and are susceptible to extravascular hemolysis.⁷ Thus, the patient manifests extremely low levels of both intra- and extravascular hemolysis. It is interesting to verify whether ordinary PNH patients harbor dormant extravascular hemolysis. Judging from the fluorescence intensity of C3d-positive erythrocytes, the amount of C3d on the PNH erythrocytes of our patient appears less than that of some PNH patients on eculizumab (Figure 1C; current report⁴). In contrast, C3d⁺ erythrocytes were undetectable in PNH patients before eculizumab treatment (Figure 1C).⁴ The amount of C3d on erythrocytes may inversely correlate with the intensity of intravascular hemolysis. It then led us to speculate that intravascular hemolysis is too rapid to allow extravascular clearance of C3d-

bound PNH erythrocytes in vivo. It is also theoretically possible that eculizumab-associated extravascular hemolysis is controllable by decreasing the dose of eculizumab. The C3d deposition could also be affected by the altered expression of erythrocyte glycolipids.⁹ In general, infection amplifies both intravascular hemolysis of PNH¹⁰ and extravascular hemolysis of hereditary spherocytosis. Eculizumab may not completely eliminate the infection-associated precipitation of hemolysis in PNH patients having both types of hemolysis.

The findings in our exceptional PNH patient surely promote unveiling of complex pathophysiology and contribute to the establishment of a better terminal complement-targeted therapy in PNH.

Nobuyoshi Hanaoka
 Department of Hematology/Oncology, Wakayama Medical University, Wakayama, Japan

Yoshiko Murakami
 Research Institute for Microbial Diseases, and WPI Immunology Frontier Research Center, Osaka University, Osaka, Japan

Masahide Nagata
 Nagata ENT Clinic, Kumamoto, Japan

Shoichi Nagakura
 Department of Hematology, National Hospital Organization Kumamoto Medical Center, Kumamoto, Japan

Yuji Yonemura
 Department of Blood Transfusion Medicine and Cell Therapy, Kumamoto University, Kumamoto, Japan

Takashi Sonoki
 Department of Hematology/Oncology, Wakayama Medical University, Wakayama, Japan

Taroh Kinoshita
 Research Institute for Microbial Diseases, and WPI Immunology Frontier Research Center, Osaka University, Osaka, Japan

Hideki Nakakuma
 Department of Hematology/Oncology, Wakayama Medical University, Wakayama, Japan

Acknowledgments: The authors thank Kentaro Horikawa and Tatsuya Kawaguchi of Kumamoto University, Takahiko Horiuchi of Kyushu University, and Michiyo Hatanaka of Kobe Tokiwa University for critical discussion, and Naoto Minoura, Kenichi Nakatsuka, and Kazuki Fujii of Wakayama Medical University for technical assistance.

This work was supported by grants from the Ministry of Education, Culture, Sports, Science, and Technology of Japan, the Ministry of Labor and Welfare of Japan, and the Takeda Science Foundation.

Contribution: N.H. designed and performed research, analyzed the data, and wrote the paper; Y.M. and T.K. performed molecular analyses; M.N., S.N., Y.Y., and T.S. analyzed the clinical data; and H.N. supervised the project, analyzed the data, and wrote the paper.

Conflict-of-interest disclosure: Y.Y., T.K., and H.N. receive honoraria from Alexion Pharmaceuticals. The remaining authors declare no competing financial interests.

Correspondence: Hideki Nakakuma, Department of Hematology/Oncology, Wakayama Medical University, 811-1 Kimiidera, Wakayama 641-8510, Japan; e-mail: hnakakum@wakayama-med.ac.jp.

References

1. Hillmen P, Hall C, Marsh JC, et al. Effect of eculizumab on hemolysis and transfusion requirements in patients with paroxysmal nocturnal hemoglobinuria. *N Engl J Med*. 2004;350(6):552-559.
2. Parker C. Eculizumab for paroxysmal nocturnal haemoglobinuria. *Lancet*. 2009;373(9665):759-767.
3. Kelly RJ, Hill A, Arnold LM, et al. Long-term treatment with eculizumab in paroxysmal nocturnal hemoglobinuria: sustained efficacy and improved survival. *Blood*. 2011;117(25):6786-6792.
4. Hill A, Rother RP, Arnold L, et al. Eculizumab prevents intravascular hemolysis in patients with paroxysmal nocturnal hemoglobinuria and unmasks low-level extravascular hemolysis occurring through C3 opsonization. *Haematologica*. 2010;95(4):567-573.
5. Risitano AM, Marando L, Seneca E, Rotoli B. Hemoglobin normalization after splenectomy in a paroxysmal nocturnal hemoglobinuria patient treated by eculizumab. *Blood*. 2008;112(2):449-451.
6. Fridkis-Hareli M, Storek M, Mazsaroff I, et al. Design and development of TT30, a novel C3d-targeted C3/C5 convertase inhibitor for treatment of the human complement alternative pathway-mediated diseases. *Blood*. 2011;118(17):4705-4713.
7. Skattum L, van Deuren M, van der Poll T, Truedsson L. Complement deficiency states and associated infections. *Mol Immunol*. 2011;48(14):1643-1655.
8. Yonemura Y, Kawakita M, Koito A, et al. Paroxysmal nocturnal haemoglobinuria with coexisting deficiency of the ninth component of complement: lack of massive haemolytic attack. *Br J Haematol*. 1990;74(1):108-113.
9. Nakakuma H, Kawaguchi T, Horikawa K, et al. Altered expression of gangliosides in erythrocytes of paroxysmal nocturnal hemoglobinuria. *J Clin Invest*. 1990;85(5):1456-1461.
10. Nakakuma H, Hidaka M, Nagakura S, et al. Expression of cryptantigen Th on paroxysmal nocturnal hemoglobinuria erythrocytes in association with a hemolytic exacerbation. *J Clin Invest*. 1995;96(1):201-206.