

Conflict-of-interest disclosure: The authors declare no competing financial interests.

Correspondence: Henri H. Versteeg, Ph.D., Einthoven Laboratory for Experimental Vascular Medicine, Leiden University Medical Center, Albinusdreef 2, Leiden, 2333 ZA, The Netherlands; e-mail: h.h.versteeg@lumc.nl.

References

- Ahamed J, Versteeg HH, Kerver M, et al. Disulfide isomerization switches tissue factor from coagulation to cell signaling. *Proc Natl Acad Sci U S A*. 2006; 103(38):13932-13937.
- Le DT, Rapaport SI, Rao LV. Relations between factor VIIa binding and expression of factor VIIa/tissue factor catalytic activity on cell surfaces. *J Biol Chem*. 1992;267(22):15447-15454.
- Kothari H, Rao LV, Pendurthi U. Cys186-Cys209 disulfide-mutated tissue fac-

- tor does not equal cryptic tissue factor: no impairment in decryption of disulfide mutated tissue factor. *Blood*. 2010;116(3):502-503.
- Pendurthi UR, Ghosh S, Mandal SK, Rao LV. Tissue factor activation: is disulfide bond switching a regulatory mechanism? *Blood*. 2007;110(12):3900-3908.
- Chen VM, Ahamed J, Versteeg HH, et al. Evidence for activation of tissue factor by an allosteric disulfide bond. *Biochemistry*. 2006;45(39):12020-12028.
- Ruf W, Versteeg HH. Tissue factor mutated at the allosteric Cys186-Cys209 disulfide bond is severely impaired in decrypted procoagulant activity. *Blood*. 2010;116(3):500-501.
- Reinhardt C, von Bruhl ML, Manukyan D, et al. Protein disulfide isomerase acts as an injury response signal that enhances fibrin generation via tissue factor activation. *J Clin Invest*. 2008;118(3):1110-1122.
- Kothari H, Nayak RC, Rao LV, Pendurthi UR. Cysteine 186-cysteine 209 disulfide bond is not essential for the procoagulant activity of tissue factor or for its de-encryption. *Blood*. 2010;115(21):4273-4283.
- Chang QL, Gummadi SN, Menon AK. Chemical modification identifies two populations of glycerophospholipid flippase in rat liver ER. *Biochemistry*. 2004; 43(33):10710-10718.

To the editor:

Haploidentical hematopoietic stem cell transplantation for graft-versus-host disease after liver transplantation

A 74-year-old woman with hepatitis C and hepatocellular carcinoma underwent deceased donor liver transplant (LT) from a male donor in August 2008. Donor and recipient were blood group A⁺ and 2-loci HLA matched (DR01 and DR15). Initial immunosuppression included a corticosteroid taper and tacrolimus. On postoperative day (POD) 28, she developed a papular erythematous rash, diarrhea, and neutropenia. Skin biopsy showed perivascular lymphocytic infiltrate with necrotic keratinocytes and full thickness epidermal necrosis. FISH analysis demonstrated XY-chimerism in both peripheral blood (29.2%) and skin (18.5%, 37/200 nuclei) consistent with graft-versus-host disease (GVHD). Bone marrow

biopsy showed < 10% cellularity with XY chimerism (2/10 nuclei) on karyotype analysis. Liver function tests were normal. High dose steroids and mycophenolate mofetil 500mg TID were added. The patient developed refractory neutropenia and thrombocytopenia. After failing a trial of IVIG (0.5mg/kg/d) and rabbit anti-thymocyte globulin (rATG; 1.5mg/kg/d), we sought a donor for rescue hematopoietic stem cell transplantation (HSCT) based on prior success with this strategy in GVHD following HSCT.¹

On POD 42 she received a haploidentical CD34⁺ selected (Baxter Isolex 300i) HSCT (2.01 × 10⁶ cells, CD3⁺ 0.3%) from her son (3-loci HLA match) after 7 days of rATG. A second

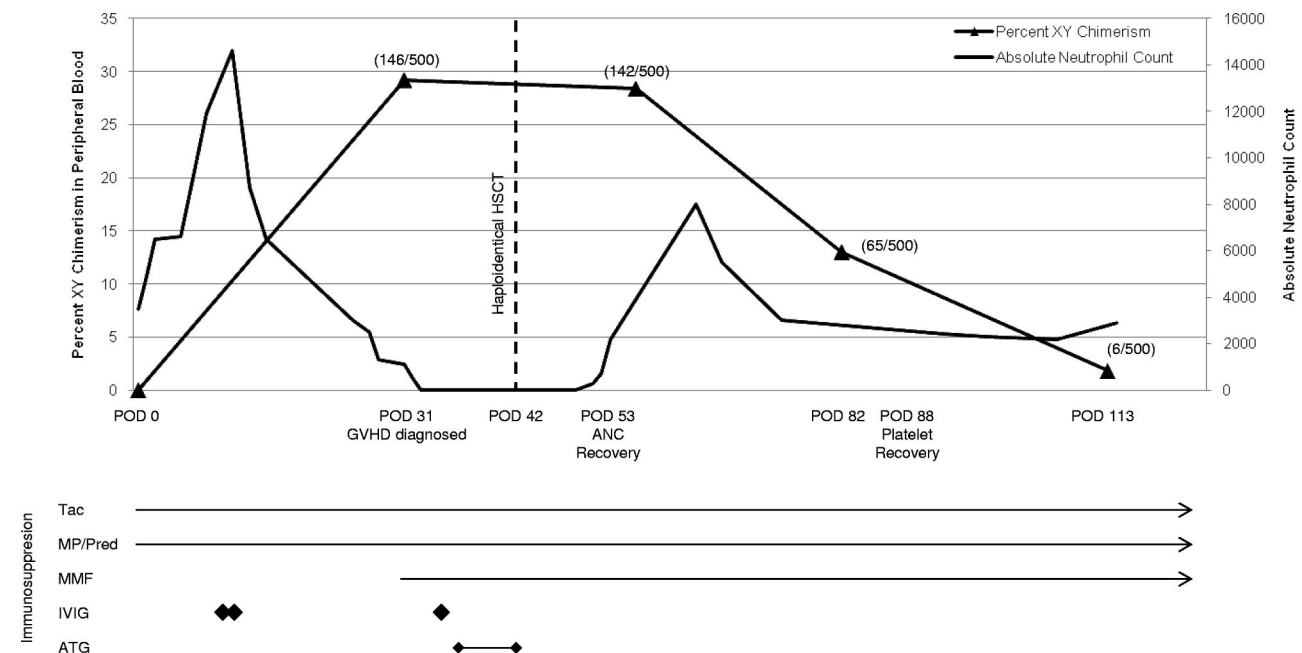


Figure 1. Trend in XY chimerism of peripheral blood relative to bone marrow function. Peripheral blood FISH analysis demonstrating XY chimerism (number of XY nuclei/total nuclei counted) with corresponding absolute neutrophil count (ANC) representing bone marrow function. Recovery of ANC occurred with XY chimerism suggesting either transient engraftment of son's cells or immunomodulatory effect of CD34⁺ infusion facilitating resolution of GVHD with subsequent stable marrow function and near complete restoration of patient XX chimerism on POD 113. Time of ANC recovery and platelet recovery are noted as defined by CIBMTR reporting standards. Timing of immunosuppression relative to clinical course is also noted.

infusion of 0.96×10^6 ($CD3^+ 0.4\%$) cells was given on POD 45. HSCT was not on study protocol. Informed consent was obtained from both patient and donor. Immunosuppression regimen at HSCT included tacrolimus, mycophenolate mofetil 500mg TID, and prednisone (30mg BID). Neutropenia and thrombocytopenia resolved 10 (POD 53) and 46 (POD 88) days after HSCT, respectively (Figure 1). Chimerism studies demonstrated transient XY chimerism of peripheral blood (13%) on POD 58 and near complete reconstitution of bone marrow with XX cells on POD 113 (98.85%; Figure 1). Thirty-two months after LT, she has stable liver graft function and normal hematopoietic cell lines.

Acute GVHD is a rare complication following LT with an estimated incidence of $< 1\%$ and a high mortality rate (80%).^{2,3} This is the first report of lymphodepletion followed by haploidentical HSCT for the management of GVHD following LT. After failure of traditional therapies involving augmentation of immunosuppression,^{4,6} we sought a novel intervention based on prior data demonstrating resolution of refractory GVHD following HSCT in 50% of patients after secondary allogeneic HSCT.¹

The mechanism of action is unclear. Graft-versus-tumor effect has been demonstrated with higher doses of $CD3^+$ infusions ($\geq 1 \times 10^8$ cells). Our mean $CD3^+$ yield post- $CD34^+$ selection of 0.35% (1×10^5 cells) measured by flow cytometry is below this reported threshold, making a direct cytotoxic graft-versus-graft effect possible but less likely.⁷ Transient engraftment has been reported as early as 10 days post-HSCT with subsequent restoration of recipient chimerism by as early as day 28.⁷ It is unclear if this occurred since STR analysis was not performed. $CD34^+$ progenitor cell modulation of antigen presentation may have contributed to resolution of GVHD, similar to mechanisms proposed in mesenchymal stem cell infusions.^{8,9} We conclude that rescue HSCT should be considered for GVHD following LT, as most cases are refractory to current approaches.

Michael Kriss

Department of Medicine, Division of Hepatology,
Northwestern University Feinberg School of Medicine,
Chicago, IL

Josephine Feliciano

Department of Medicine, Division of Hematology/Oncology,
Northwestern University Feinberg School of Medicine,
Chicago, IL

Jonathan Fryer

Department of Surgery, Division of Transplant Surgery,
Northwestern University Feinberg School of Medicine,
Comprehensive Transplant Center of Northwestern University,
Chicago, IL

Jayesh Mehta

Department of Medicine, Division of Hematology/Oncology,
Northwestern University Feinberg School of Medicine,
Robert H. Lurie Comprehensive Cancer Center of Northwestern University,
Chicago, IL

Josh Levitsky

Department of Medicine, Division of Hepatology,
Northwestern University Feinberg School of Medicine,
Comprehensive Transplant Center of Northwestern University,
Chicago, IL

Acknowledgments: All peripheral blood and skin chimerism studies were performed at the Cytogenetics Laboratory at Mayo Clinic (Rochester, MN). Bone marrow karyotype analysis was performed at Children's Memorial Hospital (Chicago, IL) by Dr Katrin Carlson Leuer.

Correspondence: Dr Josh Levitsky, Department of Medicine, Division of Hepatology, Northwestern University Feinberg School of Medicine, 676 N St Clair St, Arkes 19th Fl, Chicago, IL 60611; e-mail: j-levitsky@northwestern.edu.

References

1. Passweg JR, Orchard K, Buergi A, et al. Autologous/syngeneic stem cell transplantation to treat refractory GvHD. *Bone Marrow Transplant.* 2004;34(11):995-998.
2. Perri R, Assi M, Talwalkar J, et al. Graft vs. host disease after liver transplantation: a new approach is needed. *Liver Transpl.* 2007;13(8):1092-1099.
3. Pescatello LS, Guidry MA, Blanchard BE, et al. Exercise intensity alters postexercise hypotension. *J Hypertens.* 2004;22(10):1881-1888.
4. Alousi AM, Weisdorf DJ, Logan BR, et al. Etanercept, mycophenolate, denileukin, or pentostatin plus corticosteroids for acute graft-versus-host disease: a randomized phase 2 trial from the Blood and Marrow Transplant Clinical Trials Network. *Blood.* 2009;114(3):511-517.
5. Sullivan KM, Kopecky KJ, Jocom J, et al. Immunomodulatory and antimicrobial efficacy of intravenous immunoglobulin in bone marrow transplantation. *N Engl J Med.* 1990;323(11):705-712.
6. Caccavelli L, Field AC, Betin V, et al. Normal IgG protects against acute graft-versus-host disease by targeting CD4(+)CD134(+) donor alloreactive T cells. *Eur J Immunol.* 2001;31(9):2781-2790.
7. Colvin GA, Berz D, Ramanathan M, et al. Nonengraftment haploidentical cellular immunotherapy for refractory malignancies: tumor responses without chimerism. *Biol Blood Marrow Transplant.* 2009;15(4):421-431.
8. Beyth S, Borovsky Z, Mevorach D, et al. Human mesenchymal stem cells alter antigen-presenting cell maturation and induce T-cell unresponsiveness. *Blood.* 2005;105(5):2214-2219.
9. Le Blanc K, Frassoni F, Ball L, et al. Mesenchymal stem cells for treatment of steroid-resistant, severe, acute graft-versus-host disease: a phase II study. *Lancet.* 2008;371(9624):1579-1586.