

2 patients after the initiation of R-CHOP.<sup>1</sup> However, the strategy of antiviral therapy after completion of chemotherapy in the HCV-positive patient is attractive and was associated with improved outcomes in one small retrospective study.<sup>11</sup> The optimal timing of HCV antiviral therapy in aggressive lymphoma will require prospective study, and the results from Ennishi et al suggest that further efforts to prevent progressive liver failure after treatment are needed (see figure).

The greatest advance in the treatment of DLBCL in the past 2 decades has been the addition of rituximab to CHOP (or CHOP-like) chemotherapy, which has increased survival rates significantly in all subgroups with the disease.<sup>12</sup> Patients with DLBCL and HCV infection appear to derive similar benefits. Whether R-CHOP has an adverse effect on the long-term natural history of HCV infection and its complications similar to that reported after allogeneic hematopoietic cell transplantation is unclear.<sup>13</sup> It is clear that care must be used to monitor for acute and chronic hepatotoxicity associated with therapy, particularly in those with elevated transaminases at presentation or with underlying hepatic complications of HCV infection (including HCC). The role of antiviral therapy in aggressive lymphoma remains undefined and will require focused study.

*Conflict-of-interest disclosure: The author declares no competing financial interests.* ■

## REFERENCES

- Ennishi D, Maeda Y, Niitsu N, et al. Hepatic toxicity and prognosis in HCV-infected patients with diffuse large B-cell lymphoma treated with rituximab-containing chemotherapy regimens: a Japanese multicenter analysis. *Blood*. 2010;116(24):5119-5125.
- Armstrong GL, Wasley A, Simard EP, McQuillan GM, Kuhner WL, Alter MJ. The prevalence of hepatitis C virus infection in the United States, 1999 through 2002. *Ann Intern Med*. 2006;144(10):705-714.
- Giordano TP, Henderson L, Landgren O, et al. Risk of non-Hodgkin lymphoma and lymphoproliferative precursor diseases in US veterans with hepatitis C virus. *JAMA*. 2007;297(18):2010-2017.
- Morton LM, Engels EA, Holford TR, et al. Hepatitis C virus and risk of non-Hodgkin lymphoma: a population-based case-control study among Connecticut women. *Cancer Epidemiol Biomarkers Prev*. 2004;13(3):425-430.
- Mele A, Pulsoni A, Bianco E, et al. Hepatitis C virus and B-cell non-Hodgkin lymphomas: an Italian multicenter case-control study. *Blood*. 2003;102(3):996-999.
- Besson C, Canioni D, Lepage E, et al. Characteristics and outcome of diffuse large B-cell lymphoma in hepatitis C virus-positive patients in LNH 93 and LNH 98 Groupe d'Etude des Lymphomes de l'Adulte programs. *J Clin Oncol*. 2006;24(6):953-960.

- Visco C, Arcaini L, Brusamolino E, et al. Distinctive natural history in hepatitis C virus positive diffuse large B-cell lymphoma: analysis of 156 patients from northern Italy. *Ann Oncol*. 2006;17(9):1434-1440.
- Lake-Bakaar G, Dustin L, McKeating J, Newton K, Freeman V, Frost SD. Hepatitis C virus and alanine aminotransferase kinetics following B-lymphocyte depletion with rituximab: evidence for a significant role of humoral immunity in the control of viremia in chronic HCV liver disease. *Blood*. 2007;109(2):845-846.
- Hermine O, Lefrere F, Bronowicki JP, et al. Regression of splenic lymphoma with villous lymphocytes after treatment of hepatitis C virus infection. *N Engl J Med*. 2002;347(2):89-94.
- Niitsu N, Hagiwara Y, Tanaka K, Kohri M, Takahashi N. Prospective analysis of hepatitis B virus reactivation in

patients with diffuse large B-cell lymphoma after rituximab combination chemotherapy. [Published online ahead of print September 13, 2010]. *J Clin Oncol*. doi:10.1200/JCO.2010.29.7531.

- La Mura V, De Renzo A, Perna F, et al. Antiviral therapy after complete response to chemotherapy could be efficacious in HCV-positive non-Hodgkin's lymphoma. *J Hepatol*. 2008;49(4):557-563.
- Sehn LH, Donaldson J, Chhanabhai M, et al. Introduction of combined CHOP plus rituximab therapy dramatically improved outcome of diffuse large B-cell lymphoma in British Columbia. *J Clin Oncol*. 2005;23(22):5027-5033.
- Peffault de Latour R, Levy V, Asselah T, et al. Long-term outcome of hepatitis C infection after bone marrow transplantation. *Blood*. 2004;103(5):1618-1624.

## ● ● ● HEMATOPOIESIS & STEM CELLS

Comment on Shin et al, page 5162

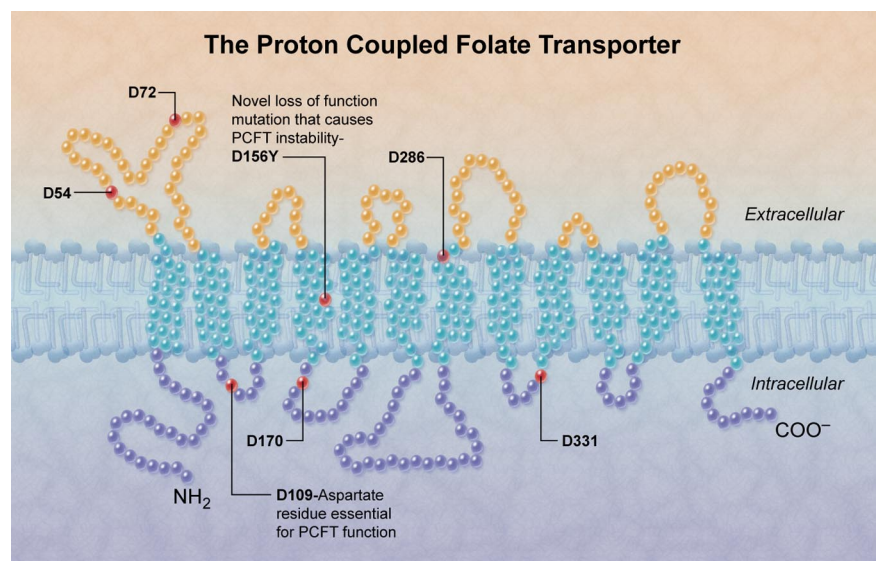
# ABC of D's in the folate transporter

Ralph Green UNIVERSITY OF CALIFORNIA DAVIS

Consanguinity “loads the dice” for turning up matching pairs when it comes to Mendelian inheritance of autosomal recessive genes. Such is the case in a novel loss-of-function mutation involving PCFT in a female infant with megaloblastic anemia, seizures, and severe growth retardation described by Shin et al in this issue of *Blood*.<sup>1</sup>

Using painstaking and elegant studies, Shin and colleagues characterized the molecular lesion involving the replacement of aspartate by tyrosine at position 156 in the human proton-coupled folate transporter

(PCFT) and its functional consequences in their patient. Then, using site-directed mutagenesis, they went on to describe that in the complex PCFT molecule that threads out and in through 12 transmembrane domains, 4 of



In the topologic diagram used by Shin et al<sup>1</sup> to depict the transmembrane proton-coupled folate receptor, the location of conserved aspartate residues is shown. Mutation of aspartate to tyrosine at position 156 is responsible for instability of the receptor and consequent hereditary folate malabsorption in the patient whom they describe. The aspartate at position 109 is essential for stability of the molecule. (Professional illustration by Alice Chen.)

the 6 conserved aspartate residues (designated “D” in amino acid notation) in the molecule (see figure) are permissive to change, but the other 2 (D109 and D156) are critical for function with resulting marked impairment or total loss of function when mutated. Why aspartate? This amino acid is more highly conserved than others because of several attributes that include a short side chain, a high charge density, strong polar interactions, and molecular rigidity.<sup>2</sup>

Recently, the same laboratory were the first to identify that PCFT plays a critical role in folate absorption from the relatively acidic milieu of the upper small intestine and transports folate into the brain through the blood, choroid plexus, cerebrospinal fluid conduit.<sup>3</sup> Unlike the reduced folate receptor, PCFT has a similar affinity for reduced folate and folic acid, at pH 5.5, ambient in the upper small intestine. A loss-of-function mutation affecting the *pcft* gene coding for this transmembrane protein was identified as the cause of hereditary folate malabsorption,<sup>3,4</sup> an uncommon cause of folate deficiency of previously obscure etiology that presents within the first few months of life and leads to death during early infancy if not treated. Since then, several mutations affecting various other critical amino acid residues have been described in individuals with hereditary folate malabsorption (HFM) and these have been reviewed recently.<sup>5,6</sup> Using a HELA cell subclone that lacks membrane folate transporters including PCFT, Shin and coworkers transiently transfected the cells with site-directed mutants of PCFTs and monitored functionality using tritiated methotrexate as surrogate cargo for the transporter.<sup>1</sup> The overall conclusions from these studies were that D156, located in the fourth transmembrane domain, is critical for PCFT protein stability. In addition, D109, in the first intracellular loop (between the second and third transmembrane domains) is absolutely essential for PCFT function, perhaps to maintain flexibility at what may be a critical hinge point in the molecule allowing for inward or outward flip-flop during the transport cycle.

Recommended treatment for HFM consists of parenteral injection of folate, preferably with folinic acid (5-formyl tetrahydrofolate), for correction of the anemia and central nervous system problems.<sup>6,7</sup> As emphasized in the recent comprehensive review of this topic,<sup>6</sup> the fact that folinic acid (leucovorin) has a

much higher affinity than folic acid for the reduced folate carrier proves important in the management of HFM. In addition, as further pointed out by the same group, folic acid can bind irreversibly to the folate receptor alpha in the choroid plexus, also required for transport across this organ, putatively blocking transport of reduced folate forms including leucovorin that provide rescue to a folate-deprived brain.<sup>8</sup>

More than just a tour de force of molecular exploration, the present publication has, at core, a happy ending. All too often, by the time that the diagnosis of HFM is made, the patient has sustained irreversible damage to the nervous system. The efficacy of oral folate (as occurred in the patient who formed the basis of the current study) is curious and suggests either passive diffusion or hobbled participation by the reduced folate carrier located on the apical brush border membrane of the small intestine that functions poorly at low pH. Sufficiently high blood folate concentrations presumably then could be attained to clear the choroid plexus hurdle. In the currently described patient, after treatment first with oral folic acid and then only later with supplementary folinic acid (1.6 mg/kg/d), the outcome was fortunately excellent. At age 18 months, she fell above the 95th percentile for weight, having attained normal developmental mile-

stones—a satisfying, though seemingly fortuitous, example of translational success.

*Conflict-of-interest disclosure: The author declares no competing financial interests.* ■

## REFERENCES

1. Shin DS, Min SH, Russel L, et al. Functional roles of aspartate residues of the human proton-coupled folate transporter (PCFT; SLC46A1): D156, mutated in hereditary folate malabsorption, is critical for protein stability, D109 is irreplaceable. *Blood*. 116(24):5162-5169.
2. Fiser A, Simon I, Barton GJ. Conservation of amino acids in multiple alignments: aspartic acid has unexpected conservation. *FEBS Lett*. 1996;397(2-3):225-229.
3. Qiu A, Jansen M, Sakaris A, et al. Identification of an intestinal folate transporter and the molecular basis for hereditary folate malabsorption. *Cell*. 2006;127(5):917-928.
4. Zhao R, Min SH, Qiu A, et al. The spectrum of mutations in the PCFT gene, coding for an intestinal folate transporter, that are the basis for hereditary folate malabsorption. *Blood*. 2007;110(4):1147-1152.
5. Zhao R, Matherly LH, Goldman ID. Membrane transporters and folate homeostasis: intestinal absorption and transport into systemic compartments and tissues. *Expert Rev Mol Med*. 2009;11:e4.
6. Mahadeo K, Min SH, Diop-Bove NK, Kronn D, Goldman ID. Hereditary folate malabsorption. *GeneReviews*. 2010. <http://www.ncbi.nlm.nih.gov/bookshelf/br.fcgi?book=gene&part=folate-mal>. Accessed September 2010.
7. Whitehead, VM. Acquired and inherited disorders of cobalamin and folate in children. *Br J Haematol*. 2006;134(2):125-136.
8. Zhao R, Min SH, Wang Y, Campanella E, Low PS, Goldman ID. A role for the proton-coupled folate transporter (PCFT-SLC46A1) in folate receptor-mediated endocytosis. *J Biol Chem*. 2009;284(7):4267-4274.

## ● ● ● IMMUNOBIOLOGY

Comment on Mei et al, page 5181

# A gut feeling about plasmablasts

David Tarlinton THE WALTER AND ELIZA HALL INSTITUTE OF MEDICAL RESEARCH

Detailed characterization of the plasma cell precursors that persist in patients' blood after rituximab treatment suggests a mucosal origin, potentially identifying a subset of B cells refractory to anti-CD20 depletion and capable of continued differentiation.

**R**ituximab, the CD20-specific antibody introduced more than 10 years ago as a therapy for non-Hodgkin B-cell lymphoma,<sup>1</sup> has since had its use extended with success into the treatment of several forms of autoimmune disease thought to have a B-cell component, including rheumatoid arthritis (RA) and systemic lupus erythematosus (SLE).<sup>2,3</sup> Although in some diseases there is a near complete ablation of autoantibodies after anti-

CD20 therapy, others—including RA and SLE—show a persistence of autoimmune disease markers. That is, despite almost complete B-cell deletion as measured in peripheral blood, aspects of autoimmune disease such as rheumatoid factor persist. While there is agreement that long-lived plasma cells resist CD20-mediated depletion due to their sessile lifestyle and low-level expression of CD20, the persistence of other B-cell types is less easily