



# Policy Statement—Ritual Genital Cutting of Female Minors

## abstract

The traditional custom of ritual cutting and alteration of the genitalia of female infants, children, and adolescents, referred to as female genital mutilation or female genital cutting (FGC), persists primarily in Africa and among certain communities in the Middle East and Asia. Immigrants in the United States from areas in which FGC is common may have daughters who have undergone a ritual genital procedure or may request that such a procedure be performed by a physician. The American Academy of Pediatrics believes that pediatricians and pediatric surgical specialists should be aware that this practice has life-threatening health risks for children and women. The American Academy of Pediatrics opposes all types of female genital cutting that pose risks of physical or psychological harm, counsels its members not to perform such procedures, recommends that its members actively seek to dissuade families from carrying out harmful forms of FGC, and urges its members to provide patients and their parents with compassionate education about the harms of FGC while remaining sensitive to the cultural and religious reasons that motivate parents to seek this procedure for their daughters. *Pediatrics* 2010;125:1088–1093

## INTRODUCTION

Ritual cutting and alteration of the genitalia of female infants, children, adolescents, and adults has been a tradition since antiquity. Female genital cutting (FGC) is most often performed between the ages of 4 and 10 years, although in some communities it may be practiced on infants or postponed until just before marriage.<sup>1</sup> Typically, a local village practitioner, lay person, or midwife is engaged for a fee to perform the procedure, which is done without anesthesia and by using a variety of instruments such as knives, razor blades, broken glass, or scissors. In developed countries, physicians may be sought to perform FGC under sterile conditions with the use of anesthesia.

The ritual and practice of FGC persists today primarily in Africa, the Middle East, and small communities in Asia.<sup>2</sup> Immigrants from these countries have brought the practice with them to Europe and North America, but no data are available for the prevalence of this practice in the West.<sup>3</sup>

The language to describe this spectrum of procedures is controversial. Some commentators prefer “female circumcision,” but others object that this term trivializes the procedure, falsely confers on it the respectability afforded to male circumcision in the West, or implies a medical context.<sup>4</sup> The commonly used “female genital mutilation” is

## COMMITTEE ON BIOETHICS

### KEY WORDS

female genital mutilation, FGM, female genital cutting, FGC

### ABBREVIATION

FGC—female genital cutting

This document is copyrighted and is property of the American Academy of Pediatrics and its Board of Directors. All authors have filed conflict of interest statements with the American Academy of Pediatrics. Any conflicts have been resolved through a process approved by the Board of Directors. The American Academy of Pediatrics has neither solicited nor accepted any commercial involvement in the development of the content of this publication.

[www.pediatrics.org/cgi/doi/10.1542/peds.2010-0187](http://www.pediatrics.org/cgi/doi/10.1542/peds.2010-0187)

doi:10.1542/peds.2010-0187

All policy statements from the American Academy of Pediatrics automatically expire 5 years after publication unless reaffirmed, revised, or retired at or before that time.

PEDIATRICS (ISSN Numbers: Print, 0031-4005; Online, 1098-4275).

Copyright © 2010 by the American Academy of Pediatrics

also problematic. Some forms of FGC are less extensive than the newborn male circumcision commonly performed in the West. In addition, “mutilation” is an inflammatory term that tends to foreclose communication and that fails to respect the experience of the many women who have had their genitals altered and who do not perceive themselves as “mutilated.”<sup>5</sup> It is paradoxical to recommend “culturally sensitive counseling” while using culturally insensitive language. “Female genital cutting” is a neutral, descriptive term.<sup>4</sup>

It is estimated that at least 100 million women have undergone FGC and that between 4 and 5 million procedures are performed annually on female infants and children, with the most severe types performed in Somali and Sudanese populations.<sup>6,7</sup> Pediatricians, therefore, may encounter patients who have undergone these procedures, and pediatric surgeons and pediatric urologists may be asked by patients or their parents to perform a ritual genital operation.

During the past 2 decades, several international and national humanitarian and medical organizations have drawn worldwide attention to the physical harms associated with FGC. The World Health Organization and the International Federation of Gynecology and Obstetrics have opposed FGC as a medically unnecessary practice with serious, potentially life-threatening complications.<sup>8,9</sup> The American College of Obstetricians and Gynecologists and the College of Physicians and Surgeons of Ontario, Canada, also opposed FGC and advised their members not to perform these procedures.<sup>10,11</sup> In 2006, the Council on Scientific Affairs of the American Medical Association reaffirmed its recommendation that all physicians in the United States strongly denounce all medically unnecessary procedures to alter female gen-

italia and promote culturally sensitive education about the physical consequences of FGC.<sup>12</sup>

FGC is illegal and subject to criminal prosecution in several countries, including Sweden, Norway, Australia, and the United Kingdom.<sup>13,14</sup> In the United States, federal legislation in 1996 criminalized the performance of FGC by practitioners on female infants and children or adolescents younger than 18 years and mandated development of educational programs at the community level and for physicians about the harmful consequences of the practice.<sup>15</sup> Various state laws exist as well.<sup>4</sup>

### CULTURAL AND ETHICAL ISSUES

FGC has been documented in individuals from many religions, including Christians, Muslims, and Jews.<sup>5</sup> The relationship of FGC and Islam is complex and controversial. Some of the most conservative Islamic societies, such as Saudi Arabia, do not practice FGC, whereas in some African settings, the primary motivation seems tribal and nationalistic rather than religious.<sup>16</sup> For many Muslim religious scholars, male circumcision is considered obligatory, whereas some form of female “circumcision” is considered optional but virtuous.<sup>17</sup> Across nations and cultures that practice FGC, the perception that it is religiously obligated or at least encouraged is ubiquitous.<sup>5</sup>

Kopelman<sup>18</sup> summarized 4 additional reasons proposed to explain the custom of FGC: (1) to preserve group identity; (2) to help maintain cleanliness and health; (3) to preserve virginity and family honor and prevent immorality; and (4) to further marriage goals, including enhancement of sexual pleasure for men. Preservation of cultural identity was noted by Toubia<sup>19</sup> to be of particular importance for groups that have previously faced colonialism and for immigrants threatened by a dominant culture. FGC is endemic in many poor societies in which

marriage is essential to women’s social and economic security. FGC becomes a physical sign of a woman’s marriageability, with social control over her sexual pleasure by clitorrectomy and over reproduction by infibulation (sewing together the labia so that the vaginal opening is about the width of a pencil).

When parents request a ritual genital procedure for their daughter, they believe that it will promote their daughter’s integration into their culture, protect her virginity, and, thereby, guarantee her desirability as a marriage partner. In some societies, failure to ensure a daughter’s marriageable status can realistically be seen as failure to ensure her survival.<sup>20</sup> It is tragic that the same procedure that made the daughter marriageable may ultimately contribute to her infertility.<sup>21</sup> Parents are often unaware of the harmful physical consequences of the custom, because the complications of FGC are attributed to other causes and are rarely discussed outside of the family.<sup>22</sup> Women from developing countries who are advocates for children’s health have differing perspectives on how to respond to FGC. Some activists put the campaign against FGC at the center of their work, but others complain that the West’s obsession with FGC masks an indifference to children’s suffering caused by famine, war, and infectious disease.<sup>23</sup>

The physical burdens and potential psychological harms associated with FGC violate the principle of nonmaleficence (a commitment to avoid doing harm) and disrupt the accepted norms inherent in the patient-physician relationship, such as trust and the promotion of good health. More recently, FGC has been characterized as a practice that violates the right of infants and children to good health and well-being, part of a universal standard of basic human rights.<sup>24</sup>

Protection of the physical and mental health of girls should be the overriding

concern of the health care community. Although physicians should understand that most parents who request FGC do so out of good motives, physicians must decline to perform procedures that cause unnecessary pain or that pose dangers to their patients' well-being.

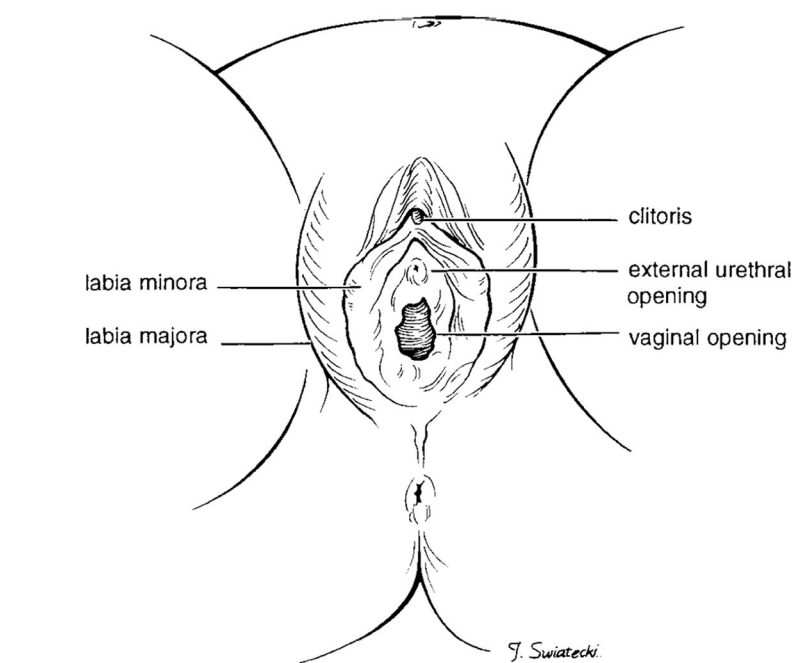
## TYPES OF FGC

Figure 1 shows the normal genital anatomy of a prepubertal female. The various ritual genital practices are classified into 4 types on the basis of severity of structural alteration.<sup>2</sup>

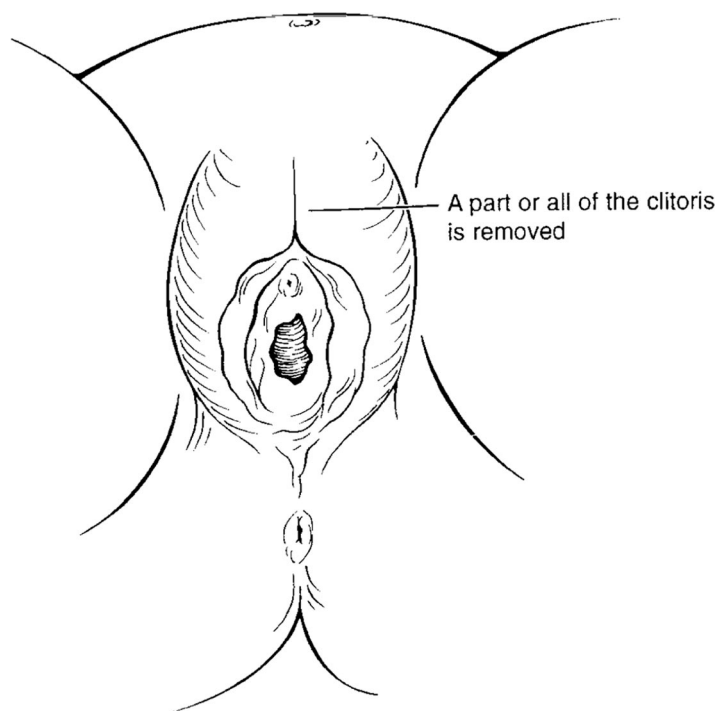
Type 1 FGC, often termed clitorrectomy, involves excision of the skin surrounding the clitoris with or without excision of part or all of the clitoris (Fig 2). When this procedure is performed on infants and young girls, a portion of or all of the clitoris and surrounding tissues may be removed. If only the clitoral prepuce is removed, the physical manifestation of type 1 FGC may be subtle, necessitating a careful examination of the clitoris and adjacent structures for recognition.

Type 2 FGC, referred to as excision, is the removal of the entire clitoris and part or all of the labia minora (Fig 3). Crude stitches of catgut or thorns may be used to control bleeding from the clitoral artery and raw tissue surfaces, or mud poultices may be applied directly to the perineum. Because of the absence of the labia minora and clitoris, females with type 2 FGC do not have the typical contour of the anterior perineal structures. The vaginal opening is not covered in the type 2 procedure.

Type 3 FGC, known as infibulation, is the most severe form, in which the entire clitoris and some or all of the labia minora are excised, and incisions are made in the labia majora to create raw surfaces (Fig 4). The labial raw surfaces are stitched together to cover the urethra and vaginal introitus, leaving a small posterior opening for urinary and menstrual flow. In type 3 FGC, the patient will have a firm band of tissue replacing the labia and obscuring the urethral and vaginal openings.

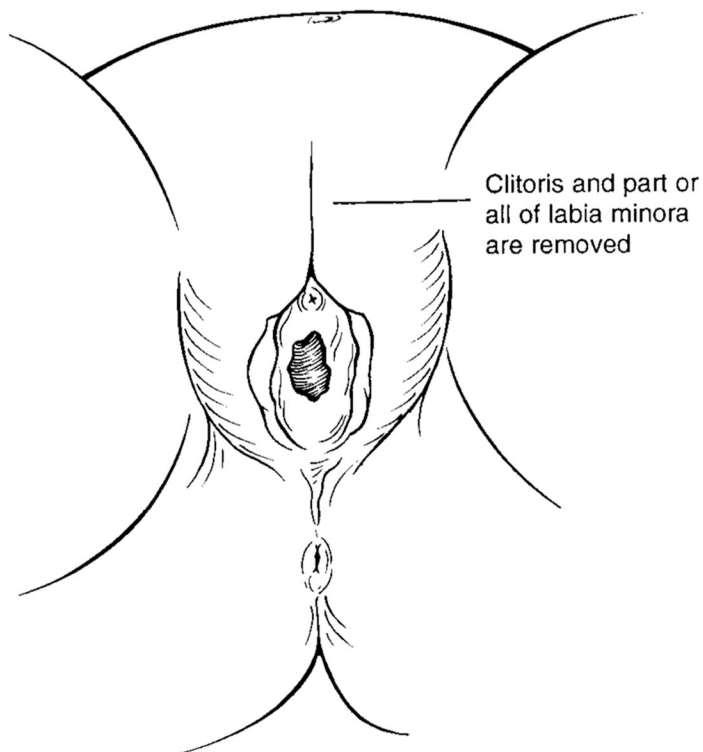


**FIGURE 1**  
Normal female genital anatomy.

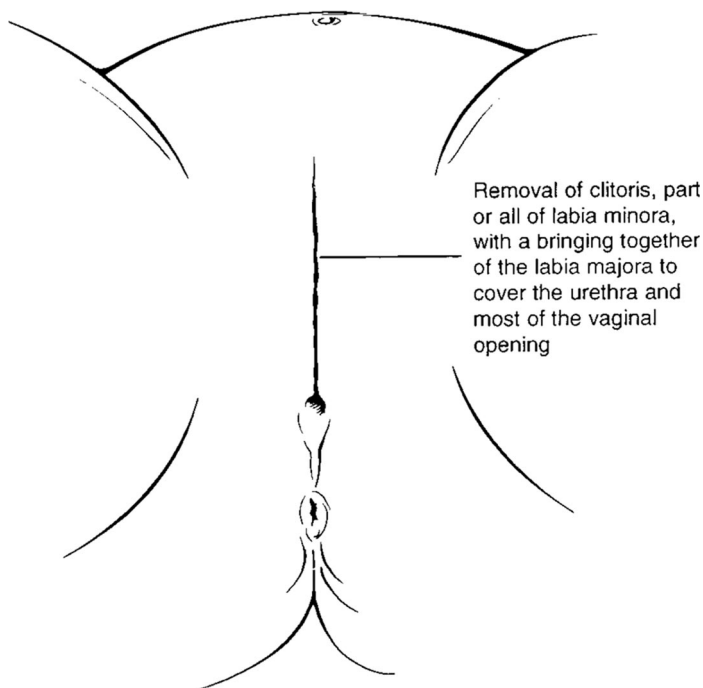


**FIGURE 2**  
Type 1 female genital mutilation.

Type 4 FGC includes different practices of variable severity, including pricking, piercing, or incising the clitoris and/or labia; stretching the clitoris and/or



**FIGURE 3**  
Type 2 female genital mutilation.



**FIGURE 4**  
Type 3 female genital mutilation.

labia; cauterizing the clitoris; and scraping or introducing corrosive substances into the vagina.

The physical complications associated with FGC may be acute or chronic. Early, life-threatening risks include

hemorrhage, shock secondary to blood loss or pain, local infection and failure to heal, septicemia, tetanus, trauma to adjacent structures, and urinary retention.<sup>25,26</sup> Infibulation (type 3 FGC) is often associated with long-term gynecologic or urinary tract difficulties. Common gynecologic problems involve the development of painful subcutaneous dermoid cysts and keloid formation along excised tissue edges. More serious complications include pelvic infection, dysmenorrhea, hematocolpos, painful intercourse, infertility, recurrent urinary tract infection, and urinary calculus formation. Pelvic examination is difficult or impossible for women who have been infibulated, and vaginal childbirth can present significant challenges. Scarring may prevent accurate monitoring of labor and fetal descent. Although deinfibulation may facilitate delivery, women who have undergone deinfibulation are at increased risk of complications, including perineal tears, wound infections, separation of repaired episiotomies, postpartum hemorrhage, and sepsis.<sup>27</sup>

Less well-understood are the psychological, sexual, and social consequences of FGC, because little research has been conducted in countries where the practice is endemic.<sup>28</sup> However, personal accounts by women who have had a ritual genital procedure recount anxiety before the event, terror at being seized and forcibly held during the event, great difficulty during childbirth, and lack of sexual pleasure during intercourse.<sup>29</sup> Some women have no recollection of the event, particularly if it was performed in their infancy. Other women have described the event in joyful terms, as a communal ritual that inducted them into adult female society.<sup>30</sup>

## EDUCATION OF PATIENTS AND PARENTS

An educational program about FGC requires, above all, sensitivity to the cultural background of the patient and her parents and an appreciation of the significance of this custom in their tradition.<sup>5</sup> Objective information should include a detailed explanation of female genital anatomy and function, as well as a thorough review of the lifelong physical harms and psychological suffering associated with most forms of FGC. It should be emphasized that many countries in Africa have supported efforts to educate the public about the serious negative health effects of FGC and that prominent physicians from Africa are advocates for the elimination of these practices because of their adverse consequences. Pediatricians and pediatric surgical specialists who care for patients from populations known to practice FGC commonly, such as Somali, Ethiopian, Eritrean, and Sudanese communities, should be aware of local counseling centers. Successful educational programs typically require the active involvement and leadership of immigrant women, whose experience and knowledge can address the health, social status, and legal aspects of FGC. Health educators must also be prepared to explain to parents from outside North America why male genital alteration is routinely practiced here but female genital alteration is routinely condemned.<sup>31</sup>

Some physicians, including pediatricians who work closely with immigrant populations in which FGC is the norm, have voiced concern about the adverse effects of criminalization of the practice on educational efforts.<sup>32</sup> These physicians emphasize the significance of a ceremonial ritual in the initiation of the girl or adolescent as a

community member and advocate only pricking or incising the clitoral skin as sufficient to satisfy cultural requirements. This is no more of an alteration than ear piercing. A legitimate concern is that parents who are denied the cooperation of a physician will send their girls back to their home country for a much more severe and dangerous procedure or use the services of a non-medically trained person in North America.<sup>33,34</sup> In some countries in which FGC is common, some progress toward eradication or amelioration has been made by substituting ritual "nicks" for more severe forms.<sup>2</sup> In contrast, there is also evidence that medicalizing FGC can prolong the custom among middle-class families (eg, in Egypt).<sup>35</sup> Many anti-FGC activists in the West, including women from African countries, strongly oppose any compromise that would legitimize even the most minimal procedure.<sup>4</sup> There is also some evidence (eg, in Scandinavia) that a criminalization of the practice, with the attendant risk of losing custody of one's children, is one of the factors that led to abandonment of this tradition among Somali immigrants.<sup>36</sup> The World Health Organization and other international health organizations are silent on the pros and cons of pricking or minor incisions. The option of offering a "ritual nick" is currently precluded by US federal law, which makes criminal any nonmedical procedure performed on the genitals of a female minor.

The American Academy of Pediatrics policy statement on newborn male circumcision expresses respect for parental decision-making and acknowledges the legitimacy of including cultural, religious, and ethnic traditions when making the choice of whether to surgically alter a male infant's genitals. Of course, parental decision-making is not without limits, and pediatricians must always

resist decisions that are likely to cause harm to children. Most forms of FGC are decidedly harmful, and pediatricians should decline to perform them, even in the absence of any legal constraints. However, the ritual nick suggested by some pediatricians is not physically harmful and is much less extensive than routine newborn male genital cutting. There is reason to believe that offering such a compromise may build trust between hospitals and immigrant communities, save some girls from undergoing disfiguring and life-threatening procedures in their native countries, and play a role in the eventual eradication of FGC. It might be more effective if federal and state laws enabled pediatricians to reach out to families by offering a ritual nick as a possible compromise to avoid greater harm.

Efforts should be made to use all available educational and counseling resources to dissuade parents from seeking a ritual genital procedure for their daughter. For circumstances in which an infant, child, or adolescent seems to be at risk of FGC, the American Academy of Pediatrics recommends that its members educate and counsel the family about the detrimental health effects of FGC. Parents should be reminded that performing FGC is illegal and constitutes child abuse in the United States.

## RECOMMENDATIONS

The American Academy of Pediatrics:

1. Opposes all forms of FGC that pose risks of physical or psychological harm.
2. Encourages its members to become informed about FGC and its complications and to be able to recognize physical signs of FGC.
3. Recommends that its members actively seek to dissuade families



from carrying out harmful forms of FGC.

4. Recommends that its members provide patients and their parents with compassionate education about the physical harms and psychological risks of FGC while remaining sensitive to the cultural and religious reasons that motivate parents to seek this procedure for their daughters.

## REFERENCES

1. Toubia N. Female circumcision as a public health issue. *N Engl J Med*. 1994;331(11):712–716
2. World Health Organization. Female genital mutilation (FGM). Available at: [www.who.int/reproductive-health/fgm/index.html](http://www.who.int/reproductive-health/fgm/index.html). Accessed May 6, 2009
3. Strickland JL. Female circumcision/female genital mutilation. *J Pediatr Adolesc Gynecol*. 2001;14(3):109–112
4. Davis DS. Male and female genital alteration: a collision course with the law? *Health Matrix Clevel*. 2001;11(2):487–570
5. Lane SD, Rubinstein RA. Judging the other: responding to traditional female genital surgeries. *Hastings Cent Rep*. 1996;26(3):31–40
6. Kouba LJ, Muasher J. Female circumcision in Africa: an overview. *Afr Stud Rev*. 1985;28(1):95–110
7. Ntiri DW. Circumcision and health among rural women of southern Somalia as part of a family life survey. *Health Care Women Int*. 1993;14(3):215–226
8. World Health Organization. *UN Agencies Call for End to Female Genital Mutilation*. Geneva, Switzerland; World Health Organization; 1997
9. World Health Organization, International Federation of Gynecology and Obstetrics. Female circumcision: female genital mutilation. *Eur J Obstet Gynecol Reprod Biol*. 1992;45(2):153–154
10. American College of Obstetricians and Gynecologists. *Committee Opinion: Female Genital Mutilation*. Washington, DC: American College of Obstetrics and Gynecology; 1995
11. College of Physicians and Surgeons of Ontario. *New Policy: Female Circumcision, Excision and Infibulation*. Toronto, Ontario, Canada: College of Physicians and Surgeons of Ontario; 1992
12. Council on Scientific Affairs. Female genital mutilation. *JAMA*. 1995;274(21):1714–1716
13. Government Offices of Sweden, Ministry of Health and Social Affairs. Act Prohibiting the Genital Mutilation of Women. 1995;SFS 1982:316
14. United Kingdom Female Genital Mutilation Act 2003. Chapter 31. Available at: [www.opsi.gov.uk/acts/acts2003/pdf/ukpga\\_20030031\\_en.pdf](http://www.opsi.gov.uk/acts/acts2003/pdf/ukpga_20030031_en.pdf). Accessed May 6, 2009
15. Illegal Immigration Reform and Immigrant Responsibility Act of 1996. Pub L No. 104–208
16. Douglas J. Female circumcision: persistence amid conflict. *Health Care Women Int*. 1998;19(6):477–479
17. Winkel E. A Muslim perspective on female circumcision. *Women Health*. 1995;23(1):1–7
18. Kopelman LM. Female circumcision/genital mutilation and ethical relativism. *Second Opin*. 1994;20(2):55–71
19. Toubia N. *Female Genital Mutilation: A Call for Global Action*. New York, NY: RAINBo; 1995
20. Teare P. Culture shock. *Nurs Times*. 1998;94(27):34–35
21. Almroth L, Elmusharaf S, El Hadi N, et al. Primary infertility after genital mutilation in girlhood in Sudan: a case-control study. *Lancet*. 2005;366(9483):385–391
22. Female circumcision/genital mutilation. *Forward News*. 1990;2:1–10
23. Gruenbaum E. The cultural debate over female circumcision: the Sudanese are arguing this one out for themselves. *Med Anthropol Q*. 1996;10(4):455–475
24. James SA. Reconciling international human rights and cultural relativism: the case of female circumcision. *Bioethics*. 1994;8(1):1–26
25. Institute for Development Training. *Health Effects of Female Circumcision*. Chapel Hill, NC: Institute for Development Training; 1986
26. Armstrong S. Female circumcision: fighting a cruel tradition. *New Sci*. 1991;129(1754):42–48
27. Nour N. Female genital cutting: clinical and cultural guidelines. *Obstet Gynecol Surv*. 2004;59(4):272–279
28. Dorkenoo E, Elworthy S. *Female Genital Mutilation. Proposals for Change*. London, England: Minority Rights Group; 1992
29. Crossette B. Female genital mutilation by immigrants is becoming cause for concern in the US. *New York Times*. December 10, 1995:118
30. Gibeau AM. Female genital mutilation: when a cultural practice generates clinical and ethical dilemmas. *J Obstet Gynecol Neonatal Nurs*. 1998;27(1):85–91
31. Abu-Sahlieh SA. To mutilate in the name of Jehovah or Allah: legitimization of male and female circumcision. *Med Law*. 1994;13(7–8):575–622
32. Kelley T. Doctor fights ban on circumcising girls. *Seattle Times*. June 6, 1996:B3
33. Ostrom C. Harborview debates issue of circumcision of Muslim girls. *Seattle Times*. September 13, 1996:A15
34. Hamm L. Immigrants bring the practice of female circumcision to the U.S. *Associated Press*. December 1, 1996; Domestic News
35. El-Gibaly O, Ibrahim B, Mensch BS, Clark WH. The decline of female circumcision in Egypt: evidence and interpretation. *Soc Sci Med*. 2002;54(2):205–220
36. Essén B, Johnsdotter S. Female genital mutilation in the West: traditional circumcision versus genital cosmetic surgery. *Acta Obstet Gynecol Scand*. 2004;83(7):611–613

## COMMITTEE ON BIOETHICS, 2006–2007

Douglas S. Diekema, MD, MPH, Chairperson  
Armand H. Matheny Antommara, MD, PhD  
Mary E. Fallat, MD  
Ian R. Holzman, MD  
Steven R. Leuthner, MD  
Lainie F. Ross, MD, PhD  
Sally Webb, MD

## LIAISONS

Philip Baese, MD – *American Academy of Child and Adolescent Psychiatry*

Jeffrey L. Ecker, MD – *American College of Obstetricians and Gynecologists*  
Marcia Levetown, MD – *American Board of Pediatrics*  
Ellen Tsai, MD, MHS – *Canadian Paediatric Society*

## CONSULTANT

\*Dena S. Davis, JD, PhD

## STAFF

Alison Baker, MS  
abaker@aap.org

\*Lead author